

Analysis of Cases of Posterior Segment Diseases Attending Retina Clinic of Assam Medical College

Dr. (Mrs) M. Borooh¹, Dr. Sunanda Nandi²

¹(Associate Professor, Department of Ophthalmology, Assam Medical College & Hospital; Dibrugarh, Assam; India)

²(Post- Graduate Student, Department of Ophthalmology, Assam Medical College & Hospital; Dibrugarh, Assam; India)

Corresponding Author: Dr. (Mrs) M. Borooh

Abstract:

Objective: To determine the disease pattern of patients attending retina clinic of assam medical college, dibrugarh.

Materials and Methods: A retrospective hospital based analysis of 385 cases visiting Retina Clinic of Assam Medical College over a period of one year was carried out in order to know the disease pattern for planning purpose.

Results: Out of 23,241 new patients, 385 patients attended retina clinic over a period of one year. Males outnumbered females (67.53% versus 32.46%). The diseases were common in the age group between 50-59 years. Diabetic retinopathy was the commonest cause for attendance in retina clinic (35.58%) with CSME in 43.06% DR cases, followed by ARMD and hypertensive retinopathy changes.

Keywords: posterior segment diseases pattern, diabetic retinopathy, ARMD, hypertensive retinopathy

Date of Submission: 26-06-2019

Date of acceptance: 13-07-2019

I. Introduction

Unlike the affections in anterior segment of the eye, the diseases affecting retina are mostly irreversible and often sight threatening. The set up for their evaluation and management especially surgical is expensive and for average Assam population the treatment is not affordable unless subsidized by the hospital. Assam has the highest instance of blindness in the country followed by Arunachal Pradesh. This was revealed at the 14th annual conference of Vision 2020 held on 9th and 10th June 2018 in Guwahati, Assam. According to the Rapid Assessment of Avoidable Blindness Survey 2003, the prevalence of blindness in Assam is 3.05 per cent and 2.28 per cent in Arunachal Pradesh. However recent data on magnitude of posterior segment disease of this region is not available but the impression based on hospital practice shows that the problem is on rise.

II. Material And Methods

Place of study: Assam Medical College, dibrugarh

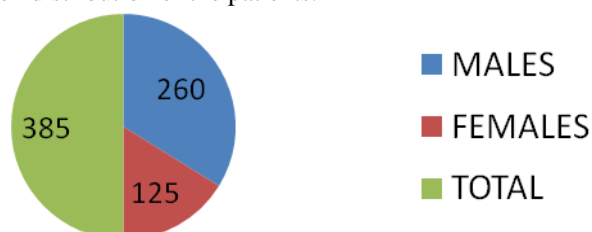
Duration of study: 12 months (June 2017- may 2018)

Type of study : retrospective study

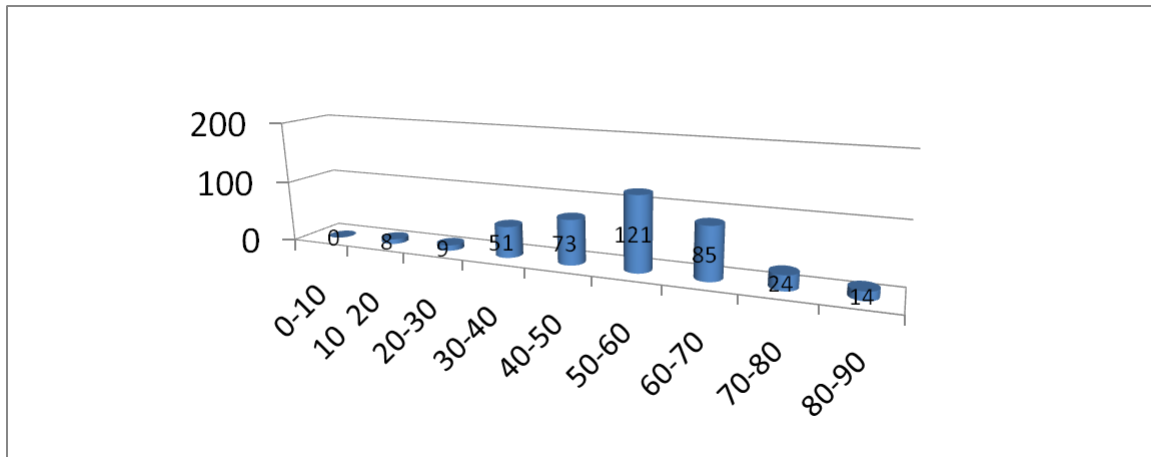
Data was taken from the hospital records and were analyzed to determine their **age, sex distribution and diagnosis**. All patients underwent visual acuity, refraction, slit lamp examination and pupil dilatation for fundus evaluation with binocular indirect ophthalmoscope and slit lamp using 20D and 90D lenses respectively.

III. Result

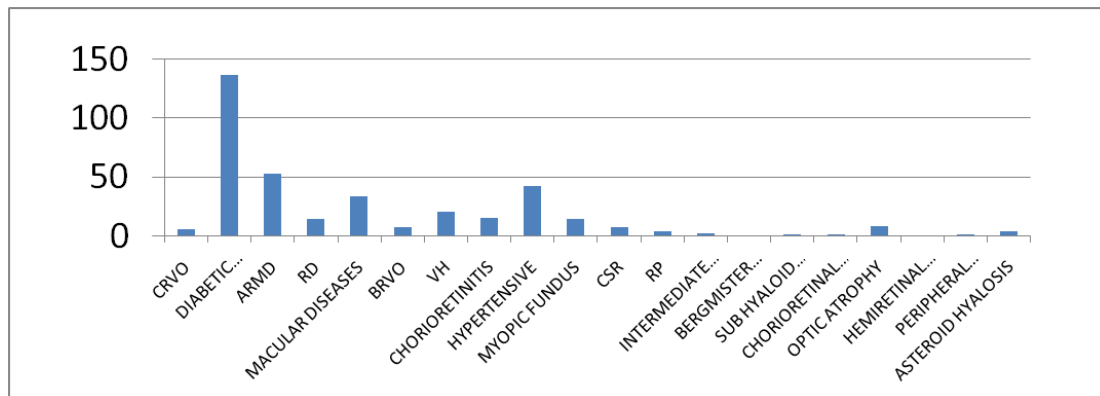
The following diagram shows the sex distribution of the patients.



The following diagram shows the age distribution of the patients. The majority of the patients were seen in the age group between 50-60 years.



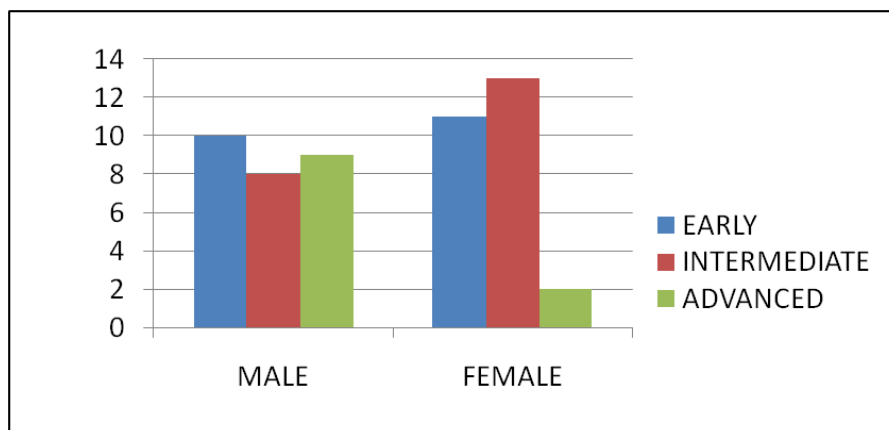
The following diagram shows the distribution of the patients according to the disease pattern.



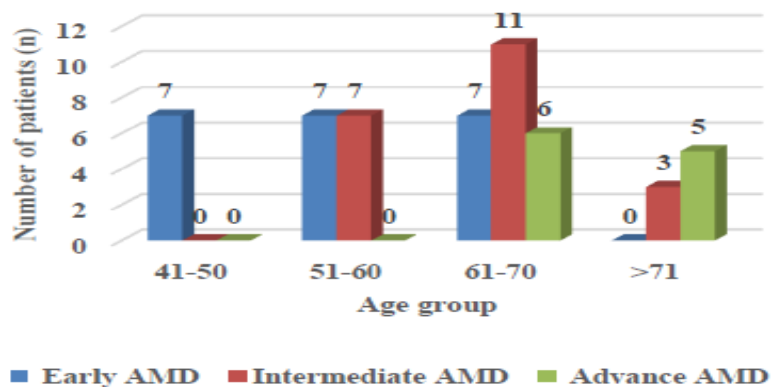
It appeared that **diabetes** with or without retinopathy was the commonest cause for attendance in retina clinic followed by ARMD and hypertensive disorders.

IV. ARMD Cases

Out of 53 patients 27 were males (50.94%) and 26 were females (49.06%). In males 10 patients were having early AMD, 8 patients were having intermediate AMD and 9 patients were having advanced AMD. In females 11 patients were having early AMD, 13 patients were having intermediate AMD and 2 patients were having advanced AMD.


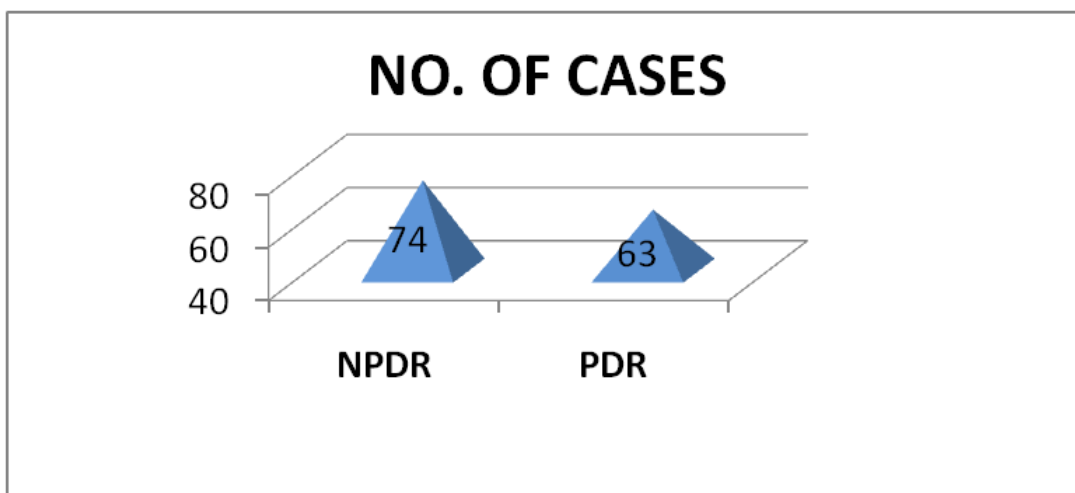


In the age group 41-50 years all the cases were of early AMD (7 cases). In the age group 51-60 years there were equal number of early and intermediate AMD cases. (7 cases in each group).

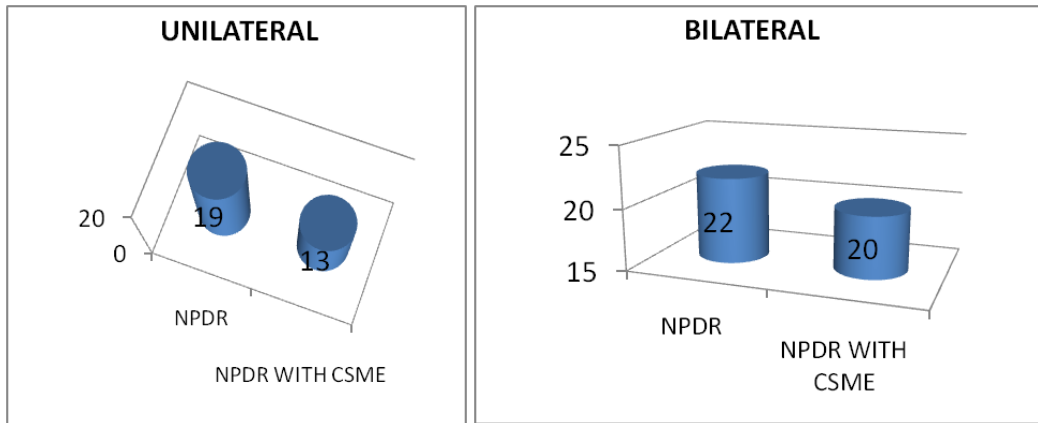


DIABETIC RETINOPATHY


There were 137 cases of diabetic retinopathy consisting of both NPDR and PDR changes.



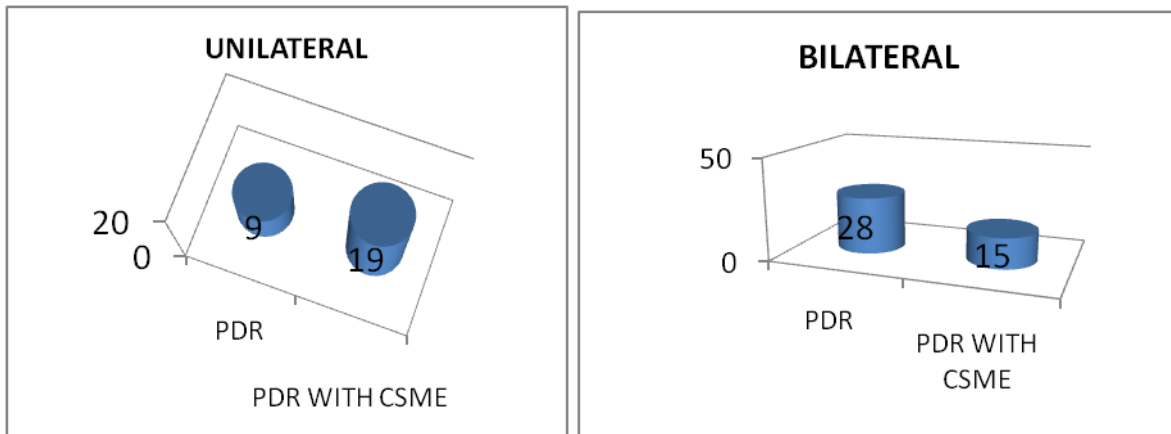
NPDR WITH CSME

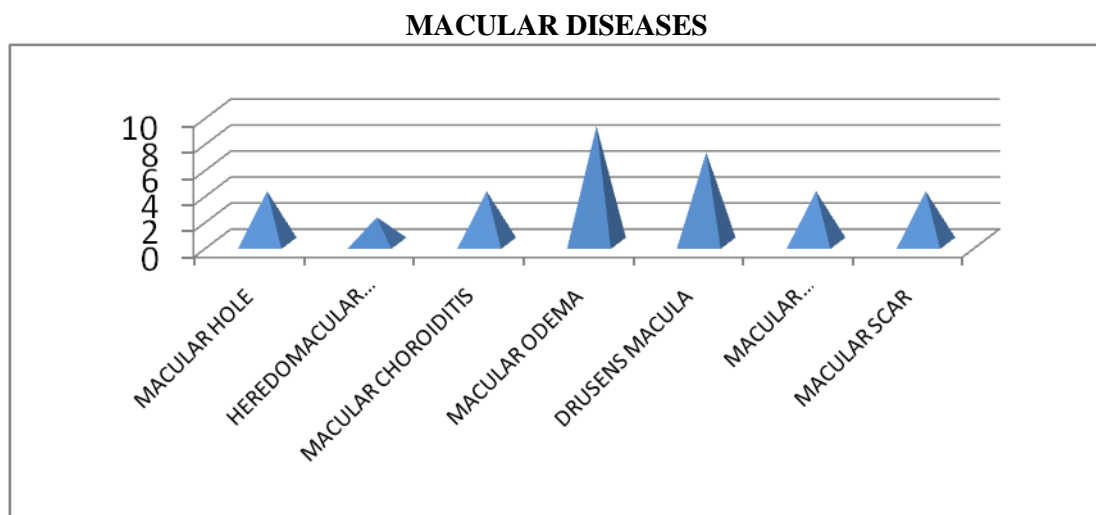


PDR CASES



PDR WITH CSME





Therefore ocular involvement due to diabetes is a common occurrence which lead to visual impairment or permanent visual loss. Hence diabetic patients should be timely screened, evaluated and treated.

V. Discussion

The trend of retinal blindness has changed its pattern over the years in developing countries¹. A decade ago, hereditary retinal disorders formed the major cause of visual loss due to retinal diseases. With the improvement in health and science, Diabetic retinopathy, age-related macular degeneration (ARMD) and retinopathy of prematurity (ROP) have become the important and increasing causes of retinal blindness¹.

In our study, the results were consistent with the other parts of the country, with diabetic retinopathy(35.58%) being the major cause of retinal blindness followed by ARMD(13.76%) changes,hypertensive retinopathy(11.10%),macular disease(8.83%).

A cross-sectional study of diabetic patients was conducted as an initiative of the All India Ophthalmological Society from 14th November to 21st November 2014 which showed that DR prevalence in the entire data set was 21.7% which demands its need for screening and treatment.²

The prevalence of ARMD ranges from 0.6 to 1.1% in developing countries with the exception of certain countries such as Pakistan and Bangladesh.³ *In our study the percentage of ARMD changes was found to be 13.76%.*

Samuel et al in a study in southwestern Nigeria found that 3131 cases were reviewed of which 407(13%) patients presented **with retinal diseases**. Their male:female ratio 1.3:1 (P=0.05). Macula diseases (35.6%), hypertensive retinopathy (12%), retinochoroiditis (11.5%) and diabetic retinopathy (9.6%) were the predominant retinal diseases.⁴

In another study, *Amil khan et al* in a study in karachi found that out of 27,000, 3615 patients were registered in retina clinic. It was found that 648 (45% of total DR) patients had clinically significant macular edema (CSME).⁵

However in our study, out of 23,241 new patients,385 patients attended retina clinic over a period of one year. Males outnumbered females(67.53% versus 32.46%). The diseases were common in the age group between 50-59 years. Diabetic retinopathy was the commonest cause for attendance in retina clinic(35.58%) with CSME in 43.06% DR cases, followed by ARMD and hypertensive RP changes.

Suman S thapa et al in a study in Nepal found that the prevalence of vitreo-retinal disorders in this Nepalese population was 5.35%, which increased significantly with age. ARMD was the predominant retinal condition followed by diabetic retinopathy⁶. *However in our study ARMD was the second most predominant retinal condition to cause poor vision.*

VI. Conclusion

In our study we also found other vitreo-retinal diseases causing vision impairment uncorrected by refraction or other modalities, therefore patients should be always encouraged for a fundus examination to identify lacunae in the current process of case detection and improve future screening programs.

References

- [1]. Nazimul H, Rohit K, Anjli H. Trend of retinal diseases in developing countries. *Expert Review of Ophthalmology*. 2008 Feb 1;3(1):43-50.
- [2]. Gadkari SS, Maskati QB, Nayak BK. Prevalence of diabetic retinopathy in India: The all India ophthalmological society diabetic retinopathy eye screening study 2014. *Indian journal of ophthalmology*. 2016 Jan;64(1):38.
- [3]. Srinivasan S, Swaminathan G, Kulothungan V, Raman R, Sharma T. Prevalence and the risk factors for visual impairment in age-related macular degeneration. *Eye*. 2017 Jun;31(6):846.
- [4]. Uhumwangho OM, Itina EI. Retinal diseases in a tertiary hospital in southern Nigeria. *Journal of the West African College of Surgeons*. 2015 Apr;5(2):1.
- [5]. Khan A, Riaz Q, Soomro F, Qidwai U, Qazi U. Frequency and patterns of eye diseases in retina clinic of a tertiary care hospital in Karachi. *Pak J Ophthalmol*. 2011;27(3):155-9.
- [6]. Thapa SS, Thapa R, Paudyal I, Khanal S, Aujla J, Paudyal G, van Rens G. Prevalence and pattern of vitreo-retinal diseases in Nepal: the Bhaktapur glaucoma study. *BMC ophthalmology*. 2013 Dec;13(1):9.

Dr. (Mrs) M. Borooah. "Analysis of Cases of Posterior Segment Diseases Attending Retina Clinic of Assam Medical College." *IOSR Journal of Dental and Medical Sciences (IOSR-JDMS)*, vol. 18, no. 7, 2019, pp 20-25