

Variations in the Location of Formation of Median Nerve and Multiple Lateral Roots of the Median Nerve.

Pritik Shah¹, Divya Srinivasan², Dr. Pushpa M S³, Dr. Meenakshi Parthasarathy⁴

1. Undergraduate, Bangalore Medical College and Research Institute.

2. Undergraduate, Bangalore Medical College and Research Institute.

3. Assistant Professor of Department of Anatomy of Bangalore Medical College and Research Institute.

4. Professor of Department of Anatomy of Bangalore Medical College and Research Institute.

Corresponding Author: Pritik Shah

Abstract: Introduction:- Variations in the arrangement and distribution of brachial plexus and its branches have been commonly noted. These variations are significant for neurologists, surgeons, anaesthetists and anatomists.

Aims and Objectives:- To analyse and study the anatomical and morphological variations of the formation of the median nerve via the roots of the lateral cord and medial cord.

Materials and Methods :- A total 52 brachial plexuses were isolated post dissection from 26 middle aged cadavers and the formation of the median nerve was studied and analysed with fine dissection methods.

Results :- This Study has helped to achieve the following variations in the Location of formation of the Median Nerve in South Indian Population - Formation at Lateral or Anterior side of 3rd Part of Axillary Artery(80.77%) , Formation at the 2nd Part of Axillary Artery(7.69%) , Formation at the Brachial Artery Proximal to the Insertion of Coracobrachialis(7.69%) and Formation at the Brachial Artery Distal to the Insertion of Coracobrachialis(3.84%) This Study has also helped to understand the variation in the roots of the Median Nerve as follows - Two Roots with one medial and lateral root(92.31%) , Three Roots with two lateral roots originating from same location of Lateral Cord (3.84%) and different locations on the Lateral Cord (3.84%).

Conclusion:- This case study shows Anomalies of the nerve structures which would be one of the sources of atypical anatomical findings, which could lead to surgical errors. Variations in the formation of median nerve may be of critical importance for surgeons and anaesthesiologists, while they carry out procedures.

Key Word – Median Nerve(MN) , Roots (Lateral and Medial) , Formation , Variation , Anomalies .

Date of Submission: 26-06-2019

Date of acceptance: 13-07-2019

I. Introduction

Anatomy of peripheral nerve formation and distribution can vary. Knowledge of such variations is important in clinical practice for evaluation of nerve injuries without misinterpretation of clinical symptoms and during surgeries of limbs to prevent accidental injuries to nerves. Median nerve is one of the nerves that show multiple variations in its formation, communications and distribution. There are number of studies done on abnormal communications of the median nerve in the axilla and arm. But there are only few studies have been done to find out variations of median nerve formations and its relation to the arteries in the axilla and arm. Therefore the main aim of this study was to identify anatomical variation of the median nerve formation and to find out the site of formation of median nerve in relation to Axillary artery(AA) and Brachial Artery(BrA).

The cords and branches of the brachial plexus are one of the major contents of the axilla, which lie in relation to the axillary artery. Classically, the Median Nerve is formed by the joining of a single lateral root and a single medial root, given off from the lateral and medial cords of brachial plexus respectively. The lateral and medial roots of MN are located on respective sides of AA. The **medial root of the MN (MRMN)** crosses the AA superficially, to reach its lateral side and joins the **lateral root (LRMN)** to form the MN. This results in the formation of MN lateral to the AA. Then, until the lower third of the arm, the MN runs on the lateral aspect of brachial artery, where it crosses the medial side of the brachial artery and later becomes a content of the cubital fossa. The Variations in the Formation of the MN with identified multiple LRMN from **Lateral Cord(LC)** and Variations in the location with respect to the AA and BrA for the Formation of the Median Nerve was Observed and a careful Study was made to understand these anomalies and variations that needs to be accounted for .

II. Materials And Methodology

The study was done in the Department of Anatomy , Bangalore Medical College and Research Institute , Karnataka , India , during the Undergraduate Course. A total number of 52 upper limbs in 26 formalin fixed cadavers which included 16 male and 10 female specimens that were dissected according to the Cunningham’s manual of Practical Anatomy[2]. The brachial plexus was studied meticulously to find out the anatomical variations of formations of the median nerve. Each median nerve was observed in order to find the number of roots, their morphology and relations to the axillary and brachial artery. The site of formation of the median nerve was noted in relation to the parts of the axillary artery (part I, II or III) when the nerve was formed in the axilla. The origin of the median nerve was also noted in the arm with relation to the brachial artery based upon the location proximal or distal to the insertion of the coracobrachialis .

III. Inclusion And Exclusion Criterias

Inclusion Criteria- The cadaver that had an intact brachial plexus with observable and notifiable area of axilla containing axillary artery and brachial artery .

Exclusion Criteria – The cadavers that had any sort of injury or improperly dissected axillary region displacing the contents from their original position hence hindering the data analysis of this paper’s aim .

Scope Of Study

This was a very precise study of lateral roots of the median nerve which has been compared in its types and variability in South Zone –Karnataka (Bangalore). More studies must be done in different zones and a comparative analysis must be done with all the studies conducted .

IV. Results

Table 1

Formation at Lateral or Anterior side of 3rd Part of Axillary Artery (Normal)	42	80.77%
Formation at the 2nd Part of Axillary Artery	4	7.69%
Formation at the Brachial Artery Proximal to the Insertion of Coracobrachialis	4	7.69%
Formation at the Brachial Artery Distal to the Insertion of Coracobrachialis	2	3.84%
Total	52	100%

Table 2

Two Roots with one medial and lateral root (Normal)	48	92.31%
Three Roots with two lateral roots originating from same location of Lateral Cord (Type 2 , Figure 1)	2	3.84%
Three Roots with two lateral roots originating from two different locations of Lateral Cord (Type 3 , Figure 2)	2	3.84%
Total	52	100%

V. Discussion

This case study shows Anomalies of the nerve structures which would be one of the sources of atypical anatomical findings .

A very important analysis of this study is to divide and sub classify the types of Lateral Root Formations of the Median Nerve . Most of the prior literature has only observed the presence of the variation , but with this analysis and data collected , there is a possible sub-classification that can be created .

NORMAL – As per Cunningham’s manual of Practical Anatomy it is observed that the formation of Median Nerve by one Lateral and one Medial Root given of Lateral Cord and Medial Cord respectively .This was observed in 42 out of the 52 Brachial Plexus studied (92.31%) .

Type 1 – This is a special variation with the Lateral Roots formed having two separate origins from the lateral cord and common joining point with the medial root forming the Median Nerve .

Type 2 – The other type of variation was two lateral roots originating from the same point on the lateral cord and inserts on different points along with the medial root to form the Median Nerve . [Figure 1]

Type 3 – The next type of variation is the presence of two lateral roots originating from two different points on the lateral cord and joining the medial root at two different points to form the median Nerve . Vinay Sharma [3] had observed the formation of this variety and had classified it as Type 2 in Le-Minors Classification of communications between Musculocutaneous and Median Nerve is an overlap with this type of variation observed. [Figure 2]

Type 4 – Formation of median Nerve by 4 Roots including 3 lateral Roots and one medial Root .Satyanarayana N, Guha R [5] reported this type of variation .

Type 2 , 3 and Normal was observed in this specific study of anatomical variations.

IMAGES

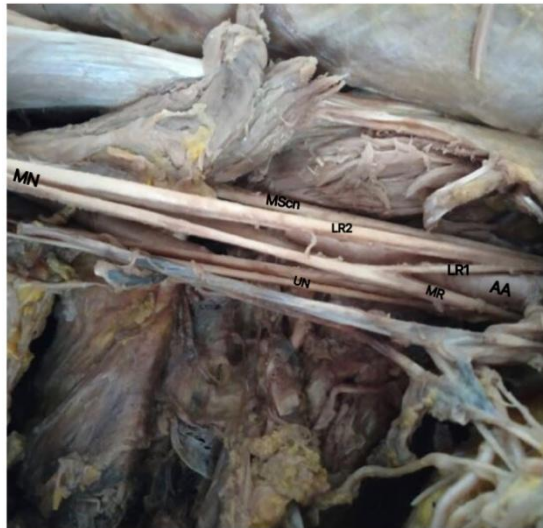

Figure No.1

Type of variation with two lateral roots originating from the same point on the lateral cord and inserts on different points along with the medial root to form the median nerve .

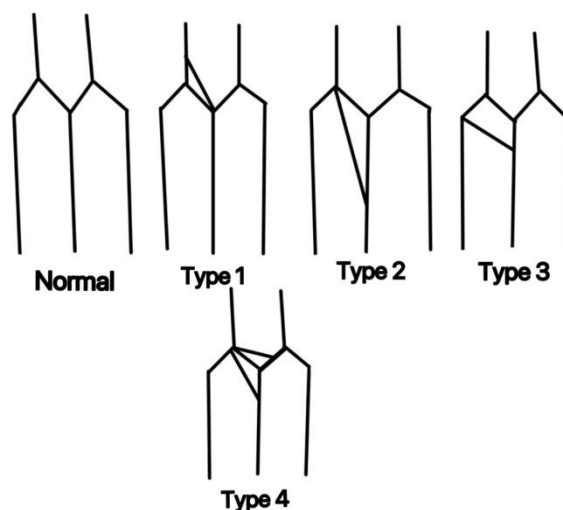
AA-Axillary Artery ,MScn-Musculocutaneous Nerve , UN-Ulnar Nerve , LR1,LR2-Lateral Roots ,MN- Median Nerve , MR-Medial Root .

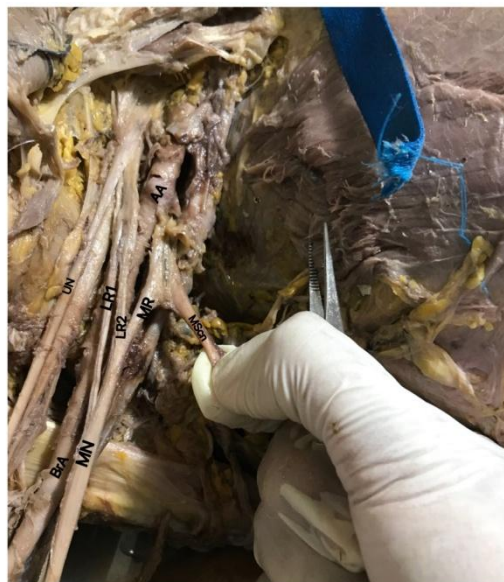

Figure No.2

Type of variation showing presence of two lateral roots originating from two different points on the lateral cord and joining the medial root at two different points to form the Median Nerve

AA-Axillary Artery ,MScn-Musculocutaneous Nerve , UN-Ulnar Nerve , LR1,LR2-Lateral Roots ,MN- Median Nerve , MR-Medial Root .



Schematic representation of classification created to understand the variation of formation of lateral roots to form the median nerve[figure no.3]

References

- [1]. David J, Harold E. Gray's Anatomy. In: Pectoral girdle, shoulder region and axilla. 41st Edition, New York Churchill Livingstone Elsevier, 2008.
- [2]. Rachel Koshi .Cunninghams Manual Of Practical Anatomy (Volume 1) In:Pectoral Region and Axilla . 16th Edition, Oxford Publications, United Kingdom, 2017.
- [3]. Vinay Sharma, C.S. Ramesh Babu, Vishnu Gupta. VARIATION OF ROOTS IN THE FORMATION OF MEDIAN NERVE International Journal of Anatomy and Research, Int J Anat Res 2018, Vol 6(4.2):5853-60. ISSN 2321-4287 DOI: <https://dx.doi.org/10.16965/ijar.2018.361>
- [4]. Dinit K Tom, Sonali A. Khake, S.M. Belsare, Maitreyee M Mutalik. Variation in Lateral Root of Median Nerve, International Journal of Anatomy and Research, Int J Anat Res 2018, Vol 6(3.1):5441-44. ISSN 2321-4287 DOI: <https://dx.doi.org/10.16965/ijar.2018.228>
- [5]. Satyanarayana N, Guha R – Formation of median nerve by four roots. J college of medical sciences 2008;5(1):105-7.
- [6]. P. S. Chitra, V. Anandhi - A STUDY OF THE DIFFERENT TYPES OF FORMATION OF MEDIAN NERVE International Journal of Anatomy and Research, Int J Anat Res 2016, Vol 4(2):2397-2400. ISSN 2321-4287 DOI: <http://dx.doi.org/10.16965/ijar.2016.157>
- [7]. Chauhan R, Roy TS Communication between the median and musculocutaneous nerve- a case report. JASI 2002;52(1):72-75.
- [8]. Uzun, A and Seeling, L. A variation in the formation of the median nerve: communicating branch between the musculocutaneous and median nerve in man. Folia Morphologica, 2001;60(2):99-101.
- [9]. Walsh, J. F. The anatomy of the brachial plexus. Am. J. Med. Sci., 1877;74:387-97.
- [10]. Malivalaya Namking, Arada Chaiyamoorn, Wunnee Chaijaroonkhanarak. Incidence of Unusual Formation of the Median Nerve in Thai-Northeast Embalmed Cadavers, Int. J. Morphol., 2017;35(1):52-55.

Pritik Shah" Variations in the Location of Formation of Median Nerve and Multiple Lateral Roots of the Median Nerve." IOSR Journal of Dental and Medical Sciences (IOSR-JDMS), vol. 18, no. 7, 2019, pp 40-43.