

Means Beyond Surgeries & Implants; For Atrophic Ridges- A Case Report

Dr Divya Malik

Abstract: *The ultimate objective of dentistry is to help and support patients to keep all their teeth throughout their lives in healthy and comfortable condition. However, if teeth are lost despite the efforts to save them, a restoration must be made in such a manner that it functions efficiently and comfortably in harmony with the muscles of the stomatognathic system and temporomandibular joints. Since it is difficult to achieve this harmony in highly atrophic mandible so in order to have a favourable prognosis in such conditions, the impression technique selected must be based on the present state of the basal tissue support and the biometric denture space should be respected. This paper presents a case report, whereby a complete denture has been shaped by muscle function in harmony with the surrounding oral structures and special impression technique is used to record atrophic ridges to increase the retention and stability of the denture besides maintaining the facial aesthetics.*

Keywords: *Atrophic ridges, All Green technique, neutral zone, piezography.*

Date of Submission: 27-06-2019

Date of acceptance: 13-07-2019

I. Introduction

Providing complete denture therapy to patients with atrophic residual alveolar ridge is often challenging; because these patients suffer ongoing diminution of the denture foundation.¹ Whereas, the modern approaches often increasingly prescribe dental implant therapy as a means of improving the denture foundation and supplementing the mechanics of prosthesis support, retention and stability. However, there may be certain medical, surgical and very often economic reasons when it is not possible to provide implants.² In such complex cases, an alternative approach has been experimented whereby denture technique to provide physiologically optimal denture contours and denture teeth arrangement has been used to maximize prosthesis stability, comfort and functionality for patients. Hence, the concept of 'neutral zone' was introduced. It is an old concept, but extremely valuable till date and, yet practiced very sparingly.

II. Case Report

A male patient aged about 70 years reported to our department, with the chief complaint of loose, ill fitting and unstable lower denture. The patient stated that lower denture dislodged while speaking and chewing, causing extreme discomfort. On examination, it was found that the patient was completely edentulous with an atrophic mandibular residual ridge. Also, there was loss of vertical dimension, collapse of facial profile and loss of muscle tonicity. (Fig. 1a, 1b)

Treatment procedure

STEP 1: Preliminary impression

- The preliminary impression for mandibular arch was made using McCord's technique [3 parts impression compound+7 parts greenstick compound] in a metal stock tray and refined using irreversible hydrocolloid over the existing primary impression. The maxillary arch was recorded using irreversible hydrocolloid in a stock tray. (Fig. 1c, 1d)
- A custom impression tray was fabricated on the preliminary cast using self cure acrylic resin. The extensions of the tray were checked in the mouth and the wax spacer was removed.

STEP 2: Functional secondary impressions

- Green stick impression compound was softened and loaded over the anterior third of the intaglio surface of the special tray. (Fig. 1e)
- The tray was seated over the denture bearing area, the labial borders were moulded and the patient was asked to perform various tongue movements to mould the lingual flange.
- This procedure was repeated for middle third, followed by posterior third of the impression tray on either side simultaneously. Any excess green stick material on the periphery was trimmed away with a Bard-Parker blade.

- The material from the crest of the ridge was trimmed to provide the required relief. Then the impression surface was roughened by making grooves and holes to enable mechanical retention for final impression material. Adhesive was applied on the impression and the wash impression was made in poly vinyl siloxane in light body consistency while performing lip, cheek movements and tongue movements. (Fig. 1f)
- In maxillary arch, border moulding with green stick compound was done in conventional manner followed by wash impression using zinc-oxide eugenol.

STEP 3: Jaw registration and Piezographic training

- The wax record rims were constructed on the acrylic bases for jaw registrations. The maxillary rim was trimmed to provide support for the musculature labially and buccally and record full width of the sulcus to develop the correct width of the lower arch.
- Once correct incisal level was established, the mandibular rim occlusal plane was adjusted to appropriate occlusal vertical dimension (OVD).
- The rims were registered in centric relation and articulated. Special piezographic training was given to the patient during this appointment for the following step of functional muscle trimming.

STEP 4: Construction of the Vertical Superstructure

- The wax was removed from the mandibular denture base and a superstructure in the form of vertical occlusal pillars (acrylic blocks). (Fig. 2a) These vertical pillars were constructed using auto polymerising resin on the denture base along its center to provide even occlusal stops at the correct OVD and support for the functional muscle moulding.

STEP 5: Recording neutral zone using piezography

- The denture base was placed in the patient's mouth and minimum amount of polyvinyl siloxane material was placed along vertical pillars to prevent its accumulation in the sulcus and accurately reproduce sulcus in non distorted form. (Fig. 2b)
- Then the patient was asked to perform the various peizographic actions in order to simulate physiological functioning: smile, grin, pout/purse lips, count from 60-70, talk aloud, pronounce the vowels, sip water, swallow ,slightly protrude the tongue and lick the lips, move the tongue gently to right and left.³
- Finally patient was asked to speak and swallow until material is completely set for complete registration of the modiolus, the lingual aspect of the tongue in its dynamic position, and the internal aspect of the cheek (the buccinators and masseter).
- Phonetic registration was performed to determine the position of the tongue, lips and the physiological contraction of the orbicularis oris. The patient was requested to swallow to confirm the correct inter maxillary relationship.

Laboratory procedure

- The piezographic impression obtained was placed on the master cast and locating grooves were prepared on the cast.
- The plaster index was adapted around the impression in order to preserve the space of the neutral zone.
- After the peizographic impression was removed from the denture base and the index replaced, the void was filled with molten wax to give an exact representation of the neutral zone. Teeth were then arranged following the index.

STEP5: Arrangement of teeth and try-in

Teeth arrangement was done by the setting principles within the confines of the mould space i.e. the biometric denture space. (Fig.2c) Since it was a severely resorbed ridge, a monoplane occlusion concept was adopted. The records were reassembled and checked for teeth positioning within the neutral zone area. The trial denture was checked in patient's mouth for aesthetics and occlusion.

STEP6: Complete denture insertion

Once the wax try-in was deemed satisfactory, the dentures were then processed and finished in conventional manner. Patient was recalled after 24 hours & the occlusal adjustments were done. The dentures provided the patient with improved facial appearance, stability and retention during function. (Fig.2d)

III. Discussion

The success of every complete denture relies on the fulfilment of the three basic properties: - retention, stability and support. Mandibular dentures usually present more difficulties in achieving these three properties because of large number of anatomic limitations. A number of modified impression techniques for atrophic mandibular ridges have been suggested by various authors that can be attributed to evolution of newer impression materials and better understanding of underlying tissues.

The primary impression for above mentioned case makes use of low fusing green stick that is less viscous than impression compound and does not over compress the tissues as the latter does. It also possesses better flow and handling characteristics and records accurate details. This primary impression was refined by making the impression with alginate to record the finer surface details that provides a stable, properly extended, close fitting custom tray. Then all green technique was used followed by functional secondary impression using light body polyvinyl siloxane.³ This technique has the following advantages: (1) they can be easily controlled to gain maximum coverage of residual ridge in passive form; (2) they can be corrected readily; (3) can be used to accurately determine the extent of the mucucobuccal reflections; (4) can be used to direct pressure towards the load bearing areas, therefore, providing functional support from the edentulous ridge.⁴

Successful treatment of patients with complete dentures also depends upon the proper positioning of the artificial teeth. Arranging artificial teeth within the neutral zone allows normal and peri-oral muscle activity to apply force alongside the complete dentures to stabilize and retain the prosthesis rather than displace the denture. Zero-degree teeth were arranged to a monoplane articulation to allow the patient to clench and grind in and around maximum intercuspation during both functional and non-functional activities and also to aid in denture stability as large cuspal forms tend to induce instability via a tipping effect. Moreover, use of acrylic posterior teeth and its ability to self adjust, improves stability and function of the dentures.⁵

In this case, piezography was used to record denture space by means of the speech & function of the patient. Piezography is a technique used to record patient's denture space in relation to oral function by means of pressure.^{6, 7}

The advantage of piezography is that the changes might occur in vertical dimension during recording of the neutral zone which can be prevented by the vertical occlusal stops of self cure acrylic blocks along the centre of the denture base. Earlier various materials have been used to record the potential physiological space in the mandible for muscle balance like impression compound and tissue conditioner. Impression compound becomes hard on early setting before the material can be manipulated properly in the patient's mouth. Later, tissue conditioner came into use which had the potential difficulty of material manipulation due to its tackiness. To overcome these disadvantages, light body poly vinyl siloxane material was chosen for this case.⁸

The entire procedure was aimed at using the materials that are available easily by the chair side with most of the clinicians. Various other advantages seen in such dentures are reduced food lodgement, good aesthetics due to facial support, proper positioning of posterior teeth which allows sufficient tongue space.⁹ Such improvement in the patient will obviously lead to the social rehabilitation of persons who cannot afford expensive treatments like implants. This is very relevant in the Indian context because a larger population does not have access to modern technologies and more important is that their affording capacity inhibits decent living. Therefore, the above combination of techniques with neutral zone must be viewed in the social context also.

IV. Conclusion

The biometric denture space (neutral zone) is the space that exists in each individual, where the denture is designed to function in harmony with oral musculature neutralizing the forces of the tongue against the lips and cheeks.⁶ Innovative use of Neutral zone technique is a relatively simple and time saving technique. Moreover, retention and stability are greatly improved especially in severely atrophic ridges

References

- [1]. **Cagna DR, Massad JJ, Schiesser FJ.** The neutral zone revisited: From historical concepts to modern application J Prosthet Dent 2009; 101:405-412.
- [2]. **Kumar A., Prasad K.** Neutral Zone Impression Technique for Mandibular Compromised Ridges: A Case Report International Journal of Dental and Medical Research | Nov - Dec 2014 | Vol 1 | Issue 4.
- [3]. **Herekar M et al.** A Physiologic Impression Technique for Resorbed Mandibular Ridges *Journal of Dental & Allied Sciences* 2013;2(2):8.
- [4]. **Yadav B et al** Comparison of Different Final Impression Techniques for Management of Resorbed Mandibular Ridge: A Case Report Hindawi Publishing Corporation Case Reports in Dentistry Volume 2014.
- [5]. **Sankar S. S. et al.** Biometric Denture Space- Concept of Neutral Zone Revisited Using A Hydrocolloid Impression Material Journal of Clinical and Diagnostic Research. 2015 Nov, Vol-9(11): ZD10-ZD12.
- [6]. **Klein P.** Piezography: dynamic modelling or prosthetic volume. Actual Odontostomatol (Paris). 1974; 28:266-276.
- [7]. **Mersel A. B Gerodontolog-** a contemporary prosthetic challenge. Mandibular impression technique. Gerodontolog. 1989; 8:79-81.

- [8]. **Arora S, Arora A, Khullar A.** Functionally Trimmed Denture for Atrophic Ridges. Indian Journal of Dental Sciences. March 2015, Issue: 1, Vol.:7.
- [9]. **Jain C et al.** Neutral Zone approach for severely atrophic ridges; Avenues beyond implants and surgeries –A case report IJCDS August 2011

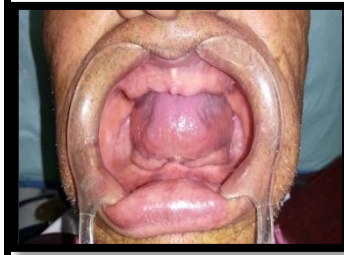
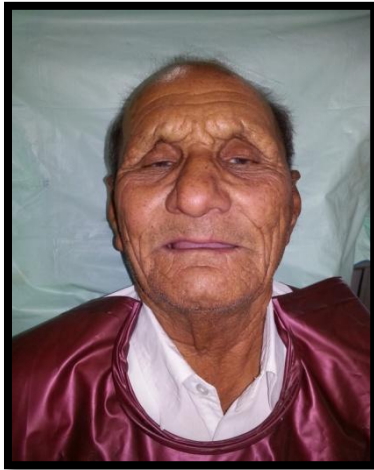
Fig.1(a), 1(b) Pre-rehabilitative extra-oral and intra-oral view

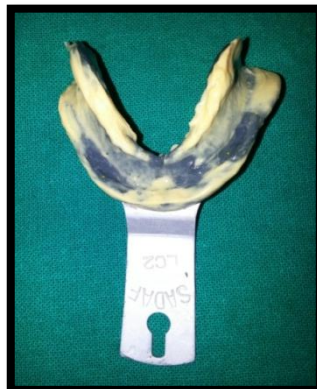
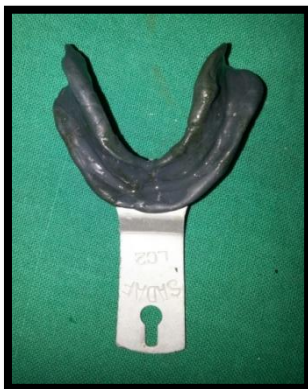
Fig. 1(c), 1(d) Preliminary impression using McCord's technique and refined using

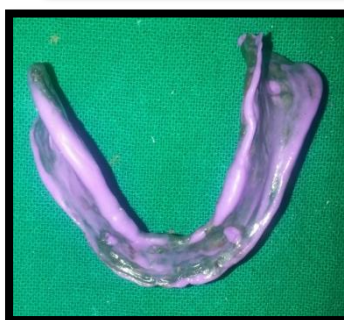
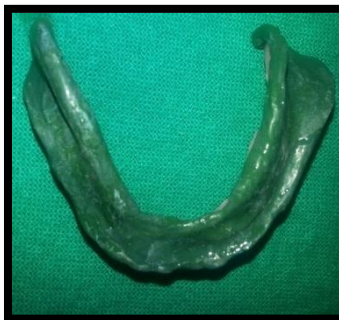
Fig. 1(e) Border moulding using All Green technique

Fig. 1(f) Wash impression made in polyvinyl siloxane

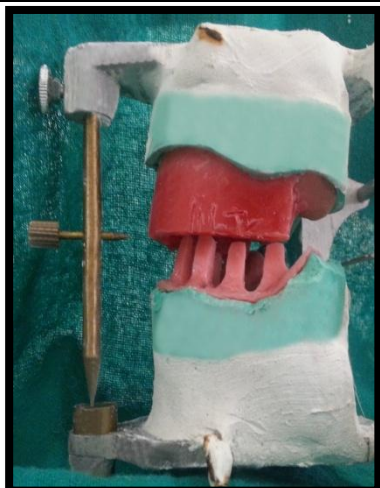


Fig. 2a Mandibular denture base with occlusal acrylic blocks



Fig. 2b Neutral zone recorded using piezography

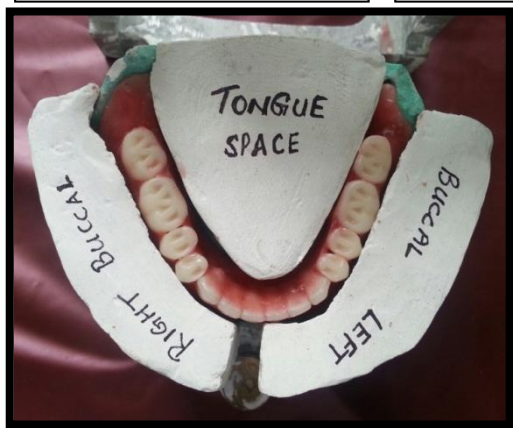

Fig. 2(c) Teeth arrangement within the confines of neutral zone

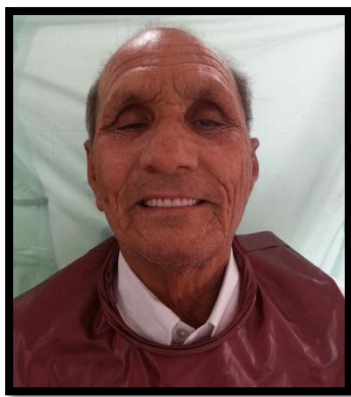

Fig. 2(d) Post-rehabilitative extra-oral view

Dr Divya Malik. "Means Beyond Surgeries & Implants; For Atrophic Ridges- A Case Report." IOSR Journal of Dental and Medical Sciences (IOSR-JDMS), vol. 18, no. 7, 2019, pp 45-49