

Macular hole: Observational study

Dr. Jitendra Kumar¹, Dr. Punam Tiwari²

¹ (Associate Professor & Head, Dept. of ophthalmology, MLB Medical College Jhansi, India).

² (Junior Resident, Dept. of ophthalmology, MLB Medical college Jhansi, India).

^{*} Corresponding Author: Dr. Jitendra Kumar

Abstract-A macular hole (MH) is a retinal break, which commonly involve the foveal area of almost central part of retina, mainly affecting the people over the age of 55 and mostly female predominance. The most common etiology is idiopathic; other causes are vitreous traction, trauma, diabetic eye disease and patients with high degree of myopia. Optical coherence tomography (OCT) is an important tool to diagnosed a macular hole as well as treatment follow up. Total 27 patients who were observed as a case of macular hole (both old and new), were included in this cross-sectional study conducted in OPD of ophthalmology, MLB medical college, Jhansi from Aug. 2017 to July 2018. An assessment of present complaints detailed clinical history was taken. All necessary ocular assessment as like, visual acuity, refraction, Amsler grid, Maddox rod, direct and indirect ophthalmoscopy, Fundus photography and fluorescence angiography and finally OCT was done. Most commonly affected age group was 50-65 years (51.85%). Male female ratio was 1:1.25. Only 2 (7.41%) cases diagnosed as a bilateral macular hole. Most of the macular holes were idiopathic origin (77.78%). Most of the macular holes were classified as a grade 3 macular hole (58.62%).

Keywords: Amsler grid, Fluorescence angiography, Macular hole, Maddox rod, OCT, Vitreous traction

Date of Submission: 06-07-2019

Date of acceptance: 20-07-2019

I. Introduction

The macula lutea is an oval-shaped pigmented area because it is enriched with xanthophyll pigment. The macula in humans has a diameter of around 5.5 mm (0.22 in) and is divided into different zones namely the umbo, foveola, foveal avascular zone (FAZ), fovea, parafovea, and perifovea areas¹ The anatomical macula at 5.5 mm (0.22 inch.) is much larger than the clinical macula which, at 1.5 mm (0.059 inch.), corresponds to the anatomical fovea.² A macular hole (MH) is a retinal break commonly involving the fovea. A macular hole was first elaborated by Knapp in 1869 in a patient who presented with blunt trauma to the eye.

Causes

Macular hole commonly affects the people over the age of 55 and mostly occurs in females. Most of the cases develop spontaneously without any obvious cause. That's why; there is currently no effective way to prevent their formation and development of macular hole. If a macular hole develops in one eye, there is a 5% to 15% chances to develop macular hole in the fellow eye.

Conditions which can increase the risk of macular hole formation, includes:

1. **Vitreous traction:** the vitreous is a gel like structure that fills up the inside of the eyeball. With aging, the vitreous gel can shrink and create traction upon retina, this is the 2nd most common cause of macular hole formation.
2. **Injury or trauma:** Another known cause of macular hole. Commonly occurs in young age group after ocular trauma.
3. **Diabetic eye disease:** Peoples with diabetes, there is risk to develop macular hole
4. **High myopia (nearsightedness)**
5. **Macular pucker:** It is a formation of a scar tissue layer over the macular region of retina that can wrap and causing traction on macula which can further leads to macular hole.

Traumatic macular hole (TMH) was mainly due to direct impact on eyeball.^{3,4} while, it is now apparent that Traumatic macular hole apparently occurs immediately after trauma, but clinically visible after few days to weeks later. Sudden disturbance in visual acuity is mainly due to detachment of fovea, while cystic changes and loss of photoreceptor causes late onset visual disturbance.^{5,6} In other studies, traumatic macular holes were found in 1.4% patients with closed eye trauma and 0.15 % patients with open eye trauma.⁷

Patients with macular holes suffer with a variety of visual/ocular symptoms. Initial symptoms include blurred central vision or Metamorphopsia. Sometimes few patients may describe the exact moment at which the hole developed, but more commonly, they describe the onset as slow and gradual if at all noticeable. Later, a

larger macular hole may produce a central visual field loss (scotoma). Few patients with macular hole may be asymptomatic and diagnosed by routine ophthalmological examination.

Optical coherence tomography (OCT), which can provide detailed high resolution cross-sectional images of the retina, which was defined by Gass's original classification and description of idiopathic macular holes (IMHs)^{8,9}

- **Stage 1 Macular hole:** It is also known as an impending MH, it presents as loss of foveal depression as compare to normal picture of retina. Stage one macular hole further divided into stage 1A and 1B macular hole. Stage 1A is foveolar detachment appears as a loss of the foveal contour and a lipofuscin-colored spot. Stage 1B is a foveal detachment which is characterized by appearance of a lipofuscin-colored ring.
- **Stage 2 Macular hole:** It is defined by a full thickness break over macular region but less than 400µm in size. In most cases, posterior hyaloid remain intact on fovea which is confirmed by OCT.
- **Stage 3 Macular hole:** It is defined by further progression of stage 2 macular hole, a hole ≥ 400 µm in size. A grayish macular rim and sub retinal fluid (SRF) often associated with stage 3 macular hole. The posterior hyaloid is observed to be detached over the macula with or without an overlying operculum.
- **Stage 4 Macular hole:** It is defined by a stage 3 macular hole with a complete posterior vitreous detachment (PVD) and Weiss ring.

II. Material and Method

A total of 27 Patients who were diagnosed as a case of macular hole (both old and new), were included in this cross-sectional study conducted in the Dept. of Ophthalmology, MLBMC, Jhansi, Uttar Pradesh, India over a period of 12 months from Aug. 2017 to July 2018. All procedures in this study were following the ethical standards committee on human experimentation (institutional or regional) and with the Helsinki Declaration of 1975, as revised in 2000. The necessary permission from the Ethical and Research Committee of the college was obtained for the study.

Inclusion criteria:

1. Patients with macular hole, irrespective of grade and etiology of macular hole.
2. Both male and female patients were included in this cross-sectional study.
3. The patient, above 20 year of age.
4. Both old and new patients were included in this study.

Exclusion criteria:

1. Patients with history of surgical treatment of macular hole were excluded from the study.
2. Patients below 20 year of age were excluded from the study.

Initially started with present complains with detailed clinical history (present and past), dietary habit, any other medication and any ocular surgery/trauma. Patient's personal details as like age, sex, occupation, socio-economic status, personal histories were recorded. Ophthalmological check up as external examination of the eyes, visual acuity, torch light examination, slit lamp examination, colour vision, refraction, Amsler grid, Maddox rod, direct Ophthalmoscopy, Perimetry, Fundus photography and fluorescence angiography and OCT were done. Our study is totally based on OCT findings.

III. Result

All the patients with macular hole were classified on the basis of various parameters :

n- Total number of patients with macular hole.

N- Total number of eye with macular hole.

All patients with macular hole were evaluated by OCT (optical coherence tomography) model **Topcon 3D OCT-1 Maestro (Spectral Domain)**.

Table-1: Age and sex distribution of the patients in study (n=27)

Age group	Male	Percentage	Female	Percentage	Total	Percentage
20-35 years	01	3.70%	Nil	Nil	01	3.70%
36-50 years	02	7.41%	02	7.41%	04	14.81%
51-65 years	06	2.22%	08	29.63%	14	51.85%
Above 65 years	03	1.11%	05	18.52%	08	29.63%
Total	12	44.44%	15	55.56%	27	100%

As table 1, macular hole most commonly found in 51-65 years of age group (51.85%) followed by patients above 65 year of age (29.63%). Only 1 patient who (3.70%) had macular hole age between 20-35 years.

Table 2: Unilateral vs. Bilateral cases (n=27)

	Unilateral	Bilateral
Male	12	Nil
Female	13	02
Total	25	02

As table 2, out of 27 patients, only 2 patients (7.41%) had bilateral macular hole, rest 25 patients had unilateral macular hole (within 1-2 years of follow-up)

Table 3: Grade wise distribution of patients (on the basis of OCT) (N=29)

Grade of macular hole	Number of patients	Percentage
Grade 1	02	6.9%
Grade 2	06	20.7%
Grade 3	17	58.62%
Grade 4	04	13.79%

On the basis of OCT finding all 29 eyes of the patients with macular hole were evaluated and classified into 4 grades. Most of the eyes had grade 3 macular hole (58.62%), followed by grade 2 macular hole (20.7%), and 13.79 % had grade 4 macular hole. Minimum number of patients that is 6.9% are categorized as grade 1 macular hole.

Table 4: Distribution of patients according to assumed risk factors/ etiology (N=29)

Etiology	No. of patients	Percentage
Idiopathic	21	77.78%
Retinal detachment surgery	01	3.70%
Injury or trauma	02	7.41 %
Diabetic eye disease	04	14.81%
Myopia	01	3.70%
Total	29	100%

IV. Discussion

Total 27 patients who were diagnosed as a case of macular hole (both old and new), were included in this cross-sectional study. 29 eyes with macular hole in 27 patients met inclusion criteria for the study. Among these, 21 macular holes (77.78%) were idiopathic. Non-idiopathic macular holes were attributed to the following etiologies: one case occurred after retinal detachment repair, two cases occurred secondary to trauma, 4 cases had previous history of diabetic eye disease and one case detected as a case of high myopia.

In this study the male female ratio was 1:1.25. In other study macular holes were found to be more common in females (male to female ratio of 1:2.4). However, male to female ratios varies widely in different studies and ranges from 1:1.2 in India¹⁰ to 1:7 China¹¹. In this study bilateral macular holes occurred in 7.41% of patients (2 cases). The rate of macular holes occurring bilaterally varies across studies from 8% in India¹⁰ to 14.3% in China.¹¹ In our study, most common age of presentation was 50-65 years of age group (51.85%) followed by patients above 65 year age (29.63%). In other study the mean age of onset is 65, but patients as young as in their thirties have been reported. Most of the macular holes were classified as a grade 3 macular hole (58.62%). This was possibly due to grade 1 and 2 macular holes are apparently asymptomatic in comparison to grade 3 and grade 4 macular hole.

V. Conclusion

Currently, the optical coherence tomography (OCT) is being used for evaluation of macular holes and for grading of macular holes.^{12, 13} OCT provides a noninvasive, non-contact imaging technique capable of producing high resolution optical cross sectional images of ocular structures in vivo with a theoretical maximum longitudinal resolution of approximately 10 μm .^{14,15} OCT is capable of differentiating full thickness macular hole from pseudoholes and also provides useful anatomical information on vitreo-macular relation.^{16,17} Vitro-macular relation is important for vitreo-retinal surgeries and visual outcome. In developing country like India the vitreo-retinal evaluation and management are not very passionate and unreachable for common patients, so most of the patients with macular holes are undiagnosed and untreated and causes significant permanent visual impairment. Early evaluation and management of macular hole according to their grade and severity can prevent the further ocular complication and visual loss.

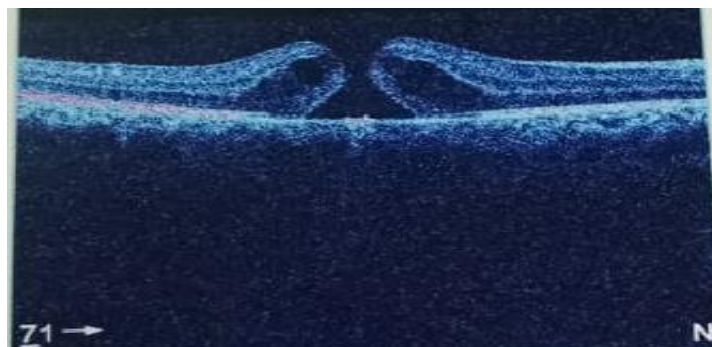

Fig1: OCT-3D Macula, right eye of 35-year-old male showing full thickness macular hole.




Fig2. OCT-3D Macula (45-year-old male, Right eye) showing partial thickness macular hole.

References:

- [1]. "Interpretation of Stereo Ocular Angiography: Retinal and Choroidal Anatomy". Project Orbis International. Archived from the original on 19 December 2014. Retrieved 11 October 2014.
- [2]. Yanoff, Myron (2009). *Ocular Pathology*. Elsevier Health Sciences. p. 393. ISBN 0-323-04232-5. Retrieved 7 November 2014.
- [3]. Knapp H. Ueber Isolirte Zerreibungen der Aderhaut infolge von Traumen auf Augapfel. *Arch Augenheilkd*. 1869;1:6–29.
- [4]. Oglivie F. One of the results of concussion injuries of the eye. *Trans Ophthalmol Soc UK*. 1900;20:202–229.
- [5]. Yanagiya N, Akiba J, Takahashi M, et al. Clinical characteristics of traumatic macular hole. *Jpn J Ophthalmol*. 1996;40:544–547.
- [6]. Mizusawa Y, Ichibe M, Yoshizawa T, et al. Clinical evaluation of traumatic macular hole. *Jpn Rev Clin Ophthalmol*. 1996;90:790–792
- [7]. Kuhn F, Morris R, Mester V, et al. Internal limiting membrane removal for traumatic macular holes. *Ophthalmic Surg Lasers*. 2001;32(4):308–315.
- [8]. Gass JDM. *Stereoscopic atlas of macular diseases: diagnosis and treatment*. 4th ed. Mosby; St. Louis, MO: 1997.
- [9]. Altaweel M, Ip M. Macular hole: improved understanding of pathogenesis, staging, and management based on optical coherence tomography. *Semin Ophthalmol*. 2003.
- [10]. Sen P, Bhargava A, Vijaya L, George R. Prevalence of idiopathic macular hole in adult rural and urban south Indian population. *Clin Experiment Ophthalmol*. 2008;36:257–60
- [11]. Wang S, Xu L, Jonas JB. Prevalence of full-thickness macular holes in urban and rural adult Chinese: the Beijing Eye Study. *Am J Ophthalmol*. 2006;141:589–91
- [12]. Puliafito CA, Hee MR, Lin CP, et al. Imaging of macular diseases with optical coherence tomography. *Ophthalmology* 1995;102:217–29.
- [13]. Hee MR, Puliafito CA, Wong C, et al. Optical coherence tomography of macular holes. *Ophthalmology* 1995;102: 748–56.
- [14]. Toth CA, Narayan DG, Boppart SA, et al. A comparison of retinal morphology viewed by optical coherence tomography and by light microscopy. *Arch Ophthalmol* 1997;115: 1425–8.
- [15]. Chauhan DS, Marshall J. The interpretation of optical coherence tomography images of the retina. *Invest Ophthalmol Vis Sci* 1999;40:2332–42.
- [16]. Gaudric A, Haouchine B, Massin P, et al. Macular hole formation: new data provided by optical coherence tomography. *Arch Ophthalmol* 1999;117:744–51.
- [17]. Chauhan DS, Antcliv RJ, Rai PA, et al. Papillofoveal traction in macular hole formation: the role of optical coherence tomography. *Arch Ophthalmol* 2000;118:32–8

Dr. Jitendra Kumar "Macular hole: Observational study" *IOSR Journal of Dental and Medical Sciences (IOSR-JDMS)*, vol. 18, no. 7, 2019, pp 20-23.