

Foreign body ingestion in children and their follow-up in a tertiary care paediatric surgery institution.

Dr.B.Hemanthkumar.,*Dr.N.Karrupasamy.,Dr.P.Jayakumar.,Dr.C.Aravindan.,
Dr.R.Srinivasakumar.,Dr.K.Ragha Dharshini.

Department of Paediatric Surgery, Government Rajaji Hospital and Madurai Medical College, Madurai,
Tamilnadu, India,625009.

*Corresponding Author:- Dr.N.Karrupasamy.

Abstract:-Foreign body(FB)ingestion in children needs to be followed carefully to avoid the morbidity related to it. Most of the foreign bodies passed out without any complications, some needs endoscopic or surgical procedure to retrieve the same. Here we retrospectively studied the children came for ingested FB's in our paediatric surgery department.

Keywords:- Battery; Children ; Coin; Foreign Body (FB); Ingestion;

Date of Submission: 03-08-2019

Date of acceptance: 19-08-2019

I. Introduction

Foreign body(FB) ingestion in children can cause morbidity and mortality to the children and anxiety to the parents. Most(80–90%) of the ingested FB's will be passed out without any complications, but some require endoscopic(10-20%) or open surgical intervention(1%)[1].In this study, we find out the outcome of ingested foreign bodies in paediatric age group in our institution.

II. Material and Methods

This retrospective follow up study was done over a period of 12 months(August 2018 to July 2019) in the department of paediatric surgery, Govt. Rajaji hospital, Madurai. The study included the patients of paediatric population presented with foreign body ingestion.X-Ray was taken immediately to find out the anatomical position of the foreign body lodged.Data regarding age, sex, foreign body type, size, shape and time to pass out were collected.The time of ingestion of the particle to the time of passing out was noted in admission cases and the same was collected via phone call for the out patients. The outcome of ingested foreign bodies were presented here.

III. Results

Total foreign body ingestion recorded was 51. Male children was 30 and female 21 (M:F=3:2).Minimum age observed was 7 months to maximum of 13 years with the mean age of 7.19 years. Five years old and less were 18(35%). The remaining 33(65%) were 6 years to 13 years of age. Coin was the most common foreign body ingested which accounts 25(49%). Next most common one was button battery 6(12%), magnet 3(6%), nail 2(4%), bulb 2(4%) and ring 2(4%). Others were each one including cloth piece, dice, hairpin, iron ball, key with ring, pen cap, plastic bullet, closed safety pin, open safety pin, screw and washer[Figure.1, Figure.1a,b&c].

X ray wise possible location of the foreign body was in intestines 21(41%), stomach 12(24%), pelvis 8(16%), oesophagus 3(6%), crico-pharynx 2(4%), right bronchus 1(2%) and the remaining 3(6%) were non radio-opaque so location can't be identified[Figure.2].

Most of the ingested foreign bodies were blunt, 46(90%) and the remaining 5(10%) was sharp. Shapes of the foreign body ingested were circular 35(70%), cylindrical 5(10%), oval 4(8%), rectangular 3(6%) and each 1(2%) in star,irregular, triangular & bow like.

Length of the FB ingested ranged from minimum 3 mm to maximum 6 cm. Mean length of the ingested FB was 2.35 cm. Less than or equal to 2.5 cm length FB's were 38(75%) and more than 2.5cm were 13(25%).

All the ingested foreign bodies that reached stomach were spontaneously passed out without any intervention. Total intervention needed cases were 5(10%). Two crico-pharyngeal and one bronchial foreign body were removed by endoscopy in otolaryngology department. One oesophageal lithium battery, which caused mucosal erosion and an open safety pin in lower oesophagus were removed by endoscopy in our department. No open surgical intervention needed in our series.

All follow-up details were available for 21 patients. Time to pass out the foreign body from the time of ingestion was available for 15 patients and six patients don't know when the FB was passed out. Others were passed out the FB, but follow-up details not available. Mean time taken for the 15 FB's was 48.36 hours. Mean time for less than or equal to 2.5 cm FB's (total 10) was 48.8 hours and for more than 2.5 cm (total 5) was 47.6 hours.

Among the 21 children, 10(48%) caretakers noticed that the children were playing with FB. Among the 10 noticed 5(50%) had the time lag from notice to ingestion. When age increases the time to pass out increases as per figure 3. Mean time for 5 years & less was 35.4 hours and for more than 5 years to 13 years it was 60.4 hours.

IV. Discussion

Most(75%) of the FB ingestion was reported in ≤ 5 years of age, but in our study this age group accounts to only 35% and mean age also high in our study[1].

Common FB ingested was coin followed by button batteries, which was confirmed with other studies also. But no button or bone was noted in our study. Oesophageal erosion was noted with a lithium battery during endoscopic removal[2,3]. In the remaining 5 cases of battery, even though they were asymptomatic complications like mucosal erosion or ulcer couldn't be ruled out.

X ray wise location of FB was intestine(41%), stomach, pelvis and oesophagus in this order. But other studies showing high percentage of FB's in oesophagus may be due to early presentation to the hospital[4].

In our study, around 90% of the ingested FB's passed out spontaneously with out any intervention. Endoscopic procedures needed for removal was around 10%, which was comparable to other studies[1].

While comparing the size of the FB, transit time didn't vary with the size of the ingested FB's in our study. But the transit time increases with age, which was comparable to the study done by Macgregor D et al[5].

Parents should be educated regarding harms of allowing their children to play with loose toy parts, coins and small objects. These above mentioned FB's should be kept out of reach for the children.

V. Conclusion

Sharp FB's and batteries in oesophagus/stomach needs to be removed to avoid complications. Blunt foreign bodies needs to be watched carefully for their transit. Parents should be educated to care their children by discourage playing with coins, batteries and small toy parts or objects.

References

- [1]. Lee JH. Foreign Body Ingestion in Children. Clin Endosc. 2018 Mar;51(2):129-136. doi: 10.5946/ce.2018.039. Epub 2018 Mar 30.
- [2]. Diaconescu S, Gimiga N, Sarbu I, Stefanescu G, Olaru C, Ioniuc I, Ciongradi I, Burlea M. Foreign Bodies Ingestion in Children: Experience of 61 Cases in a Pediatric Gastroenterology Unit from Romania. Gastroenterol Res Pract. 2016;2016:1982567. doi: 10.1155/2016/1982567
- [3]. Lee JH, Lee JH, Shim JO, Lee JH, Eun BL, Yoo KH. Foreign Body Ingestion in Children: Should Button Batteries in the Stomach Be Urgently Removed? Pediatr Gastroenterol Hepatol Nutr. 2016 Mar;19(1):20-8. doi: 10.5223/pghn.2016.19.1.20.
- [4]. Yalçın S, Karnak I, Ciftci AO, Senocak ME, Tanyel FC, Büyükpamukçu N. Foreign body ingestion in children: an analysis of pediatric surgical practice. Pediatr Surg Int. 2007 Aug;23(8):755-61.
- [5]. Macgregor D, Ferguson J. Foreign body ingestion in children: an audit of transit time. J Accid Emerg Med. 1998 Nov;15(6):371-3.

Figure.1. Foreign bodies ingested

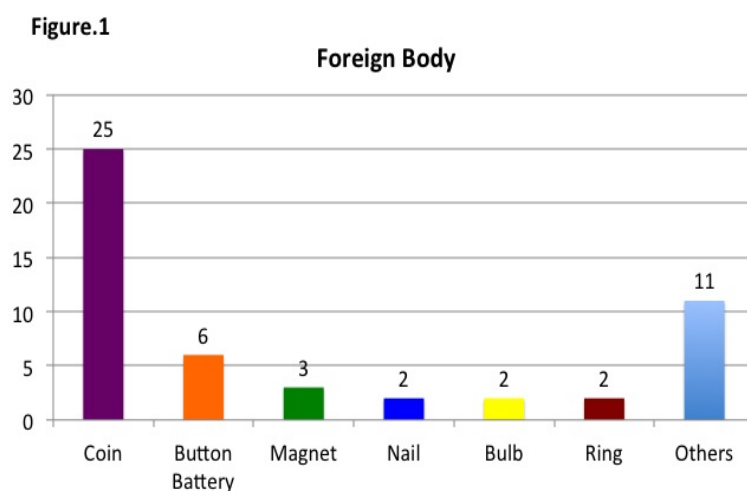


Figure.1a. Coin in upper, lower oesophagus and intestine over a time period

Figure.1b. Open safety pin in oesophagus

Figure.1c. Triangular shaped magnet at crico-pharynx

Figure.1a.

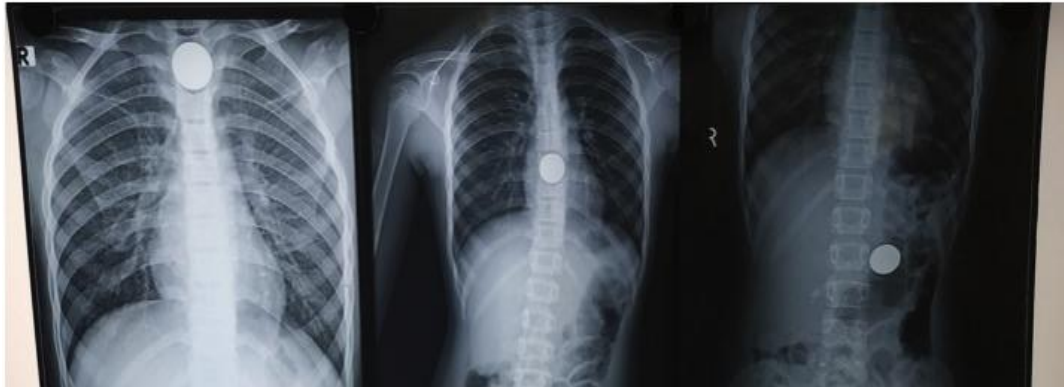

Figure.1b.

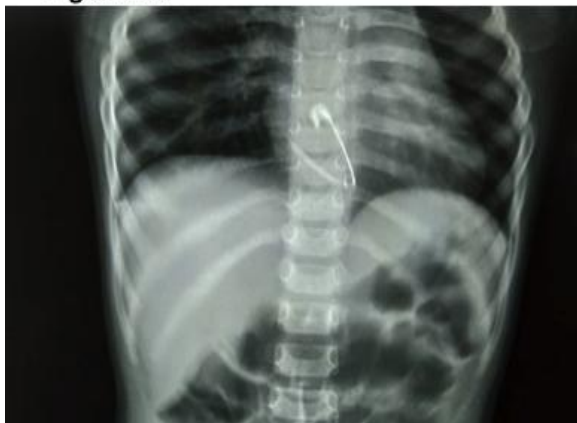

Figure.1c.

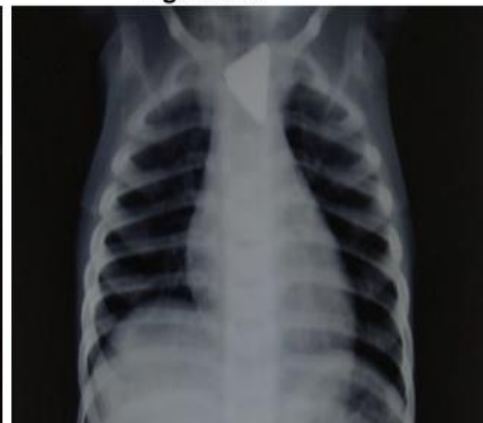

Figure.2. X-ray wise location of the foreignbody

Figure.2

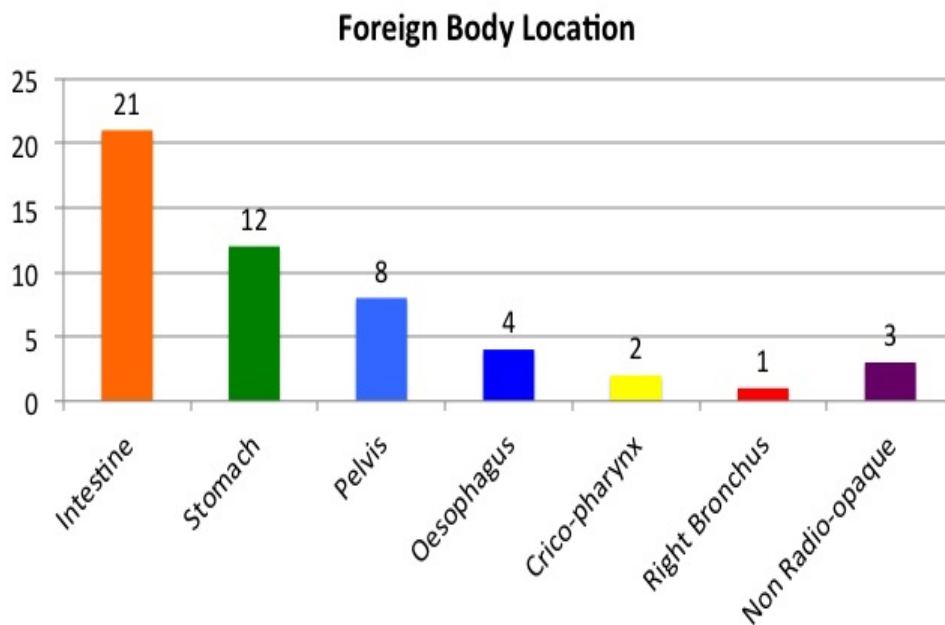
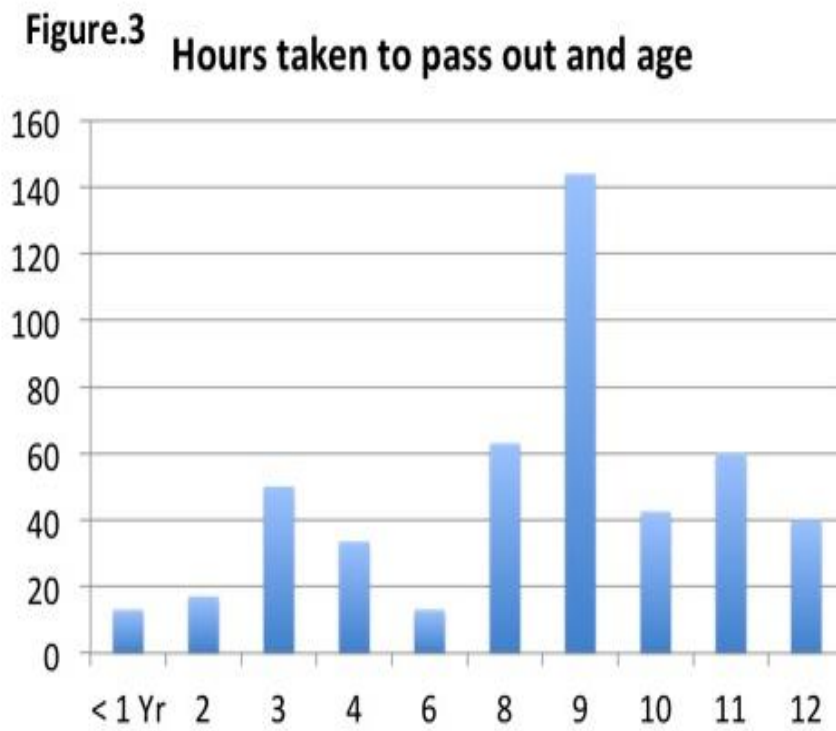


Figure.3. Age in years and time taken to pass out(n=15)



Dr.B.Hemanthkumar et al. " Foreign body ingestion in children and their follow-up in a tertiary care paediatric surgery institution."IOSR Journal of Dental and Medical Sciences (IOSR-JDMS), vol. 18, no. 8, 2019, pp 33-36.