

Evaluation of dry eye before and after manual small incision cataract surgery in Bundelkhandregion : comparative study

Dr. Jitendra Kumar¹, Dr. Puneet Kumar Jaisal^{2*}

¹. Associate Professor & Head, Dept. of ophthalmology, MLB Medical College Jhansi, India.

². Junior resident, Deptt. of ophthalmology, MLB Medical College Jhansi, India.

*Corresponding author : Dr. Puneet Kumar Jaisal

Abstract:

AIM: Dry eye disease is an ocular surface disorder which produces discomfort and reduced vision due to tear film instability. To evaluate the proportion of dry eye before and after manual small incision cataract surgery. To evaluate changes in tear secretion using Schirmer's test 1 (ST-1). To evaluate changes in tear film stability using tear film break up time (TBUT). The study was conducted for a period of 18 months the proportion of dry eye before and after manual small incision cataract surgery. **Materials & Methods:** The prospective study was conducted in 110 eyes of 110 patients. Those included were selected from the patients diagnosed as having unilateral or bilateral age related uncomplicated cataract without dry eye symptoms. All selected patients were studied for any abnormalities in tear film pre and post manual small incision cataract surgery. The various parameters studied were tear meniscus height (TMH), tear film break up time (TBUT), Schirmer test 1 (ST1) and Rose Bengal staining (RB). The tests were performed for all patients 1 day before and 1 day, 1 month, and 3 months after surgery. **Results:** The majority of the study participants were aged between 51- 60 years (51%). 30% of the eyes showed lower TMH at 3 months post operative visit. 8 % the eyes recorded lower TBUT values at 3 months postoperative follow up, which was statistically significant ($P < 0.01$). There was a statistically significant difference in ocular surface changes with Rose Bengal staining between preoperative and postoperative 1 week, 1 month, and 3 months follow up ($P < 0.002$). The mean postoperative ST1 results were no different from preoperative values. **Conclusion:** Patient undergoing SICS without having dry eye preoperatively showed lower values of tear film indices like TMH, TBUT and RB at 1 week and still lower values at 1 month. All the patients should be evaluated before and after SICS to prevent and manage will not have poor quality of life and vision due to dry eye disease.

Key Words: Dry Eye Disease, Schirmer's test-1, Tear film break up time, Small Incision Cataract Surgery, Tear Film.

Date of Submission: 03-08-2019

Date of acceptance: 19-08-2019

I. Introduction

Dry eye disease is an ocular surface disorder which produces discomfort and reduced vision due to tear film instability. Incidence of dry eye in the US has been estimated to be around 2.7 per year. Incidence of dry eye in India amongst patients attending the outpatient department has been estimated to be around 0.46% with a male:female ratio of 1:1.22 [1]. Cataract is the leading cause of blindness in the world. At the same time, cataract surgery is the most successful and rewarding surgery in the field of ophthalmology. However, after cataract surgery, many patients complain of foreign body sensation, irritation, redness and blurring of vision which are considered as unwanted effects of the surgery [2]. These persist in some patients until they are managed by subsequent effective treatment [3]. Some studies have reported aggravation of dry eye symptoms and signs after cataract surgery (Ram et al.) [4,5]. Thus, in spite of a perfect cataract surgery and a good Snellen visual acuity, the patients may remain dissatisfied. In developing countries like ours, the most efficient and the economical means of doing a cataract surgery is manual small incision cataract surgery with a corneo scleral tunnel incision. Now-a-days, even the base camp surgeries which are done under the National Program for Control of Blindness are manual small incision cataract surgeries (SICS) with corneo scleral tunnel incisions. The procedure is fast and has a low rate of complications and can be performed in dense cataract [6,7]. Manual SICS is a good alternative to phacoemulsification in areas where very high volume surgery with inexpensive instruments is required. Perioperative abnormalities of the tear film are recently being noted as perioperative dry eye. The International Dry Eye Workshop in 2007 stated that "Dry eye is a multifactorial disease of the tears and ocular surface that results in symptoms such as ocular discomfort, visual disturbance, and tear film instability with potential damage to the ocular surface" [29]. Risk factors for perioperative dry eye have been reported to include forceful opening of the eye lids [30], aging [31], light and heat from the operating

microscope[32], preservatives in eye drops[33], topical nonsteroidal anti-inflammatory drugs (NSAIDs)[34] topical anesthetics[34] and cleansing of the conjunctival sac and lids with povidone iodine. The mechanism, through which these risk factors induce dry eye after cataract surgery with IOL implantation, its incidence, as well as its prevention and treatment method have not yet been established. In the present study, the aim was to evaluate the changes in tear film following cataract surgery by comparative analysis of tear film indices before and after manual SICS.

II. Materials and Methods

In the present study 110 eyes of 110 patients who attended Out Patient Department of the department of Ophthalmology of Maha Rani Laxmi Bai Medical College, Jhansi Uttar Pradesh from period of Jan 18 to June 19 were included. All the patients were above 50 yrs and were diagnosed as senile cataract. All patients underwent uneventful manual SICS with either superior or temporal corneo-scleral incision. An informed consent was taken from all patients. The study was approved by the institutional ethical committee (IEC). All methods adhered to the tenets of the Declaration of Helsinki for research involving humans.

Inclusion Criteria:

1. All the patients were above 50 yrs and were diagnosed as senile cataract
2. Those included were selected from the patients diagnosed as having unilateral or bilateral age related uncomplicated cataract without dry eye symptoms.

Exclusion Criteria:

3. Patients with of any etiology other than age like traumatic cataract, complicated cataract, drug induced cataract, etc were excluded from the study.
4. Patients with surgical complications, pre-existing dry eyes, Sjogren's syndrome, rheumatoid arthritis and other autoimmune disorders and patients with pre-existing ocular diseases like glaucoma, uveitis, disorders of the lid or the nasolacrimal pathway, ocular allergies, pterygium and previous ocular surgeries were not included in the study.
5. Patients who received concomitant medications that could cause dry eye such as antihistamines, antidepressants, birth control pills, decongestants.
6. Patients who lost follow up were excluded.
7. Patients were also excluded if they developed intra operative complications during present surgery.

Detailed medical and ophthalmic history of all patients were noted. All patients underwent a full ophthalmological examination including slit lamp examination, dilated fundus examination. Sac syringing was done and intraocular pressure was noted. Fitness was taken pre-operatively for all patients. TMH, TBUT, ST1, RB staining was done in all patients to rule out any pre-existing ocular surface disease. The patients were started on systemic and topical antibiotics one day before surgery. The patients were started on systemic and topical antibiotics one day before surgery. On the day of surgery pupils were dilated using 0.8 mg tropicamide and 10% phenylephrine hydrochloride drops 90 minutes before cataract surgery. A manual small incision cataract surgery with either superior temporal sclero corneal tunnel was performed under peribulbar block. The incision was 6 to 6.5 mm in length and 1.5 to 2 mm from the limbus. A rigid PMMA intraocular lens was implanted in all patients. A standard post operative regime was followed in all the patients. All patients received steroid antibiotic combination in tapering doses for 8 weeks. Post operative evaluation was done at 1 week, 1 month and 3 months. At each visit TMH, TBUT, ST1 and RB staining was done.

Tear meniscus height (TMH): Tear meniscus height was recorded as normal or low (under narrow beam of slit lamp). Precorneal tear film was observed for presence of debris (mucous/oil droplets /debris)

SCHIRMER'S TEST-1: Schirmer's test 1 was done. It was done by using the Schirmer's strip, which is made up of the Whatman no. 41 filter paper with its dimensions, 5mm x 35mm. The initial 5mm of the Schirmer's strip was folded and kept in the junction of the lateral one third and the medial two third of the lower fornix of the eye and it was kept in situ for 5 minutes. The patient was asked to keep their eyes open. The wetting of the strip at the end of 5 minutes was noted by using the scale which was present on the strip. The patients were graded as follows

- Normal: 10-25mm
- Borderline : 5-10 mm
- Hyposecretive: <5m

TEAR BREAK UP TIME (TBUT) : The TBUT measures the interval between the last complete blink and the first appearance of a dry spot or disruption of the tear film. The tear film was stained by sterile fluorescein strip. The fluorescein strip was moistened with saline and applied to the inferior cul-de sac. Under a slit lamp, the time interval between the appearance of a dark spot on the cornea after a complete blink and next

blink was noted by using a stop watch..The test was repeated three times, and the average was calculated to see whether the patient had dry eye. An average score of 10 seconds or more was classified as normal; a TBUT shorter than 10 seconds indicated the presence of dry eye.[Figure 2]

Rose Bengal stain (RB): It is a measure of assessing ocular surface damage. A sterile, commercially available Rose Bengal strip moistened with 4% xylocaine was applied to the inferior cul de sac. After 15 seconds, the eye was examined for staining of cornea and conjunctiva under red free light or bright light under the slit lamp. VanBijsterveld scoring system was used to grade the staining of cornea and conjunctiva, based on a scale of 0-3 in 3 areas: nasal conjunctiva, temporal conjunctiva and cornea. An additive score of 4 or more in the eye was considered as positive test. [Figure 3]

Statistical analysis: Chi-square test was applied for analyzing significance among qualitative variables. Paired t-test was applied for analyzing significance among quantitative variables and to check preoperative and postoperative results. Descriptive statistics was applied for quantitative variables, Mean and SD.The Statistical software SPSS 20.0 was used for analysis of the data and Microsoft word and Excel 2011 was used to generate graphs and tables.

III. Results

All the patients were followed till 3 months postoperatively And assessed for the development of dry eye on the basis of tear meniscus height (TMH), Schirmer's test (ST1), tear film breakup time (TBUT) and rose Bengal (RB) staining of ocular surface. The results of the study were analyzed as below. In the present study majority (51%) of the study participants were aged between 51 to 60 (yrs) 43% were aged between 61-70 (yrs). [Table1]. In the present study 46% of the subjects were males and 54% were females [Fig.1].TMH analysis showed that preoperatively all subjects had normal TMH values. 29%, 34% and 30% had low TMH at postoperative 1 week, 1 month and 3 months respectively which was statistically significant [Table2]. The TBUT analysis showed that preoperatively all subjects had normal TBUT values. At postoperative 1 week, 1 month and 3 months 8%, 26% and 9% had low TBUT values. 92% of the patients regained normal values in 3 months followup period which was statistically significant.[Table3].ST1 analysis was normal in all patients pre operatively. 0%,5% and 0% had low ST1 values at post-op 1 week, 1 month and 3 months respectively. After 3 months postoperative all patients regained ST1 value of >10 which was statistically significant [Table4].Rose Bengal stain analysis showed statistically significant difference in Rose Bengal stain grading between preoperative, postoperative 1 week, 1 month and 3 months.[Table 5]

Figure 1: Distribution according to sex

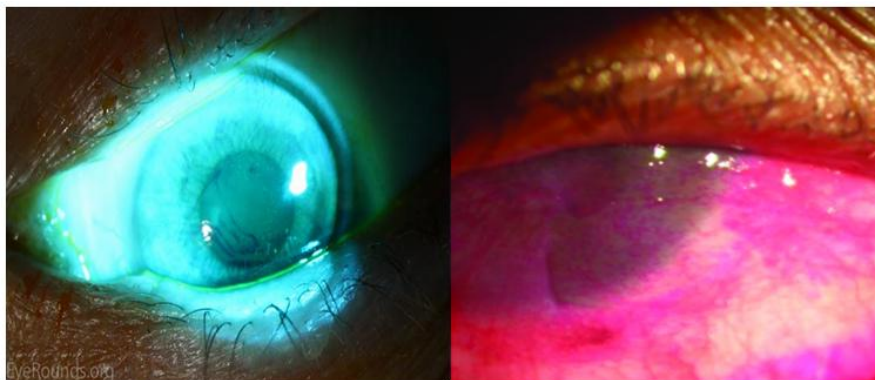
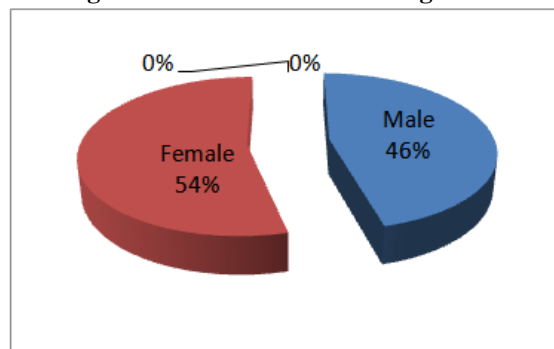


Figure 2: TBUT: appearance of first black spot

Figure 3: RB staining

Table-1: Distribution of study subjects according to age

Age (yrs)	Frequency	Percent
51-60	56	51%
61-70	47	43%
71-80	6	5%
81-90	1	1%
Total	110	100

TABLE: 2: Multiple bar diagram representing, TMH at Pre, Post-op at 1 week, 1 month and 3 months

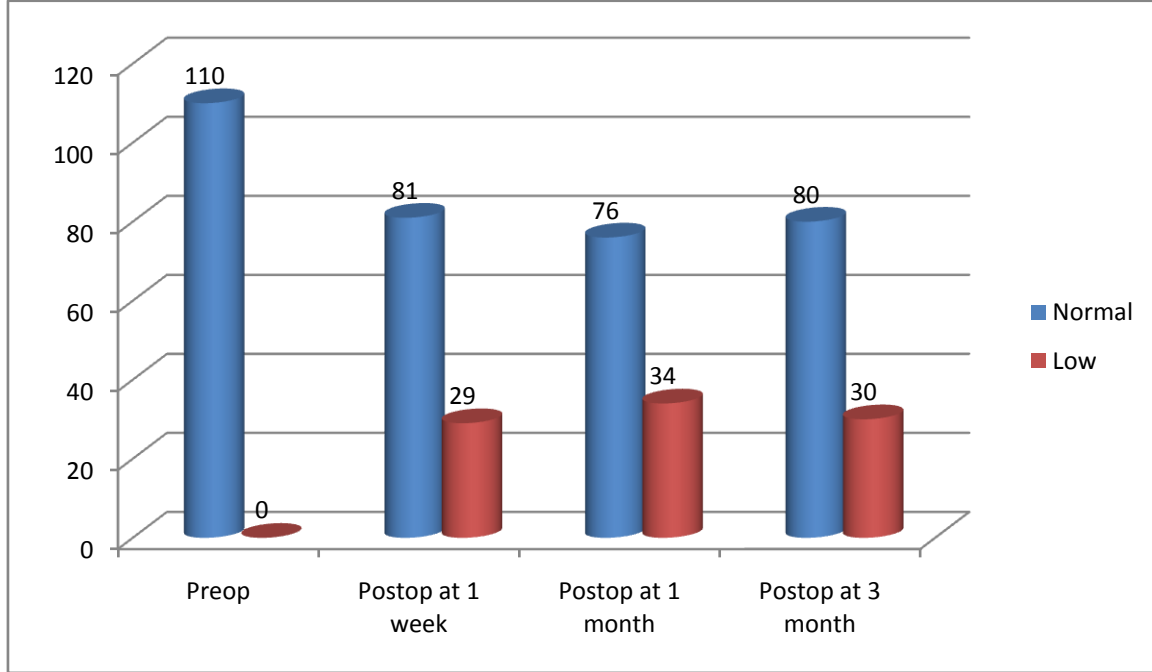


Table 3: Comparison of TBUT at Pre-op, Post-op at 1 week, 1 month and 3 months

TBUT	Pre op		Post op at 1 week		Post op at 1 month		Post op at 3 month		t-value	p-value
	Frequency	MEAN ± SD	Frequency	MEAN± SD	Frequency	MEAN± SD	Frequency	MEAN± SD		
≥10 Normal	110	21.13+5.732	102	18.51+5.031	84	16.15+4.31	101	17.62+4.36	8.71	P<0.001
<10 Dry	0	0	8	8+1.10	26	7.61+1.51	9	8+1.73		
Total	110		110		110		110			

Table 4: Comparison of ST at Pre-op, Post-op at 1 week, 1 month and 3 months

ST1	Preop		Post-op at 1 week		Post-op At 1 month		Post-op at 3 month		t-Value	p-value
	Frequency	MEAN ± SD	Frequency	MEAN ± SD	Frequency	MEAN± SD	Frequency	MEAN± SD		
≥10 Normal	110	24+6	110	22.71+5.32	105	18.72+4.65	110	24.73+4.38	64.73	<0.000
<10 Dry	0	0	0	0	5	8+0	0	0		
Total	110		110		110		110			

Table 5: Comparison of RB at Pre-op, Post-op at 1 week, 1 month and 3 months

RB	Pre-op	Post-op at 1 week	Post-op at 1 month	Post-op at 3 month	P - value
0=Normal	110	78	55	69	P<0.002
1= Mild	0	24	32	24	
2=Moderate	0	7	16	13	
3=Severe	0	1	7	4	
TOTAL	110	110	110	110	

IV. Discussion

Dry eye disease is a multifactorial disease of the tear film and ocular surface that results in symptoms of discomfort, visual disturbance, and tear instability with potential damage to the ocular surface. It is accompanied by increased osmolarity of the tear film and inflammation of the ocular surface, as described in the International Dry Eye Work Shop, 2007[23]. Dry eye produces discomfort and reduced vision when the tear film becomes chronically unstable and repeatedly breaks up into dry spots between blinks, exposing the corneal and conjunctival epithelium to evaporation (Parson, et al.,2007)[24]. Cataract surgery is the most successful and classic surgery, which has given good visual acuity to many patients. Cataract operations have substantially increased from 16 lakh in 1992-93 to 59.1 lakh in 2009-10 according to the annual report 2010-11 Of National Programme For Control Of Blindness[25]. The etiology of dry eye following cataract surgery is characterized by presence of either pre-existing dry eye or surgically-induced dry eye. Various factors might affect the ocular surface environment after cataract surgery. Most important is corneal desensitization[7]. Superficial punctate keratitis, recurrent filamentary keratitis, secondary infections including conjunctivitis, infective keratitis, persistent or recurrent epithelial defects, stromal keratolysis and corneal ulceration have been reported in dry eye patients after cataract surgery notably conventional extracapsular cataract extraction (ECCE) by Ram et al in 2002[26]. The intra operative factors that cause dry eye are long exposure to microscope light, prolonged surgical time, vigorous irrigation of the tear film, usage of excessive cautery and large incision at the limbus causing denervation of the corneal nerves leading to reduced corneal sensation which leads to reduced lacrimal gland tear production, which in turn leads to dry eye. Vigorous irrigation of the tear film and manipulation of the ocular surface intraoperative may reduce the goblet cell density and result in shortened TBUT postoperatively. Use of light filters, decreased exposure time, appropriate irrigation and gentle handling of the ocular surface tissue, using minimal cautery may decrease dry eye after cataract surgery[27]. Postoperative factors that cause dry eye are use of steroid, NSAIDs and antibiotic eye drops which contain preservatives like Benzalkonium chloride which leads to increased evaporation of the tear film[26,28]. Dry eye can develop after various types of ophthalmic surgeries such as photorefractive keratectomy and laser assisted in situ keratomileusis [LASIK]. The present study was undertaken to evaluate the proportion of dry eye before and after manual small incision cataract surgery with corneo-scleral tunnel. Many previous studies comparing the preoperative and postoperative changes in dry eye symptoms and/or dry eye test values showed significant worsening after cataract surgery[2,5,8,9]. A difficulty in assessing dry eye is that there is no gold standard test[1]. As a result various diagnostic tools with different sensitivities and specificities are used to diagnose dry eye. In present study TMH, TBUT, ST1 and ocular surface staining with Rose Bengal was done (RB can easily detect ocular surface inflammation). Cataract surgery can affect or interrupt the neurogenic response of the ocular surface and decrease tear secretion. Like other studies, we also report that dry eye can develop after cataract[3,5]. In the present study the TMH values were lowest at 1 month, while it showed slight improvement at 3 months. Cho, et al., in their study found that TMH value decreased in all the follow up visits from the preoperative value in the nondry eye group[2]. Gharaee, et al., also showed a decreased TMH value at 3 months follow up visit [10]. The lowest value of TBUT was seen at 1 month and after 3 months there was slight improvement. Chandan C et al[12], Mohan S et al[14], in their study also found lower value of TBUT at 1 month follow up. In the present study none of the patients had ST1 values in the dry eye range pre operatively, whereas 0%, 3% and 0% of patients in the postoperative 1 week, 1 month and 3 months respectively had ST1 values in the dry eye range. In a study by Srinivasan R et al[1], Chandan C et al[12], Kavitha et al[11], the schirmertest values decreased in the pre and postoperative cases of cataract surgery to a significant levels. In a study by Ram et al[5], And Mohan S et al[14], Li et al and Liu Z et al[13] conducted. Schirmers test values decreased significantly till 4 weeks postoperatively. In the present study none of the patients had abnormality of RB staining preoperatively where as 29%, 52% and 37% of patients in the postoperative 1 week, 1 month and 3 months had abnormal RB staining. In a study by Oh et al[15] RB staining showed a similar pattern. In the present study dry eye was noticed in 10 cases at post-operative 1 month out of which 3 cases had mild dry eye and 7 cases had moderate dry eye. After 3 months the severity of dry eye decreased but never returned to baseline levels. In a study by Saif MYS et al[16], severity dry eye significantly increased 1 week after surgery and remained increased up to 4 weeks after surgery. After 3 months the severity of dry eye decreased again and returned to near base line. Both Phacoemulsification and SICS patients had more severe dry eye at 1 week post-operative which slightly decreased after 4 weeks[17]. In a study by Kasetsuwan et al[9] concluded that severity of dry eye peaked 7 days post Phacoemulsification. Within 1 month and 3 months both symptoms and signs showed gradual improvement. In the present study RB staining showed that most of the patients had mild dry eye with a peak at 1 month (32%) and decreased again but never returned to normal at 3 months postoperative period (24%). In studies by Cho et al[2], I, Li et al[3], Gharaee et al[10], dry eye appeared at 1 week post operatively and reached a peak at 1 month postoperative period. In several studies like Ram et al[4], Hardten et al[19], Cohen et al¹⁸, Insler et al[20], Jones et al[21], and Roberts et al[22] there was overwhelming evidence suggesting the aggravation or initiation of dry eye following cataract surgery. Disruption of the normal corneal innervation or

lacrimal functional unit feedback can reduce the tear flow and blink rate and cause instability of the tear hyperosmolarity and tear film. With corneal healing postoperatively, new neurite cells emerge and after 25 days neural growth factor is released to regenerate the sub epithelial corneal axons. Thus, the recovery of the corneal nerves may explain why the dry eye was seen early after surgery and improved thereafter. Even though, in theory, neurogenic inflammation may affect the feedback loop in the contralateral eye, in the present study the other eye did not show significant dryness after surgery.

V. Conclusion

Patients undergoing SICS with normal dry eye indices pre operatively showed lower values of dry eye indices like TMH, TBUT, ST1 and RB staining at 1 week and still lower values at 1 month postoperative. The incidence of dry eye was more at postoperative 1 month following SICS. 10% of the patients had dry eye of which mild dry eye was seen in 7% and moderate dry eye was seen in 3% at 1 month postoperative. Preoperative assessment should be done properly by using questionnaire about dry eye symptoms, tests for tear film production and its stability. Early detection of changes in the tear film status after cataract surgery and starting appropriate treatment aids in better post operative results with regard to quality of life of the patient. Cataract surgery can cause or aggravate pre existing dry eye. We conclude that dry eye symptoms can develop immediately after cataract surgery and reach a peak on day 7. Both symptoms and signs of dry eye can improve overtime.

References

- [1]. Srinivasan R, Agarwal V, Suchismitha T, Kavitha. Dry eye after phacoemulsification. *AIOC* 2008; 116-8.
- [2]. Cho YK, Man SK. Dry Eye After Cataract Surgery and Associated Intraoperative Risk Factors *Korean J Ophthalmol* 2009; 23:65-73.
- [3]. Li XM, Hu L, Hu J, Wan W. Investigation of Dry Eye Disease and Analysis of the Pathogenic Factors in Patients after Cataract Surgery. *Cornea* 2007; 26:16-20.
- [4]. Ram J, Sharma A, Pandav SS, Gupta A, Bamberg P. Cataract surgery in patients with dry eyes. *J. Cataract Refract Surg.* 1998;24:1119-24.
- [5]. Ram J, Gupta A, Brar GS, Kaushik S, Gupta A. Outcomes of phacoemulsification in patients with dry eye *J Cataract Refract Surg.* 2002; 28:1386-9.
- [6]. Stern ME, Beuerman RW, Fox RI, Goa J, Mirchoff AK, Pflugfelder SC. The pathology of the dry eye and the interaction between the ocular surface and the lacrimal glands. *Cornea.* St. Louis: Mosby 1997; 663-86.
- [7]. Fernando Murrillo LSCP, Jay H. Krachmer MJMEJH. Dry eye. *Cornea.* St. Louis: Mosby 1997; 663-86
- [8]. Kohlhaas M. Corneal sensation after cataract and refractive surgery. *J Cataract Refract Surg* 1998; 24:1399-409.
- [9]. Kasetuwana N, Satitpitakul V, Changul T, Jariyakosol S. Incidence and Pattern of Dry Eye after Cataract Surgery. *PLoS One* 2013; 8:e78657.
- [10]. Gharaei H, Mousavi MN, Daneshvar R, Hosseini M, Sazande S. Effect of clear corneal incision location on tear film following Phacoemulsification surgery. *Iranian Journal of Ophthalmology* 2009; 21:29-34.
- [11]. Kavitha C, et al. Evaluation of dryness of eyes after manual small incision cataract surgery with corneo scleral tunnel incision. *JCDR* 2012; 4461:2304.
- [12]. Chandan C, Udayaditya M, et al., Dry eye disease following MSICS; A study from eastern India. *IJAR* 2016; 6:270-3.
- [13]. Liu Z, Luo L, Zhang Z, Cheng B, Zheng D, et al. Tear film changes after phacoemulsification. *Zhonghua Yan Ke Za Zhi* 2002; 38:274-7.
- [14]. Mohana S, Abhik S, Bithi C. Comparative evaluation of dry eye following cataract surgery; A study from north India. *IOSRJDMS* 2014; 13:13-8.
- [15]. Oh T, Jung Y, Chang D, et al. Changes in the tear film and ocular surface after cataract surgery. *Jpn J Ophthalmol* 2012; 56:113-8.
- [16]. Saif MYS, et al. Dry eye changes after phacoemulsification and manual small incision cataract surgery *Int. J Ophthalmology Eye Res* 2016; 4:184-91
- [17]. Liu Xi, Yang-shun Gu, Ye-sheng Xu. Changes of tear film and Tear secretion after phacoemulsification in diabetic patients. *J Zhejiang Univ Sci B.* 2008; 9:324-328
- [18]. Cohen KL. Sterile corneal perforation after cataract surgery in Sjogren's syndrome. *Br J Ophthalmol* 1982; 66:179-182.
- [19]. Hardten DR. Dry eye disease in patients after cataract surgery. *Cornea* 2008; 27:855
- [20]. Insler MS, Boutros G, Boulware DW. Corneal ulceration following cataract surgery in patients with rheumatoid arthritis. *J. Am. Intraocul. Implant. Soc.* 1985; 11:594-597.
- [21]. Jones RR, Maguire LJ. Corneal complications after cataract surgery in patients with rheumatoid arthritis. *Cornea* 1992; 11:148-150.
- [22]. Roberts CW, Elie ER. Dry eye symptoms following cataract surgery. *Insight* 2007; 32:14-21. M. A. Lemp, C. Baudouin, J. Baum et al., The definition and classification of dry eye disease: report of the definition and classification subcommittee of the international Dry Eye Workshop, *Ocular Surface*, 2007, 5(2), 75-193
- [23]. M. A. Lemp, C. Baudouin, J. Baum et al., The definition and classification of dry eye disease: report of the definition and classification subcommittee of the international Dry Eye Workshop, *Ocular Surface*, 2007, 5(2), 75-193
- [24]. Sihota, R, and Tandon R. *Parsons' Disease of the Eye*, 20th ed., New Delhi: Elsevier, 2007
- [25]. Ministry of Health and Family Welfare, Govt. Of India. National Programme for Control of Blindness, Annual Report 2010-11, MOHFW, Govt of India, p. 109-111
- [26]. Ram J, Gupta A, Brar GS, Kaushik S, Gupta A. Outcomes of phacoemulsification in patients with dry eye. *J Cataract Refract Surg.* 2002 March; 28: 1386-1389
- [27]. Cho YK, Man Soo Kim. Dry Eye After Cataract Surgery and Associated Intraoperative Risk Factors. *Korean J Ophthalmol.* 2009 June; 23(2): 65-73.
- [28]. Mohana Sinha, Abhik Sinha, Bithi Chowdhury Comparative Evaluation of Dry Eye Following Cataract Surgery: A Study from North India: *IOSR Journal of Dental and Medical Sciences (IOSR-JDMS)*, 2014, 13 (6) Ver. III, 13-18.

- [29]. International Dry Eye WorkShop. 2007 Report of the international dry eye workshop (DEWS). *Ocular Surf.* 2007;5(2):65–202
- [30]. Nakamori K, Odawara M, Nakajima T, Mizutani T, Tsubota K. Blinking is controlled primarily by ocular surface conditions. *Am J Ophthalmol.*
- [31]. Patel S, Farrell JC. Age-related changes in precorneal tear film stability. *Optom Vis Sci.* 1989;66(3):175–178.
- [32]. Paschides CA, Stefaniotou M, Papageorgiou J, Skourtis P, Psilas K. Ocular surface and environmental changes. *Acta Ophthalmol Scand.* 1998;76(1):74–77.
- [33]. Pisella PJ, Pouliquen P, Baudouin C. Prevalence of ocular symptoms and signs with preserved and preservative free glaucoma medication. *Br J Ophthalmol.* 2002;86(4):418–423.
- [34]. Pharmakakis NM, Katsimpris JM, Melachrinou MP, Koliopoulos JX. Corneal complications following abuse of topical anesthetics. *Eur J Ophthalmol.* 2002;12(5):373–378

Emmanuel P Blessing" Vestibuloplasty using diode laser – A case report" *IOSR Journal of Dental and Medical Sciences (IOSR-JDMS)*, vol. 18, no. 8, 2019, pp 48-54.