

## Acute Appendicitis Due To Enterobius Vermicular in a Elderly Adult, Very Rare Finding in North costal Andhra Pradesh - A Case Report.

Dr. S.S.R.Nagendra Babu<sub>1</sub>, Dr.G. Nagabuhna rao<sub>2</sub>, Dr. R.Sasidhar<sub>3</sub>,  
Dr.N. Venugopal<sub>4</sub>

1(Civil assistant surgeon, Department of General Surgery, District Hospital, Vizianagaram (district), Andhra Pradesh, India.

2(Civil surgeon, Department of General Surgery, District Hospital, Vizianagaram (district), Andhra Pradesh, India.

3 (Civil Assistant surgeon, Department of General Surgery, District Hospital, Vizianagaram (district), Andhra Pradesh, India.

4(Civil surgeon, Department of General Surgery, District Hospital, Vizianagaram (district), Andhra Pradesh, India.

Corresponding author: Dr S.S.R. Nagendra Babu

---

**Abstract:** Vermiform appendix should not be considered a vestigial organ in human beings. It is a lymphoid organ which when inflamed causes serious trouble. The most common cause of acute appendicitis is obstruction of its lumen. Among all the causes of appendicitis Enterobius vermicular is a rare cause. It is commonly seen in children. It mimics the features of acute appendicitis but may not always be responsible for acute appendicitis. The finding of E.vermicularis in appendectomy specimens is infrequent. We report a case of acute appendicitis due to Enterobius vermicular in an elderly aged Male patient. Acute appendicitis due to parasitic infection is very rare in north costal Andhra Pradesh. In our institute it was the first case among the 150 cases of acute appendicitis in past 3yr. No Clinical features of intestinal Enterobius infection. But Features of sever acute appendicitis were present. If E.vermicularis is found to be the cause of appendicitis it should be confirmed by histopathological examination of the excised appendix though rare as in our case. , The patient underwent emergency Laparoscopic Appendectomy resected end of appendix contained bunch of worms, and should be given anti helminthes post operatively to all family members.

**Key words:** Appendicitis, Enterobius vermicular is, helminthes, intestinal, parasitic infection.

---

Date of Submission: 26-08-2019    Date of Acceptance: 10-09-2019

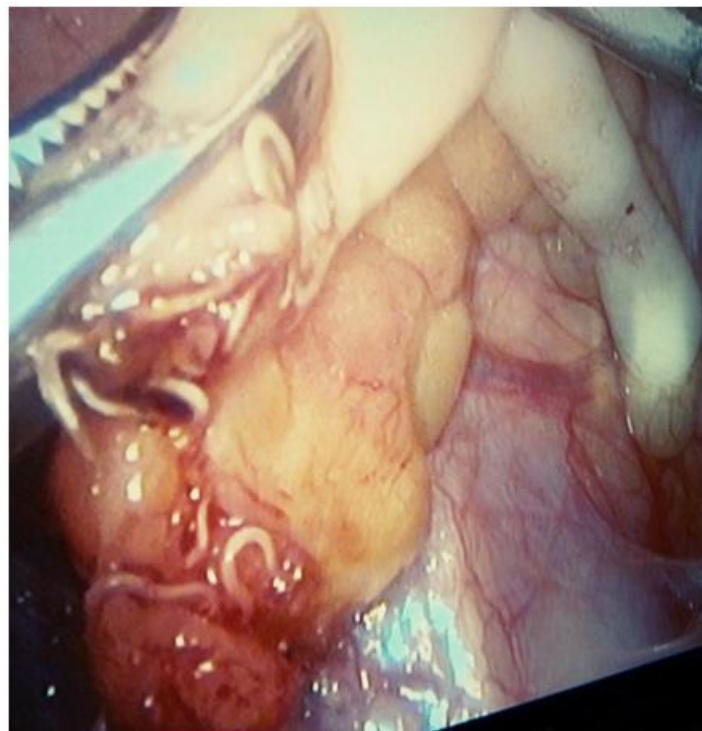---

### I. Introduction

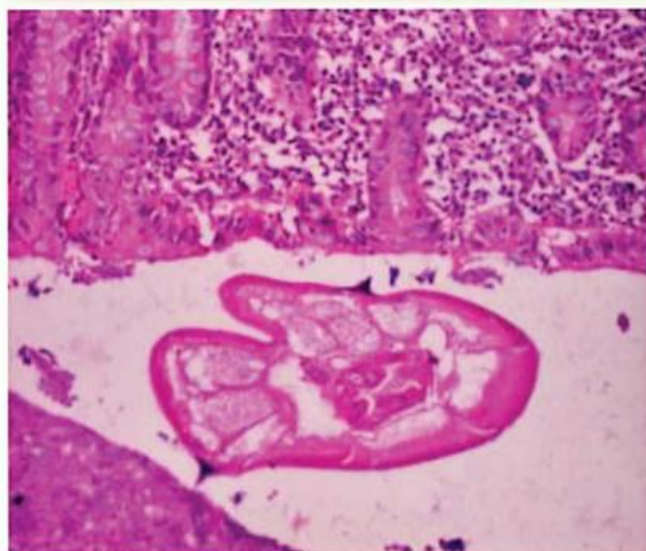
The vermiform appendix is a tubular structure found just below the ileocecal junction on the caecum. It has got an immune function and is no longer a vestigial organ. Most important implication of the appendix is acute appendicitis which is the most common surgical emergency worldwide [1]. The inflammation of appendix is generally secondary to obstruction of the lumen of the appendix. Most commonly it is caused by lymphoid hyperplasia, Fecoliths, foreign bodies, tumors or parasites. Among the parasites most common is Enterobius vermicular is. Mostly it is seen in children however no age is immune to this infection. Enterobius vermicular is can lead to acute appendicitis rarely but it is mostly diagnosed after surgery. Whether Enterobius vermicular is is responsible for acute appendicitis is not definitely clear but Enterobius vermicular is infestation can mimic the features of acute appendicitis. A course of antihelminthic treatment is required to get rid of the parasite From the alimentary tract after appendicectomy [2]. The reported incidence of Enterobius infestation in patients with symptoms of appendicitis ranges from 0.2–41.8% [3] . Several studies tried to document the relationship of pin worms and appendicitis but their causal relationship remains controversial. Enterobius vermicular is infestation can have a varied presentation.. E. vermicular is in the appendix can produce symptoms of acute appendicitis or 'appendiceal colic', independent of histological acute inflammation , or can produce no tissue reaction or a chronic inflammatory infiltrate of eosinophils may be associated or it can be responsible for histological appendicitis in extremely rare circumstances as is in our case.

## II. Case Summary

A 65 year old male patient presented to us with the complaints of colicky pain in the right lower abdomen for 5 days associated with vomiting (4 episodes) and fever for 5days. There was no migration of Pain. He had few episodes of similar pain in past. The patient didn't give any history of passage of worms in stools. The patient was febrile (99.6 degree centigrade) and had tachycardia (100/minute). There was tenderness in whole of the abdomen but most marked in right iliac fossa and the periumblical region. On abdominal examination, there was tenderness, rebound tenderness and guarding in the right iliac fossa .Rovsing sign positive there was no palpable lump and no signs of generalized peritonitis. Modified Alvarado score 9-10. A clinical diagnosis of acute appendicitis was made. Total leucocytes count was raised (14500/cubic millimeter) with 80% neutrophils, 18% lymphocytes and 2% other cells. Ultrasound of the abdomen was suggestive of acute appendicitis. Abdominal X-rays showed few ileal loops with air fluid levels in right iliac fossa. Patient was taken up for surgery, after fluid resuscitation and administration of broad spectrum antibiotics. An emergency laparoscopic appendectomy was performed. Appendix was found inflamed, congested, elongated, multiple worms visible at base of cut end of appendix. It was sent for histopathological examination, which revealed acute appendicitis showing cut section of a parasite: Enterobius vermicularis ( Fig. 1 and Fig. 2) . The patient was given single doses of Albendazole [400mg] and ivermectin [600mg] post operatively and follows up till date is uneventful. Other family members were also given same treatment and were followed up to repeat another dose of 400 mgof albendazole after two weeks. The histopathological report confirmed the diagnosis of acute appendicitis and Enterobius vermicularis found in lumen. The patient has recovered well.



**Figure No 1** worms with appendix (laparoscopic view)



**Figure 2 :** Cut section of appendix showing *Enterobius vermicularis*

### III. Discussion

Appendix is an innocent looking organ situated below the ileocecal valve on the caecum in human beings. It is usually 6-9 cm long however may range in length from 1-30 cm. Its acute inflammation is the most common surgical emergency, thus emergency appendectomy is the most commonly performed emergency surgery worldwide [1]. Having a tubular structure and a narrow lumen makes it more prone to closed loop obstruction. The common causes of acute appendicitis are faecal stasis, Fecoliths and lymphoid hyperplasia. Rarely intestinal parasites can cause acute appendicitis [2]. In early twentieth century Aschoff said that parasites were responsible for about 1% cases of appendicitis. Most prominent of these parasites is *Enterobius vermicularis* [4]. *Enterobius vermicularis* is responsible for infestation of 200 million people across the globe [1] While often considered tropical, parasitic diseases are now seen more frequently in development countries because of immigration and increased world travel. It is most commonly seen in children however it can infect all age groups. The infection is usually asymptomatic but the patient complains of pruritus ani, lethargy, generalized weakness or abdominal colic. It is the major parasite of appendix however it is mainly seen in terminal ileum and ascending colon. The appendix can be inflamed due to parasite inside the lumen or due to ova of the parasite inside the appendix. The diagnosis is by examining the cellophane tape under the microscope which has been run across the perianal region of the patient for pinworms or eggs. The eggs are smooth, elongated, flat on one side and convex on other side and occasionally may contain a fully developed larva. They don't have particular staining characteristics. The female worms are almost completely full of eggs [5]. Still, first described the relationship between appendicitis and *Enterobius vermicularis* in late nineteenth century [2]. This infection can give rise to appendiceal colic's or mimic them, hence most of the times normal appendices are reported after appendectomy. *Enterobius vermicularis* is seen in 0.6% to 3.8% of the appendectomy specimens. Inflammation in appendices containing *Enterobius vermicularis* is seen in 13-37% cases [6]. Appendicitis usually presents with a history of abdominal pain migrating to right iliac fossa along with nausea, vomiting and fever. The patients complain of anorexia. [4] Retrospective studies have indicated that *Enterobius vermicularis* is the commonest worm found in the appendix and that its presence can cause pathologic changes ranging from lymphoid hyperplasia to acute phlegmonous inflammation with life-threatening complications like gangrene and peritonitis The diagnosis is usually clinical but may be aided by ultrasound of the abdomen or CT-Scan of the abdomen. Alvarado score is an excellent tool for diagnosing acute appendicitis. It makes use of signs, symptoms and laboratory investigations in a patient of acute appendicitis. However the clinical features in children may be confusing. Omentum is known as 'Policeman of abdomen' which is not well developed in children. Normally the omentum migrates to right iliac fossa to contain the inflammation but not in children. Thus appendicitis may present with peritonitis in children and delay in diagnosis and treatment may be fatal. Here CT-Scan of the abdomen may be valuable in reaching the diagnosis [6]. Appendectomy is the treatment of choice for acute appendicitis however some patients may be managed conservatively with the help of injectable antibiotics and analgesics. The patients having *Enterobius vermicularis* infection should be given antihelminthics after appendectomy for taking care of rest of the parasites in the gut and preventing future complications [7]. Commonly used antihelminthics like albendazole, mebendazole and pyrantel pamoate are effective in treatment of pinworm infection. A single dose of any of these drugs repeated after two weeks is

sufficient. Family members and classmates who are infected should be treated simultaneously. Personal and group hygiene should be improved. Children should be advised to avoid licking fingers and to wash hands properly [4]. Careful history, clinical examination and look out for pruritus ani or eosinophilia in the blood examination, will definitely prevent unnecessary appendectomies [8].

#### **IV. Conclusion**

1. Acute appendicitis is the most common surgical emergency and emergency appendectomy most common operation being performed worldwide. Though the abdominal parasites are rare cause of acute appendicitis but they must be considered as a possible suspect among children. Adult may not present with typical features of acute appendicitis which further complicates the situation. The key to diagnosis is patient history, good clinical knowledge and repeated examinations. Treatment of choice is appendectomy but antihelminthic treatment should be given before the patient is discharged from the wards. At the same time family members should be treated too, so as to prevent the further relapses and infection.

#### **Consent**

Written informed consent was obtained from the patient for publication of this Case Report and any accompanying images. A copy of the written consent is available for review by the Editor-in-Chief of this journal.

#### **References**

- [1]. Burkitt DP (1971) The aetiology of appendicitis. *Br J Surg* 58: 695-699.
- [2]. Yabanoğlu H, Aytaç HÖ, Türk E, Karagülle E, Çalışkan K, et al. (2014) Parasitic Infections of Appendix. *Turkiye Parazitoloj Derg* 38: 12-26.
- [3]. Eleni Efraimidou, Anthia Gatopoulou, Charilaos Stamos, Nikolaos Lirantzopoulos and George Kouklakis; Enterobius Vermicularis infection of the appendix as a cause of acute appendicitis in a Greek adolescent: a case report, *Cases Journal* 2008, 1:376 doi:10.1186/1757-1626-1-376 (Cases Journal).
- [4]. Pickering LK, Baker CJ, Long SS, McMillan JA (2006) 2006 Report of the Committee on Infectious Diseases (27th edn.), American Academy of
- [5]. Pediatrics, United States of America
- [6]. Aydın O (2007) Incidental parasitic infestations in surgically removed appendices: a retrospective analysis. *Diagn Pathol* 2: 16.
- [7]. Aydın O (2007) Incidental parasitic infestations in surgically removed appendices: a retrospective analysis. *Diagn Pathol* 2: 16.
- [8]. Panidis S, Paramythiotis D, Panagiotou D, Batsis G, Salonikidis S, et al. (2011) Acute appendicitis secondary to Enterobius vermicularis infection in a middle-aged man: a case report. *J Med Case Rep* 5: 559.
- [9]. Stavros Panidis, Daniel Paramythiotis, Dimitris Panagiotou, Georgios Batsis, Spyridon Salonikidis, Vassiliki Kaloutsi and Antonios Michalopoulos; Acute appendicitis secondary to Enterobius vermicularis infection in a middle-aged man: a case report, *Journal of medical case reports*. 2011, 5:559. (Journal of medical case report).

Dr S.S.R. Nagendra Babu" Acute Appendicitis Due To Enterobius Vermicular in a Elderly Adult, Very Rare Finding in North costal Andhra Pradesh - A Case Report." *IOSR Journal of Dental and Medical Sciences (IOSR-JDMS)*, vol. 18, no. 9, 2019, pp 01-04.