

“Case Study of Obstructed Labor Caused By Sacrococcygeal Teratoma in Foetus”

Dr Rekha Verma

Consultant gynecologist, Vishakha hospital Jaipur

Background: Neonatal tumors are usually prenatally diagnosed or within the first 30 days of life. The true incidence of neonatal tumors is unknown as a great number of pregnancies with a prenatally diagnosed mass result in stillbirth or miscarriage. Most solid neonatal tumors are benign whereas less than 50% of neonatal neoplasms are malignant; however, some tumors with malignant patterns may histologically show benign behaviors. The incidence of malignant tumors is 1 in every 12,500-27,500 live births, accounting for 2% of all childhood cancers. Teratomas are the most common perinatal neoplasms, accounting for 25-33% of the cases. Around two-thirds of all sacrococcygeal teratomas (SCTs) are reported in the neonatal period but with a small risk of malignancy. Case report: Herein, we reported a case of SCT in a newborn leading to a complicated cesarean delivery. Conclusion: In general, teratomas are embryonic typically benign tumors arising from germ cells. They usually consist of various tissues originating from two or more embryonic layers. These tumors are believed to be the most common neonatal germ cell tumors. The sacrococcygeal region is the most common site for extra gonadal teratomas formation. Keywords: Neonatal tumors, Neoplasm, Teratoma

Date of Submission: 14-01-2020

Date of Acceptance: 30-01-2020

I. Introduction

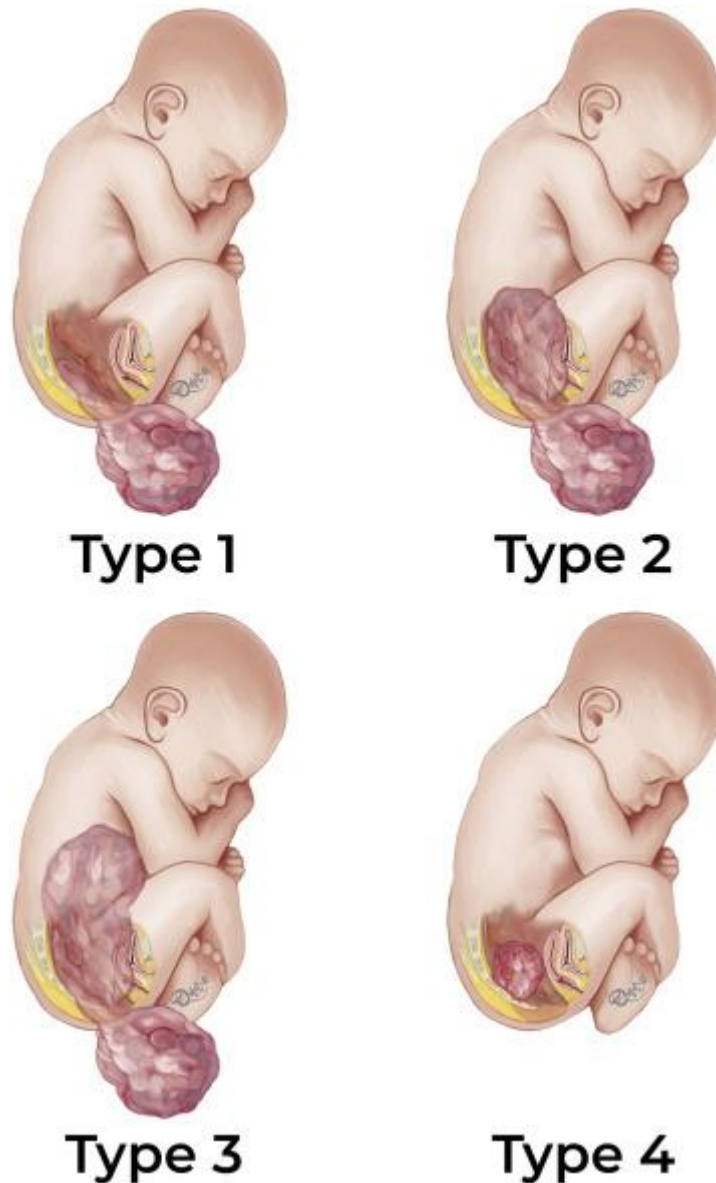
Most teratomas occur in ovaries and testes of adolescents and originate from germ-cells. Teratomas can also be found in midline structures: sacrococcygeal, presacral, retro peritoneum, post anal or even anterior mediastinum and pineal gland [1]. Teratomas of non-gonadal location originate from embryonic cells. Various theories try to explain the origin of teratomas. The pathogenesis is generally thought to be a growth of primitive totipotential cells that have differentiated and matured. According to the germ cell theory the totipotential cell is a “wandering germ cell” left behind during migration of embryonic germ cells from yolk sac to the gonad. According to the most popular theory the source of totipotential cells is a residual cell from the primitive streak and Hansen node of very early embryonic development. Normally, this primitive structure degenerates, however remains may persist in the sacrococcygeal region and develop into teratomas. There is also the theory that teratomas might be the result of twinning attempts [2,3].

Familial form of presacral teratomas, inherited in an autosomal dominant pattern, has been reported. They differ from usual teratomas because of nearly equal sex prevalence, a low prevalence of malignancy and a sacral defect [3].

Primary presacral teratomas are extremely rare in adults. Teratomas of such localization appear in neonates and young adults. Sacrococcygeal teratomas are most commonly found in neonates, infants and children younger than four years. They appear with incidence of approximately 1:35,000–40,000 live births and a female to male ratio 4:1 [4]. Most changes can be diagnosed prenatally, 50–70% are found during first few days of life, less than 10% are diagnosed beyond the age of two years [2]. Malignant transformation has been found in approximately 1% of teratoma patients comprising squamous cell carcinoma, adenocarcinoma, sarcoma and other malignancies [4]. In adults presacral teratomas occur at a rate between 1 in 40,000 and 63,000 with female preponderance 3:1 [5]. Multiple masses of tumor are extremely unusual, only two cases have been reported [2].

Tumours of sacrococcygeal location originate ventral or dorsal to the sacrum, they may grow poster inferiorly into the gluteal area or anterosuperiorly into the lesser pelvis. Especially in the ventral location these tumors may grow to a large size as they develop into the retro rectal or presacral space [5].

Altman et al. classifies sacrococcygeal teratomas. They marked out 4 categories by location. Type I are predominantly external tumours with minimal presacral component. Type II presents externally but with significant intrapelvic extension. Type III is still apparent externally but predominantly a pelvic mass extends into the abdomen. Type IV is a presacral mass with no external presentation. Our case conform type IV of Altman’s classification, although most common in adults is type III [6]. Other literature stated that the type I SCT carry the best prognosis [6].



Case Report

A 22 YEAR LADY come at Vishakha hospital on 22 October 2017.it was referred case from remote area complaining of 8 month amenorrhea with difficulty in labour.Patient have labor pain since 2 days and was referred from PHC level

Patient was exhausted, cooperative and have a labor pain.

P/A abdomen overdistended, tense, fetal heart cannot localized

P/V Cervix thick and edematous, 1 (F), uneffaced, presenting part high up. Foul smelling greenish liquor seen,.

ultrasonography done showing the single intrauterine dead fetus of 34 weeks in vertex presentation, liquorexcess and a $15.6 \times 14 \times 6.4$ cm mass was found in the sacrococcygeal region with a lobulated surface and variable consistency.no spinal cord, rectum, or bladder involvement, and other congenital anomalies

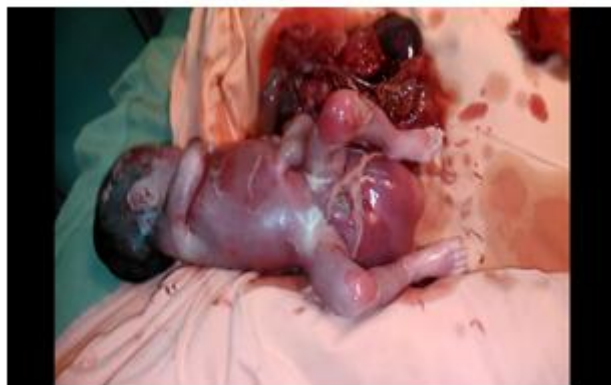. All laboratory examination were within normal limits (Hemoglobin 14 g/dL, serum creatinine level 0.9 mg/dL, blood urea nitrogen (BUN) level 27 mg/dL, blood glucose level 80 mg/dL, bilirubin 1mg/dL, activated partial thromboplastin time (aPTT) 37.4, prothrombin time (PT) 14.9, international normalized ratio (INR) 1.13, serum electrolytes and urine examination are normal

Due to obstructed labor decision for caesarian section taken

Operative notes

Under all aseptic condition P&Ddone. SpinalAnesthesiagiven. Abdomen open by transverse incision in layers, niche over the uterus was given. Excessive liquor drain which was meconium stained, a female dead baby extracted in vertex position with two tight loop of cord around the neck. Baby have a huge mass at sacral region. Baby handed over to paedetrician.Placenta was big in size and with calcification, removed. Uterus

closed in two layers. Abdomen closed in layers. Postoperative period was uneventful. The tumor was classified as SCT type I according to The American Academy of Pediatrics Surgical Section (AAPSS) classification.



Histopathology examination shown the tumor belong to cystic teratoma. Tumor tissue consists of glial tissue, connective tissue, smooth muscle tissue, skeletal muscle tissue, adipose tissue, bronchus epithelium, squamous epithelium, and eccrine gland. The cysts that form papillae are lined by columnar epithelium. Other cysts are lined by squamous epithelium. No evidence of malignancy was found. Karyotyping test of both parents were normal.

II. Discussion

Sacrococcygeal teratoma has already been described in some chromosomal disorders syndrome such as partial trisomy 1q, partial trisomy 3q, and mosaic $r(21)(7-9)(11-18)$ and genomic gain in 1q and 12p has been observed in sacrococcygeal teratoma. Furthermore, it has been shown that some genes in individuals with trisomy 21 may inhibit the generation and growth of tumors originating from the remnant of Hensen's node.⁽¹⁰⁾

Quri MeihaeraniSavitr et ALi Benign teratomas are more common in the newborn. Ten percent of the cases are malignant in the neonatal period, and more than 50% are malignant if the resection is delayed. The tumor which grows quickly may cause higher maternal obstetric complication during the perinatal periods such as tumor rupture, preterm labor, or dystocia. A large tumor may cause dystocia and therefore, cesarean section may be required. Alpha-fetoprotein (AFP) tumor marker is helpful in distinguishing benign and malignant teratomas during the antenatal period. AFP value is also important as a prediction of the presence of residual tumor.

Aparna Girwalkar-Bagle et al There is a rare condition called 'Mirror syndrome', where the mother mirrors the baby's sickness.¹³ This is due to fluid retention in fetal compartments, water retention in mother also occurs and she suffers the same symptoms as the sick fetus. Mother will become ill and have signs of preeclampsia, water retention, and high blood pressure, protein in the urine, placetomegally and failing heart. If this occurs baby should be delivered immediately. Early diagnosis may necessitate delivery by cesarean

Altman et al., SCTs were classified into three groups based on their size and diameter as small (2-5 cm), moderate (5-10 cm), and large (>10 cm) (7); accordingly, our patient had a large tumor. On ultrasound, SCT was reported as type I that is the most common type in neonates and has a low risk of developing malignancy (1, 5)

III. Conclusion

SCTs in the neonatal period and early childhood are mostly benign. Commonly, the uterus mother is larger compared to gestational age. Regular antenatal check-ups and ultrasonography are recommended for all pregnant mother to avoid organ dysfunction, diminished quality of life, and mortality. Early diagnosis and proper surgical intervention have the best outcome in most cases.

References

- [1]. Cho SH, Hong SC, Lee JH, et al. Total laparoscopic resection of primary Larde Retroperitoneal Teratoma Resembling an Ovarian Tumor in an Adult. *J Minim Invasive Gynaecol.* 2008;15:384–86. [PubMed] [Google Scholar]
- [2]. Park YJ. Multiple Presacral Teratomas in an 18-year-old Girl. *J Korean Soc Coloproctol.* 2011;27(2):90–93. [PMC free article] [PubMed] [Google Scholar]
- [3]. Keslar P, Buck J, Suarez E. From the archives of the AFIP. *Radio Graphics.* 1994;14:607–20. [Google Scholar]
- [4]. Golas MM, Gunawan B, Raab BW, et al. Malignant transformation of an untreated congenital sacrococcygeal teratoma: a amplification at 8q and 12p detected by comparative genomic hybridization. *Cancer Genet Cytogenet.* 2010;197(1):95–98. [PubMed] [Google Scholar]
- [5]. Paramythiotis D, Papavramidis T, Michalopoulos A, et al. Chronic constipation due to presacral teratoma in a 36-year-old woman: a case report. *J Med Case Rep.* 2010;4:23. [PMC free article] [PubMed] [Google Scholar]

- [6]. Altman RP, Randolph JG, Lilly JR. Sacrococcygeal teratoma: American Academy of Pediatrics Surgical Section Survey-1973. *J Pediatr Surg.* 1974;9(3):389–98.[PubMed] [Google Scholar]
- [7]. Dische MR, Gardner HA. Mixed teratoid tumors of the liver and neck in trisomy 13. *Am J Clin Pathol.* 1978;69:631–637.
- [8]. Yapar EG, Ekici E, Gökmen O. Sonographic diagnosis of epignathus (oral teratoma), prosencephaly, meromelia and oligohydramnios in a fetus with trisomy 13. *Clin Dysmorphol.* 1995;4:266–271.
- [9]. Hargitai B, Csabai L, Bán Z, et al. Rare case of exomphalos complicated with umbilical cord teratoma in a fetus with trisomy . *Fetal Diagn Ther.* 2005;20:528–533.
- [10]. Kobayashi T, Sakemi Y, Yamashita H. Increased incidence of retroperitoneal teratomas and decreased incidence of sacrococcygeal teratomas in infants with Down syndrome. *Pediatr Blood Cancer.* 2014;61:363–365.
- [11]. Wax JR, Benn P, Steinfeld JD, Ingardia CJ. Prenatally diagnosed sacrococcygeal teratoma. A Unique Expression of Trisomy 1q. *Cancer Genet Cytogenet.* 2000;117:84–86.
- [12]. Dundar M, Uzak A, Erdogan M, et al. Partial trisomy 3q in a child with sacrococcygeal teratoma and Cornelia de Lange syndrome phenotype. *Genet Couns.* 2011;22:199–205.
- [13]. Chen CP, Chang SD, Lee YX, et al. Ring chromosome 21 presenting with sacrococcygeal teratoma: prenatal diagnosis, molecular cytogenetic characterization and literature review. *Gene.* 2013;522:111–116.
- [14]. López Ginés C, Gil R, Pellin A, Martorell M, Vilar F, Llombart-Bosch A. Trisomy 12 and translocation (7;9) in an ovarian immature teratoma. *Int J Gynecol Pathol.* 1989;8:277–285.
- [15]. Schwartz S, Raffel LJ, Sun CC, Waters E. An unusual mosaic karyotype detected through prenatal diagnosis with duplication of 1q and 19p and associated teratoma development. *Teratology.* 1992;46:399–404.
- [16]. Mertens F, Kullendorff CM, Hjorth L, Alumets J, Mandahl N. Trisomy 3 as the sole karyotypic change in a pediatric immature teratoma. *Cancer Genet Cytogenet.* 1998;102:83–85.
- [17]. Le Caignec C, Winer N, Boceno M, et al. Prenatal diagnosis of sacrococcygeal teratoma with constitutional partial monosomy 7q/trisomy 2p. *Prenat Diagn.* 2003;23:981–984.
- [18]. Batukan C, Ozgun MT, Basbug M, Caglayan O, Dundar M, Murat N. Sacrococcygeal teratoma in a fetus with prenatally diagnosed partial trisomy 10q (10q24. 3→qter) and partial monosomy 17p (p13. 3→ pter). *Prenat Diagn.* 2007;27:365–368.

Dr Rekha Verma "Case Study of Obstructed Labor Caused By Sacrococcygeal Teratoma in Foetus" *IOSR Journal of Dental and Medical Sciences (IOSR-JDMS)*, 19(1), 2020, pp. 43-46.