

Role of Ct in the Evaluation of Acute Pancreatitis

Dr.K.Sambasivarao¹ Dr.B.Anuradha² Dr.P.Kusumalatha³ Dr.K.S.Suneetha⁴

^{1.} Associate Professor In Radiodiagnosis, Rangaraya Medical College, Kakinada

^{2.} Corresponding Author : Associate Professor In Radiodiagnosis, Rmc, Kakinada

^{3.} Assistant Professor In Radiodiagnosis, Rmc, Kakinada

^{4.} Assistant Professor In Radiodiagnosis, Rmc, Kakinada

Abstract:

Objectives: To determine the role of computed tomography in the evaluation of Acute Pancreatitis.

Materials & Methods: This study was conducted in Department of Radio-diagnosis in Government general hospital Kakinada between January 2019 to July 2019. This study comprised of 50 cases on clinical suspicion/diagnosis of Acute Pancreatitis.

Results: Edematous pancreatitis was in 48% patients and pancreatic necrosis was in 32% patients. Other features like diffuse/focal pancreatic enlargement in (76%), peri-pancreatic fat stranding in (72%) and peri-pancreatic fluid collection in (20%). The accuracy and sensitivity of CT in the diagnosis of Acute Pancreatitis was 100% accuracy and sensitivity.

Conclusion: Computed tomography is a sensitive, non-invasive imaging in early diagnosis and staging of severity of acute pancreatitis which help in prediction of prognosis of the disease. Modified CT severity index helps in evaluating the percentage pancreatic necrosis and to predict the possibility of developing local and systemic complications

Keywords: Computed tomography, Acute pancreatitis, Modified CT severity index, Pancreatic necrosis.

Date of Submission: 14-01-2020

Date of Acceptance: 28-01-2020

I. Introduction:

Acute pancreatitis is an acute inflammatory disease of pancreas, typically presenting with abdominal pain and associated with raised levels of pancreatic enzymes in the blood. It has a broad spectrum of findings that varies in severity from mild interstitial or edematous pancreas to severe forms with significant local and systemic complications. It is a common disease with high rate of morbidity and mortality.

Computed tomography is the gold standard non-invasive technique to identify the morphology of pancreas, peripancreatic regions and complications associated with acute pancreatitis. Contrast-enhanced computed tomography helps in early diagnosis and staging of severity of acute pancreatitis and helps in prediction of prognosis of the disease.

CT severity index (CTSI) popularly called Balthazar scoring system based on pancreatic morphology, number of peri-pancreatic fluid collections and pancreatic necrosis. Now Modified Computed Tomography Severity Index (MCTSI) has been introduced by including the presence of extra pancreatic complications and grading the peripancreatic fluid collection in terms of presence or absence instead of the number of fluid collections. The grading of necrosis is also different in this system.

II. Materials & Methods :

This study was conducted in Department of Radio-diagnosis in Government general hospital, Rangaraya Medical College, Kakinada between January 2019 to July 2019. The present study comprised of 50 cases on clinical suspicion/diagnosis of acute pancreatitis, altered biochemical parameters (serum amylase, serum lipase) and ultrasonography in favour of acute pancreatitis, Ultrasonography suggestive of chronic pancreatitis with features of acute symptoms are taken up for computed tomography study and evaluated. Patients with Chronic pancreatitis, Congenital pancreatic lesions, Pancreatic carcinoma and metastasis, Pancreatic trauma were excluded from the study.

CT scan was done using a GE Revolution Acts 16 slice CT scanner. Plain and post-contrast series of the abdomen and pelvis were taken. Acquisition of contiguous axial sections, of thickness 5mm of abdomen and pelvis, 3mm in region of interest in the cranio-caudal direction from the level of the xiphisternum to pubic-symphysis before and after administration of oral and intravenous iodinated contrast of 80-100 ml. All images were viewed in a range of soft tissue window settings. The patient was explained prior to the procedure and written consent was taken from the patient/ by stander. The patient was asked to be in overnight nil-oral status

and after obtaining renal function tests the contrast-enhanced CT was done. Clinical details, laboratory, ultrasonography and computed tomography findings of the case were recorded as per the proforma.

III. Results:

The present study was done on 50 patients, of which 44 patients were male and 6 were female, with a male to female ratio of 7.3:1 indicating a higher incidence of Acute Pancreatitis in males. 88% patients were males and 12% patients were females.

Majority of the cases were in the age group of 20-30, with 20 (40%) patients, followed by 30-40 years with 18 (36%) patients. Indicating the higher incidence (76%) of Acute Pancreatitis (38 out of 50 cases)between the ages 20 -40 years . the mean age group in the study was 33 years.

History of alcohol intake was seen in 42 cases, indicating the most common cause of Acute Pancreatitis in 84% of the cases. Followed by gall stones(GB/CBD) in 8 cases. Alcohol consumption was the commonest cause of acute pancreatitis in about 95% of the male patients and gall stone ileus was the commonest cause in 100% of the female patients .

Ultrasonography has been inconclusive or normal in 15 cases and diagnostic in 35 cases indicating the diagnostic accuracy of 70% in Acute Pancreatitis patients.

CECT has been diagnostic in identifying the pancreatic parenchymal morphology as Acute edematous pancreatitis in 24 cases (48%) and Acute necrotising pancreatitis in 16 (32%) cases. Acute on chronic pancreatitis has been diagnosed in 10 (20%) patients.

Diffuse/focal pancreatic enlargement has been identified in 38 (76%) patients, followed by peri-pancreatic fat stranding in 36 (72%) patients and peri-pancreatic fluid collection in 20 (40%) patients. Pancreatic pseudocysts of varying sizes have been identified in about 22(44%) of the patients. Ascites was the most common extra pancreatic complications noted in our study in 30 (60%) patients followed by pleural effusions in 25 (50%) patients. No complication was noted in 5 cases (10%) in our study. The accuracy and sensitivity of serum amylase in diagnosing Acute Pancreatitis is 44% (22 cases). The accuracy and sensitivity of serum lipase in diagnosing AP is 76% in 38 cases . CECT has showed 100% accuracy and sensitivity in identifying cases of Acute pancreatitis.

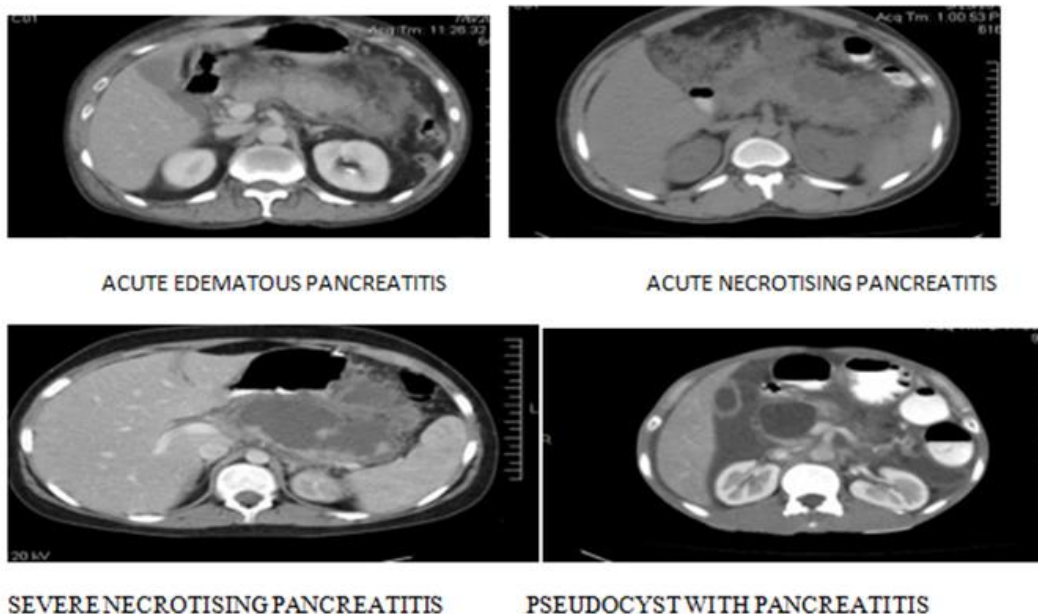
Patients were classified as per the Modified CT Severity Index (MCTSI) as mild (2 and 4), moderate (6) and severe (8 and 10) of which majority had mild Acute Pancreatitis of 64% patients, 22% patients had moderate and 14% patients had severe pancreatitis .

MTCSI SCORES	NO.OF PATIENTS	PERCENTAGE
2& 4 (Mild)	32	64%
6 (Moderate)	11	22%
8 & 10 (Severe)	07	14%

Distribution of pancreatic necrosis according to MCTSI was 6% patients in mild, 10% patients in moderate and 16% patients in severe.

CT Grade	Pancreatic necrosis	PERCENTAGE
2& 4 (Mild)	3	6%
6 (Moderate)	5	10%
8 & 10 (Severe)	8	16%

In our study intervention was needed in the form of radiological guidance of aspiration in 16% patients, fluid aspiration without radiological guidance in 8% patients and surgical intervention in 10% patients.



IV. Discussion:

The present study Computed Tomography evaluation of Acute pancreatitis was conducted in Department of Radio-diagnosis in Government general hospital, Kakinada between January 2019 to July 2019. This study comprised of 50 cases on clinical suspicion/ diagnosis of acute pancreatitis. These patients underwent CECT of the abdomen and pelvis, and were graded according to the modified CT severity index.

Most of the patients were male (88 %) as compared to female (12%). No association of age and gender was noted with severity of pancreatitis in our study. These observations were similar to that of a study conducted by Lankish et al on 602 patients of acute pancreatitis which showed no correlation between age, gender with severity of acute pancreatitis. The study also showed the maximum incidence of acute pancreatitis in age group 20 to 40 years similar to our study.

Majority of the cases were in the age group of 20-30, with 20 (40%) patients, followed by 30-40 years with 18 (36%) patients. Indicating the higher incidence (76%) of Acute Pancreatitis (38 out of 50 cases) between the ages 20 -40 years. The mean age group in the study was 33 years. History of alcohol intake was seen in 42 cases, indicating the most common cause of Acute Pancreatitis in 84% of the cases. Followed by gall stones(GB/CBD) in 8 cases. Alcohol consumption was the commonest cause of acute pancreatitis in about 95% of the male patients and gall stone ileus was the commonest cause in 100% of the female patients. A study by Wongnai et al conducted in 90 patients showed 60% patient of alcohol, 18% patient of CBD/MPD calculi.

Out of 50 cases, 24 (48 %) patients had edematous pancreatitis. 16 (32%) patients showed evidence of pancreatic necrosis out of which 10 had <30 of necrosis and 6 had >30 of necrosis. CT plays an important role in differentiating edematous and necrotizing form of Acute Pancreatitis, since clinical assessment alone cannot predict the severity of disease. A study by Bollen et al and Casas et al identified necrosis in 18 % and 15 % of patients with Acute Pancreatitis respectively. They concluded by saying that necrosis almost always occurs within 48 hrs after onset of symptoms. Glandular necrosis is an important feature for determining prognosis and guiding treatment in patients with Acute Pancreatitis. Diffuse/focal pancreatic enlargement was seen in 76% patients, peri-pancreatic fat stranding was seen in 72% patients and peri-pancreatic fluid collection was seen in 40% patients.

In the ultrasound studies conducted on the patients with Acute Pancreatitis direct evidence of pancreatitis (bulky and hypo echoic pancreas with peri pancreatic fluid) was seen in 25 patients (50%), Features consistent with pancreatitis was seen in 10 patients (20%) in form of ascites, pleural effusion (unilateral / bilateral). No abnormality was detected in 15(30%) of the patients. In the observation made by Balthazar et al abnormal ultrasound findings are seen in 33-90% of patients with Acute Pancreatitis. Edematous pancreatitis was depicted on ultrasound as an enlarged hypoechoic gland. Thus the main role of ultrasound in the imaging of Acute Pancreatitis is limited to the detection of cholelithiasis and choledocholithiasis and identification of fluid collections.

The accuracy and sensitivity of serum amylase in diagnosing Acute Pancreatitis is 44%. The accuracy and sensitivity of serum lipase in diagnosing Acute Pancreatitis is 76%. The samples were taken at the time of CECT and follow-up serum amylase/lipase levels were not included in these study. When compared with CT findings of these patients, it showed 100% accuracy and sensitivity which helps in early diagnosis and predicting the severity of AP. Balthazar et al says that early overall detection rate of 90% with 100% sensitivity. CECT is the most important imaging modality for diagnosis and staging of AP due to its ability in demonstrating early inflammatory changes as well as development of complication. The CT grades were classified into 2, 4, 6, 8 and 10 according to the MCTSI. We further classified the grades into mild (grade 2 & 4), moderate (grade 6) and severe (grade 8 & 10). The previous studies by Bollen et al and Mortelet et al have classified grade 2 as mild, grade 4 and 6 as moderate and grade 8 and 10 as severe. The prognosis of patients with grade 2 and 4 pancreatitis was similar and milder than patients who had a grade of 6 as observed in our study, hence were grouped together in our study.

The maximum patients were seen to fall in the mild -grade 2 and 4 category (64%) followed by moderate – grade 6 category in 22% and minimum patients (14%) were seen in grade 8 and 10 category. According to the study by Bollen et al the morphologic severity of pancreatitis was graded as mild in 86 (44%), moderate in 75 (38%), and severe in 35 (18%) cases. The study had patients with severe pancreatitis as the minimum number of patients which is similar to our study. Most patients are of mild grade in our study that possibly explains early use of CECT usefulness in mild cases of AP.

The extra-pancreatic complications were seen in 45 patients (90%) in our study. Ascites was seen in 30 patients (60%), and pleural effusions in 25 patients (50%). Most of the cases have both ascites and pleural effusions. According to Chishty et al, conducted a study in 40 patients of which extra-pancreatic complication was seen in 89%. Pseudocyst was seen in 22 patients (44 %) in our study. Pseudocyst formation occurred in 50% of patients in a study conducted by Gonzalez et al 53.

There was evidence of development of local complications in patients with mild pancreatitis. In our study intervention was needed in the form of laparotomy in 5 patients with large pseudocysts due to Acute Pancreatitis. Radiological intervention was needed in 8 patients (16 %) of grade 6, 8 and 10. Aspiration of pseudocyst and pleural effusion was needed in 8 patients (13%) with grade 4 and 6 of pancreatitis. Thus patients who need an intervention have more moderate and severe CT grades. This is similar to the study by Bollen et al which demonstrated that development of local complications and need for intervention was significantly associated with grade of pancreatitis.

According to Bollen et al The MCTSI accurately correlated with extrapancreatic complication and the need for intervention compared with clinical score indices (APACHEII). CT is the modality of choice for detecting the local complications. Thus the MCTSI is as useful in predicting the severity of AP in terms of organ failure, detecting the local complications and confirming necrosis in AP.

V. Conclusion:

CECT helps in differentiating between edematous and necrotizing pancreatitis. Serum lipase and amylase levels do not help to differentiate the type of Acute Pancreatitis. The MCTSI helps in evaluating the percentage pancreatic necrosis. Modified CT severity index can be used to predict the possibility of developing local and systemic complications. MCTSI grading correlates directly with the development of local and systemic complications. Modified CT severity index can predict the need for interventions.

References:

- [1]. Banks PA. Practice guidelines in acute pancreatitis. *Am J Gastroenterol.* 1996; 92:377-386.
- [2]. Carl Z, Pallie W. Correlative anatomy and computed tomography: A module on the pancreas and posterior abdominal wall. *Radiographics.* 1981 may; 1:61-83.
- [3]. Haaga JR, Dogra V, Forsting M, Gilkeson R, Kwon Ha H, Sundaram M. CT and MR imaging of the whole body. 5th ed. Philadelphia: Elsevier; 2003.p.1599–1667.
- [4]. Rizzo R, Szucs R, Turner M. Congenital abnormalities of the pancreas and biliary tree in adults. *Radiographics.* 1995 Jan;15:49-68.
- [5]. Kasper D, Brawnwald E, Fauci A, Hauser S, Longo D, Jameson L, et al. *Harrison's principles of Internal Medicine.* 17th ed. New York: McGraw-Hill; 2008.p.1895-1905.
- [6]. Freeny P.C.1988 "Radiology of the Pancreas": Two decades of progress in imaging and intervention. *AJR,* 150:975-981.
- [7]. Beger HG, Rau B, Mayer J, Pralle U. Natural course of acute pancreatitis. *World J Surg.* 1997;21:130-135.
- [8]. Balthazar E. Acute Pancreatitis: Assessment of Severity with Clinical and CT Evaluation. *Radiology.* 2002 Jun;223:603-613.
- [9]. Brown A, Baillargeon JD, Hughes MD. Can fluid resuscitation prevent pancreatic necrosis in severe acute pancreatitis? *Pancreatol.* 2002;2:104–7.
- [10]. Kalfarentzos F, Kehagias J, Mead N. Enteral nutrition is superior to parenteral nutrition in severe acute pancreatitis: Results of a randomized prospective trial. *Br J Surg.* 1997;84:1665–9.
- [11]. Isenmann R, Runzi M, Kron M. Prophylactic antibiotic treatment in patients with predicted severe acute pancreatitis: A placebo-controlled, double-blind trial. *Gastroenterology.* 2004;126:997–1004.
- [12]. Runzi M, Niebel W, Goebell H. Severe acute pancreatitis: Nonsurgical treatment of infected necroses. *Pancreas.* 2005;30:195–9.
- [13]. Sharma VK, Howden CW. Metaanalysis of randomized controlled trials of endoscopic retrograde cholangiography and endoscopic sphincterotomy for the treatment of acute biliary pancreatitis. *Am J Gastroenterol.* 1999;94:3211–4.

- [14]. Merkle EM, Rich J. Imaging of acute pancreatitis. *Eur Radiol.* 2002;12:1979–1992.
- [15]. Heller SJ, Noordhoek E, Tenner SM. Pleural effusion as a predictor of severity in acute pancreatitis. *Pancreas.* 1997;15:222–225.
- [16]. Rumack C, Wilson S, Charboneau W. *Diagnostic ultrasound.* 3rd ed. Missouri: Mosby; 2005.p 213-239.
- [17]. Scaglione M, Casciani E, Pinto A, Andreoli C, De Vargas M, Gualdi GF. "Imaging assessment of acute pancreatitis: a review.". *Semin Ultrasound CT MR.* 2008;29 (5): 322–340.
- [18]. Urban BA, Fishman EK. Tailored helical CT evaluation of acute abdomen. *Radiographics.* 2000;20:725-749.
- [19]. Uhl W, Roggo A, Kirschstein T. Influence of contrast-enhanced computed tomography on course and outcome in patients with acute pancreatitis. *Pancreas.* 2002;24:191–197.
- [20]. McMenamin DA, Gates LK. A retrospective analysis of the effect of contrastenhanced CT on the outcome of acute pancreatitis. *Am J Gastroenterol.* 1996;91:1384–1387
- [21]. Dr.Amogh VN, Dr. Balakrishna B.V. CT evaluation of acute pancreatitis 2013-14

Dr.K.Sambasivarao, et.al. "Role of Ct in the Evaluation of Acute Pancreatitis" *IOSR Journal of Dental and Medical Sciences (IOSR-JDMS)*, 19(1), 2020, pp. 69-73.