

# Comparative Study on Iris Claw Lens Implantation with and Without Peripheral Iridectomy and Its Effect on Post Operative Intraocular Pressure

Dr. Anant Singhi<sup>1</sup>, Dr. Nisha V. Ahuja<sup>2</sup>

<sup>1</sup> Fellow (Cataract and IOL), Sankara Eye Hospital, Mogar, Anand, Gujarat, India

<sup>2</sup> Consultant (Cornea and Cataract Services), Sankara Eye Hospital, Mogar, Anand, Gujarat, India

## Abstract:

**Aim:** To compare post operative intraocular pressure in patients undergoing iris claw implantation with and without surgical peripheral iridectomy.

**Materials and methods:** Patients who underwent iris claw implantation belonging to two groups, one with surgical peripheral iridectomy (PI) and one without peripheral iridectomy, were followed postoperatively for intraocular pressure and other parameters were also studied.

**Results:** 55 out of 60 patients achieved vision better than 6/18 on Snellen's chart. Corneal edema and raised IOP (20%) was the most common complication on day 1 followed by ovalization of pupil (16.67). Iritis was seen in only 10 % patients. Mean IOP on day 1 post surgery was significantly higher in patients who underwent iris claw implantation without surgical PI. Though at 6 weeks both groups were comparable with normal IOP.

**Conclusion:** IOP is seen to be raised in cases with Iris claw implantation without surgical PI on day 1 but it resolves with medical management. Final IOP were similar in both the groups irrespective of surgical PI performed or not. .

**Keywords:** Iris claw implantation, Peripheral iridectomy, intraocular pressure

Date of Submission: 22-12-2019

Date of Acceptance: 05-01-2020

## I. Introduction

Posterior chamber intraocular lens (PCIOL) implantation in the capsular bag might not be feasible under certain circumstances when there is insufficient capsular or zonular support. In cases with large posterior capsule rupture (PCR) or significant zonular dehiscence (ZD) or capsular bag delivery and acquired zonular weakness as in cases of ocular trauma, pseudoexfoliation syndrome, pathological myopia or hypermature cataract.

Various options are available for lens implantation in such eyes with inadequate capsular support. They are anterior chamber intraocular lens (ACIOL), scleral fixated IOLs (SFIOL), glued IOL, anterior iris fixated IOL, and posterior or retropupillary iris-claw IOL.<sup>1-3</sup>

Although ACIOLs have been used extensively, they are known to have a high risk of corneal decompensation and glaucoma.<sup>4</sup> The surgical technique for implanting SFIOLs and glued IOLs has a steep learning curve and needs more intraocular maneuvering.

In view of aphakia, pupillary block glaucoma due to anterior vitreous is a possibility. When implanting iris claw lens, though a thorough anterior vitrectomy is done, due to the size of the optic of the iris claw lens, a theoretical risk of pupillary block glaucoma still exists.

The aim of this study, therefore, was to analyze the results of anterior vitrectomy along with retropupillary iris-claw IOL implantation with and without surgical peripheral iridectomy during primary surgery or secondary aphakia correction in patients with regard to Intra Ocular Pressure (IOP) in post operative period.

## II. Materials And Methods

This prospective study included 60 patients. The cases belonged to two clinical settings: Elective secondary implantation in patients who were aphakic and those with intraoperative large posterior capsular rupture or zonular dehiscence. Other inclusion criteria were intact iris diaphragm, normal IOP at presentation and no other intraocular pathology. Exclusion criteria were large iris defects, chronic uveitis, and retinal disorders (proliferative diabetic retinopathy, macular scars and cystoid degenerations).

In elective secondary implantation, a 5.5 mm temporal scleral tunnel was made or revised according to duration from primary surgery using a crescent knife. Two paracenteses were made 180 degrees apart

perpendicular to the tunnel site. The anterior chamber was entered after injecting viscoelastic material. This was followed by anterior vitrectomy. The lens optic was firmly held with the iris claw holding forceps and positioned in the center, posterior to the pupil. The mid- peripheral iris was gently enclaved in the claw using Sinsky hook. Viscoelastic material was removed. Primary wound was closed with 10-0 nylon suture. In eyes with intraoperative large posterior capsular rupture or zonular dehiscence, implantation of posterior iris fixated IOL as explained above was preceded by anterior vitrectomy. Surgical Peripheral iridectomy was done with vitreous cutter in 30 patients chosen randomly (Group I) while in other 30 patients PI was not done (Group II). Intracameral antibiotic was given in both cases.

Postoperatively, topical steroid- antibiotic-cycloplegic regimen was followed. The patients received Ofloxacin-dexamethasone eye drops six times daily tapered over 6 weeks along with cyclopentolate eye drops for 2 weeks.

Postoperative assessment included visual acuity, slit lamp examination to see IOL stability and centration, IOP, postoperative intraocular inflammation (anterior chamber reaction), presence of hyphema, pigment dispersion and fundus evaluation to look for any complications.

Postoperative follow- up was done by a single observer on day 1, 2 weeks and 6 weeks in all patients.

Cells and flare in the anterior chamber were counted using a 1 by 1 mm slit and graded according to the Standardization of Uveitis Nomenclature (SUN) working group. IOP was measured with NCT on day 1 and applanation tonometry at 2 weeks and at 6 weeks.

### STATISTICAL METHODOLOGY

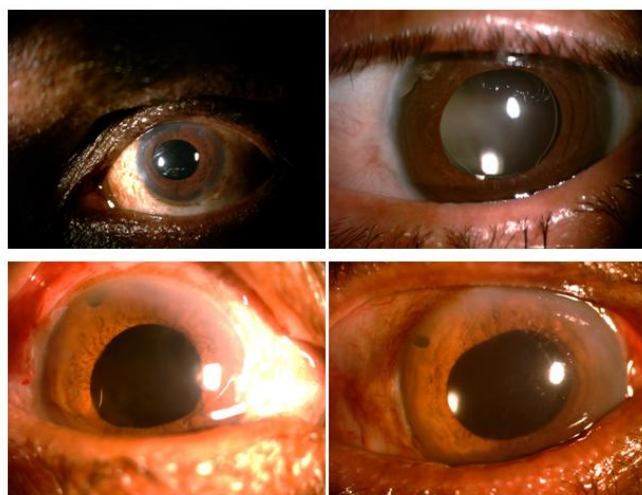
The data were presented as the mean ± standard deviation. Statistical differences during follow ups were assessed using a Paired t-test. To find correlation between the variables Pearson’s correlation of coefficient was applied. A p-value of less than 0.05 was considered to be statistically significant.

### III. Results:


Our study included 60 patients out of which 39 were males and 21 were females. Mean age was 65.1±9.484 years. 13 patients were enrolled for secondary IOL implantation, 29 patients had pre existing zonular weakness and 18 patients had intra operative large ZD or PCR necessitating iris claw implantation (Table 1)

TABLE 1: INDICATIONS FOR IRIS CLAW IMPLANTATION		
Secondary IOL implantation	Surgical <u>Aphakia</u>	13
Pre existing <u>zonular weakness</u>	<u>Pseudoexfoliation syndrome</u>	10
	Hyperature cataract	11
	Traumatic <u>subluxation</u>	8
<u>Intraoperative</u>	Large ZD/PCR	18

Out of 60 patients enrolled, 55 patients had preoperative vision of less than 6/60 on Snellen’s chart while only 4 patients had vision between 6/60 and 6/24. One patient had vision of 6/18. On contrary, at 6 week final follow up, 55 patients achieved vision better than 6/18 on Snellen’s chart while only 5 patients had vision less than 6/18. Only one patient had visual acuity less than 6/60.



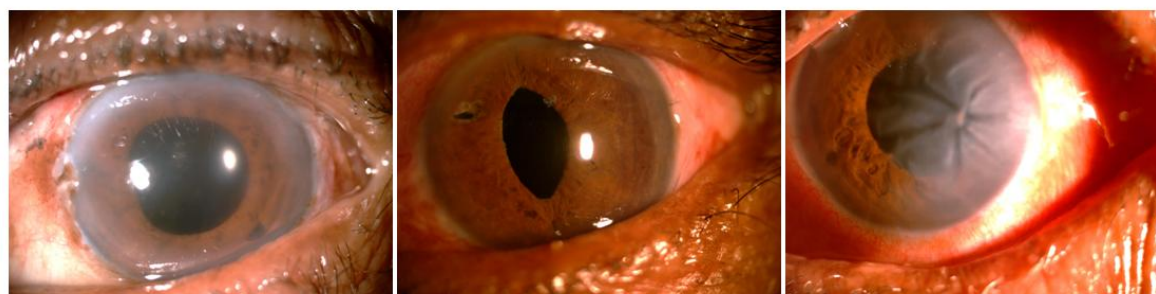**Figure 1:** Few patients with iris claw implantation.



**Figure 2:** Iris claw in retro illumination. Note PI

On slit-lamp biomicroscopic examination (Day 1), 12 patients had corneal edema while 8 patients had striate keratopathy which resolved by 1<sup>st</sup> week. (Figure 3) 6 patients had iritis with cells and flare of 2+ or more. These patients were put on frequent topical steroids, nonsteroidal anti-inflammatory drugs, and cycloplegics and recovered within 2 weeks.

Ovalization of the pupil was seen in 10 cases. (Figure 3)



**Figure 3:** Complications following Iris claw implantation A: Corneal edema, B: Ovalization of pupil, C: Striate keratopathy

2 patients from Group II (without PI) had shallow AC with mild raised IOP. Out of these two one was managed medically while one needed neodymium-doped yttrium aluminum garnet (Nd: YAG) laser peripheral iridotomy (PI). None of the patients had anterior chamber inflammation or hyphema or hypotony at and beyond 2 weeks follow-up. There were no major postoperative adverse events, decentration or dislocation of IOL in our series. None of the patient had any evidence of CME or Retinal detachment till 6 week follow up.

**Mean IOP in Group II on day 1 post surgery was significantly higher than Group I (Table 2).** At follow up visits, there was no significant difference noted in both groups.

	Pre Operative	Post operative period		
		Day 1	2 weeks	6 weeks
Iris claw with PI (Group I)	16.23±2.294	17.9±3.836	17±2.600	16.63±2.173
Iris claw without PI (Group II)	17.23±2.046	20.7±4.872	18.13±2.688	17.33±1.936
't' value	1.782	2.473	1.655	1.317
P value	0.080	0.0163	0.1033	0.1929
Significance	Not Significant	Significant	Not Significant	Not Significant

At day 1, Only 3 patients had raised IOP (> 21 mm/Hg) in Group I while 9 patients from Group II had raised IOP. At 2 weeks follow up, 4 patients from group II had slightly high IOP which also got normal in future follow ups with single drug regimen (timolol 0.5% eye drops ). (Table 3)

	Day 1	2 weeks	6 weeks
Group I	3	0	0
Group II	9	4	0

#### IV. Discussion:

Posterior iris-claw lenses also have the advantage of a simpler procedure, positioning near the nodal point, and no need for extra sutures or glue. There are very few studies supporting the use of posterior iris-claw IOL in aphakic patients with good postoperative results in terms of visual acuity. Our results were comparable to other studies of posterior iris-claw IOL implantation.<sup>5</sup>

None of our patients had chronic anterior chamber inflammation like studies by Jare *et al*<sup>5</sup> and Upadhyay *et al*.<sup>6</sup>

Similarly, raised IOP was observed in one out of 31 patients by Schallenberg *et al*.<sup>7</sup> and 3 out of 108 patients by Jare *et al*<sup>5</sup> where they did routine surgical PI in all the patients. We reported little raised IOP on day1 as many of our patients had primary iris claw implantation following intraoperative complications while these studies had secondary iris claw implantation and included surgical PI in every patients. IOP was managed medically and most patients had normal IOP by 2 weeks.

Although spontaneous disenclavation of one or both iris-claw haptics with or without dislocation of IOL has been reported, we encountered no such case in our series. Forlini *et al*.<sup>8</sup> have reported three cases of disenclavation, one case of spontaneous posterior dislocation. while Gonnermann *et al*.<sup>9</sup> have reported disenclavation in 8.7% eyes.

None of our patients had hyphema, hypotony, or pigment dispersion like Jare *et al*.<sup>5</sup>

The present publication reports the findings at the end of 6 weeks. The study, however, will continue to follow-up the cohort for a longer duration, notwithstanding the loss to follow-up expected over an extended period.

#### V. Conclusion:

Retropupillary iris-claw IOL combines the ease of anterior chamber IOL implantation with optical and physiological advantages of posterior IOL location, ensuring a good visual outcome and a low risk of complication.

The most common abnormalities after retropupillary iris-claw IOL implantation are ovalization of pupil, mild iritis, corneal edema which have no influence on final visual outcomes.

IOP is seen to be raised in cases with Iris claw implantation without PI on day 1 but it resolves with medical management. One patient developed pupillary block glaucoma which needed Nd:YAG Peripheral iridotomy. If proper anterior vitrectomy is done risk of pupillary block glaucoma is very minimal as seen in our study. Final IOP were similar to the cases where surgical PI was done.

Retropupillary iris-claw IOL implantation is a safe and relatively fast method in the cases of iatrogenic failure, which does not allow for intracapsular or sulcus implantation during primary complicated cataract surgery.

#### References

- [1]. Rao R,Sasidharan A. Iris claw intraocular lens: A viable option in monocular surgical aphakia. Indian J Ophthalmol 2013;61:74-5.
- [2]. Gicquel JJ, Langman ME, Dua HS. Iris claw lenses in aphakia. Br J Ophthalmol 2009;93:1273-5
- [3]. Evereklioglu C, Er H, Bekir NA, Borazan M, Zorlu F. Comparison of secondary implantation of flexible open-loop anterior chamber and scleral-fixated posterior chamber intraocular lenses. J Cataract Refract Surg 2003;29:301-8
- [4]. Snellingen T, Shrestha JK, Huq F, Husain R, Koirala S, Rao GN, et al. The South Asian cataract management study: Complications, vision outcomes, and corneal endothelial cell loss in a randomized multicenter clinical trial comparing intracapsular cataract extraction with and without anterior chamber intraocular lens implantation. Ophthalmology 2000;107:231-40.
- [5]. Jare NM, Kesari AG, Gadkari SS, Deshpande MD. The posterior iris-claw lens outcome study: 6-month follow-up. Indian journal of ophthalmology. 2016 Dec;64(12):878.
- [6]. Upadhyay AM, Nataraj A. Visual outcomes and complications of posterior iris-claw intraocular lens implantation in aphakic postvitrectomized eyes. Kerala Journal of Ophthalmology. 2017 Sep 1;29(3):184.
- [7]. Schallenberg M, Dekowski D, Hahn A, Laube T, Steuhl KP, Meller D, et al. Aphakia correction with retropupillary fixated iris-claw lens (Artisan) – Long-term results. Clin Ophthalmol 2014;8:137-41.