

Stabilization of Diaphyseal fractures of both bone forearm with Limited Contact Dynamic Compression plate vs Locking Compression plate: Comparison of clinical outcomes

Dr.Soumendu Nath¹, Dr. S.N. Chishti², Dr.TanujKanti Chaudhuri¹,
Dr.Kamleshkumar Sharma¹, Dr. Raja Nag¹

^{1.} Post Graduate trainee, Dept. of Orthopaedics, Regional Institute of Medical Sciences, Imphal, Manipur, India

^{2.} Professor and Head, Dept. of Orthopaedics, Regional Institute of Medical Sciences, Imphal, Manipur, India

Abstract:

Background: Conservative treatment of displaced forearm shaft fractures usually results in a poor functional outcome because of the importance of the anatomic relationship of the radius and ulna and the difficulty in obtaining and maintaining an acceptable reduction. Operative treatment thus represents the rule rather than exception in the treatment of forearm shaft fractures. The purpose of operative treatment is to achieve anatomic reduction and obtain stable fixation to allow early range of motion while healing occurs. Although the Locking compression plate (LCP) represents the latest development in plating systems, its usage in fractures with simple configuration and its superiority over conventional plating system (LC-DCP) is yet to be proved.

Aims: To analyze and compare the outcomes of using the Locking compression plate(LCP) and Limited contact Dynamic compression plate(LC-DCP) for internal fixation in adult diaphyseal both bone forearm fractures in terms of fracture union and functional outcome.

Materials and Methods: In this non randomized controlled trial, closed transverse or short oblique fractures of the shaft of both bone of forearm without any comminution of age above 18 years were included. On admission simple sequential allocation was done to place the patients into two groups. Group 1 – Patient treated with LCP fixation. Group 2 – Patient treated with LC-DCP fixation. The patients were advised not to do any strenuous work for another 10 to 12 weeks post operatively. All the patients were followed up for a total of 12 months. Functional outcome were assessed by criteria of Anderson et al and Quick Dash score. Data in the study was analyzed by using the independent sample t-test and p-value less than 0.05 was considered statistically significant.

Results: Total of 50 patients were included, of which 31 were males and 19 females. The difference between results of LCP and LC DCP fixation was significant in terms of mean time to fracture union($p=0.001$), which showed a lower time to union in LC DCP fixation when used in the compression mode. However as per functional outcome, the difference in the two groups was statistically insignificant ($p=0.6$).

Conclusion: Both groups had 100% union rate without any failure. Overall result of our study did not demonstrate any clear superiority of either fixation method for the surgical management of both bone forearm fractures. The only disadvantage of LCP is being expensive than the LC DCP.

Key Word: Locking compression plate (LCP), Limited contact Dynamic compression plate (LC-DCP), Criteria of Anderson et al, Quick Dash score, Compression mode.

Date of Submission: 26-12-2019

Date of Acceptance: 10-01-2020

I. Introduction

The presence of proximal and distal radio ulnar joints in forearm allows pronation and supination and such movements are important to all of us in the usual activities of daily living. Therefore fracture involving the bones of the forearm present unique problems not encountered with fractures of other long bones and can therefore result in significant dysfunction if treated inadequately. Conservative treatment of displaced forearm shaft fractures usually result in a poor functional outcome because of the importance of the anatomic relationship of the radius and ulna and the difficulty in obtaining and maintaining an acceptable reduction. Operative treatment represents the rule rather than exception in the treatment of forearm shaft fractures. The purpose of operative treatment is to achieve anatomic reduction and obtain stable fixation to allow early range of motion while healing occurs.¹ Treatment by closed reduction and cast immobilization results in a poor functional outcome with unsatisfactory results reported in upto 92% of cases, usually caused by malunion,

non-union or synostosis.^{2,3,4} Thus the Limited contact-dynamic compression plates (LC DCP) were developed in 1991 by the AO/ASIF. The LC-DCP has groove within the under surface which leads to an improvement in the blood supply to the underlying plate bone segment and also allows for a small amount of callus formation as well as even distribution of stiffness along the plate, undercut plate holes allow extended tilting of plate screws, uniformly spaced as well as symmetrical plate holes and has an optimal screw effect.⁵ The LC DCP was claimed to reduce the bone plate contact by approximately 50%.^{6,7} The new Locking compression plate (LCP) with combination holes can also be used, depending on the fracture situation, either in a conventional technique (compression principle), bridging technique (internal fixator principle) or a combination technique (compression and bridging) principle. The LCP was released for clinical application in March 2000. Although the LCP represents the latest development in plating systems, its usage in fractures with simple configuration and its superiority over conventional plating system (LC-DCP) is yet to be proved.⁸ Therefore the present study was aimed to compare the effectiveness of LCP over LC DCP in simple both bone forearm fractures of adults in terms of fracture union and functional outcome.

II. Materials And Method

Study design: Non randomized controlled trail

Study Location: This was a tertiary care teaching hospital based study done in Department of Orthopaedics, Regional Institute of Medical Sciences, Imphal, Manipur, India.

Sample size: 50 patients.

Study duration: 2 years from September 2017 to August 2019

Subjects & selection method: Patients with both bone fracture forearm who attended OPD and emergency department of Orthopaedics, RIMS Hospital during the study period. Simple sequential allocation was done to place the patients into two groups. The first patient was assigned to the LCP group, second patient was assigned LC DCP group and this sequence was continued throughout the study. Group 1 – Patient with diaphyseal both bone fracture and LCP fixation. Group 2 – Patient with diaphyseal both bone fracture and LC-DCP fixation.

Inclusion criteria:

1. Closed or type I open simple, transverse or short oblique fractures of the shaft of both bone of forearm without any comminution.
2. Age above 18 years.
3. Those who were willing to take part in the study.
4. Patients fit for surgery.

Exclusion criteria:

1. Type II or higher open fractures of the both bone forearm.
2. Loss to follow up
3. Poly trauma patients with neurovascular deficits.
4. Pathological fractures.

Operative methodology: The choice of anaesthesia was left to the anaesthesiologists. The patient was placed in supine position. Rubber tourniquet was used in the upper arm. The operating field was prepared with povidine iodine and carefully draped. The radius was exposed through the anterior Henry approach and the plate was applied on volar surface when the fracture was on the lower two third or through the dorsal Thompson approach and the plate was applied on the dorsal surface when the fracture was on upper third. The ulna was exposed through the postero medial subcutaneous surface between extensor carpi ulnaris and flexor carpi ulnaris and the plate was applied on the posterior surface since it is the tension side of ulna. Radius was fixed first followed by ulna. Non compression mode (bridging mode) was applied in LCP fixation and compression mode was applied in LC DCP fixation. Post operatively a posterior plaster slab was applied and the limb was elevated for 24 to 48 hours and the patient was instructed to move their fingers and elbow joint. Post operatively antibiotics and analgesics were continued till 7th post-operative day and sutures were removed on the 10th post-operative day. On the 14th post-operative day, the posterior slab was discarded, wound was inspected and flexion-extension exercises of wrist and elbow joints were restarted. Patients were called for check up on completion of 4 weeks and later every weekly till union occurred. After bony union they were called for follow up every monthly. The patients were advised not to do any strenuous work for another 10 to 12 weeks post operatively. All the patients were followed up for a total of 12 months. The criteria of Anderson et al was used for grading the functional outcome.⁹ Subjective assessment was done using the Quick DASH score.¹⁰

Statistical analysis: Statistical analysis was done using IBM SPSS software (version 21.0). The data were compared between the two groups under study by using the independent sample t-test. A p-value less than 0.05 was considered statistically significant.

Fig 1: Showing full range of movements of forearm in LCP group at 12 months follow up

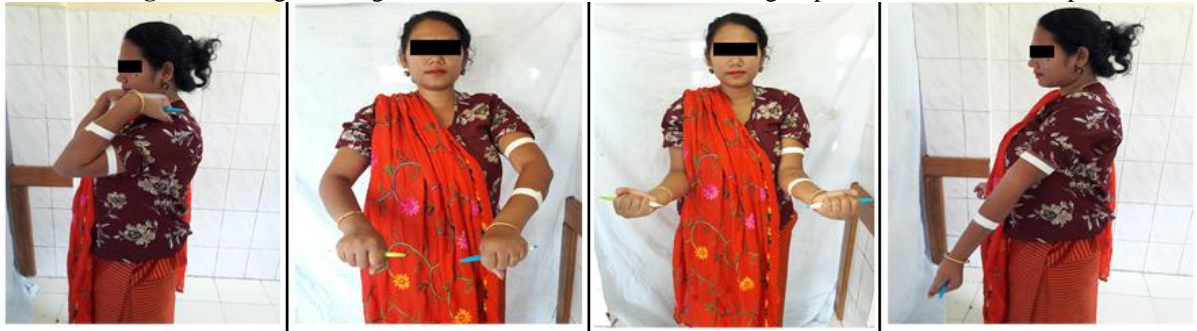

Fig 2: Showing full range of movements of forearm in LC DCP group at 12 months follow up

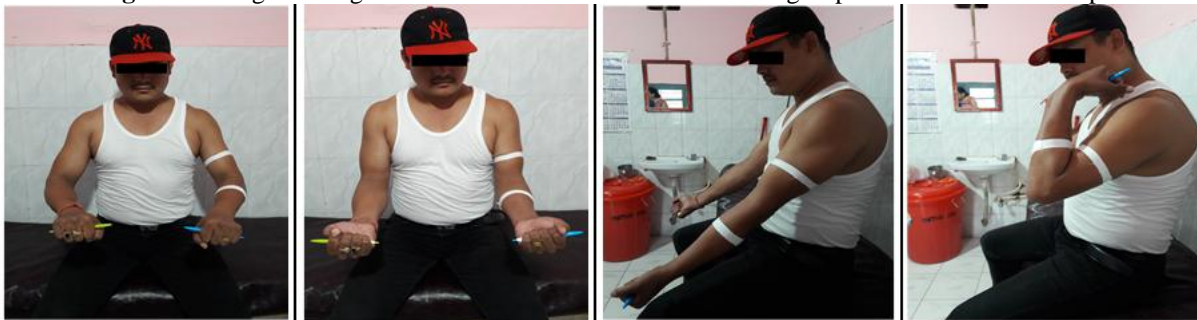

Fig 3: Showing post-operative X-Ray(LCP)

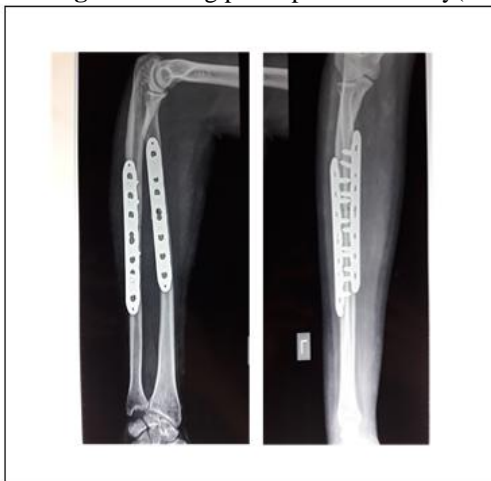
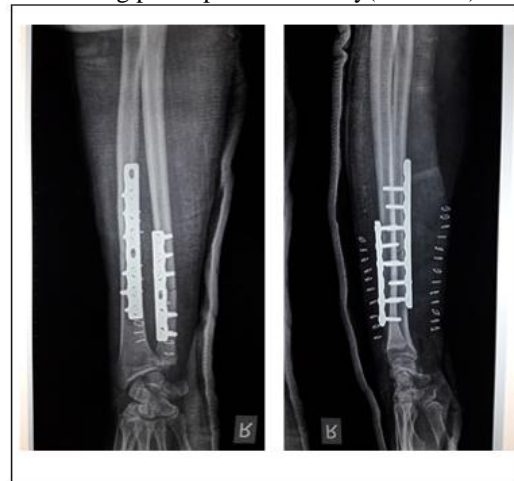
Fig 4: Showing post-operative X-Ray(LC DCP)



III. Results

The overall mean age for all patients was 39.64years (SD± 12.14).There were total of 31 males (62%) and 19 females (38%) in the study. In the LCP group there were 14 males and 11 females, whereas in the LC DCP group there were 17 males and 8 females.In the LCP group right side was involved in 15 cases and left side involved in 10 cases, whereas in the LC DCP group the right side was involved in 17 cases and in 8 cases the left side was involved.In our study RTA was the most common cause of injury accounting for 28 cases (56%) followed by fall from height in 12 cases (24%), assault in 7 cases (14%) and sport related injury in 3 cases (6%).In the LCP group the mean time to surgery was 7.16 days (SD±2.21) while in LC DCP group it was 8.00 days (SD±3.16).The mean operating time in LCP group was 67.48 mins (SD±12.98), while in LC DCP group it was 73.68 min (SD±14.11). The difference between means of the two groups was insignificant (p=0.113).

In the LCP group the mean duration of fracture union was 16.88 weeks (SD±2.261), while in the LC DCP group it was 14.72 weeks (SD±1.969). The difference in means of the two groups was statistically significant (p=0.001).In the LCP group, excellent outcome was seen in 21 cases, satisfactory outcome in 3 cases and unsatisfactory outcome in 1 case. While in the LC DCP group excellent outcome was seen in 22 cases and satisfactory outcome in 3 cases. None had failure in both groups. The difference in the two groups was

statistically insignificant ($p=0.6$). The Quick Dash score at end of 12 months follow up was calculated. The score ranged from 0 to 34.1 in the LCP group with mean score of 15.83 ($SD\pm 8.54$). The score ranged from 0 to 29.5 in the LC DCP group with mean score of 14.82 ($SD\pm 7.31$). The difference in mean score in both the groups was insignificant ($p=0.65$).

Fig 5: Showing mean duration to fracture union in different groups

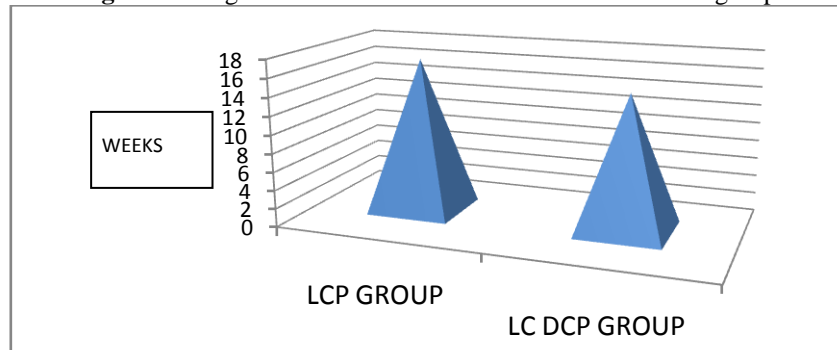
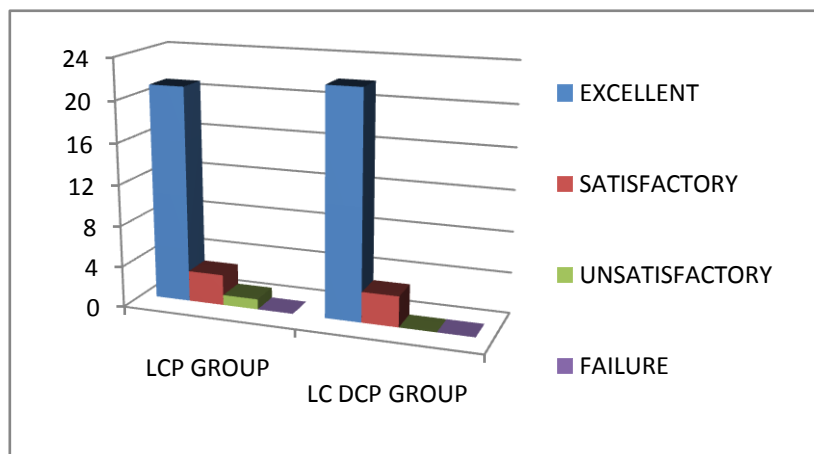


Fig 6: Showing distribution of functional outcome (as per criteria of Anderson) in different groups



IV. Discussion

Road traffic accidents are a common cause of forearm fractures in the adult population. Conservative treatment of displaced forearm shaft fractures usually results in a poor functional outcome because of importance of the anatomic relationship of radius and ulna. Thus open reduction and internal fixation with LCP or LC DCP is generally accepted for anatomic reconstruction in order to restore full functional recovery. In our comparative study, the difference between results of LCP and LC DCP fixation was significant in terms of mean time to fracture union, which showed a lower time to union in LC DCP fixation when used in the compression mode. However difference in overall functional outcome in both groups was not significant. Both groups had 100% union rate without any failure.

Overall result of our study did not demonstrate any clear superiority of either fixation method for the surgical management of both bone forearm fractures. The only disadvantage of LCP is being expensive than the LC DCP. We are of opinion that open reduction and internal fixation with LCP and LC DCP provides excellent results in terms of union rate and functional outcome.

V. Conclusion

With the available data our study points to the fact that LC DCP when used for simple or short oblique transverse fractures of both bone in compression mode showed lower time to fracture union as compared to LCP fixation. However the overall functional outcome was comparable in both groups and there was no statistical difference between the two groups as far as functional outcome was concerned.

References

- [1]. Streubel PN, Pesantez RF. Diaphyseal fractures of the Radius and Ulna. In: Court-Brown CM, Heckman JD, Tornetta III P, Ricci WM, editors. Rockwood and Green's fractures in adults Vol. I, 8th ed. Philadelphia: Wolter Kluwer;2015.p.1121-77.
- [2]. Charnley J. Closed treatment of common fractures. 4th ed. Edinburgh: Livingstone;1999.p.116.
- [3]. Hughston JC. Fractures of the distal radial shaft; mistakes in management. J Bone Joint Surg Am 1957 Apr;39-A(2):249-64.
- [4]. Knight RA, Purvis GD. Fractures of both bones of the forearm in adults. J Bone Joint Surg Am 1949 Oct;31A(4):755-64.
- [5]. Perren SM. The concept of biological plating using the Limited contact dynamic compression plate (LC-DCP).Scientific background, design and application. Injury 1991;22(1):1-41.
- [6]. Leung F, Chow SP: A Prospective randomized trial comparing the limited contact dynamic compression plate with the point contact fixation for forearm fractures. J Bone Joint Surg Am 2003 Dec;85(12):2343-8.
- [7]. Egol KA, Kubiak EN, Fulkerson E, Kummer FJ, Kowal KJ. Biomechanics of locked plates and screws. J Orthop Trauma 2004 Sep;18(8):488-93.
- [8]. Sommer C, Gautier E, Muller M, Helfet DL, Wagner M. First clinical results of the locking compression plate (LCP). Injury 2003 Nov;34(2):43-54.
- [9]. Anderson LD, Sisk D, Tooms RE, Park WI III. Compression plate fixation in acute diaphyseal fractures of the radius and ulna. J Bone Joint Surg Am 1975 Apr;57(3):287-97.
- [10]. Gummesson C, Ward MM, Atroshi I. The shortened disabilities of the arm, shoulder and hand questionnaire (Quick DASH):validity and reliability based on responses within the full length DASH. BMC MusculoskeletDisord 2006 May;7:44.

Dr.Soumendu Nath.et.al. "Stabilization of Diaphyseal fractures of both bone forearm with Limited Contact Dynamic Compression plate vs Locking Compression plate: Comparison of clinical outcomes." *IOSR Journal of Dental and Medical Sciences (IOSR-JDMS)*, 19(1), 2020, pp. 37-41.