

Acute Superior Mesenteric Vein Thrombosis Associated With Hormonal Contraceptive Use: A Case Report And Brief Review Of Literature.

Sharad Jain, Ratendra singh

Department of general surgery, R.N.T. Medical College, Udaipur, Rajasthan, India

Abstract: Abdominal pain is a common occurrence and may vary from subtle pain to very agonizing pain due to variety of causes, some of which may be life threatening. Here in this case report, we report a case of abdominal pain in a young otherwise healthy lady, with no co-morbid association, non smoker, non alcoholic. Her pain rapidly increased with associated symptoms leading to diagnosis of peritonitis and only significant factor found was that patient was on oral contraceptive pills from last 4 years. Later investigations and imaging techniques revealed SUPERIOR MESENTERIC VEIN thrombosis for which available tests were done and patient was put on anticoagulants, but her general condition rapidly deteriorated not giving a chance for exploration and finally patient collapsed despite all efforts.

Take home message and lesson is that oral contraceptive pills cannot be taken casually. Especially now with the help of internet, more and more patients take oral contraceptive pills without consultation with their doctors. A casual fun seeking approach which may prove to be life threatening. Oral contraceptive pills are also called as combined oral contraceptives pills because it contains both estrogen and progesterone and depending on type of progesterone, they are classified as first, second, third and fourth generation. As of today incidence of thrombosis is least with second generation oral contraceptive pills.

Keywords: SMVT, OCP, Prothrombotic states, APS (antiphospholipid syndrome).

Date of Submission: 26-12-2019

Date of Acceptance: 10-01-2020

I. Introduction

Mesenteric venous thrombosis is one of the most intriguing surgical dilemma. Mesenteric vein thrombosis is not so rare as believed in the previous era because of lack of facilities for its diagnosis and it is a potentially lethal form of mesenteric ischemia. It was first described by Elliot in 1895 as “**thrombosis of the porto-mesenteric venous system**” which disallowed venous drainage from the gut leading to bowel infarction. This entity is also said to be initially identified by Warren and Ebeahard in 1935. In other words SUPERIOR MESENTERIC VEIN thrombosis was recognized as a cause of intestinal gangrene more than a century ago by Elliot but Warren and Ebeahard were the first to characterize SUPERIOR MESENTERIC VEIN thrombosis as a cause of intestinal infarction distinct from mesenteric arterial occlusion and SUPERIOR MESENTERIC VEIN Thrombosis accounts for 5 to 15% of all mesenteric ischemic events.

The venae rectae forming a venous arcade drains the small bowel and proximal colon through the ilio-colic, middle colic and right colic veins to form superior mesenteric vein. The superior mesenteric vein and the splenic vein join and continue to the liver as portal vein. (fig.1)

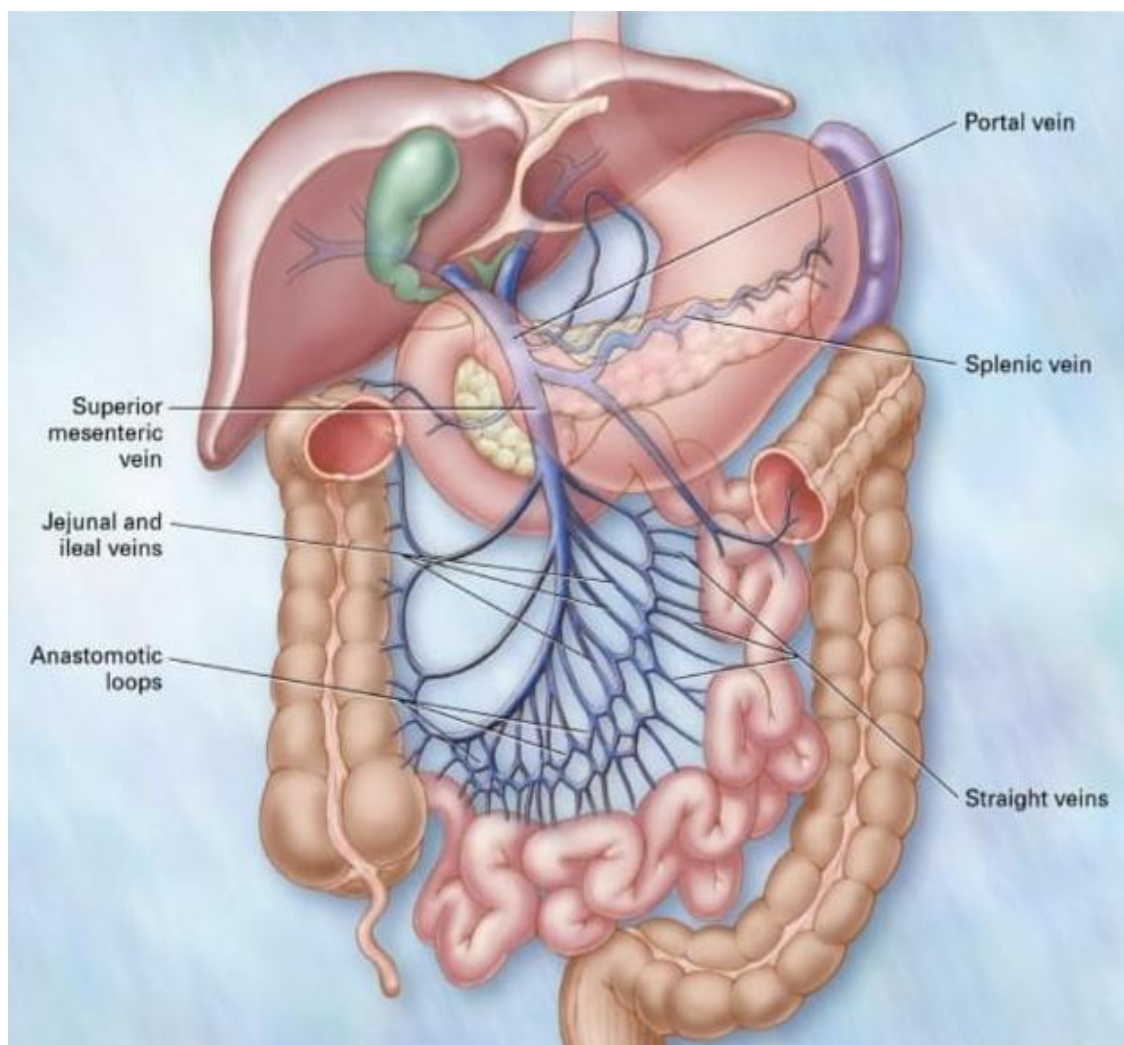


FIG.-1

Still some believe superior mesenteric vein thrombosis comes in the category of rarest of rare abdominal emergencies, therefore, rarely diagnosed early in patients admitted with provisional diagnosis of acute abdomen from the casualty emergency room. However, now with the advantage of USGM and CT scan facility commonly available, these cases are diagnosed much earlier than before.

II. Case Report

A 30 year old about 100kg female was admitted in the casualty room on 09/01/2019 at 08:34AM with complaints of pain abdomen and vomiting from last 3 days. Patient was alright till 06/01/2019 evening when she suddenly started complaining of generalized pain abdomen, severe in intensity, non radiating, non referring, with no aggravating and relieving factors. She also gave history of 3-4 episodes of vomiting per day which became blackish in colour from 07/01/2019. However it was non projectile and non-foul smelling. She did not pass flatus, motion after the beginning of pain. Her past, personal(non-smoker, non-alcoholic), family history were non contributing, her menstrual history was also regular, menstrual period moderate flow and Gravida-2Living-2. Both normal delivery, younger child being around 5 years of age and the patient was on oral contraceptives containing levonorgestrel and ethinyl estradiol from last 5 years.

On examination, her general condition was poor. However, she was conscious, oriented, obese, intelligent and could not attribute her pain to any factor like over eating, change in diet, trauma etc. Pulse was 112/min, BP was 146/90mm Hg, as patient was referred from elsewhere. She had a Levin's tube in with suction being 100cc on that day, blackish in color, with urine output (with Foley's indwelling catheter in-situ) being 1300cc on that day.

Local Examination. Abdomen was soft with generalized tenderness, guarding but no rigidity and distension, no organomegaly, no scar mark or dilated veins over abdomen.

Per-rectal examination. Rectum was loaded with hard fecal matter which was digitally evacuated with blood stain on finger.

Other systems CVS, CNS, Respiratory system did not reveal any abnormality.

Patient had USG of abdomen and pelvis dated 07/01/2019 with impression of diffuse and marked hypochoic circumferential wall thickening of small bowel loops.

? vascular insult

? infective

? inflammatory etiology along with presence of mild ascites and fatty liver.

Associated sonography films documented superior mesenteric vein thrombosis.

A provisional and tentative diagnosis of **Superior Mesenteric Vein Thrombosis** was made and treatment started.

Patient was immediately shifted to surgical ICU without wasting a minute and started on:

1. IV Fluids
2. Ryle's Tube
3. Broad spectrum antibiotics
4. LMWH 0.6 units S.C. TID
5. Oxygen and supporting treatment.

However, her general condition rapidly deteriorated which excluded any kind of surgical intervention. She wasn't given anything by mouth, her PT-INR on 11/01/2019 was 1.35 and aPTT test time was 33.00 seconds.

On 11/01/2019 Ryle's tube aspiration for occult blood: positive.

CECT abdomen dated 10/01/2019:

- non-enhancing filling defect in SUPERIOR MESENTERIC VEIN extending up to the confluence of portal vein suggestive of **Superior Mesenteric Vein Thrombosis**.
- Moderate hepatomegaly
- Mild ascites with diffused mesenteric fat stranding

ETIOLOGY of MESENTERIC VEIN THROMBOSIS.

Mesenteric vein thrombosis is classified on the basis of etiological factors as:

1. Primary
2. Secondary: when etiological factor is obvious, patients are said to have secondary mesenteric venous thrombosis.

Causes of Mesenteric Vein Thrombosis (Table 1.)

Broadly classified into two types:

A. Prothrombotic States

B. Others

-Hematological

- Inflammatory

- Post operative

- Miscellaneous

- **Prothrombotic States**

1. Antithrombin III deficiency
2. Protein C deficiency
3. Protein S deficiency
4. Factor V Leiden
5. G 20 210 A mutation in prothrombin gene
6. Anti phospholipid antibodies
7. Hyper homocysteinemia
8. Oral contraceptive use*
9. Pregnancy
10. Neoplasm*

- **Hematological Disorders**

1. Polycythemia vera*

2. Essential thrombocytopenia*
3. Paroxysmal nocturnal hemoglobinuria*

- **Inflammatory Diseases**

1. Pancreatitis*
2. Peritonitis and intrabdominal sepsis*
3. Inflammatory bowel disease
4. Diverticulitis

- **Post Operative State**

1. Abdominal surgeries*
2. Splenectomy
3. Sclerotherapy for esophageal varices
4. Cirrhosis and portal hypertension

- **Miscellaneous Causes**

1. Blunt abdominal trauma
2. Decompression sickness

*** - factors among the more common causes of MVT**

Though initially most cases were identified as primary or idiopathic MVT, but now the proportion of patients with idiopathic MVT continue to decline as our ability to recognize hyper-coagulable states improved because of marked revolution in imaging techniques, biochemistry and genetic engineering. Currently etiological factors can be identified in about 3 quarters (75%) of patients, among which the Oral Contraceptive Pills(OCPs) account for 18% of the MVT episodes in young women – which probably was the factor in our case.

The clinical manifestation depends largely on the following factors:

- Extent of thrombus
 - Size of vessel(s) involved
 - Depth of bowel wall ischemia
- (a) When ischemia is restricted to mucosa, the manifestation consists of abdominal pain and diarrhea
 - (b) Transmural ischemia leads to necrosis with gastrointestinal bleeding, perforation and peritonitis.

The location of the thrombus may be determined on the basis of underlying cause. Thrombosis due to intrabdominal cause starts in larger vessels at the site of compression and then progresses peripherally to involve the small venous arcades and arcuate channels. In contrast, thrombosis due to underlying prothrombotic states, begins in the small vessels and progresses to involve the larger vessels, probably as occurred in our patient due to oral contraceptive use.

CLINICAL PRESENTATION:

MVT may be acute, sub-acute or chronic.

- **Acute:** Symptoms occur suddenly (as in this case)
- **Sub-acute:** Patient having abdominal pain for days or weeks without infarction
- **Chronic:** Portal vein thrombosis with portal hypertension and esophageal varices

75% of patients have symptoms for around 24 to 48 hours i.e. acute mid abdominal pain. Hematemesis, hematochezia are common or diarrhea may be present in some with positive occult blood in stool in 50% as in our case.

When we first saw our patient, the bowel infarction had been probably little deeper than mucosal or transmural, because she had generalized abdominal tenderness, guarding suggestive of the fact that bowel infarction had already occurred or was impending.

In patients with acute mesenteric vein thrombosis, hemodynamic instability can result from the collection of fluids within the bowel lumen or the abdominal cavity and systolic pressure of less than 90mm Hg denotes poor prognosis.

In short classification of mesenteric vein thrombosis can be done in three ways-

Table 1- A.) Prothrombotic state

B.)Others

Table 2- A.) Idiopathic or primary


B.) Secondary to hypercoagulable state

Table 3 Clinically as- A.) Acute
 B.) Subacute
 C.) Chronic

DIAGNOSIS:

A) Abdominal films may show findings specific for bowel ischemia in only 5%. Blunt, semi-opaque, indentation of the bowel lumen (thumb printing) is suggestive of mucosal edema, whereas gas in the wall of the bowel (Pneumatosis intestinalis) or free peritoneal air are suggestive of bowel infarction.

B) USG and CT are diagnostic in more than 90% cases. SUPERIOR MESENTERIC VEIN in USG (fig. 2) and in CT (fig. 3) is evident as central lucency in mesenteric vein. MRI also has excellent sensitivity and specificity for MSV. GI endoscopy is of limited value given the rarity of colonic or duodenal involvement. Therefore, as of today, USG and CT scan of abdomen are recommended as 1st line diagnostic tool for SUPERIOR MESENTERIC VEIN Thrombosis and may also define the extent of affected bowel.



Once the provisional diagnosis of MVT is confirmed by imaging techniques, comes the question of etiology as summarized in table 1 previously i.e.

- 1) Prothrombic states
- 2) Others

The great and eminent German physician Rudolf Virchow (1821-1902) described the factors responsible for or contributory to the process of thrombosis.

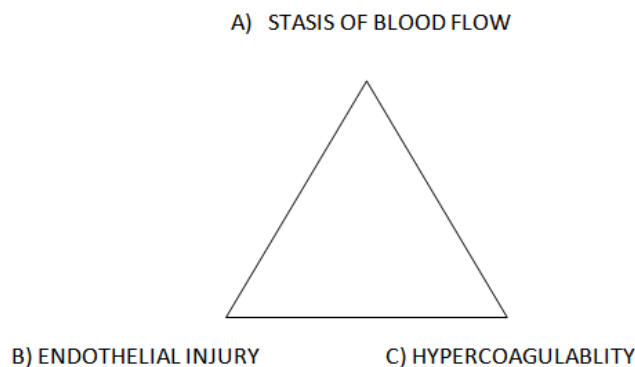


Table 4

| (A) Stasis of Blood flow | (B) Endothelial Injury | (C) Hypercoagulability (Prothrombotic States) |
|--------------------------|---|---|
| Long surgical procedures | Arising from shear-stress or hypertension | Hyperviscosity |
| Prolonged immobility | Bacteria | Coagulation factor V Leiden mutation |
| Long plane or car ride | Shards of foreign material (I.V. Canula) | Coagulation factor II G 202-10-A mutation in prothrombin gene |
| During hospitalization | Biomaterial of implants of medical devices | Deficiency of anti thrombin-III |
| Varicose vein | Membranes of activated platelets(in chronic inflammation) | Protein C or S deficiency |
| | Membranes of monocytes(in chronic | Severe trauma, burn, cancer |

| | | |
|--|---------------|----------------------------|
| | inflammation) | |
| | | Late delivery in pregnancy |
| | | Oral contraceptives |
| | | Smoking and cancer |
| | | Obesity |

All factors in column C can cause a situation called hypercoagulability (excessive early clotting of blood)

So to summarize from table 1 and table 4, we reach a conclusion of predisposing factors of thrombosis:

A) **Genetic blood clotting disorders:** clinically not demonstrable.

B) **Acquired factors:** clinically demonstrable

- Prolonged immobility
- Injury or surgery
- Pregnancy
- Oral contraceptives
- Obesity
- Smoking
- Cancer

As far as inherited or genetic Bleeding Disorders are concerned, prevalence of major states in different patient populations are :

Table 5

| Hypercoagulable State | Concerned population(%) |
|-----------------------------|-------------------------|
| Factor V Leiden | 03-07% |
| Prothrombin G 20210A | 01-03% |
| Antithrombin III deficiency | 0.02% |
| Protein C deficiency | 0.2-0.4% |
| Protein S deficiency | N/A |
| Hyperhomocysteinemia | 05-10% |
| Antiphospholipid Antibodies | 0-7% |

LAB EXAMINATION: Table-6

| SCREENING TESTS | CONFIRMATORY TESTS |
|--|--|
| APCR | Factor V Leiden PCR |
| Prothrombin G20210A mutation testing by PCR | Antigenic assay for Antithrombin III, Protein C or Protein S |
| Antithrombin III, Protein C and Protein S activity levels | Confirmatory tests for Las |
| Factor VIII activity level | |
| Screening tests for LAs (sensitive) aPTT, aPTT mixing studies, dilute viper venom time | |
| Anticardiolipin antibody testing by ELISA | |
| Fasting total plasma homocysteine level | |

1. PCR – Polymerase Chain Reaction
2. aPTT – activated Partial Thromboplastin Time
3. ELISA – Enzyme Linked Immunosorbent Assay
4. APCR – Activated Protein C Resistance
5. LA – Lupus Anticoagulants : these are antibodies directed against plasma proteins, which also bind to PL surface; they are usually of IgG, IgM types and frequently interact with standard PL dependent coagulation test.

A). The APL antibodies account for 65-70% of cases of thrombotic episode in women with venous thrombosis in less common site (eg: cerebral, portal, splenic, subclavian, superior mesenteric and other mesenteric veins). About 1/4th of thrombotic events occur during pregnancy and post partum period. These observations suggests that women with documented APS should avoid estrogen-progesterone combination oral contraceptives. Diagnosis of Antiphospholipid Antibody Syndrome(APS) requires at least one clinical and one laboratory criteria.

CLINICAL CRITERIA:

- (a) One or more episodes of venous-arterial and small vessel thrombosis
- (b) Complications of pregnancy:
 - i) one or more unexplained death of morphologically normal fetus after 10 weeks of gestation

- ii) one or more premature birth of morphologically normal fetus at or before 34 weeks of gestation
- iii) three or more unexplained consecutive spontaneous abortions before 10 weeks of gestation

APS: Antiphospholipid Antibody Syndrome

Lab criteria are:

1. CLS- anticardiolipin IgG or IgM antibodies present at moderate or high levels in the blood on two or more occasions atleast 6 weeks apart.
2. LA antibodies detected in the blood on two or more occasions atleast 6 weeks apart according to guidelines of the International Society of Thrombosis and Hemostasis.

B) Women with factor V Leiden mutation are also at increased risk for venous thrombosis complications associated with hormone replacement therapy and perhaps with tamoxifen and selective estrogen receptor modulators.

C) Protein C deficiency: one should consider prophylactic measures during period of increased thrombotic risk such as the peri-partum period, perioperative, or during period of prolonged immobilization. Also potential for increased risk of thrombosis during oral contraceptive therapy should be considerable. Screening of hypercoagulable state must be considered in recurrent fetal loss.

- DVT and/or Pulmonary embolism(PE) on birth
- contraceptive pill or hormone replacement
- while pregnant or post partum.

“See the most dangerous control pills”

Choice: levonorgesteral

Ethinyl estradiol – safest pill

MANAGEMENT:

Once MVT is confirmed or suspected, work up to diagnose the underlying etiology is indicated. Draw blood samples before initiation of anticoagulants, specially for diagnosis of prothrombotic states.

Goals of treatment are:

A) Re-canalization, prevention of propagation of thrombosis which otherwise can lead to worsening of intestinal ischemia.

B) Supportive treatment and bowel rest.

A)Anticoagulation with unfractionated or Low Molecular Weight Heparin(LMWH) should be initiated as soon as the diagnosis is made or suspected. Anticoagulation results in re-canalization in most of the patients if started early in the course of disease. If the patient survives or acute phase is over, anticoagulation should be maintained to prevent recurrence of thrombosis for 3 to 6 months, however lifelong anticoagulation should be maintained in patients with persistent hypercoagulable states i.e. genetic. This may be achieved with warfarin targeting an international normalized ration (INR) of 2-3 with frequent monitoring.

Note: a note should be made of interventional radiological treatment wherein Mesenteric vein is accessed via Femoral Vein or Trans-jugular route with injectable anticoagulant with good treatment response but with extreme expertise and very high risk of complications.

Supportive treatment is that of peritonitis.

III. Discussion

Virchow’s triad describes three broad category of factors that are thought to contribute to thrombosis:

- Hypercoagulability
- Hemodynamic changes (stasis, turbulence)
- Endothelial injury (dysfunction)

In centuries are born one God gifted person and German physician Rudolf Virchow (1821-1902) was one such gifted person. There is a historical dispute if these factors were ever suggested by Virchow as a triad, however that is not the concern of this article.

| VIRCHOW's | MODERN | NOTES |
|---|-------------------------------------|--|
| Phenomenon of Interrupted Blood Flow | Stasis | The first category i.e. alteration in normal blood flow, refers to several situations. Venous stasis because of: 1. Long surgical procedures 2. Prolonged immobility (while on plane, car ride or bed bound) 3. Varicose veins |
| Phenomenon associated with irritation of the vessels and its vicinity | Endothelial injury or vessel injury | This includes vessels piercing and damages arising from shear stress or hypertension. This category is ruled by "surface phenomenon" and contact with procoagulant surfaces such as: - Bacteria - Shards of foreign materials - Biomaterials of implants or medical devices - Membranes of activated platelets and monocytes in chronic inflammation |
| Phenomenon of blood coagulation | Hypercoagulability | This category has both: a. Genetic factors b. Acquired factors (already discussed) |

The clinical diagnosis of SUPERIOR MESENTERIC VEINTHROMBOSIS has evaded clinicians for decades; consequently, the true incidence of this condition is unknown.

The diagnosis is largely dependent upon the awareness of SUPERIOR MESENTERIC VEIN in acute abdomen which cannot be easily diagnosed with USG and CECT abdomen by even an experienced radiologist.

Risk factors for venous thrombosis include hypercoagulable states which may be genetic or acquired. Acquired causes can be attributed seeing the table, however if acquired cause is not responsible, then a thorough work up for **primary hypercoagulable state** is warranted.

Immediate treatment with anti-coagulants is the treatment of choice with supportive treatment for peritonitis along with broad spectrum antibiotics.

immediate laparotomy is indicated if the general condition of the patient permits and if there is suspicion of bowel ischemia or infarction by various investigations. Even if laparotomy is undertaken, the anticoagulants are carefully continued.

Reports of thromboembolic disease in patients taking oral contraceptives have become more frequent. Mayor Joseph M Ciretta et al in their article "MSV associated with Oral Contraceptives" report about a female taking tab of 1mg Norethindrone and 0.05mg of Mestranol (Ortho-Novum-1) cyclically for 4 months. Her condition worsened suddenly on 3rd post admission day almost as in our case. They undertook laparotomy and did resection anastomosis of the infarcted bowel. On 24th post operative day patient became dyspneic, tachypneic, diaphoretic and cyanotic with pulse rate of 160/min, B.P. of 60-70 mm Hg were recorded. Diagnosis of massive pulmonary embolism was confirmed by pulmonary angiography. Pulmonary embolectomy was performed but patient died 6 hours later. Post mortem examination disclosed two residual emboli in pulmonary arteries and scattered small peripheral clots. In the abdomen bilateral iliac vein thrombosis were found as well as occlusion of portal system by organizing thrombus, and pelvic abscess.

Millions of females today take oral contraceptives however exact relationship of birth control pills to MSV is still highly speculative.

In this patient also, no other predisposing factors could be related to MSV.

Alternatives to Surgery: Using a percutaneous transhepatic approach Yankes et al described successful recanalization of the superior mesenteric vein using a urokinase infusion and occlusion balloon. Also, Robin et al noted use of systemic IV infusion of recombinant tissue plasminogen activator to lyse a SUPERIOR MESENTERIC VEIN thrombus. Using a combination if Angiojet Amplatz thrombectomy and balloon angioplasty, they re-established the blood flow quickly without risking bowel ischemia. Branch of right portal vein was accessed with 22-gauge Chiba Needle by percutaneous transhepatic route and placed a sheath, using a 5 French glide JB1 catheter and steerable angled Terumo guide wire they accessed the distal SUPERIOR MESENTERIC VEIN. After crossing SUPERIOR MESENTERIC VEIN thrombus, a 6 frenchpediceangiojet thrombectomy device was used for thrombectomy.

In our patient the risk factor identified is hypercoagulability state secondary to intake of OCP. Combined OCP are well known risk factor for venous thromboembolism (VTE). A study from U.K. examining over 10000 cases of VTE reported an increased risk of VTE nearly three times when on current exposure to

OCP. The risk is higher for first generation progesterone containing OCP than those containing the second-generation progesterone. The number of cases of VTE per year per 10000 treated women was lowest for levonorgestrel when compared to desogestrel and cyproterone.

As we are aware that the VTE is dependent on the estrogen component, the newer generation progesterone exerts some protective effects. The mechanism responsible for the thromboembolic phenomenon in OCP users are not very well defined. However, there are several mechanisms which are postulated:

1. OCP may induce a prothrombotic state by acceleration of both the intrinsic as well as extrinsic pathways of coagulation cascade or by decreasing the Antithrombin III levels.
2. OCP may cause antifibrinolytic activity by reducing spontaneous fibrinolysis.
3. They may induce intimal hyperplasia.

NOTE:

- Norethisterone is the first active progestin used in OCP and classified as first-generation progestin.
- Norgestrel and levonorgestrel are 2nd generation progestins.
- While desogestrel, gestodene and norgestimate are the newer 3rd generation progestins.

On the basis of studies performed, risk of VTE is 3 times higher with second-generation pills and 6-7 times higher with third and fourth-generation pills. The investigators recommend the use of second-generation pills with lowest estrogen content as first choice OCP.

Oral contraceptive pills- The first generation of progestin includes

- Norethindrone
- Lynestrenol
- Ethinodiol diacetate and
- Norethisterone

The second generation includes-

- Levonorgestrol
- Norgestrol

The third generation includes-

- Desogestrel
- Gestodene and
- Norgestodene

Oral contraceptive pills or combined oral contraceptive pills often includes a combination of estrogen (usually ethinyl estradiol) and a progesterone (specifically a progestin) or there may be progestin only pill (POP).

Since oral contraceptive pills are available in UK since early 1960 undergone through several incarnations. These are referred to as 'generation' of which there are four generations. Main difference between the four types of progesterone which is used, while the estrogen used is either ethinyl estradiol or estradiol.

Generally second generation pills considered to be safest. Third and fourth generation pills have been developed to address side effects because of second generation pills.

Second generation pill (1970) contains much lower amount of hormones and they contain progestin such as levonorgestrel and norethisterone.

Third generation pill (1980) use progestins such as norgestimate, desogestrel, gestodene and cyproterone acetate.

Fourth generation pill contains progestins such as drospirenone and dienogest.

Throughout the generations, the oral contraceptive pills has been linked to an increased chance of developing blood clots; but in recent years there have been various media stories suggesting that newer forms of oral contraceptive pills are more dangerous than their second generation counterparts, it is therefore, as of today, second generation pills such as MICROGYNON, LOGYNON AND LOESTRIN are considered best from the point of view of developing blood clots.

Bibliography:

- [1]. Acute SUPERIOR MESENTERIC VEIN thrombosis in patient with primary Antiphospholipid Antibody Syndrome: a case report and brief review of literature. Steve Egreonure, J Gastrointestine Digestive System 5:360. Doi: 10.4172/2161-069X.1000360
- [2]. Mesenteric Venous Thrombosis: Still a lethal disease in 1905. Robert Y Rhee et. al. 1994 Society for Vascular Surgery and International Society for Cardio-Vascular Surgery. North American Chapter. Published by Elsevier.
- [3]. Mesenteric Venous Thrombosis. Robert Y. Rhee et. al SCNA Vol 77 Issue 2, 1st April 1997. Pg 327-338.
- [4]. Mesenteric Venous Thrombosis: Shaji Kumar MD et. al Current concepts. NEJMAC Password 1955rj.
- [5]. MVT BestharHmoud, Ashwani K et. al Journal of Clinical and Experimental Hematology.

- [6]. Mesenteric and Portal Vein Thrombosis: Treated with early initiation of anticoagulants. *European Journal of Vascular and Endovascular Surgery*. Vol 29, Issue 2, Feb 2005, Pages 204-208. J.H. John, D.I. Kim.
- [7]. MSV associated with oral contraceptives – Major Joseph M et. al *Gastroenterology* 58(5) 713-716. 1970
- [8]. Treatment of Acute SUPERIOR MESENTERIC VEIN Thrombosis with Percutaneous Techniques. Michael F. Goldberg and Hyun S. Kim. *American Journal of Roentgenology* Vol 181; Issue 5. Page 1305-1307.
- [9]. Mesenteric Venous Thrombosis: Diagnosis and Non Invasive Imaging. Michelle S. Bradgury et. al. *Radiographics* Vol 22. No.3. Secondary Hypercoagulable States : A concise review. Mark J Prosciak, Stanislaw P Stawicki.
- [10]. *International Journal of Academic Medicine*, April 2017.

Sharad Jain.et.al. “Acute Superior Mesentric Vein Thrombosis Associated With Hormonal Contraceptive Use: A Case Report And Brief Review Of Literature.”*IOSR Journal of Dental and Medical Sciences (IOSR-JDMS)*, 19(1), 2020, pp. 76-85.