

Closed Reduction of Displaced Colles' Fracture Using Hematoma Block

Dr. Raja Nag¹, Dr. S.N. Chishti², Dr. Kamlesh Kumar Sharma¹,
Dr. Soumendu Nath¹, Dr. Suraj Kumar¹.

1. Post Graduate trainee, Orthopaedics Department, RIMS Imphal / Manipur University, India

2. Professor and Head, Orthopaedics Department, RIMS Imphal / Manipur University, India

Abstract:

Background: One of the most common fractures we encounter in our day to day practice is Colles' fracture. Closed reduction of these fractures is one of the most important method of management. The objective of the study is to determine the pain lowering effect of hematoma block for closed reduction of these fractures.

Materials and Methods: This was a quasi experimental study conducted at department of orthopaedics, RIMS, Imphal from September 2017 to August 2019. All patients with distal radius fracture who attended OPD and casualty were included in this study. Open fractures, intra-articular fractures and comminuted fractures requiring reduction with the use of other forms of anaesthesia were excluded from the study. Pain score was measured with Visual Analogue Scale at 1 minute, 2 minutes, 3 minutes, 4 minutes and 5 minutes after hematoma block. Chi-Square test was used to see the significant difference.

Results: Out of 100 patients with Colles' fractures, males were 44(44%) and females were 56(56%). Highest numbers of patients were of the age group of 51-70 years. Frykman type 1 fracture was more common (67%) than Frykman type 2 (33%). Right side was involved in 54 patients (54%) and left side in 46 patients (46%). There was a significant difference in the pain sensation after giving hematoma block with 2% lignocaine solution assessed with VAS Score which ranged from no pain in 52% patients when reduction was performed 5 minutes after giving the block to worst pain in 7% of patients when reduction was carried out 1 minute after giving the block which was statistically significant having p value of 0.000.

Conclusion: Hematoma block provides significant pain lowering effect when it is used for reducing displaced Colles' fracture with excellent clinico-radiographic result making it a procedure of choice in many health care set ups.

Key Word: Colles' fracture; Distal radius; Intra-articular; Hematoma; Lignocaine; Pain measurement; Visual Analogue Scale.

Date of Submission: 26-12-2019

Date of Acceptance: 10-01-2020

I. Introduction

Colles' fracture is the most common fracture treated; more than one sixth of all fractures that we treat are Colles' fracture, that means 10% to 25% of all fractures seen at an emergency department and constitutes 17% of all the fractures and 75% of all forearm fractures.¹ The growth of the elderly population and a rise in the number of active elderly are directly responsible for the increase seen in this age group.² In children and adolescent the distal radius fractures are the most common physeal injuries and 46% of physeal injuries occur in distal radius.³ Management of these fractures has remained a controversial issue.⁴ They are often treated with closed reduction and immobilization. Adequate anesthesia is of paramount importance for closed reduction of Colles' fracture. Literature shows that hematoma block is a safe method to obtain analgesia for closed reduction of fractures and is almost equally beneficial in term of efficacy to intravenous propofol.⁵ Now-a-days an increasingly large number of minor procedures are performed under local anaesthesia in clinical settings outside operation theatre.⁶ In case of Colles' fracture, there is a marked trend away from general anaesthesia in the favor of local anaesthesia.⁷ Hematoma block is a simple form of local anaesthesia which can be performed by Accident and Emergency doctors. It is a technique of injecting local anaesthetic at the site of fracture directly into the hematoma for closed reduction.⁸ It is given in the most recent cases of these fractures, not more than 24 hours after the injury.

The present study is therefore aimed to show the pain lowering property of the hematoma block for closed reduction of displaced Colles' fracture in emergency care settings.

II. Material And Methods

This quasi experimental study was carried out on patients of Department of Orthopaedics at RIMS ,Imphal from September 2017 to August 2019. A total 100 patients were included in the study.

Study Design: Quasi – experimental study.

Study Location: This was a tertiary care teaching hospital based study done in Department of Orthopaedics at RIMS , Imphal.

Study Duration: September 2017 to August 2019.

Sample size: 80 patients.

Sample size calculation:

Sample size was calculated using the following formula:

$$N = \frac{(U + V)^2 (S_1^2 + S_2^2)}{(M_1 - M_2)^2}$$

Where,

N= Sample size

U = α value at 95% Confidence interval - 1.96.

V = Z value at 80% power – 0.84.

S₁= Standard deviation of pain score at 1 minute – 1.68(Value taken from study conducted by Afsar SS et al⁵).

S₂=Standard deviation of pain score at 2 minute – 1.58(Value taken from study conducted by Afsar SS et al⁵).

M₁=Meanscore at 1 minute – 5.70(Value taken from study conducted by Afsar SS et al⁵)

M₂=Mean score at 2 minute – 4.98(Value taken from study conducted by Afsar SS et al⁵)

Therefore, N = 79.5 ~ 80.

Though my sample size was 80, I have included 100 patients in my study as Colles' fracture is very common in this locality and large number of patients come to the OPD with this fracture.

Subjects and selection method:

Patients who were between 20 – 80 years of age having Colles' fracture within last 24 hours presenting to the OPD and Emergency department of Orthopaedics and who gave consent and fulfilled the inclusion criteria were included in the study till sample size is achieved.

Inclusion Criteria:

- 1) Those patients who gave consent for this study.
- 2) Adult male or female patients in the age range of 20 -80 years.
- 3) Displaced Colles' fracture requiring manipulation: > 15⁰ dorsal angulation and > 2mm radial shortening.
- 4) Only extra-articular fractures.
- 5) Fractures within 24 hours of duration.

Exclusion Criteria:

- 1) Open fractures and comminuted fractures, requiring external fixation or K- wire fixation for which hematoma block is not suitable.
- 2) Patients with systemic disorders like thyroid disease, hypertension, cardiovascular diseases or diabetes mellitus.

Procedure methodology:

On receiving the patients in the OPD or Emergency department, an informed consent document was taken. A thorough general assessment of the patient was conducted and pulse, blood pressure and body weight recorded. Proper cardiological assessment was done to prevent any toxicity related to lignocaine. The duration which was lapsed since time of injury was recorded. Radiological assessment was done in every case. A postero-anterior and lateral view of the wrist was obtained. In Colles' fracture, there is dorsal angulation of the distal radial fragment, decreased radial inclination and shortening of the length of the radius. On pre-reduction radiographs, the value of these parameters was recorded.

The patient was positioned supine on the table with one bottle of normal saline solution was fixed to the normal hand. The fractured hand was thoroughly painted with 10% povidone iodine solution from elbow to tip of fingers and was properly draped. 2% plain lignocaine solution was used in the dose of 0.2 ml/kg body weight for hematoma block in all cases. One test dose of lignocaine solution was injected intra dermally to check for any allergic reactions. After 5 minutes of giving the test dose the local anaesthetic solution was infiltrated under aseptic conditions. About four -fifth of the total dose was given dorsally into the fracture hematoma. Five minutes after the injection of the solution manipulation was carried out. With counter traction on the arm above the elbow, the hand was pulled to disimpact the fracture fragments. The thenar eminence of

one hand of the manipulator was placed dorsally over the lower radius at the wrist and the other hand was placed on the lower forearm in line with the radial shaft. The lower radial fragments were then manipulated in a volar and medial direction and was also pronated to overcome supination deformity. A plaster of paris back slab was applied to stabilize the fracture in reduced position. Blood pressure and pulse of the patients was closely monitored in order to diagnose any cardiovascular complications of local anaesthesia. Post reduction radiographs of the wrist was taken to assess the accuracy of reduction. Acceptable X- Ray parameters for a healed Colles' fracture- radial length less the 2mm of contra lateral wrist, palmer tilt to dorsal tilt 11 to 20 degrees, intra articular step off < 1 mm, restoration of radial tilt to 22 degrees.

The limb was kept elevated at all times and active finger movements were encouraged. The patient was administered a questionnaire by the attending nurse. It was written both in English as well as Manipuri and patient completed this questionnaire in the language, he/she knows better. It was about the severity of pain perception during the procedure and whether the patient was satisfied with the level of analgesia provided by anaesthetic technique. Illiterate patients got help from nurse or the doctor to tick mark the questionnaire according to his feeling about the procedure. A visual analogue scale (VAS) was also included in the questionnaire for better assessment of pain perception by the patient.

Statistical Analysis:

- Data was checked for completeness and consistency.
- Data was entered and analyzed using SPSS V.21 for window (IBMInc.)
- Descriptive data was presented using percentage and proportions for variables like age, sexetc.
- Pain perception with respect to time of infiltration of anaesthesia was calculated using chi square test.
- A p-value of less than 0.05 was considered to be statistically significant.

III. Results

100 patients with Colles' fracture who met the inclusion criteria were included in the study. The study showed patients of 61 to 70 years of age comprised the highest number of patients. Females constituted most of the study population (56%). Frykman Type I extra articular fracture was more common (67%) than Frykman Type II extra articular fracture (33%). There was a highly significant difference in the pain sensation after giving local hematoma block with 2% lignocaine injection assessed with VAS score which ranged from no pain in 52% of patients when reduction was performed 5 minutes after giving the block to worst pain in 7% of patients when reduction was carried out 1 min after giving the block. Duration of fracture union was within 4 to 6 weeks with no significant complications.

- **Age group distribution:** The age group of 61 to 70 years comprised the highest number of patients (30).

Table No 1: Showing age distribution of patients.

Age in years	Frequency	Percent
20-30	8	8
31-40	9	9
41-50	13	13
51-60	20	20
61-70	30	30
71-80	20	20

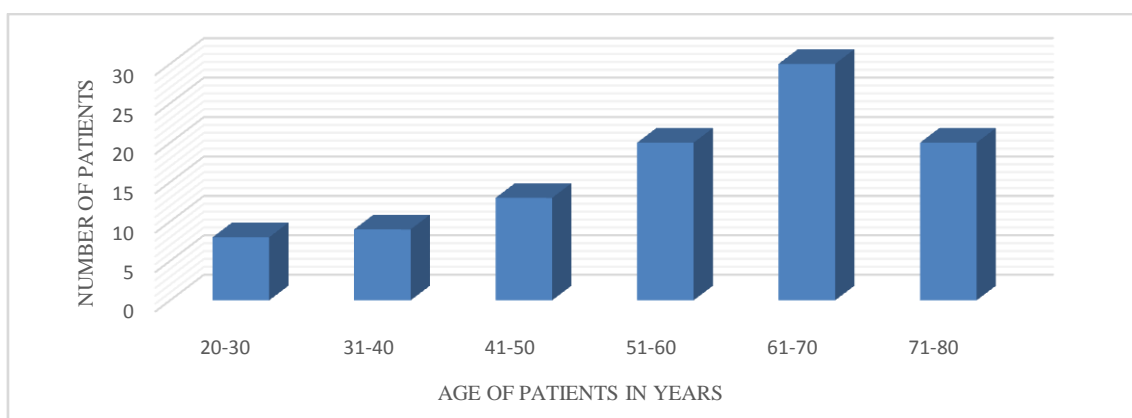


Figure 1: Showing distribution of age in different age group

- **Type of fracture according to Frykman classification :**Fractures classified according to Frykman classification showed 67 cases (67%) with Type I and 33 cases (33%) with Type II extra-articular fractures.

Table No 2: Showing distribution of fracture according to Frykman classification

Type	Frequency	Percent
I	67	67.0
II	33	33.0

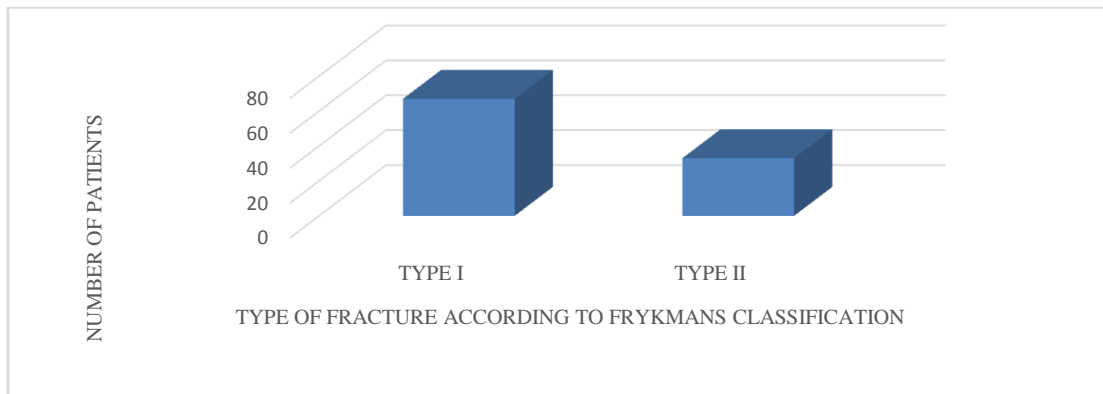


Figure2: Showing distribution of fracture according to Frykman classification.

- **Duration of fracture union (Radiological):** Most of the fractures showed radiological union at 6 weeks comprising of maximum number of patients 41 (41%) followed by union at 4 weeks comprising 35 (35%) of patients.

Table No 3: Showing duration of fracture union in different age groups

Age	4 weeks	5 weeks	6 weeks	7 weeks	8 weeks	Total
20-30 years	2	2	4	0	0	8
31-40 years	2	1	5	1	0	9
41-50 years	2	5	6	0	0	13
51-60 years	9	4	5	0	2	20
61-70 years	12	5	12	1	0	30
71-80 years	8	3	9	0	0	20
Total	35	20	41	2	2	

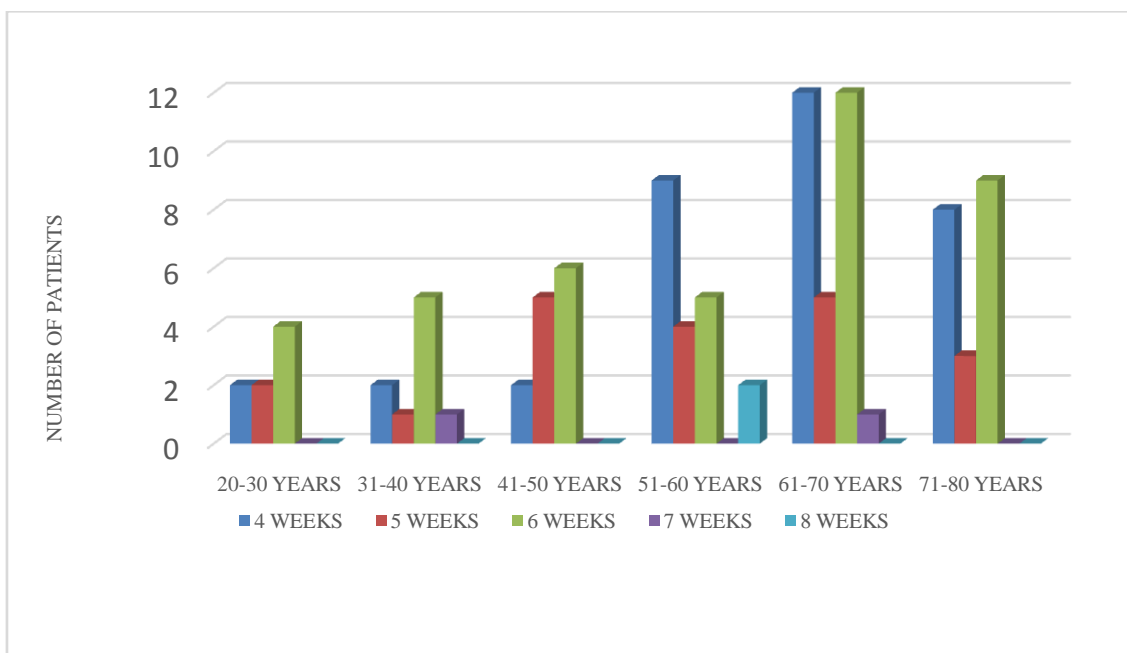


Figure 3: Showing duration of fracture union in different age groups

- **Time to reach hospital after sustaining the injury:**After sustaining the injury 43 patients (43%) reached the hospital in less than 3 hours which is the maximum number followed by 19 patients (19%) within 3 to 6 hours , 13 patients (13%) within 7 to 9 hours , 13 patients (13%) within 10 to 12 hours , 8 patients (8%) within 13 to 15 hours and 4 patients (4%) more than 15 hours after sustaining the injury.

Table No 4 : Table showing time to reach hospital after sustaining the injury

Time	Frequency	Percent
< 3 hours	43	43.0
3-6 hours	19	19.0
7-9 hours	13	13.0
10-12 hours	13	13.0
13-15 hours	8	8.0
>15 hours	4	4.0
Total	100	100.0

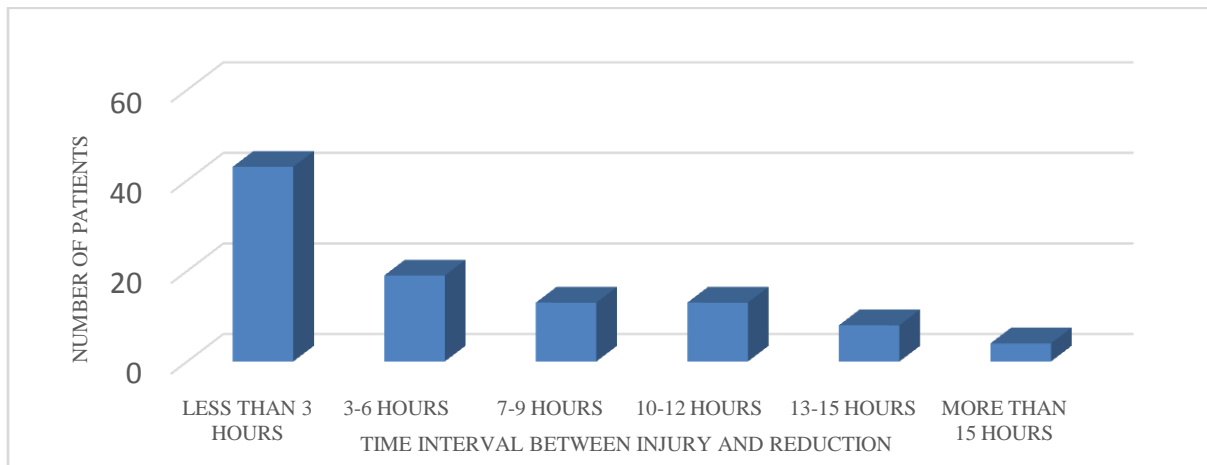


Figure 4: Showing time interval between injury and reduction

- **Pain sensation in relation to time of infiltration of local anaesthesia using Visual Analogue Scale (VAS) score:** Pain sensation after infiltration of hematoma block was scored according to the Visual Analogue Scale which showed that 52 patients (52%) experienced complete anaesthesia when reduction was done 5 mins after the infiltration of local anaesthetic agent (2% lignocaine injection) and 7 patients(7%) experienced worst pain when reduction was done within 1 min after infiltration of local anaesthesia which has a significant p value of .000.

Table No 5: Table showing pain sensation in relation to time (in minutes) of infiltration of local anaesthesia using Visual Analogue Scale (VAS) score.

Time	No hurt	Hurts little bit	Hurts little more	Hurts even more	Hurts a whole lot	Hurts worst
1 Min	0	0	0	0	2	7
2 Min	0	0	1	1	3	1
3 Min	0	1	7	7	0	0
4 Min	7	9	0	0	0	0
5 Min	52	0	0	1	1	0

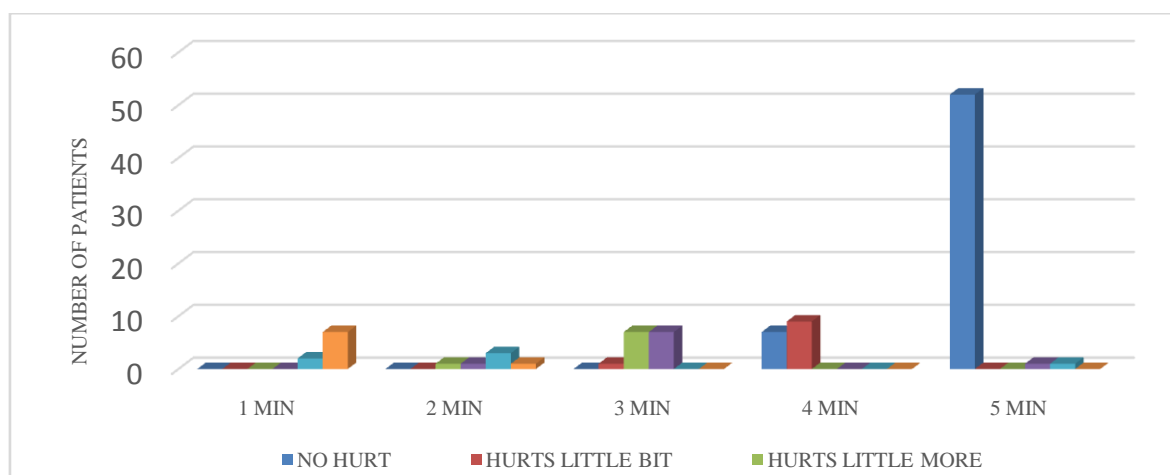


Figure 5: Showing pain sensation in relation to time (in minutes) of infiltration of local anaesthesia using Visual Analogue Scale (VAS) score.

IV. Discussion

For a fracture reduction one of the most important necessities is adequate anaesthesia or adequate pain relief. This is also true for proper reduction of Colles' fracture. Many different types of anaesthesia are used in day to day practice for manipulative reduction of this fracture having its own advantages and disadvantages. In case of closed reduction of Colles' fracture there is an increasing trend for using local hematoma, block which can prevent complications related to general anaesthesia.

This study was designed to determine the pain lowering effect of hematoma block for closed reduction of Colles' fracture. The conclusion has been drawn by studying 100 patients over a time period of 2 years who met the inclusion criteria. The reason behind adopting this technique of infiltration anaesthesia for reduction of Colles' fracture is that it is simple as it can be used in emergency set up, safe relative to conventional general anaesthesia and of course cost effective.

In our study, the age group of 61 to 70 years (30%) comprised the highest number of patients. Afsar SS et al⁵ conducted a study which showed that 56.2% of study population was more than 50 years of age. Patients of 5th and 6th decade were more prone to fracture as they are the working population of the society and involved in maximum household and outdoor activities.

In our study female patients constituted majority portion undergoing casting for Colles' fracture (56%). Afsar SS et al⁵ in their study reported that 58.3% patients undergoing hematoma block for Colles' fracture reduction were female. Ullah I et al⁹ also reported in their study that 57.1% of study population were female. This is mostly because of increased incidence of osteoporosis in elderly females which makes them vulnerable to fracture.

It was observed in our study that 54% of patients sustained injury on the right side. Afsar SS et al⁵ also reported that in their study 52.1% patients had right sided Colles' fracture and 47.9% patients had left sided Colles' fracture.

In our study fall on outstretched hand was the most common mode of injury accounting for highest number of Colles' fracture (47%) which is comparable with study conducted by Afsar SS et al⁵ which was 50%.

In our study we have included only the extra articular distal radius fractures (Frykman Type I and II) which is comparable to study conducted by Ullah I et al⁹ where also only extra articular fractures were included.

Regarding associated injuries, head injury was the most commonly encountered 9% of patients followed by patients sustaining chest injury which was 8%.

In a study conducted by Furia JP et al¹⁰ the hematoma block was compared with IV sedation for reduction of Colles' fracture. But IV sedation can cause drowsiness in the patients even after several hours of reduction and the patient needs to be hospitalized for a certain period or to be assisted by a family member or attendant to go home. But hematoma block can safely be performed by an emergency or OPD doctor and patients can be discharged without any fear of complication like drowsiness.

In our study, there was no immediate complication during the process of reduction. Late complications encountered were joint stiffness in 7% of patients which was managed by physiotherapy consisting of active range of motion exercises. 2 cases of carpal tunnel syndrome and reflex sympathetic dystrophy were managed by active physiotherapy and steroid injections. 1 patient with infection was treated with IV antibiotic therapy. There was no any systemic complication attributable to local anaesthesia consisting of anaphylactic reactions, arrhythmias, muscle twitching and collapse. Ullah I et al⁹ reported in his study that 2.8% patients developed carpal tunnel syndrome, 4.2% patients developed reflex sympathetic dystrophy which were managed by

psychological support, active motivation and intense physiotherapy and lastly in his study 1.4% patients developed infection which was treated with IV antibiotics.

In our study most of the fractures showed radiological union by 6 weeks comprising 41% of patients followed by 35% of patients who had radiological union by 4 weeks' time.

In our study the pain sensation scored according to visual analogue scale showed that 52% of patients experienced complete anaesthesia when reduction was done 5 minutes after the infiltration of hematoma block resulting in satisfying result evidenced by post reduction X- ray. On the other hand, 7% of patients experienced worst pain when reduction was done 1 minute after giving hematoma block. Afsar SS et al⁵ conducted a study in which there was highly significant pain reduction at 5 minutes after hematoma block., during reduction and 30 minutes post manipulation. Wadsworth TG et al¹¹ also conducted a study after giving 5 ml of 2% plain lignocaine on the fracture hematoma in patients with acute injury and found perfectly adequate anaesthesia in five minutes.

Bajracharya et al¹² compared the results of 50 patients receiving brachial plexus block with those of 50 patients receiving hematoma block for closed reduction of Colles' fracture. They also used VAS scoring to measure the outcome which showed that hematoma block was as effective as brachial plexus block in terms of providing analgesia.

It is our opinion that hematoma block using 2% of lignocaine injection can effectively reduce pain during closed reduction of displaced Colles' fracture which is as effective as general anaesthesia in relation to pain relief which also can be used safely by a doctor in emergency or in OPD without needing any costly or special equipment and has better patient compliance and equal outcome as with general anaesthesia, IV sedation, brachial plexus block or Bier's block.

V. Conclusion

Closed reduction of displaced Colles' fracture using hematoma block as analgesia provides significant pain lowering effect with excellent clinical and radiographic results. Patients has experienced complete anaesthesia after giving hematoma block which has proven to be very much effective for the doctors in emergency department or in OPD to carry out successful reduction of the fracture fragments. It has also been shown to have similar pain relieving and anaesthetic property as with general anaesthesia or regional blocks. The fracture got united radiologically by 4 to 6 weeks' time with good range of motion at the wrist joint. So, the significant pain lowering effect of hematoma block with low risk makes it a procedure of choice for closed reduction of distal radius fracture not only in peripheral hospitals but also in tertiary care set up.

References

- [1]. Nijs S, Broos PLO. Fracture of the distal radius: A Contemporary Approach. *Acta Chir Belg* 2004 Aug;104(4):401-12.
- [2]. Nellons KW, Kowalski E, Chung KC. The epidemiology of distal radius fracture. *Hand Clin* 2012 May;28(2) 113-25.
- [3]. Boyden EM, Peterson HA. Partial premature closure of the distal radial physis associated with Kirschner wire fixation. *Orthopedics* 1991 May 1;14(5):585-8.
- [4]. Kapoor H, Aggarwal A, Dhaon BK. Displaced intra-articular fractures of distal radius; a comparative evaluation of results following closed reduction, external fixation and open reduction with internal fixation. *Injury* 2000 March;31(2):75-9.
- [5]. Afsar SS, Idrees M, Gulzar M. Pain lowering effect of hematoma block for closed reduction of distal radius fractures. *Gomal J Med Sci* 2014 Jan-Mar; 12(1):15-8.
- [6]. Jarbo K, Batra YK, Nidhi M, Panda B. Brachial plexus block with midazolam and bupivacaine improves analgesia. *Can J Anesth* 2005 Oct 1;52(8):822-6.
- [7]. Johnson PQ, Noffsinger MA. Hematoma block of distal forearm fractures. Is it safe? *Orthop Rev* 1991 Nov;20(11):977-9.
- [8]. Chan SK, Karmakar MK, Chui PT. Local anaesthesia outside the operating room. *Hong Kong Med J* 2002 Apr;8(2):106-13.
- [9]. Ullah I. Hematoma Block Local anaesthesia For Closed Reduction of Colles- Type Fractures. *JPMI* 2011 Oct 21;25(1):56-61.
- [10]. Furia JP, Alioto RJ, Marquardt JD. The efficacy and safety of the hematoma block for fracture reduction in closed, isolated fractures. *Orthopedics* 1997 May 1;20(5):423-6.
- [11]. Wadsworth TG. Colles' fracture. *BMJ* 1990 Jul 28;301(6745):192-4.
- [12]. Bajracharya S, Singh S, Singh GK, Singh M, Bajracharya T. The efficacy of the hematoma block for fracture reduction in the distal forearm fractures: a double blind randomized controlled trial. *Int J Anesthesiol* Jun 2008;17(2): 442-5.

Dr.Raja Nag.et.al. "Closed Reduction of Displaced Colles' Fracture Using Hematoma Block." *IOSR Journal of Dental and Medical Sciences (IOSR-JDMS)*, 19(1), 2020, pp. 01-07.