

Ocular Toxicity Caused By Calotropis

Dr. Jitendra Kumar¹, Dr. Samya Singh², Dr. Amisha Garg³

^{1.} Associate Professor & Head, Dept. of ophthalmology, MLB Medical College Jhansi, India.

^{2,3} Junior Resident, Dept. of ophthalmology, MLB Medical College Jhansi, India.

Corresponding author: Dr. Jitendra Kumar

Abstract:

Aim: to study the toxic effects of *Calotropisprocera* on the eye

Material and Methods: This is a prospective study done on patients presenting with *Calotropis* induced ocular toxicity between January 2019-October 2019 in the Department of Ophthalmology, MLB Medical College, Jhansi.

Results: *Calotropisprocera* produces copious amounts of latex, which has been shown to possess several pharmacological properties. Its local application produces intense inflammatory response. In the 20 cases of *Calotropisprocera*-induced keratitis reported here, the clinical picture showed corneal edema with striate keratopathy with little evidence of intraocular inflammation. The inflammation was reversed by the local application of steroid drops.

Conclusion: The latex of *Calotropisprocera* causes significant ocular morbidity which may be preventable by simple health education. The long-term effect on corneal endothelium has to be studied further

Keywords: *Calotropisprocera*, keratitis, latex, striate keratopathy.

Date of Submission: 26-12-2019

Date of Acceptance: 10-01-2020

I. Introduction

Calotropisprocera is a species of flowering plant in the family Apocynaceae that is native to North Africa, tropical Africa, Western Asia, South Asia, and Indochina. The green fruits contain a toxic milky sap that is extremely bitter and turns into a gluey coating which is resistant to soap.

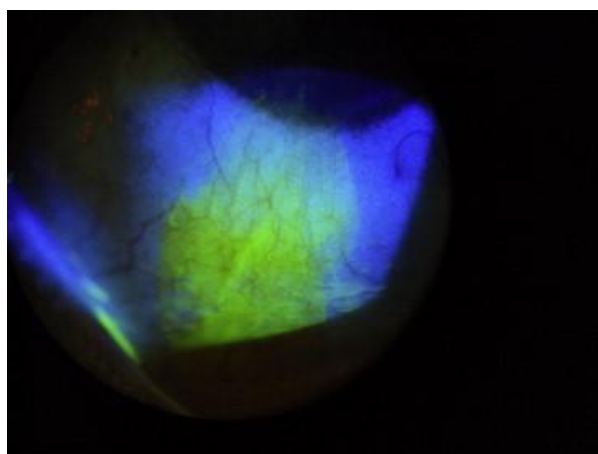
Common names for the plant include **apple of Sodom**,^[1] **Sodom apple**, **stabragh**, **king's crown**, **rubber bush** and **rubber tree** madaar. In India, it is found mainly in Assam, West Bengal, Rajasthan, Punjab, particularly in the wastelands.[2] They are medium-branched and perennial shrubs or small trees that grow up to a height of 4–5 meters with milky latex throughout. It has white or pink flowers which bloom between February and June. In Bengali, it is known as *Akanda* and in Hindi as *Ak*. Its flower or garland and the leaves are used to worship *Lord Shiva* during the festive season in the months of February and April every year in West Bengal. Thus, it is not so uncommon to get ocular injuries caused by accidental contact or inoculation of the latex of *Calotropisprocera* during plucking of the flower or leaf stalk during this season.



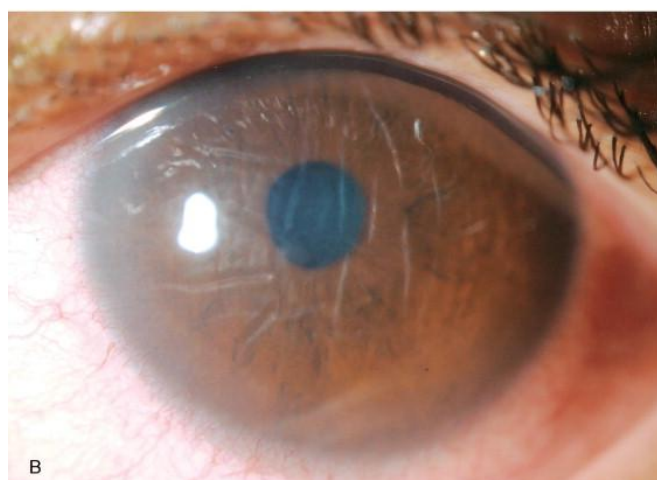
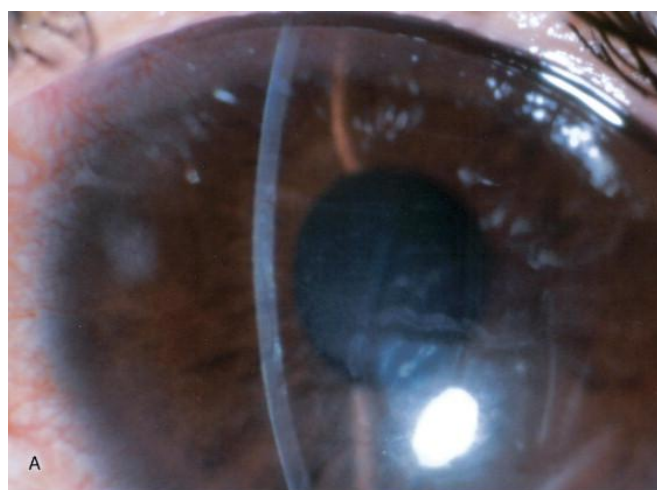
The milky white endogenous latex, produced by the plant in appreciable amount, exhibits a variety of effects in various animal models. On oral administration, the latex produces potent anti-inflammatory, analgesic,

and weak antipyretic effects, while on local administration it induces an intense inflammatory response in animal models. Pro-inflammatory activity seems to predominate over anti-inflammatory activity, suggesting its prevalence in the whole latex.

Accidental exposure to the latex has been reported to cause inflammation of the skin and eyes.[3,4,5] Ocular injury from this plant can be mechanical, or more commonly, toxic, due to the exposure to its latex. Studies suggest that this response was caused by the presence of histamine in the latex itself, as well as the release of mast cell histamine by the latex..^[9] Both histamine and prostaglandins are key mediators in an inflammatory response. Another possible mechanism is a reduced endothelial count due to the direct toxic effect of the latex



Pattern of Fluorescein stain in calotropis toxicity



Corneal edema with descemet's Folds as seen on slit lamp

II. Method And Material

This was a prospective study done in the year 2019 between January and October at Department of Ophthalmology, MLB Medical college, Jhansi. , It was performed under the Helsinki Declaration of 1975, as revised in 2000. The necessary permission from the Ethical and Research Committee was obtained for the study.

A study of 20 patients who presented with accidental ocular contact or injury with the latex of *Calotropisprocera*, in our department between January 2019 and october 2019 was performed. Apart from the demographic profile, a more detailed history was obtained from each patient to determine the mode of injury. Ocular examinations like best corrected visual acuity (BCVA) on presentation, slit-lamp findings, conjunctival injection, extent of corneal involvement including fluorescein staining and intraocular pressure by non-contact tonometer (NCT) were carried out for each Patient

They were treated with tapering doses of topical antibiotic, steroids, cycloplegics, 5% hypertonic saline and oral vitamin C. Additionally, the patients with secondary glaucoma were treated with topical antiglaucoma medication and the eyes with epithelial defect with tear substitutes. All patients were followed up at a regular interval depending upon the severity of injury, and studied for all the parameters

Maharani Laxmi Bai Medical College Jhansi
Kanpur Road Bundelkhand, University

UHD: 20200000678

CONSULTING ROOM NO. EMERGENCY OPD
CLINIC: EMERGENCY OPD TOKEN NO: 103

Department: EMERGENCY
ER No: **2020/083/0000202**
Name: **MR. DHANIRAM**
Date of Registration: 01-01-2020 10:59:02 PM
Billing Type: EMERGENCY
Mobile No.:
Address: JAIDPUR DATTA, MADHYA PRADESH, INDIA
Brought By: Self

Fees: ₹ 0
Unit: UNIT
S/O: RAGHVAR
Sex: Male Age: 48Y
Religion: UNKNOWN
Occupation: UNKNOWN
Patient Type: NON MLC Prepared By: Mr. Emergency one Email:

Presenting Complaints: 11/01/2020 11:41 PM
Ophthalmic Notes: A.H/O exposure to fluid of calotropis in (L) on 01/01/2020 at 11:00 PM near Tharu's as water tap (R)

Investigation: KUB: 1 M.I.,
Examined on patient
w.w.l. Cornea
Signature/Date: clear, 11/01/2020

Examination:
V: 3m
P: R
BP: R
R: Anterior chamber intact w/w.l.
ocular movement: w.w.l.
pupils: w.w.l.
conjunctiva/sclera: w.w.l.
Doctor's Name: Anika clear
AC: 10

vis	4/10	4/10
pupil	4/4 R	4/4 L
lens	greyish black reflex	greyish black reflex
fundus	fundal view seen	fundal view not seen

Inclusion criteria

1. All patients presenting to the Ophthalmic emergency of MLB Medical College, Jhansi post accidental exposure to Calotropis between January 2019- October 2019.

Exclusion criteria

1. Patients who refused examination and treatment
2. Patients with the history of trauma
3. Patients who refused follow up
4. Mentally or physically unfit patients

III. Results

The common features in all cases were delayed diminution of vision over a period of 2-4 h, absence of pain after initial burning sensation, inferior conjunctival staining e in the form of a triangle with apex towards inferior limbus and base towards the inferior fornix and corneal oedema with Descemet’s membrane folds. One patient had associated corneal abrasion due to mechanical rubbing of leaf of Calotropis plant against his cornea. All of them were treated in a similar manner as the main case except that topical steroids were withheld in the cases with epithelial defect till the defect healed. All the patients recovered fully over a period of 2-5 days to one week. The average period of recovery was 5 days

There was a strong male preponderance (85%), with only 3 female patients. Ten (50%) patients were flower vendors by profession and 21 (75%) patients had presented within 24 h of the injury. Right eye was affected in 12 (60%) cases. All eyes showed mild conjunctival congestion and mild to moderate ciliary congestion. All eyes had mild to severe corneal edema with Descemet's, one(5%) had mild to moderate degree of iridocyclitis, and three (15%) had secondary glaucoma. The range in intraocular pressure rise in these eyes as recorded by NCT was between 8.0–11.5 mm of Hg as compared to the fellow normal eye. In 19 (95%) eyes, the mean period of complete resolution was 5 days (range: 3–14 days) and the treatment was discontinued one week after the recovery.. The post-treatment BCVA returned to 6/6 in 18 (90%) cases with normal appearance of the cornea in all cases

Patient’s profile	Number of patients
age	25-65 years
Male:female ratio	17:3
Eye involved	Right eye-60% Left eye-40%
occupation	Flower vendor:50%(10 patients) Brahmin pundit:25%(5 patients) Others:25%(5 patients)
Time of presentation	Within 24 hours:75%(15) 24-48 hours:20%(4) After 48 hours: 5%(1)

Table 1: Clinical profile of patients with Calotropisocular toxicity

S.No.	Clinical features	Number of patients	Percentage
1	Pain	20	100
2	Redness	20	100
3	photophobia	20	100
4	Visual acuity- <6/60 6/60-6/18 6/18-6/12 6/12-6/9 6/9-6/6	2 4 4 8 2	10 20 20 40 10
5	Conjunctival congestion	16	80
6	Epithelial defect	2	10
7	Corneal edema with descemet’s folds	20	100
8	Other features	Mild Iridocyclitis-1 Secondary glaucoma-3	5 15

Table 2: Clinical features(signs and symptoms) in patients with Calotropis ocular toxicity

IV. Discussion

The sap of C. procera is acidic in reaction and turns blue litmus red. On keeping for some time the latex separates into a white coagulum and clear serum. The serum is highly toxic. Gigantin a white crystalline substance isolated from the serum has been found to be 15-20 times as poisonous as strychnine.1 Calotropis induced ocular manifestations occur because of two reasons, the first being the acidic nature of the milky sap and second due to the toxins present in the sap. The observations in our series of cases revealed that the clinical features occurred in two stages -Stage 1 - stage of acute acid injury and Stage 2 - stage of toxicity

. Stage of acute acid injury manifests like any other chemical injury due to acid. This stage is seen in all cases tha manifest immediately with burning sensation, pain and photophobia. There is staining of cornea and

conjunctiva due to epithelial defects as a result of acid injury. A very characteristic staining pattern was observed in some patients in the form of inferior conjunctival staining in the pattern of a triangle with apex towards inferior limbus and base towards the fornix. The explanation for this is that when a drop of sap falls into the eye it tracks down and settles down in the inferior fornix causing acid injury along its path.

Stage of toxicity starts from the suppression of pain after initial burning sensation and pain which appears to be the point of demarcation between the two stages.. The noticeable cause of this was corneal oedema with folds in Descemet's membrane. The finding of Descemet's membrane folds was observed in all the patients in this series and has also been reported universally in all reports in literature. The corneal oedema with Descemet's membrane folds appears to be the predominant feature due to the toxicity of *Calotropis* sap. It probably occurs because of toxicity to corneal endothelium. Pachymetry carried out in two cases showed increased central corneal thickness in affected eye as compared to the normal fellow eye. Specular microscopy revealed low endothelial cell count with pleomorphism and polymegathism in affected eye as compared to normal fellow eye.

Al-Mezaine et al[5] reported permanent endothelial cell loss with morphologic alteration in their case. Basak et al[6] reported low endothelial cell count in 17 out of 23 eyes (74%) on specular microscopy at three months in comparison to the normal fellow eye. These findings also suggest that the cause of corneal oedema is endothelial toxicity. Clinically all patients showed full recovery of corneal oedema and visual acuity within 7 days.

2 cases of iridocyclitis were seen in our study probably due to late presentation(after 48 hours) Pandey et al[7] did not report any case of iridocyclitis in their series of 10 cases. Toxic iridocyclitis due to *Calotropis* has been reported by Tomar et al[3] and also by Basak et al.[6] This could occur if the quantity of sap instilled in the eye is more or if it was not immediately washed off by the patient resulting in the tracking down of toxins to anterior chamber. The sap of *C. procera* has been found to contain histamine and prostaglandins^{6,7} which may lead to iridocyclitis. None of the cases in this series had secondary glaucoma. Pandey et al⁴ and Lakhtakia et al[8] also did not report any occurrence of secondary glaucoma which was reported by Basak et al[6] in their series. The raised intraocular pressure could be secondary to iridocyclitis all patients presented with sudden dimness of vision with photophobia due to corneal edema with Descemet's folds. Again as with other reports, pain was surprisingly absent in all the cases. This kind of painless course is probably due to the anesthetic properties of *Calotropis* latex. *Calotropis* latex is paradoxically relatively non-toxic to the corneal epithelium, but highly toxic to the corneal endothelium. That is why there was corneal edema with varying degree of Descemet's folds. The management in most cases is as simple as treating a mild chemical burn.

The irritant and pro-inflammatory property of latex of *Calotropis procera* has been well established.[9] The milky white latex of this plant irritates the mucous membrane and produces inflammatory reaction on local application or accidental exposure. It is known to produce contact dermatitis, and the latex of this plant produces intense inflammation when injected locally in animal models.[10,11] Shivkar *et al.*,[11] in their study on rat paw edema model, found that the injection of dried latex produces an intense inflammatory response involving edema formation and cellular infiltration. They showed that this was due to the presence of histamine in the latex itself and also due to the release of mast cell histamine by the latex. Besides, the latex has also been shown to induce prostaglandin synthesis through the induction of cyclooxygenase -2 (COX-2).[10] Both histamine and prostaglandins are the key mediators in an inflammatory response. Accordingly, we suggest the mechanism of stromal keratitis to be due to inflammation induced by exposure to latex due to its strong pro-inflammatory property. The resolution of keratitis with local corticosteroid use corroborates this notion. A reduction in endothelial count due to the direct toxic effect of the latex could be another possible mechanism, as suggested by Al-Mezaine *et al.*[7]

The epithelial lesions seen in three patients could be due to mechanical injury while rubbing. The painless clinical course of our patients could be attributed to the analgesic property present in the latex of *Calotropis procera*. [12]

V. Conclusion

C. procera plant expresses copious amount of poisonous sap on injury. The troops deployed in desert areas are exposed to this silent adversary particularly during night movement. It may lead to transient loss of varying degrees of vision in the affected eye. The ocular lesions are easily preventable by increasing the awareness and wearing protective glasses.

References:

- [1]. *Calotropis procera*". *Germplasm Resources Information Network (GRIN)*. *Agricultural Research Service (ARS)*, *United States Department of Agriculture (USDA)*
- [2]. http://en.wikipedia.org/wiki/calotropis_procera
- [3]. Tomar VP, Agarwal PK, Agarwal BL. Toxic iridocyclitis caused by *Calotropis*. *J All India Ophthalmol Soc.* 1970;18:15-6
- [4]. Shivkar YM, Kumar VL. Histamine mediates the pro-inflammatory effect of latex of *Calotropis procera* in rats. *Mediators*

- Inflamm. 2003;12:299–302
- [5]. Al-Mezaine HS, Al-Rajhi AA, Al-Assiri A, Wagoner MD. Calotropisprocera (ushaar) keratitis. *Am J Ophthalmol.* 2005;391:199–202.
- [6]. Basak SK, Bhaumik A, Mohanta A, Singhal P. Ocular toxicity by latex of Calotropisprocera. *Indian J Ophthalmol.* 2009;57:232e234
- [7]. Pandey N, Chandrakar AK, Garg ML, Patel SS. Calotropisprocera e induced keratitis. *Indian J Ophthalmol.* 2009;57:58e60
- [8]. Lakhtakia S, Dwivedi PC, Choudhary P, Chalisgaonkar C, Rahud J. Ocular toxicity of Calotropis e missing links. *Indian J Ophthalmol.* 2010;58:169
- [9]. Alencar NM, Oliveira JS, Mesquita RO, Lima MW, Vale MR, Etchells JP, et al. Pro- and anti-inflammatory activities of the latex from Calotropisprocera (Ait) R.Br. are triggered by compounds fractionated by dialysis. *Inflamm res.* 2006;55:559–64
- [10]. Kumar VL, Shivkar MY. Involvement of prostaglandins in inflammation induced by latex of Calotropisprocera. *Mediators Inflamm.* 2004;13:151–5
- [11]. Shivkar YM, Kumar VL. Histamine mediates the pro-inflammatory effect of latex of Calotropisprocera in rats. *Mediators Inflamm.* 2003;12:299–302
- [12]. Dewan S, Sangraula H, Kumar VL. Preliminary studies on the analgesic activity of Calotropisprocera. *J Ethnopharmacol.* 2000;73:307–11.

Dr. Jitendra Kumar.et.al. “Ocular Toxicity Caused By Calotropis.”*IOSR Journal of Dental and Medical Sciences (IOSR-JDMS)*, 19(1), 2020, pp. 29-34.