

## **Prolidase Deficiency; Leaning against Dental Aspects in Pediatric Patients: A Case Report**

Aswani Anil<sup>1</sup>, T.V Anupam kumar<sup>2</sup>, Gibi Syriac<sup>3</sup>, Raseena K.T<sup>4</sup>

<sup>1, 4</sup>(Post graduate student, Department of Pediatric and Preventive Dentistry, Government Dental college, Kottayam, Kerala, India)

<sup>2</sup>(Professor and Head of the Department, Department of Pediatric and Preventive Dentistry, Government Dental college, Kottayam, Kerala, India)

<sup>3</sup>(Assistant Professor, Department of Pediatric and Preventive Dentistry, Government Dental college, Kottayam, Kerala, India)

---

**Abstract:** Prolidase deficiency is a rare inborn disorder of collagen metabolism inherited through an autosomal recessive gene characterized by chronic recurrent cutaneous ulcers that are recalcitrant in healing, with massive multisystem enlargement. Prominent facial features include high forehead, flat nasal bridge, micrognathia and hypertelorism. The estimated incidence is 1-2 per 1 million births. Treatment of prolidase deficiency is symptomatic and supportive which necessitates a multidisciplinary expertise. This case report presents the dental management of 12 year old female patient with known history of Prolidase deficiency and iatrogenic Cushing's syndrome.

**Keywords:** Prolidase deficiency; collagen; Micrognathia; Hypertelorism; Iatrogenic Cushing's syndrome.

---

Date of Submission: 26-12-2019

Date of Acceptance: 10-01-2020

---

### **I. Introduction**

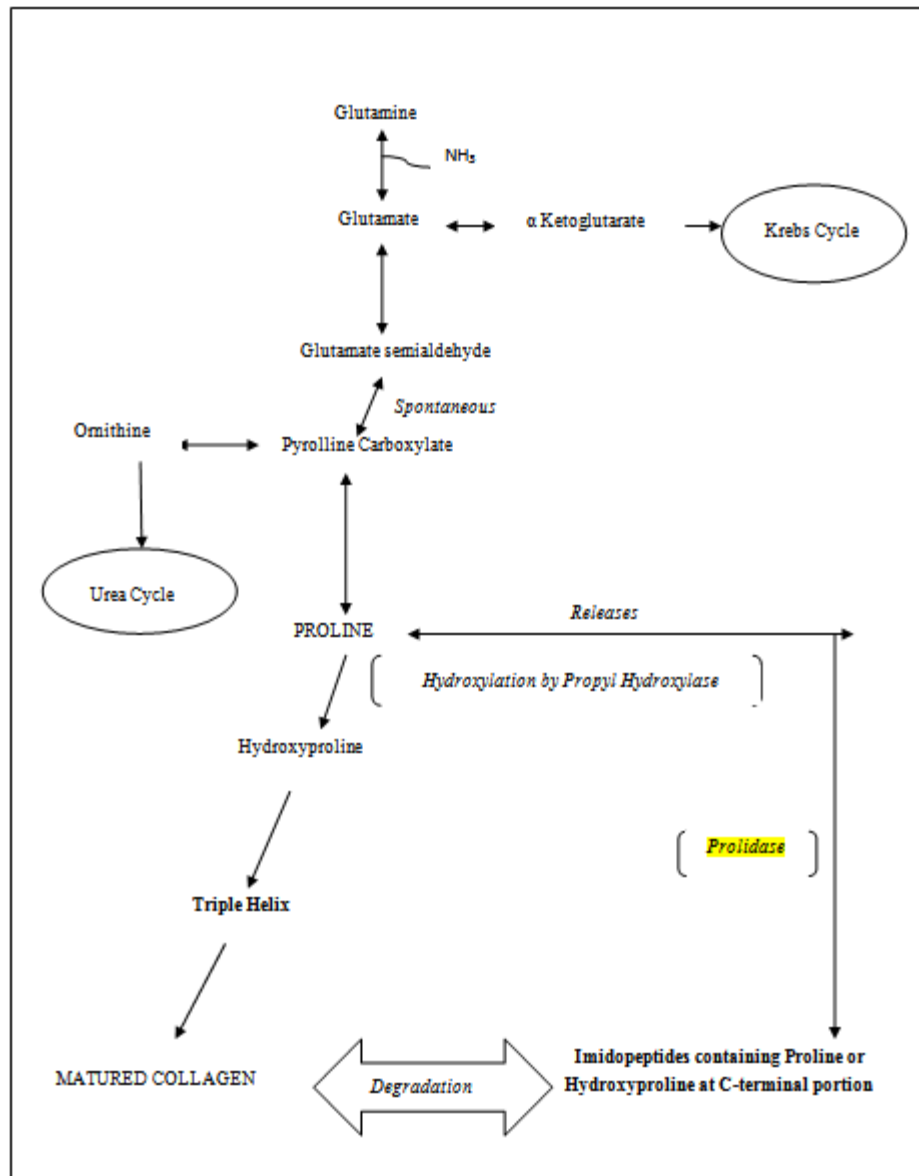
Prolidase Deficiency (PD or Peptidase Deficiency) is a rare metabolic disorder caused by mutation in peptidase D (PEPD) gene, affecting collagen degradation. Prolidase Deficiency is transmitted through an autosomal recessive gene with an incidence of 1-2 per 1,000,000 births (Lupi et al.2008). PD was first described by Goodman et al. (1968) and has a wide phenotypic spectrum with no evidence for genotype-phenotype correlation (Falik-Zaccari et al., 2010).

Prolidase, a ubiquitously distributed dipeptidase, is involved in the latter stages of degradation of endogenous and dietary proteins. It is particularly important in collagen catabolism by affecting the hydrolysis of proline or hydroxyproline- containing dipeptides at the C-terminal position.<sup>1</sup> (Fig.1)

This deficiency generally manifests during infancy and the affected individuals eliminate excessive amount of iminodipeptides in their urine. So it is also referred as *hyperimidodipeptidiuria*. Various diagnostic techniques have been advocated for the detection of imidopeptides in the urine.

PD is characterised by skin lesions, recurrent infections, and unusual facial features with multisystem enlargement. Prominent facial features include high forehead, flat nasal bridge, micrognathia and hypertelorism. Diagnosis is made based on the clinical features, patient history and genetic testing of the child. Treatment of Prolidase Deficiency is symptomatic and supportive which necessitates a multidisciplinary expertise.

Prolidase Deficiency is an extremely rare recessive disorder with only few cases reported to date in India. In this case report, the dental management of a 12-year old girl, referred from Medical College with typical features of Prolidase Deficiency diagnosed at 3 months of age is described.



**Figure 1:** showing role of Prolidase in collagen metabolism

## II. Case Report

A 12-year-old girl reported with her mother with a known history of Prolidase deficiency and Iatrogenic Cushing syndrome, was referred from medical college complaining of presheding mobility of upper left primary canine and decayed lower left permanent first molar. She was an inpatient of medical college with a chief complaint of itchy scaly lesions bilaterally on lower extremities with recurrent skin infections. Her prenatal and natal histories were normal. In her postnatal period, she was apparently asymptomatic till 6months of age. Later patient started developing itchy oozy plaques on left thigh which slowly involved her upper limbs, lower limbs, face and trunk by 1year of age. These lesions exacerbated during winter season and were associated with severe itching which affected her sleep and daily activities.

### Medical history

She gave history of recurrent furuncles, deep abscesses, swelling of left lower limb. She had more than 4 incisions and drainage done for those abscesses and had taken multiple course of oral & intravenous antibiotics and varying doses of steroids. She also had history of recurrent ear discharge and respiratory infections till 4 years of age. There was history of progressive weight gain since last 5-6years.

### Family history

She is the 2<sup>nd</sup> daughter of a non-consanguinous marriage. Elder sister had complaints of recurrent pneumonia in early childhood and vasculitic leg ulcers since 4 years.

**Personal history**

She was born at term by normal delivery with a birth weight of 2.4kg. She studied in Class VIII and had long leave of absence since the last 2 years owing to her illness.

**Extraoral examination**

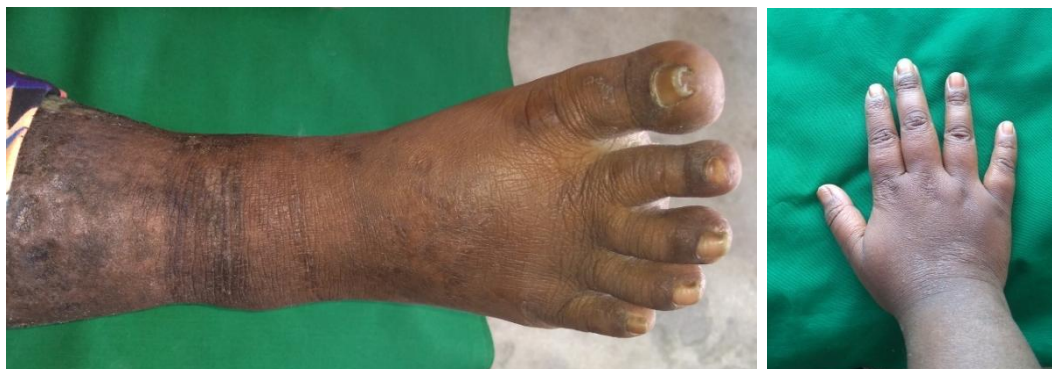Height: 147cm, Weight: 64kg (>97<sup>th</sup> centile), Abdominal Circumference: 95cm  
BMI: 29.61 (indicative of overweight)

She was conscious and well oriented and was having pallor in eyes with bilateral non-pitting pedal edema with inability to pinch the skin over dorsum of feet. There was no history of icterus, clubbing, cyanosis or lymphadenopathy. On clinical examination; child had moon facies, buffalo hump, short neck, angular chelitis, short finger and toes, short hands and feet with pale patchy nails (fig.2). Scalp showed crusted scaly plaques on sides. Upper limbs and thighs showed discrete minimally scaly plaques.



**Figure 2:** Typical features of Cushing's syndrome.

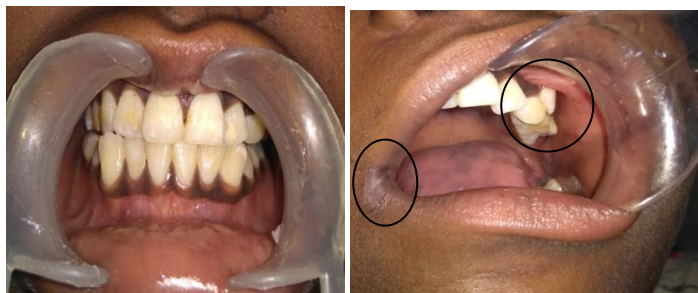There were xerosis and scaling on the trunk and proximal limbs with follicular prominence. Hyperpigmented plaques circumferentially involving both the legs were noticed. Also there were multiple irregular ulcers of size 1-2cm on the left leg with yellowish slough and serous ooze from these lesions (fig.3).



**Figure 3:** Non-healing ulcer on legs and pale patchy nails.

**Intraoral examination**

Child was in late phases of second transitional mixed dentition period. On intraoral examination, she was having poor oral hygiene, high arched palate with 13 in crossbite, preshredding mobility of 63, enamel hypoplasia of upper anteriors, deep dentinal caries of 36, developmental defects (morphologically) of lower first and second premolars and transposition between 23 and 24 (fig.4).



**Figure 4:** intraoral examination showing dental transposition and angular cheilitis

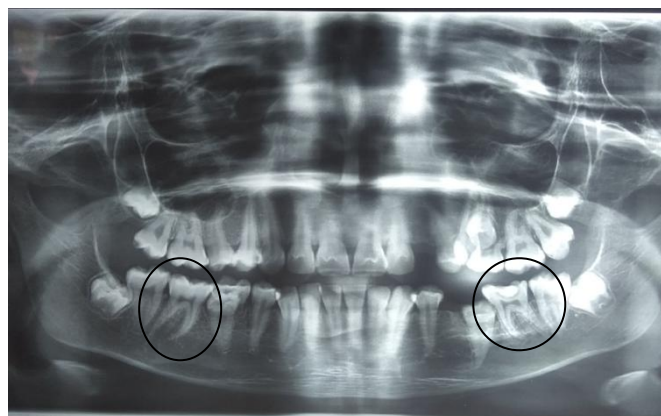
#### **Systemic examination**

Ultrasonography reports revealed Grade II fatty liver with mild hepatomegaly and splenomegaly.

Endocrinology: Iatrogenic Cushing's syndrome with osteopenia was noted on Chest X-ray. Investigations showed Hypovitaminosis D, low calcium levels and dyslipidemia

#### **Radiographic findings**

OPG showed radix endomolaris on both permanent mandibular first molars. Lateral cephalograph also showed adequate growth patterns (fig.5).



**Figure 5:** OPG showing radix endomolaris on 36 and 46

#### **General management**

For dermatitis lesions, she was on both topical and systemic steroids. She was treated with clotrimazole mouth paint for angular cheilitis. For secondary infections of superficial infections of lower limb ulcers, she was on cloxacillin and levofloxacin. She was diagnosed with adjustment disorder with depressive symptoms and was on Child Psychiatry consultation.

#### **Dental management**

Treatment is symptomatic and supportive which necessitates a multidisciplinary expertise. Extraction of 63 was done under local anaesthesia after getting clearance from dermatologist and endocrinologist. Appropriate instructions were given regarding importance of oral hygiene. Supragingival prophylaxis, topical fluoride applications were done as preventive treatment measures. Dental caries of 36 was treated with Biodentine as indirect pulp capping agent. Correction of transposed 23 and 24 was tackled by sectional fixed orthodontic therapy. Child was under regular follow up.

### **III. Discussion**

Prolidase Deficiency is rare autosomal recessive multisystem disorder caused by homozygous or compound heterozygous mutation in the PEPD gene on chromosome 19q13 affecting collagen metabolism. The parents of an individual with an autosomal recessive condition each carry one copy of the mutated gene, but they typically do not show signs and symptoms of the condition<sup>2</sup>.

Prolidase, a metalloenzyme responsible for hydrolysis of proline-containing imidodipeptides, is critical for the liberation of free proline in protein metabolism<sup>3</sup>. In humans, prolidase is essential for maintenance, rebuilding and degradation of collagen-containing connective tissue, and dysregulation of prolidase activity manifests as disruptions in collagen metabolism. Aberrations in prolidase activity are present in many disease

states such as cancers and fibrotic processes, and prolidase activity can be a useful marker in the early detection and monitoring of these conditions<sup>4</sup>.

It is associated with lack of or reduced prolidase activity in erythrocytes, leukocytes, or cultured fibroblasts<sup>5</sup>. Milligan reported multiple affected siblings, parental consanguinity, and equal sex distribution indicate that prolidase deficiency is an autosomal recessive disorder<sup>6</sup>.

Clinical features included chronic dermatitis, frequent infections, splenomegaly, and massive imidodipeptiduria. Other features include chronic ear and sinus infections, chronic skin lesions, and splenomegaly<sup>7</sup>.

Sheffield described a 11-year-old boy with Prolidase Deficiency who was born of consanguineous parents with distinctive clinical features of recurrent skin ulceration, lymphedema, hepatosplenomegaly, and mild mental retardation. Massive amounts of dipeptides, most of which had proline or hydroxyproline as the carboxyl residue, were excreted in the urine. Prolidase deficiency was demonstrable in red cells, fibroblasts, and continuous lymphocyte cultures<sup>8</sup>.

The unique features in the index case are normal physiologic development, morphological variations in permanent lower premolars, transposition of permanent canine and first premolar, presence of radix endomolaris bilaterally in lower permanent first molars.

The deficiency of this enzyme is responsible for massive loss of proline in the urine which is estimated to be as high as 3 gm per day<sup>9</sup>. The diagnosis of prolidase deficiency is based on the presence of characteristic clinical symptoms, high levels of imidodipeptides in the urine, and detection of either mutations in the *PEPD* gene or reduced levels of prolidase enzyme activity of fibroblasts and erythrocytes<sup>10</sup>.

Treatment is aimed at treating the specific symptoms present in each individual, which requires a multidisciplinary team of specialists. Treatment is of Palliative care in nature. Enzyme replacement is not possible because Prolidase does not have a specific membrane transport protein. Recently, prolidase encapsulated in nanoparticles or liposomes has been laboratory tested with success and is a promising therapeutic approach.

Prolidase deficiency that leads to skin ulceration, mental retardation, increased urinary excretion of iminopeptides, and recurrent infections has been associated with manganese deficiency. Therefore treatment modalities which seemed to be effective include supplementation with manganese, a cofactor of prolidase, and vitamin C, acting on collagen synthesis.

The topical application of ointment containing 5% glycine and 5% proline was found to be effective in number of trials. Pulsed corticosteroid treatment also showed good results and act by inhibiting iminodipeptide primed neutrophil superoxide generation<sup>11</sup>.

### **Prognosis**

In most cases, people with prolidase deficiency experience a reduced quality of life because of infections and chronic pulmonary (lung) complications. Life expectancy is often decreased, with infection being the most common cause of death<sup>12</sup>.

## **IV. Conclusion**

Prolidase deficiency is characterized by skin lesions, recurrent infections (particularly of the skin and respiratory tract), dysmorphic facial features, hepatomegaly and splenomegaly. The diagnosis of prolidase deficiency is established by detection of either *PEPD* gene or reduced prolidase enzyme activity in erythrocytes, fibroblasts who has characteristic clinical findings and imidodipeptiduria. Treatment is of interdisciplinary approach. No curative treatment is available. Supportive treatment of skin, lung, and immunologic manifestations has been found to be effective in some patients. Patient and parent educational interventions are needed to encounter and address the motor and cognitive delays.

## **References**

- [1]. Yonatan Butbul Aviel, Hana Mandel, Emily Avitan Hersh. Prolidase deficiency associated with systemic lupus erythematosus (SLE): single site experience and literature review. *Pediatr Rheumatol Online J.*2012; 10: 18.
- [2]. Prolidase deficiency. Genetics Home Reference (*GHR*).2012.
- [3]. Lowther, W.T. and Matthews, B.W. (2002) Metalloaminopeptidases: Common functional themes in disparate structural surroundings. *Chem Rev* 102, 4581–4608.
- [4]. R.L Kitchener, A.M. Grunden. Prolidase function in proline metabolism and its medical and biotechnological applications. 2012. *Journal of Applied Microbiology* 113, 233–247.
- [5]. Endo F, Motohara K, Indo Y, Matsuda I. Immunochemical studies of human prolidase with monoclonal and polyclonal antibodies: absence of the subunit of prolidase in erythrocytes from a patient with prolidase deficiency. *Pediatr. Res.* 1987.22: 627-633.
- [6]. Milligan A, Graham-Brown, Burns, D. A Anderson. Prolidase deficiency: a case report and literature review. *Brit. J. Derm.* 121: 405-409, 1989.
- [7]. Powell G. F, Kurosky A, Maniscalco R. M. Prolidase deficiency: report of a second case with quantitation of the excessively excreted amino acids. *J. Pediatr.* 1977.91: 242-246.

- [8]. Sheffield L. J, Schlesinger P, Faull K, Halpern B. J, Schier G. M., Imino-peptiduria, recurrent skin ulcerations and edema in a boy with prolidase deficiency. *J. Pediat.* 91: 578-583, 1977.
- [9]. Scriver CR, Smith RJ, Phang JM. Disorders of proline and hydroxyproline metabolism: The metabolic basis of inherited disease. 5th ed. McGraw-Hill: New York; 1983:360-81.
- [10]. Ferreira C, Wang H. Prolidase Deficiency. *Gene Reviews.* June 25, 2015.
- [11]. Yasuda K, Ogata K, Kodama H, Kodama H, Zhang J, Sugahara K. Corticosteroid treatment of prolidase deficiency skin lesions by inhibiting imino-peptide-primed neutrophil superoxide generation. *Br J Dermatol* 1999; 141:846-51.
- [12]. Jaeken J. Prolidase deficiency. *Orphanet.* July 2006.

Aswani Anil.et.al. “Prolidase Deficiency; Leaning against Dental Aspects in Pediatric Patients: A Case Report.” *IOSR Journal of Dental and Medical Sciences (IOSR-JDMS)*, 19(1), 2020, pp. 61-66.