

Differences of TNF- α Levels and Degree of Histopathological Damage of Contralateral Testis between Rattus Norvegicus Strain Wistar Which Done Orkidectomy with Ordidopexy in the Testicular Torsion Model

Besut Daryanto*, Rizki Hanifan Nugraha**

* Department of Urology, Faculty of Medicine, Brawijaya University – Dr.Saiful Anwar General Hospital, Malang

**Department of Surgery, Faculty of Medicine, Brawijaya University - Dr. Saiful Anwar General Hospital, Malang

Abstract

Background: Testicular torsion is one of urological emergencies that develop in puberty and early adulthood. Management of testicular torsion is surgical detortion and bilateral orchidopexy through transscrotal access with orchidectomy, which is indicated only for unviable cases that cannot be reperfused after detortion or with necrosis. Ischemia/reperfusion as the main pathophysiological of testicular torsion with inflammation. Systemic inflammation can make contralateral testicular damage. TNF- α is the main cytokine in the inflammatory response. Increased TNF- α can cause NF κ B activation in cells and can affect apoptosis. **Aim:** This study aims to determine differences in serum TNF- α levels and the degree of contralateral testicular histopathological damage between rats performed by orchidectomy and rats performed by orchidopexy in the testicular torsion model. **Materials and Method:** This research was conducted in a true experimental post-test design using rat animals. Subjects were divided into four negative control groups (K0), groups of rats with testicular ischemia for 6 hours followed by orchidectomy (K1), groups of rats with testicular ischemia for 6 hours without being followed by orchidectomy (K2), groups of rats with reperfusion for 6 hours followed by random detoxification and repositioning of the testicles (K3). Then after 24 hours it was observed and compared the effect of each procedure on the contralateral testis by looking at serum TNF- α levels and the degree of histopathological damage to the contralateral testis. **Results:** Significant differences were obtained in the group without orchidectomy for the control group and the group that performed orchidectomy as well as the group that performed detortion and orchidopexy because it had a p-value <0.05. **Conclusion:** The testes with testicular torsion will affect contralateral testicular damage through increased serum TNF- α levels and increased histopathological damage. Orchidectomy and orchidopexy management due to torsion of the testis will save the contralateral testes.

Keywords: Histopathology, orchidectomy, orchidopexy, testicular torsion, TNF- α , .

Date of Submission: 26-09-2020

Date of Acceptance: 09-10-2020

I. Introduction

Testicular torsion is one of urological emergencies that develops in puberty and early adulthood (1). Annual incidence is 1 in 4000 individuals under 25 years. The success of the aid depends on the duration and degree of torsion (2). Management of testicular torsion is bilateral testicular detachment and orchidopexy through transscrotal access, with orchidectomy indicated in unviable cases that cannot be reperfused after detortion, or with necrosis (6). Various researchers examine testicular torsion from various perspectives, including the effect of ischemia on testicular parenchyma, the phenomenon of reperfusion ischemia, activation of apoptosis and its potential for lesion expansion, involvement of the FAS system in the induction of apoptosis in germinative cells, damage to the contralateral testes, and steps to avoid or reduce the torsion effect (5).

Ischemic injury / reperfusion is the main pathophysiology of torsion / testicular detortion. This injury is associated with overproduction of reactive oxygen compounds and reactive nitrogen compounds. Mammalian testes are very sensitive to reactive compounds (3). Reactive oxygen compounds will increase in the area of reperfusion ischemia and play an important role in the loss of ipsilateral spermatogenesis (14). Under normal conditions, reactive oxygen compounds will be neutralized efficiently by various cellular antioxidant systems. In a variety of conditions, there is an imbalance between the production of reactive oxygen compounds and antioxidant defenses that triggers cellular destruction and dysfunction. This is known as oxidative stress (7). Depending on the level of reactive oxygen compounds, various transcription factors sensitive to changes in

redox status will be activated and coordinate certain biological responses. Oxidative stress at low levels will induce Nrf2, a transcription factor that has implications for gene reactivation that codes for enzymatic antioxidant activity. Reactive oxygen compounds at moderate levels will trigger an inflammatory response through activation of NF- κ B and AP-1. The oxidative stress at high levels will disrupt the mitochondrial pore and disruption of electron transfer which eventually causes necrosis or apoptosis (5).

TNF- α is the main cytokine in the acute inflammatory response to infection and other stimuli. Severe infections can trigger the production of TNF- α in large quantities that cause systemic reactions. TNF is called TNF- α on a historical basis and to distinguish it from TNF- β or lymphotoxins. The main sources of TNF- α are mononuclear phagocytes and antigen-activated T cells, NK cells and mast cells. At low levels, TNF- α acts against leukocytes and endothelials, inducing acute inflammation. At moderate levels, TNF- α plays a role in systemic inflammation. At high levels, TNF- α causes pathological abnormalities in septic shock (3).

In histological studies, testicular torsion can trigger focal lesions in the seminiferous tubules, which are characterized by apoptosis and germinative cell turnover. This is likely caused by humoral and cellular immune responses (13). Contralateral testicular lesions due to testicular torsion are controversial. Some researchers claim that unilateral testicular torsion causes contralateral testicular lesions while other researchers state otherwise. Some theories proposed to explain the mechanism of contralateral testicular damage are autoimmune reactions, subclinical episodes of contralateral testicular torsion, release of acrosome enzymes, vasomotor reflexes, neuroendocrine response, defects spermatogenesis, and intrinsic gonad abnormalities (10,16).

Based on the above theory, there is a relationship between ischemia / reperfusion as the main pathophysiological of torsion testis and inflammation. Thus there seems to be a relationship between systemic inflammation and contralateral testicular damage. Therefore, this study aims to analyze systemic inflammation with indicators of serum TNF- α levels in the torsion of the testis and their effect on the contralateral testis.

II. Materials And Method

This research was conducted in a true experimental post-test design using rat animals. This study has been approved by Ethical Committee of Medical and Health Research, Faculty of Medicine, University of Brawijaya (44/EC/KEPK-PPDS/02/2020).

Twenty samples of *Rattus Novergicus* rats of Wistar were divided into 4 groups (5 samples per groups) with different intervention: Negative control (K0), group of rats with testicular ischemia for 6 hours followed by orchidectomy (K1), group of rats with testicular ischemia for 6 hours without followed by orchidectomy (K2), group of rats with reperfusion during 6 hours followed by detortion and repositioning of the testicles in the scrotum (K3) randomly. After 24 hours, all rats euthanized by using 1 mg/kg Fentanyl intramuscular injection and the testes were taken for further analysis. Then, we compared the effect of each procedure on the contralateral testis by looking at serum TNF- α levels and histopathology of the contralateral testis.

Histopathological analysis was carried out by pathologists blindly, randomly, and without knowledge of the research conducted. By using the grading scale from Cosentino et al., (1986) histology injuries can be calculated. Grade 1 shows an image of normal testicular architecture with regular arrangement of germ cells. Grade 2 injuries show irregularity, non-cohesive germ cells, seminiferous tubules closely packed. Grade 3 injuries show chaos, peeling, germ cells with shrinkage, picnotic nuclei, and less apparent seminiferous tubule boundaries. Grade 4 injuries display closely packed seminiferous tubules with coagulative necrosis of germ cells. Whereas serum TNF- α analysis was carried out using the Enzyme Linked Immunosorbent Assay (ELISA) technique using the ELISA Kit for TNF- α in pg / ml units.

Statistical tests using one way ANOVA were continued by Tukey test for IL-1 and for histopathology using the Kruskal Wallis test and Lambda correlation. Significant differences were obtained without the orchidectomy of the control group and the orchidectomy group because it had a p value <0.05

III. Results

Based on descriptive analysis of all 4 groups of interventions, it was found that the lowest mean serum TNF- α levels in the negative control group (K0), while the highest serum TNF- α levels were found in the rat group with testicular ischemia for 6 hours without followed by orchidectomy(K2).

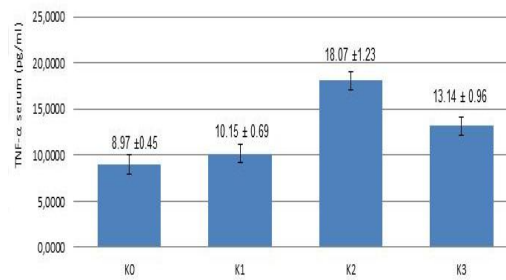


Figure 1. Graph of the average serum TNF- α levels in each treatment group.

Based on the degree of histopathological damage to the contralateral testis, it was found that the highest degree of damage was in the group of rats with testicular ischemia for 6 hours without followed by orchidectomy (K2). While the lowest degree of histopathological damage to the contralateral testis was found in the negative control mouse group (K0).

Table 1. Data on the degree of histopathological damage to the contralateral testis

Rat	Group			
	K0 (grade)	K1 (grade)	K2 (grade)	K3 (grade)
1	1	1	3	2
2	1	1	2	2
3	1	1	3	1
4	1	2	3	2
5	1	1	3	2

ANOVA analysis results, it was found that the value of sig. F for serum TNF- α levels is 0,000. Because for the parameter TNF- α serum level has a p value <0.05, then reject Ho, which means that there is a significant difference in effect between treatments at an error rate of 5%.

To find out the difference between treatments, further tests were carried out using Tukey. To find out more about the differences in treatment of the average treatment group, Post Hoc Tests analysis can be done, the difference in the treatment group is shown if the treatment has an average located in a different column.

Based on the results of the post hoc test table, it was found that K2 had significant differences with groups K0, K1, and K3. While the groups K0 and K1 have no significant differences.

From the kruskal wallis test, the p value (0.02) <0.05 indicates that at least one of the groups used is different from the other groups. This shows that the groups gave a significant difference in the degree of histopathological damage to the contralateral testis. To find out the difference in concentration then proceed with the Mann-Whitney test.

After doing the Kruskal wallis test, the different test was continued using the Mann Whitney method to find out the differences between the two treatments (the concentration used). It was found that K0 has a significant difference with K2 and K3 because it has a p-value <0.05. While K0 and K1 have insignificant differences because they have p> 0.05. K1 has a significant difference with K2 because it has a p-value <0.05. While K1 and K3 have insignificant differences because they have p> 0.05. K2 has a significant difference with K3 because it has a p-value <0.05.

From the Spearman test results, s obtained a significance value of p-value of 0,000 (<0.05) then reject the null hypothesis (H0). In conclusion, there is a significant relationship between serum TNF- α levels and the degree of histopathological damage to the contralateral testis. The magnitude of the correlation is 0.905 which means it has a very strong correlation (0.75-0.99) and is positive. This means that the higher the serum TNF- α level, the higher the degree of histopathological damage to the contralateral testis.

IV. Discussion

Testicular torsion is one of urological emergencies that develops in puberty and early adulthood (1). The success of the aid depends on the duration and degree of torsion (2). Treatment measures include surgical distortion and bilateral orchidopexy through transcrotal access, with orchidectomy indicated only for unviable cases that cannot be reperfused after distortion, or with necrosis (6).

Ischemic injury / reperfusion is the main pathophysiology of torsion / testicular detortion. This injury is associated with overproduction of reactive oxygen compounds and reactive nitrogen compounds. Mammalian testes are very sensitive to reactive compounds (3). Reactive oxygen compounds will increase in the area of reperfusion ischemia and play an important role in the loss of ipsilateral spermatogenesis (15). TNF- α is the earliest cytokine to appear in the acute process. TNF- α is an activation inducing cytokine from NF- κ B, in addition to physical stress, oxidative stress, mitogen, viruses and their products, bacteria and their products and other pathological conditions (8).

TNF- α is the main cytokine in the acute inflammatory response to infection and other stimuli. Severe infections can trigger the production of TNF- α in large quantities that cause systemic reactions. TNF is called TNF- α on a historical basis and to distinguish it from TNF- β or lymphotoxins. The main sources of TNF- α are mononuclear phagocytes and antigen-activated T cells, NK cells and mast cells. At low levels, TNF- α acts against leukocytes and endothelials, inducing acute inflammation. At moderate levels, TNF- α plays a role in systemic inflammation. At high levels, TNF- α causes pathological abnormalities in septic shock (3).

In histological studies, torsion can trigger focal lesions in the seminiferous tubules, which are characterized by apoptosis and germinative cell turnover. This is likely caused by humoral and cellular immune responses (13).

Based on the above theory, there is a relationship between ischemia / reperfusion as the main pathophysiological of torsion testis and inflammation. Thus there seems to be a relationship between inflammation and contralateral testicular damage.

In the ANOVA test data obtained with the value obtained that the value of sig. F for serum TNF- α levels is 0,000. Because the parameters for serum TNF- α levels have a p value <0.05, it means that there is a significant difference in effect between treatments. Thus there were differences in serum TNF- α levels in group 1 (testicular ischemic mice followed by orchidectomy), group 2 (testis ischemic mice without being followed by orchidectomy), group 3 (testicular reperfusion mice followed by testicular detoxification and orchidopexion), group 0 (control). To find out more about the difference in treatment of the mean treatment group, a Post Hoc Tests analysis can be done, the difference in the treatment group is indicated if the treatment has an average located in a different column. The results show that group 2 has a significant difference with the control group, group 1 and group 3 because it has an average that is located in a different column. While group 1 had insignificant differences with the control group because it was located in the same column.

In group 2 (orchidectomy (-)) the highest serum TNF- α levels were obtained. Serum TNF- α levels in group 1 (orchidectomy (+)) were the same as group 0 (control). Serum TNF- α levels are increased in group 3 (reperfusion), and have higher levels than group 1 (orchidectomy (+) and control group. In principle, if group 1 is compared with group 2 the necrotic tissue is removed without exceeding golden time the period for torsion testis is 6 hours, it will not have a bad effect, while in group 3 to the control group, group 1 and group 2 there is a significant difference. This is because in group 3 an increase in serum TNF- α levels occurs through 2 mechanisms, namely ischemia due to torsion testis and reperfusion due to testicular detortion, so that in group 3 even after 6 hours of torsion testis have been carried out with detortion and orchidopexy, serum TNF- α levels are still increasing because the reperfusion process is still ongoing.

Serum TNF- α levels and the degree of histopathologic damage to the contralateral testes in group 1 had insignificant differences with the control group. This proves that orchidectomy on torsion of the testis for 6 hours can save the contralateral testis. TNF- α levels in group 3 that experienced ischemic reperfusion of injuri performed orchidopexy showed a significant difference with group 0, group 1, and group 2. Whereas histopathologically in the ischemic group the injuri reperfusion showed no significant damage compared to group 1. Testes that were not performed orchidectomy and orchidocepeation will experience contralateral damage from torsion of the testis for 6 hours. Orchidectomy and orchidopexy will save the contralateral testis in a short-term evaluation. This is also in accordance with the golden period of handling the testicular torsion which is 6 hours.

Based on Spearman correlation test, we found a strong positive correlation, which means that the higher the serum TNF- α level, the higher the degree of histopathological damage to the contralateral testis.

The above is in line with previous studies conducted on wistar rats, proving that testicles with testicular torsion will affect contralateral testicular damage through increased levels of IL-1 and increased histopathological damage. This research was carried out by laboratory experimental experiments using rat animals. This study used male Wistar rats, young adult age (12 weeks), body weight 150-200 grams, healthy with a total sample of 20 mice. Subjects were divided into four groups (negative control (K 0), group of rats with testicular ischemia for 6 hours followed by orchidectomy (K 1), group of rats with testicular ischemia for 6 hours without followed by orchidectomy (K 2), group of rats with reperfusion for 3 hours followed by detortion and repositioning of the testicles in the scrotum (K 3) randomly. Then after 24 hours it was observed and compared the effect of each procedure on the contralateral testis by looking at IL 1 levels and the histopathology of the contralateral testis. Statistical tests using one way ANOVA were continued by Tukey test for IL-1 and for

histopathology using the Kruskal Wallis test and Lambda correlation. Significant differences were obtained without the orchidectomy of the control group and the orchidectomy group because it had a p value <0.05.(11)

The implications of this research are the accuracy of the handling of testicular torsion without exceeding the golden period and education about testicular torsion is needed for the public, The following research proposals are designing a testicular torsion model for long-term contralateral testicular damage, designing a testicular torsion model with other interleukin markers and designing a testicular torsion model by providing anti-inflammatory therapy to determine its potential in reducing contralateral testicular damage.

V. Conclusion

Testes with testicular torsion will affect contralateral testicular damage through increased serum TNF- α levels and increased histopathological damage. Orchidectomy and orchidopexy actions due to torsion of the testis will save the contralateral testes.

DISCLOSURE

The author declares no conflict of interest.

References:

- [1]. Anderson JB, Williamson RC. 1988. Testicular torsion in Bristol: a 25-year review. *Br J Surg*; 75:988-92.
- [2]. Cuckow PM, Frank JD. 2000. Torsion of the testis. *BJU Int*; 86: 349-53.
- [3]. Dokmeci D, Inan M, Basaran UN, et al. 2007. Protective effect of L-carnitine on testicular ischaemia-reperfusion injury in rats. *Cell Biochem Funct*; 25:611-8.
- [4]. Dokucu A I, et al. 2000. The protective effect of nitric oxide on the contralateral testis in prepubertal rats with unilateral testicular torsion. *BJU int*;85, 767-771.
- [5]. Glorie G, Legrand-Poels S, Piette J. 2006. NF- κ B activation by reactive oxygen species: fifteen years later. *Biochemical Pharmacology*; 72:1493-1505.
- [6]. Jesus LE. 2000. Acute scrotum. *Rev Col Bras Cir*; 27(4):271-8.
- [7]. Lee S, Lee K. 2007. Protective effect of (-)-epigallocatechin gallate against advanced glycation endproducts-induced injury in neuronal cells. *Biology Pharmacy Bulletin*; 30(8):1369-1373.
- [8]. Liu SF, Malik AB. 2006. NF- κ B activation as pathological mechanism of septic shock and inflammation. *American Journal Lung Cell Molecular Physiology*; 290:622-645.
- [9]. Mogilner JG, Lurie M, Coran AG, Nativ O, Shiloni E, Sukhotnik I. 2006. Effect of diclofenac on germ cell apoptosis following testicular ischemia-reperfusion injury in a rat. *Pediatr Surg Int*; 22:99-105.
- [10]. Nguyen L, Lievano G, Ghosh L, Radhakrishnan J, Fornell L, John E. 1993. Effect of unilateral testicular torsion on blood flow and histology of contralateral testes. *J Pediatr Surg*; 34(5):680-3.
- [11]. Pratiwi D., Purnomo BB. 2016. Perbedaan Kadar IL-1 dan Derajat Kerusakan Histopatologi pada Testis Kontralateral pada Tikus (*Rattus Novergicus Strain Wistar*) yang Mengalami Orkidektomi dan Orkidopeksi Akibat Torsio Testis. Thesis.
- [12]. Purnomo BB. *Dasar-dasar Urologi*. Jakarta : Sagung Seto. 2013. 8,145-148
- [13]. Rodriguez MG, Rival C, Theas MS, Lustig L. 2006. Immunohistopathology of rats undergoing experimental torsion of the spermatic cord. *Asian J Androl*; 8(5):576-83.
- [14]. Turner TT, Tung KS, Tomomasa H, Wilson LW. 1997. Acute testicular ischemia results in germ cell-specific apoptosis in the rat. *Biol Reprod*; 57(6):1267-74.
- [15]. Turner TT. 1985. Acute experimental testicular torsion. No effect on the contralateral testis. *J Androl*; 6(1):65-72.
- [16]. Visser AJ, Heyns CF. 2003. Testicular function after torsion of the spermatic cord. *BJU Int*; 92(3):200-3.

Besut Daryanto, et. al. "Differences of Tnf-A Levels and Degree of Histopathological Damage of Contralateral Testis between *Rattus Norvegicus Strain Wistar* Which Done Orkidektomy with Orkidopexy in the Testicular Torsion Model." *IOSR Journal of Dental and Medical Sciences (IOSR-JDMS)*, 19(10), 2020, pp. 54-58.