

Intracystic Papillary Carcinoma of the Breast in a Male Patient: A Case Report and Review of Literature

Dr. Sree Vijayaraj.AR¹, Dr. Manojh.M²

¹(Assistant Professor, Department of General Surgery, Coimbatore Medical College Hospital, The Tamil Nadu
Dr.M.G.R. Medical University, India)

²(Postgraduate, Department of General Surgery, Coimbatore Medical College Hospital, The Tamil Nadu
Dr.M.G.R. Medical University, India)

Abstract

Breast carcinoma is an uncommon neoplastic condition among man, accounting for not more than 1% of all breast cancers. Intracystic papillary carcinoma in man is an extremely rare condition and represents only 5–7.5% of all male breast carcinomas. Clinical and radiological manifestations of intracystic papillary carcinomas are not specific. Pathologic diagnosis can be difficult at classical histological examination and identification of myoepithelial cells layer by immunohistochemical study can be useful. Adjuvant therapy is still controversial, and prognosis is excellent. We report a case of this rare histological type of breast cancer in 47-year-old male patient and review the literature.

Date of Submission: 08-10-2020

Date of Acceptance: 22-10-2020

I. Introduction

Breast carcinoma in men is rare; it represents 0.6% of all breast carcinomas and less than 1% of all malignancies in men [1]. Intracystic papillary carcinoma (IPC) is a rare form of breast cancer, accounting for 0.5–1% of all breast cancers [2]. IPC in man is an extremely rare disease with only a few case reports published in the literature so far. IPC accounts for 5 to 7.5% of all male breast cancers [3]. It typically occurs at an old age with a good prognosis [4]. One study reported that 10-year survival rate for IPC is 100%; the recurrence-free survival rate is 96% and 77% at 2 and 10 years, respectively [2]. Clinical and radiologic manifestations of IPC are not specific. On ultrasonography, it can be pure cyst, a mixed image, or a solid mass. Therapeutic management of IPC is also still controversial. Endocrine therapy and radiation are used by many centers but evidence of their role in prognosis improvement is still lacking. Here, we report a case of intracystic papillary carcinoma (IPC) of breast in 47 years old male patient and review the literature.

II. Case Report

A 47-years-old man presented in General Surgical Department of our hospital with painful round swelling in the right breast, since 6-months duration. He had noticed a rapid increase in size for 10 days. There was no history of systemic disease, trauma, or family cancer history. On physical examination, 4x3 cm well-circumscribed, firm, painful mobile mass was noted in right breast. Nipple was not retracted. Bilateral axillary lymph nodes were not palpable. Left breast was normal. On sonography the mass was a cystic swelling measuring 5x3 cm (Figure 2). These finding suggested a benign breast cyst and a surgical excision was performed.

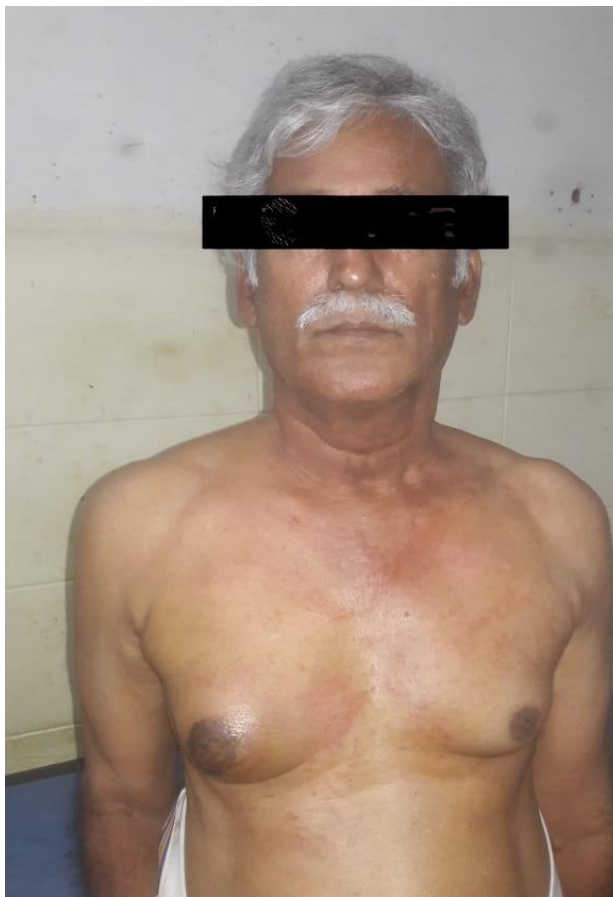

Figure 1

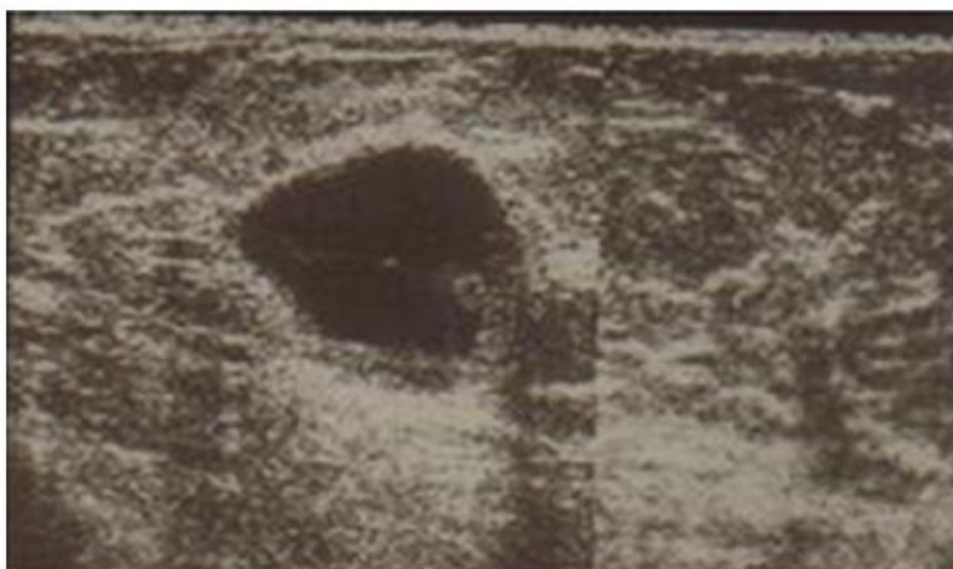

Figure 2 USG of right breast showing a cystic lesion

Specimen (Figure 3) was sent for histopathological examination. Specimen received was 5x3 cm and was lipomatous. The cut section showed cystic structures measuring 5x3cm filled with serosanguinous material. Permanent sections revealed a dilated duct with papillary structures protruding into the lumen. These papillary structures had fine fibrovascular cores and were covered with multilayered cells showing prominent nuclear pleomorphism and brisk mitotic activity (Figure 4).

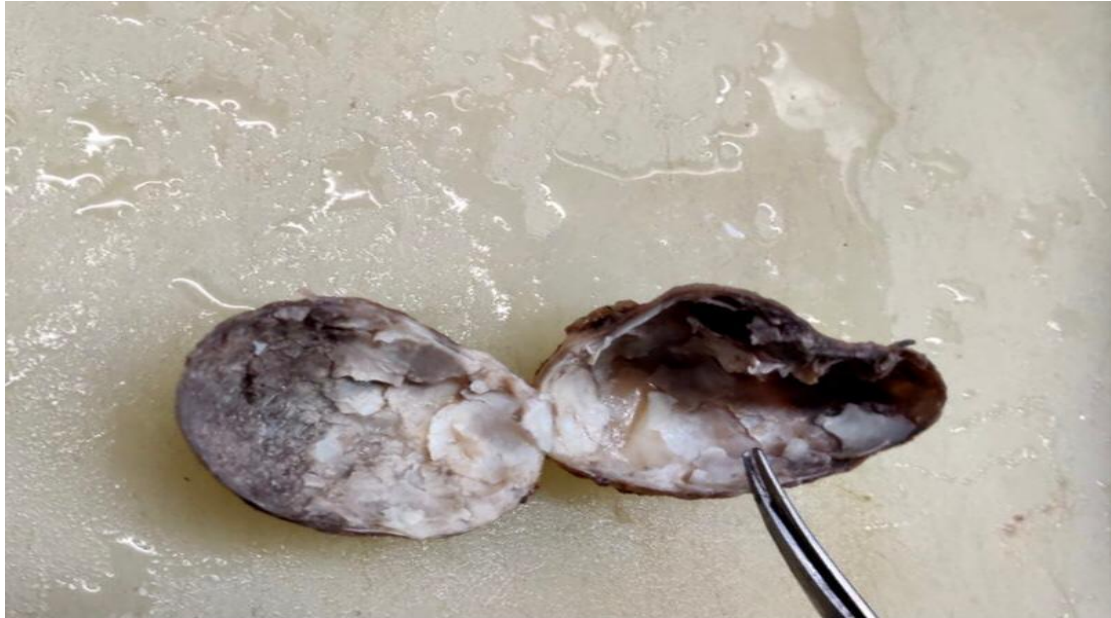

Figure 3

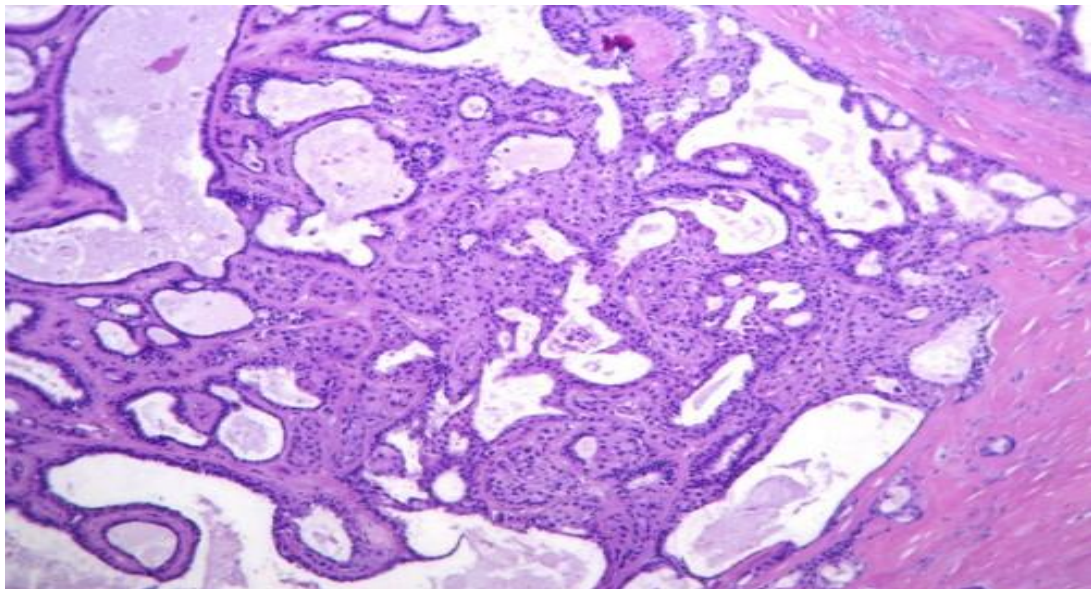


Figure 4

DEPARTMENT OF PATHOLOGY COIMBATORE MEDICAL COLLEGE HOSPITAL, COIMBATORE - 18			
Lab Ref No.	NAME	AGE/SEX	Date of Report
3554/19	Mohammed Firozulla	47/M	16/10/19
	UNIT		
	17254		
	SPECIMEN	IP No./OP No.	
	Right breast tissue	73284	
16/10/19			
GROSS			
PROCEDURE:	Right Simple Mastectomy		
SPECIMEN:	Right breast tissue		
Tumor Site:	Right breast		
Tumor Size:	Unilocular cyst measures 5.2x5.1x5 cm. papillary projection made at one focus and focus measured 0.6x0.5cm, other focus measures 0.5x0.4cm		
Margins:	Tumor has margin clearance superior - 2.5cm, Inferior - 3.5cm, Medial - 1.5cm, lateral - 1cm Deep cut margin - 10.2cm.		
Extent:	Nipple areolar complex is 3cm away from tumor overlying skin - 1cm away from tumor		
MICROSCOPY			
Histologic Type:	Intracystic papillary carcinoma with micro-invasion		
Histologic Grade:	GRADE I		
MARGINS:	Superior, Inferior, medial, lateral and deep cut margins are uninvolved by tumor.		
Extent:	Nipple areolar complex and skin overlying tumor are uninvolved by tumor.		
Lymphovascular Invasion:	Not Identified		
Perineural Invasion:	Not identified		
Lymph node Status:	Not sampled		
Pathological Staging:	PT ₃ N ₀ M ₀		
		Dr. VINITA MALAICHAMY MD (PATH) Reg. No. 21226 Senior Asst. Professor of Pathology CMC	

Figure 5

III. Discussion

Intracystic breast carcinoma is rare in females and exceedingly rare in males with a handful of case reports in the literature. The IPC is more frequently found among postmenopausal woman with an average age between 55 and 67 years old [5]. Many cases were also described in the male population in the literature, and it is the second men's breast cancer [6, 7]. IPC in man is usually reported among those of an older age group (67 to 84 years) [3]; however, in our patient, IPC developed significantly in younger age.

Histologically, IPC is divided into 3 subgroups. Pure IPC, IPC associated with DCIS, and IPC associated with invasive carcinoma. Most patients with IPC have associated ductal carcinoma in-situ (DCIS), or invasive carcinoma, or both and the treatment strategies differ on the basis of this associated pathology [8]. Hill and Yeh, using myoepithelial cell staining, suggest a spectrum of progression from in situ disease to invasive disease, signifying that what appears to be DCIS on histology may potentially cause distant metastases [9]. The lack of an intact basal myoepithelial cell layer can be identified by calponin, smooth-muscle myosin heavy chain (SMM-HC) cytoplasmic stain, and by p63 nuclear stains. This "gold standard" method has a relatively high sensitivity and denotes the invasiveness of the tumor cells in malignant papillary breast lesions [9].

The diagnosis of IPC of the male breast should be made carefully. Triple assessment is essential (clinical examination and radiological and histological assessment). IPC tends to be well defined on mammography; an irregular margin suggests the presence of invasion [10]. Ultrasonography typically reveals a hypoechoic area (representing the cyst) with soft tissue echoes projecting from wall of the cyst (intracystictumor) [11]. Contrast-enhanced MRI may show marked enhancement of cyst walls, septations, and mural nodules [12].

Fine-needle aspiration cytology and core biopsy are usually performed; however, the false negative results with cytology are relatively frequent [13]. Therefore, excisional biopsy should be carried out in all cystic

lesions of the male breast which are suspicious on any of the above diagnostic modalities. The surgical excision allows the pathologist to classify the papillary lesion by classical histological examination and especially with immunohistochemical study and to research invasion or DCIS in surroundings breast tissues, present in majority of cases [14].

There are no evidence-based guidelines for treatment of IPC. There is no randomized controlled trial comparing breast conserving surgery to mastectomy. However, many case reports and retrospective studies showed excellent prognosis with conservative surgery without axillary dissection in IPC not associated to DCIS or microinvasion lesions [2, 8, 15]. Sentinel node biopsy may be an excellent alternative to full axillary dissection in patients with IPC and associated invasive carcinoma [2]. Cutuli et al. were reported 31 male cases of ductal carcinoma in situ of the breast. Six of the 31 cases underwent lumpectomy and 25 mastectomies. All cases had negative nodes. Relapse-free survival was 83% at 10 years, since four cases had local relapse [16]. Lefkowitz et al. [17] reported 77 female cases invasive or non-invasive IPC of the breast. These cases had been treated with excisional biopsy or mastectomy and had a 10-year disease-free survival rate of 91%.

There is also, lack of evidence about the role of adjuvant therapy. Fayanju et al. reviewed the management of 45 patients with IPC in order to determine factors associated with the use of adjuvant therapy [8]. In this study, authors concluded that the most important factor determining the use of radiation and endocrine therapies is associated pathology (DCIS or microinvasion) and patients with pure IPC were less likely to undergo radiation and endocrine therapies. In their retrospective review of the treatment and outcome of 40 patients with IPC, Solorzano et al. observed that 30% of the patients had received adjuvant radiotherapy. The addition of radiation to the treatment of patients did not change the incidence of local recurrence or the likelihood of death compared to those who did not receive radiation [2]. Grabowski et al. confirmed that the addition of hormonal treatment does not appear to have impacted the outcome [7].

IV. Conclusion

IPC of male breast is an extremely rare entity with favorable prognosis. Clinical and radiologic manifestations of IPC are not specific. On ultrasonography, it can be a pure cyst, a mixed image, or a solid mass. Pathologic diagnosis can be difficult at classical histological examination and identification of myoepithelial cells layer by immunohistochemical study can be useful. The mainstay of treatment is surgical resection, with adjuvant therapy if associated to DCIS or invasive carcinoma.

References

- [1]. W. F. Anderson and S. S. Devesa, "In situ male breast carcinoma in the Surveillance, Epidemiology, and End Results database of the National Cancer Institute," *Cancer*, vol. 104, no. 8, pp. 1733–1741, 2005. View at: Publisher Site | Google Scholar
- [2]. C. C. Solorzano, L. P. Middleton, K. K. Hunt et al., "Treatment and outcome of patients with intracystic papillary carcinoma of the breast," *American Journal of Surgery*, vol. 184, no. 4, pp. 364–368, 2002. View at: Publisher Site | Google Scholar
- [3]. S. Sinha, R. G. Hughes, and N. G. Ryley, "Papillary carcinoma in a male breast cyst: a diagnostic challenge," *Annals of the Royal College of Surgeons of England*, vol. 88, no. 5, article 453, 2006. View at: Google Scholar
- [4]. L. Romics Jr., M. E. O'Brien, N. Relihan, F. O'Connell, and H. P. Redmond, "Intracystic papillary carcinoma in a male as a rare presentation of breast cancer: a case report and literature review," *Journal of Medical Case Reports*, vol. 3, article 13, 2009. View at: Publisher Site | Google Scholar Salem, K. Mrad, M. Driss, R. Hamza, and N. Mnif, "Intracystic papillary carcinoma of the breast," *Journal de Radiologie*, vol. 90, no. 4, pp. 515–518, 2009. View at: Publisher Site | Google Scholar
- [5]. J. Levêque, E. Watier, T. Lesimple, F. Goyat, and J. Y. Grall, "Intracystic breast carcinoma," *Journal de GynecologieObstetrique et Biologie de la Reproduction*, vol. 27, no. 3, pp. 329–332, 1998. View at: Google Scholar
- [6]. J. Grabowski, S. L. Salzstein, G. R. Sadler, and S. Blair, "Intracystic papillary carcinoma: a review of 917 cases," *Cancer*, vol. 113, no. 5, pp. 916–920, 2008. View at: Publisher Site | Google Scholar
- [7]. O. M. Fayanju, J. Ritter, W. E. Gillanders et al., "Therapeutic management of intracystic papillary carcinoma of the breast: the roles of radiation and endocrine therapy," *American Journal of Surgery*, vol. 194, no. 4, pp. 497–500, 2007. View at: Publisher Site | Google Scholar
- [8]. C. B. Hill and I. T. Yeh, "Myoepithelial cell staining patterns of papillary breast lesions: from intraductal papillomas to invasive papillary carcinomas," *American Journal of Clinical Pathology*, vol. 123, no. 1, pp. 36–44, 2005. View at: Publisher Site | Google Scholar Estabrook, T. Asch, F. Gump, S. J. Kister, and P. Geller, "Mammographic features of intracystic papillary lesions," *Surgery Gynecology and Obstetrics*, vol. 170, no. 2, pp. 113–116, 1990. View at: Google Scholar M. Jones and J. W. Bradbeer, "The presentation and progress of macroscopic breast cysts," *British Journal of Surgery*, vol. 67, no. 9, pp. 669–671, 1980. View at: Google Scholar
- [9]. M. S. Soo, M. E. Williford, R. Walsh, R. C. Bentley, and P. J. Kornguth, "Papillary carcinoma of the breast: Imaging findings," *American Journal of Roentgenology*, vol. 164, no. 2, pp. 321–326, 1995. View at: Google Scholar
- [10]. P. H. Levine, J. Waisman, and G. C. H. Yang, "Aspiration cytology of cystic carcinoma of the breast," *Diagnostic Cytopathology*, vol. 28, no. 1, pp. 39–44, 2003. View at: Publisher Site | Google Scholar
- [11]. L. C. Collins and S. J. Schnitt, "Papillary lesions of the breast: selected diagnostic and management issues," *Histopathology*, vol. 52, no. 1, pp. 20–29, 2008. View at: Publisher Site | Google Scholar
- [12]. D. Carter, S. L. Orr, and M. J. Merino, "Intracystic papillary carcinoma of the breast. After mastectomy, radiotherapy or excisional biopsy alone," *Cancer*, vol. 52, no. 1, pp. 14–19, 1983. View at: Google Scholar
- [13]. B. Cutuli, J. M. Dilhuydy, B. De Lafontan et al., "Ductal carcinoma in situ of the male breast. Analysis of 31 cases," *European Journal of Cancer A*, vol. 33, no. 1, pp. 35–38, 1997. View at: Publisher Site | Google Scholar

- [14]. M. Lefkowitz, W. Lefkowitz, and E. S. Wargotz, "Intraductal (intracystic) papillary carcinoma of the breast and its variants: a clinicopathological study of 77 cases," *Human Pathology*, vol. 25, no. 8, pp. 802–809, 1994. View at: [Publisher Site](#) | [Google Scholar](#)

Dr. Sree Vijayaraj.AR, et. al. "Intracystic Papillary Carcinoma of the Breast in a Male Patient: A Case Report and Review of Literature." *IOSR Journal of Dental and Medical Sciences (IOSR-JDMS)*, 19(10), 2020, pp. 13-18.