

Pseudoexfoliation Syndrome: Prevalence in patients with cardiovascular disease

Dr. Alla Venkata Pitchi Reddy¹, Dr. Narra Hema Sree², Dr. Vuyyuru Raja Sekhar³,
Dr. G. Ravi Babu⁴

¹ Assistant professor of Ophthalmology, Government General Hospital, Guntur Medical College, Guntur.

² Postgraduate of Ophthalmology, Government General Hospital, Guntur Medical College, Guntur.

³ Assistant professor of Ophthalmology, Government General Hospital, Guntur Medical College, Guntur.

⁴ Professor of Ophthalmology, Government General Hospital, Siddhartha Medical College, Vijayawada, AP, India.

Corresponding author- Dr. Narra Hema Sree² PG of Ophthalmology, Government General Hospital, Guntur Medical College, Guntur-522001, AP, India.

Abstract:

Aim: There is increasing evidence of the association of pseudoexfoliation syndrome and cardiovascular diseases. The objective of the study is to determine the prevalence of Pseudoexfoliation in cardiovascular patients.

Materials and Methods: The study was conducted in 50 patients over 40 years of age attending to ophthalmology op with cardiovascular disease, having an abnormal ECG or angiographic findings for 6 months from October 2018 to March 2019. They were enquired about a history of hypertension, angina, MI, cardiomyopathy, and drugs for cardiac illness and examined for Pseudoexfoliation by slit-lamp after complete pupillary dilatation.

Results: Prevalence of Pseudoexfoliation increased with age, higher in women. The prevalence of Pseudoexfoliation in cardiac patients was found to be 10%. It is more in patients with a history of angina and cardiomyopathy.

Conclusion: The prevalence of pseudoexfoliation syndrome in patients with cardiovascular disease was found to be 10%, which is higher when compared to normal individuals.

Keyword: Cardiovascular disease, Pseudoexfoliation syndrome.

Date of Submission: 10-11-2020

Date of Acceptance: 25-11-2020

I. Introduction

Pseudoexfoliation syndrome (PEX) is a stress-induced microfibrilopathy commonly observed in older-aged patients.[1,2] Extracellular material (EM) has been shown on the anterior lens capsule and pupillae, as well as in the conjunctiva, cornea, trabeculum, iris, ciliary body, the front surface of the vitreous, posterior ciliary arterial walls, vortex veins, central retinal artery, optic nerve sheaths, orbital connective tissue septum, extraocular muscles, and eyelid skin.[2,3] The presence of EM has been shown not only in the eyes but also in the heart, lungs, liver, kidneys, and meninges by using light/electron microscopes and immunohistochemical/biochemical methods.[4] Complications associated with secondary glaucoma, cataract, and cataract surgery may develop in the eyes of PEX patients, the frequent occurrence of hypertension (HT), angina, myocardial infarction (MI), stroke, hearing loss, and retinal vein thrombosis in PEX cases suggests the systemic feature of PEX.[2,3] These findings have led to the hypothesis that PEX is more likely a systemic disorder with multiple clinical manifestations.

Epidemiology

PEX syndrome's prevalence demonstrates considerable geographic, ethnic, and racial variation.[5] Low PEX syndrome rates (< 6% in patients older than 70 years) have been reported in Greenland Eskimos, India, the eastern part of the United States, Germany, Britain, Australia, Japan, Austria, Denmark, and Switzerland. In contrast, high PEX syndrome frequencies (> 15%) have been reported in Iceland, Finland, Russia, Tunisia, Saudi Arabia, Sweden, Norway, Turkey, and Greece.[6,7,8]

Etiopathogenesis

PEX syndrome is inherited as an autosomal dominant trait with late-onset and incomplete penetrance.[9] PEX etiopathogenesis involves both genetic and non-genetic factors. Single-nucleotide polymorphisms (SNPs) in the coding region of the lysyl-oxidase-like 1 (LOXL1) gene on chromosome 15q24, which is responsible for cross-linking of elastin, have been identified as strong genetic risk factors for PEX syndrome and

PEX glaucoma.[10,11,12] LOXL1 is known to bind to tropoelastin monomers and assists in the formation of elastin fibers in the extracellular matrix. Available data suggest that the upregulation of LOXL1 during the early stages of PEX fibrogenesis results in the aggregation of abnormal fiber deposits, while the decreased expression of LOXL1 during the advanced stages of the disease can affect elastin metabolism and promote elastotic processes that predispose to the development of glaucoma and other disorders.[13]

Moreover, non-genetic factors, including ultraviolet light exposure, dietary factors, infectious agents, and trauma, as well as oxidative stress, hypoxia, and inflammation, have been suggested to act as co-modulating external factors.

II. Materials and methods

A Cross-sectional Study was conducted in 50 cardiovascular patients over 40 years age group attending the cardiology op or admitted in the department of cardiology and patients attending to ophthalmology op with cardiovascular disease, i.e., having an abnormal ECG or abnormal angiographic or abnormal echocardiographic findings over a period of 6 months from December 2018 to May 2019.

Study Design: Cross-sectional study.

Study Location: This was a tertiary care teaching hospital-based study done in the Department of Ophthalmology at Government General Hospital, Guntur, Andhra Pradesh.

Study Duration: December 2018 to May 2019.

Study Duration: December 2018 to May 2019.

They were enquired about the history of hypertension and antihypertensive medications, angina, myocardial infarction, cardiomyopathy, and usage of cardiac drugs.

Sample size: 50 patients.

Inclusion criteria:

- 1.Cardiovascular patients (abnormal ECG, angiographic, echocardiographic findings)
- 2.Patients above 18 years of age

Exclusion criteria:

- 1.patients above 70 years of age
- 2.Patients in whom general condition not permissible for examination
- 3.patients less than 18 years of age
- 4.patients who didnot give consent for the study

Cardiovascular patients, after taking informed consent, were examined. The examination included Visual acuity testing using the Snellen chart, anterior segment examination with slit-lamp biomicroscopy after complete pupillary dilatation, fundus examination. The IOP was measured by using the Goldmannapplanation tonometer. Indirect gonioscopy, visual field testing with Humphrey field analyzer was carried out in patients with raised intraocular pressure. The results were analyzed statistically.

III. Results

Out of 50 patients suffering from different cardiovascular diseases,22 were males, and 28 were females.

After examination, Pseudoexfoliation is seen in 5 patients.

Of them, the majority were above 50 years of age group.

Patients of age group 41-50,51-60,61-70,71-80 years are 10,14,22,4 respectively.

Prevalence increased gradually with increasing age group.

Table no1:INCREASING RISK OF PEX PREVALENCE WITH AGE

AGE GROUP(Yr)	NO.OF PATIENTS	NO.OF PATIENTS WITH PEX	PREVALENCE OF PEX (%)
41-50	10	0	0%
51-60	14	1	7.1%
61-70	22	3	13.6%
71-80	4	1	25%

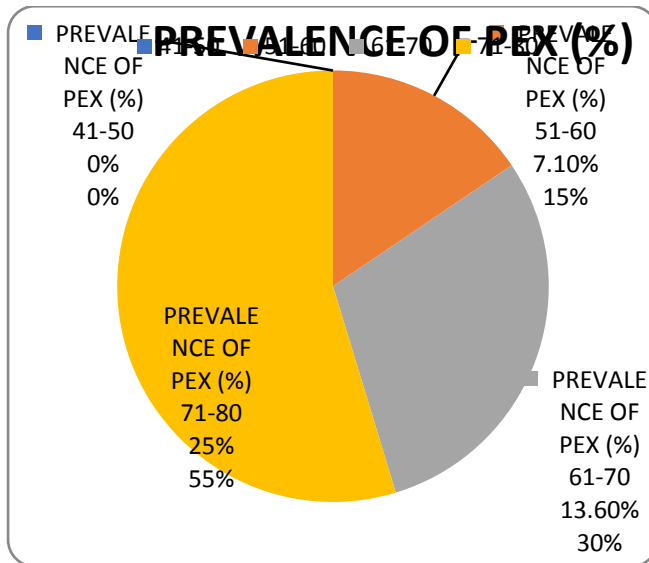


Table no2: CARDIOVASCULAR DISEASES ASSOCIATED

CO MORBIDITY	NO.OF PATIENTS
HYPERTENSION	4
CAD	0
BOTH HYPERTENSION AND CAD	46

Out of 5 patients having Pseudoexfoliation, one patient had open-angle glaucoma.

IV. Discussion

Several studies have correlated PEX syndrome with arterial hypertension.[14]

In Australia, the Blue Mountains Eye Study proposed that a history of angina, hypertension, or a combined history of angina, acute myocardial infarction, and stroke are significantly associated with the presence of PEX syndrome after multivariate adjustment including age, sex, glaucoma, and vascular risk factors.[15] This was attributed to the effect of elastosis in the vessel wall.

Citirik et al. found a significantly higher prevalence of PEX in 50 patients with coronary artery disease (CAD) proven by angiography than in healthy controls and a higher prevalence of CAD in PEX individuals.[16] PEX has been positively associated with the presence of CAD among a large cohort of patients scheduled for cataract surgery.

Andrikopoulos et al. also demonstrated that PEX was positively associated with the risk of CAD in patients of 50 years or older.[17]

More recently, French et al. reported significant associations of PEX and PEX glaucoma with a variety of cardiovascular disorders, including various stages of ischemic heart disease, cardiomyopathy, and aortic aneurysm. Moreover, subclinical myocardial ischemia, by tissue Doppler echocardiography, has been found in PEX patients.

Brajkovic et al. examined the association between PEX and various cardiovascular diseases such as hypertension, arrhythmias, CAD, diabetes, and cerebrovascular events, and only the prevalence of arrhythmia was found to be higher in patients with PEX syndrome.[18]

The possibility of an association between PEX and asymptomatic myocardial diastolic dysfunction (an important cause of heart failure), as assessed by two-dimensional echocardiography and pulsed Doppler echocardiography, has been suggested. In addition, a higher prevalence of heart failure has been described in PEX individuals in previous studies.

In the present study, there is a significant association between Pseudoexfoliation and cardiovascular diseases. Hypertension was most commonly associated. The prevalence of Pseudoexfoliation increased from 5% in the normal population to 10% in cardiovascular patients. The prevalence of pseudoexfoliation syndrome increased gradually with an increase in age group, i.e., from 7.1% in 51-60 years to 25% in 71-80 years age group. Pseudoexfoliation is the most common cause of open-angle glaucoma, and one patient out of 5 had open-angle glaucoma (20%) in our study.

V. Conclusion

Although more data is still required, an increased prevalence of PEX in cardiovascular disorder patients and several common features in their pathogenesis suggest that PEX may be an independent risk factor for cardiovascular disease, or it may occur as part of a systemic disorder with cardiovascular implications. The pathogenesis of PEX glaucoma and CAD in PEX patients may reflect different manifestations of the same process. Patients with PEX syndrome should be informed and examined frequently as cardiovascular risk may be present throughout

References

- [1]. Dewundara S, Pasquale LR. Exfoliation syndrome: a disease with an environmental component. *Curr Opin Ophthalmol*. 2015;26(2):78–81.
- [2]. Anastasopoulos E, Founti P, Topouzis F. Update on pseudoexfoliation syndrome pathogenesis and associations with intraocular pressure, glaucoma and systemic diseases. *Curr Opin Ophthalmol*. 2015;26(2):82–89.
- [3]. amarai V, Samarei R, Haghighi N, Jalili E. Sensory-neural hearing loss in pseudoexfoliation syndrome. *Int J Ophthalmol*. 2012;5(3):393–396.
- [4]. Schlotzer-Schrehardt UM, Koca MR, Naumann GO, Volkholz H. Pseudoexfoliation syndrome. Ocular manifestation of a systemic disorder? *Arch Ophthalmol*. 1992;110:1752–6.
- [5]. Ringvold A. Epidemiology of the pseudo-exfoliation syndrome. *Acta Ophthalmol Scand*. 1999;77:371–375.
- [6]. Forsius H, Forsman E, Fellman J, Eriksson AW. Exfoliation syndrome: frequency, gender distribution and association with climatically induced alterations of the cornea and conjunctiva. *Acta Ophthalmol Scand*. 2002;80(5):478–484.
- [7]. Forsius H. Prevalence of pseudoexfoliation of the lens in Finns, Lapps, Icelanders, Eskimos, and Russians. *Trans Ophthalmol Soc U K*. 1979;99(2):296–298.
- [8]. Aasved H. Prevalence of fibrilloglioneuroepitheliocapsularis (pseudoexfoliation) and capsular glaucoma. *Trans Ophthalmol Soc U K*. 1979;99(2):293–295.
- [9]. Forsman E, Cantor RM, Lu A, Eriksson A, Fellman J, Järvelä I, et al. Exfoliation syndrome: Prevalence and inheritance in a subsample of the Finnish population. *Acta Ophthalmol Scand*. 2007;85:500–7.
- [10]. Thorleifsson G, Magnusson KP, Sulem P, Walters GB, Gudbjartsson DF, Stefansson H, et al. Common sequence variants in the LOXL1 gene confer susceptibility to exfoliation glaucoma. *Science*. 2007;317:1397–400.
- [11]. Aragon-Martin JA, Ritch R, Liebmann J, O'Brien C, Blaaow K, Mercieca F, et al. Evaluation of LOXL1 gene polymorphism in exfoliation syndrome and exfoliation glaucoma. *Mol Vis*. 2008;14:533–41.
- [12]. Mossbock TG, Renner W, Faschinger C. LOXL1 gene polymorphism and exfoliation glaucoma in a Central European population. *Mol Vis*. 2008;14:857–61.
- [13]. Schlötzer-Schrehardt U. Genetics and genomics of pseudoexfoliation syndrome/glaucoma. *Middle East Afr J Ophthalmol*. 2011;18:30–6.
- [14]. French DD, Margo CE, Harman LE. Ocular pseudoexfoliation and cardiovascular disease: a national cross-section comparison study. *N Am J Med Sci*. 2012;4:468–473.
- [15]. Mitchell P, Wang JJ, Smith W. Association of pseudoexfoliation syndrome with increased vascular risk. *Am J Ophthalmol*. 1997;124:685–7.
- [16]. Citirik M, Acaroglu G, Batman C, Yildiran L, Zilelioglu O. A possible link between the pseudoexfoliation syndrome and coronary heart disease. *Eye (Lond)* 2007;21:11–5.
- [17]. Andrikopoulos GK, Mela EK, Georgakopoulos CD, Papadopoulos GE, Damelou AN, Alexopoulos DK, et al. Pseudoexfoliation syndrome prevalence in Greek patients with cataract and its association to glaucoma and coronary artery disease. *Eye (Lond)* 2009;23:442–7.
- [18]. Ercegovia A, Brajkovic J, Surac IK, Haluzan MB. Prevalence, distribution and types of corneal astigmatism in cataract surgery patients in Sibenik County. *Acta Clin Croat*. 2012;51:275–8.

Dr. NarraHemaSree, et. al. "Pseudoexfoliation Syndrome: Prevalence in patients with cardiovascular disease." *IOSR Journal of Dental and Medical Sciences (IOSR-JDMS)*, 19(11), 2020, pp. 28-31.