

## Chest X-ray findings in COVID-19

Dr. T.S.S.L.Pratyusha<sup>1</sup>, Prof.K.V.V.Vijaya Kumar M.D.,<sup>2</sup>Dr.V.Surya Kumari M.D.,<sup>3</sup>Dr.B.Padmaja M.D.,<sup>4</sup> V.Triveni<sup>5</sup>

<sup>1</sup>Post Graduate, Department of pulmonary medicine, Andhra Medical College, Visakhapatnam

<sup>2</sup> Professor and Head of the Department, Department of pulmonary medicine, Andhra Medical College, Visakhapatnam

<sup>3</sup> Associate Professor, Department of pulmonary medicine, Andhra Medical College, Visakhapatnam

<sup>4</sup> Assistant Professor, Department of pulmonary medicine, Andhra Medical College, Visakhapatnam

<sup>5</sup> Post Graduate, Department of Community Medicine, Andhra Medical College, Visakhapatnam

### Abstract:

**Background:** SARS-CoV-2 virus is a beta corona virus and the disease caused by this is the COVID-19. The disease was declared as a pandemic on March 11, 2020 by WHO. Though Chest X-ray is not a sensitive tool in the early stage of the disease, it is a very useful diagnostic tool to monitor the rapid progression of the disease.

**Materials and Methods:** In this prospective randomised controlled study, 102 patients were included based on the inclusion and exclusion criteria. A chest X-ray was obtained from the patient at the time of admission and the radiological findings were statistically analysed.

**Results:** Among the 102 recruited patients, 72.54% were males, the common age group affected was between 41-60 years (52.94%). Bilateral involvement (70.5%) was more than right or left lobar involvement. Reticulonodular opacities (45.09%) was the most common among the radiological findings observed.

**Conclusion:** Males were predominant than females, reticulonodular opacities with basal, peripheral and bilateral predominance was frequently observed in COVID-19 patients in the present study.

**Key Word:** SARS-CoV-2, COVID-19, Reticulonodular opacities

Date of Submission: 01-15-2020

Date of Acceptance: 15-12-2020

### I. Introduction

The world is amidst a pandemic that is presenting one of the greatest public health challenges of the twenty-first century. Since its emergence the new corona virus has resulted in 43.7 million infections and over 1 million deaths as of October 25, 2020, among these 20% of the deaths have occurred in the United States followed by Brazil (14%), India (10%), Mexico (7.8%) and the United Kingdom (4%)<sup>1</sup>. The virus was officially named the Severe Acute Respiratory Syndrome coronavirus 2 (SARS-CoV-2) and the disease caused by this as Coronavirus Disease 2019, or COVID-19<sup>2</sup>. In less than two months, SARS-CoV-2 went from a public health emergency to a disease of pandemic status, declared such on March 11, 2020, by WHO<sup>3</sup>. Severe acute respiratory syndrome coronavirus 2 (SARSCoV-2) is a beta corona virus, given the mortality rate of this disease, physicians should be aware of the potential risk factors associated with a fatal outcome. The disease has a geographical impact on 213 countries (two international conveyances), with an incubation period ranging from 2-14(5.2) days. The patient can be asymptomatic or pre-symptomatic during the infectious period. The speed of transmission of the disease is high compared to SARS and MERS. The rate of transmission ( $R_0$ ) is 2.0-2.5. Although chest x-ray is not considered as a sensitive tool for the detection of pulmonary involvement in the early stage of the disease, in the current emergency scenario, this can be a very useful diagnostic tool to monitor the rapid progression of the disease especially in the intensive care units.

### II. Materials And Methods

This prospective study was carried out on the patients admitted in the Department of Pulmonary Medicine at Andhra Medical College, Visakhapatnam, Andhra Pradesh in the month of July 2020. A total 102 patients of aged  $\geq 18$ , years were included in the present study.

**Study Design:** Prospective open label observational study

**Study Location:** This was a tertiary care teaching hospital based study done in Department of Pulmonary Medicine at Andhra Medical College, Visakhapatnam, Andhra Pradesh.

**Study Duration:** One month (July 2020)

**Sample size:** 102 patients.

**Subjects & selection method:** The study population is drawn from the patients admitted in the isolation wards and ICU care settings in the Department of Pulmonary Medicine, Andhra Medical College in the month of July 2020.

**Inclusion criteria:**

1. Patients who were nasopharyngeal swab positive for covid-19.
2. Who were consenting to the study.
3. Patient's age more than 18 years

**Exclusion criteria:**

1. Patients who were not consenting for the study
2. Whose age was <18 years old.

**Procedure methodology:**

After written informed consent was obtained, the patients were included based on the inclusion and exclusion criteria. All the patients were subjected to chest X-ray.

**Image acquisition and analysis:**

All the Chest X-rays were acquired as digital radiographs with the X-ray unit in the department and were performed in the postero-anterior or antero-posterior projection. Radiographic features including consolidation, reticulonodular opacities, pleural effusion, ground glass opacities and pulmonary nodules were diagnosed according to the Fleischer Society glossary of terms<sup>4</sup>. Chest X rays were assessed for distribution of the disease as unilateral (right or left) or bilateral disease and also observed for the presence of the pleural effusion, pneumothorax, cardiomegaly

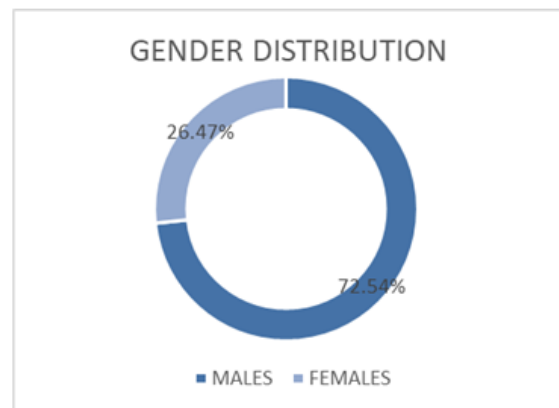
**Statistical analysis:**

Data was analyzed using Microsoft EXCEL sheet.

**III. Results**

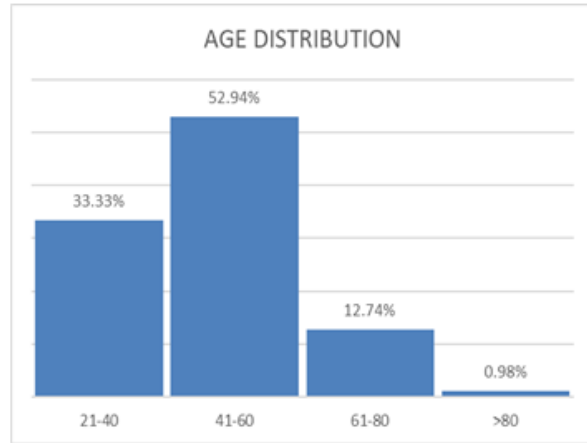
Among the 102 patients recruited in the present study, 72.54% were males and 26.47% were females with preponderance to males.

GENDER	PERCENTAGE
MALES	72.54%
FEMALES	26.47%



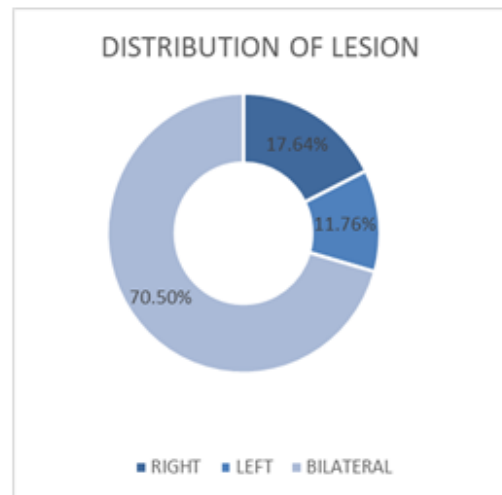
The common age group affected in the study population was among the 41-60 years age group with a range of 21-81 years.

AGE GROUP	PERCENTAGE
21-40	33.33%
41-60	52.94%
61-80	12.74%
>80	0.98%



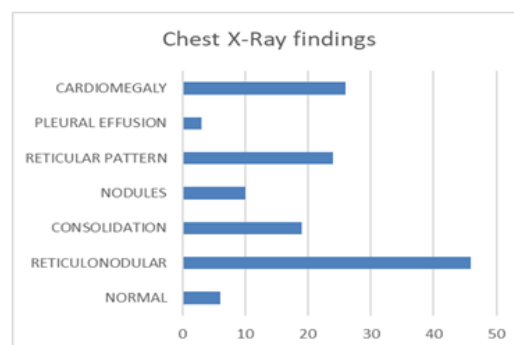
The distribution of the lesion was 17.64% on the right side, 11.76% on the left side and 70.5% involving bilaterally.

DISTRIBUTION OF LESION	PERCENTAGE
RIGHT	17.64%
LEFT	11.76%
BILATERAL	70.5%



The radiological findings observed in the patients with COVID-19 were reticulonodular opacities (45.09%), reticular pattern (23.52%), consolidation (18.62%), nodules (9.8%), pleural effusion (2.94%) and cardiomegaly in (25.49%). 5.88% of the patients had a normal chest x-ray.

RADIOLOGICAL FINDING	PERCENTAGE
NORMAL CXR	5.88%
RETICULONODULAR OPACITIES	45.09%
CONSOLIDATION	18.62%
RETICULAR PATTERN	23.52%
NODULES	9.8%
PLEURAL EFFUSION	2.94%
CARDIOMEGALY	25.49%



#### IV. Discussion

In the context of a global pandemic, the radiological approach should be aimed at a rapid classification of the patient with suspected COVID-19 infection. The CXR serves as a first-line imaging tool and reserves to chest CT and other additional roles as the identification of the typical features of COVID-19 pneumonia in selected cases. A portable X-ray machine is very useful, inexpensive, and radiographs can be obtained at the patient's bedside which minimizes the risk of cross-infection. The present study confirms the radiological characteristics in COVID-19 patients which were described in previous studies. In most of the cases CXR shows patchy or diffuse reticulonodular opacities and consolidation, with basal, peripheral and bilateral predominance. If there is a unilateral involvement, the right lung is more affected than the left lung. The CXR was performed at the time of admission or in the first 2 days of hospitalization to isolation wards and ICU. The role of CXR in clinical monitoring of these patients, especially for those who were admitted in the ICU is still on debate: the Fleischner society do not recommend daily CXR in stable intubated patients, but the progress of the disease occurs very quickly<sup>5</sup>. The radiological imaging should always be associated with clinical and biochemical parameter while monitoring the disease course.

#### V. Conclusion

Males were more affected than females and the reticulonodular opacities with basal, peripheral and bilateral predominance is frequently observed in COVID-19 patients in the present study.

#### References

- [1]. Johns Hopkins University. Coronavirus Resource Center. October 9, 2020. Johns Hopkins University. <https://coronavirus.jhu.edu/map.html>. Accessed October 9, 2020.
- [2]. Center for Health Security. SARS-CoV-2 Genetics. Johns Hopkins Bloomberg School of Public Health. April 16, 2020.
- [3]. World Health Organization. WHO Director-General's Opening Remarks at the Media Briefing on COVID-19. Geneva: World Health Organization; 2020
- [4]. Hansell DM, Bankier AA, MacMahon H et al (2008) Fleischner Society: glossary of terms for thoracic imaging. *Radiology* 246(3):697–722. <https://doi.org/10.1148/radiol.2462070712>
- [5]. Rubin GD, Ryerson CJ, Haramati LB et al (2020) The role of chest imaging in patient management during the COVID-19 pandemic: a multinational consensus statement from the Fleischner Society. *Radiology*. <https://doi.org/10.1148/radiol.2020201365>

Dr. T.S.S.L.Pratyusha, et. al. "Chest X-ray findings in COVID-19" *IOSR Journal of Dental and Medical Sciences (IOSR-JDMS)*, 19(12), 2020, pp. 01-04.