

A Prospective Study To Evaluate The Accuracy Of Axillary Staging Using Ultrasound And USG-Guided Fine Needle Aspiration Cytology In Early Breast Cancer Patients In A Tertiary Level Centre In North East India

Dr. Ashwin M¹, Dr. S. Opendro Singh², Dr. Sinkhol Laishram³, Dr. Mingge Pertin¹, Dr. Soumen Das¹, Dr. Resen Rajan SMethikkalam¹

¹(PGT, Department of General Surgery, Regional Institute of Medical Sciences, Imphal, India)

²(Assoc. Professor, Department of General Surgery, Regional Institute of Medical Sciences, Imphal, India)

³(Senior Resident, Department of General Surgery, Regional Institute of Medical Sciences, Imphal, India)

Abstract:

Background: Breast cancer is the most common site specific cancer in women and is the leading cause of death from cancer among women aged 20 to 59 years. Its incidence and mortality contribute to a major public health problem. The current goal in oncologic breast surgery is to tailor treatment options to allow optimal care without unnecessary interventions. Breast surgery has steadily evolved from an extensive to a more conservative approach. Axillary lymph node status is the single most significant predictive factor for patients with invasive breast tumours. The preoperative ultrasound (USG) guided fine needle aspiration cytology (FNAC) of axillary metastasis may avoid unnecessary axillary dissections and time consuming and costly sentinel lymph node biopsy.

Aims and Objects: The study aimed to explore the accuracy of ultrasound-guided fine needle aspiration cytology (USG-FNAC) for the evaluation of axillary lymph nodes in patients with early stage breast cancer.

Results: A total of 32 patients with early stage breast cancer were included in the study who underwent curative surgery. Among them 20 cases came to be lymph node positive. The sensitivity, specificity and positive predictive value (PPV) of axillary ultrasound were 66.67%, 95.6% and 85.7%, respectively, while for USG-FNAC, they were 88.8%, 100.0% and 100.0%, respectively. Significant differences were found in specificity, accuracy, and PPV between the 2 procedures ($P < .05$).

Conclusion: Ultrasonography combined with FNAC of axillary lymph nodes is a simple, minimally invasive, and reproducible diagnostic approach in improving the preoperative axillary staging of invasive breast cancer patients. Those who are positive can proceed to axillary lymph node dissection without the need for Sentinel lymph node biopsy.

Key Word: lymph node status; Sentinel lymph node biopsy; ultrasound; ultrasound guided FNAC

Date of Submission: 07-02-2020

Date of Acceptance: 22-02-2020

I. Introduction

Breast cancer is the most common malignancy among women in India and is the second most common cause of cancer death. Early detection with screening mammography and multimodality treatment has reduced the cancer mortality in western countries; however, it still continues to have a high prevalence in the developing countries. Every year more than 75,000 new cases of breast cancer are diagnosed in Indian women, and it is regarded as the most common cancer in women in many metropolitan cities such as New Delhi, Mumbai, Ahmadabad, Kolkata and Trivandrum, and the second most common cancer in the rest parts of the country. In Manipur, it appears to be worst in comparison to world scenario. During 2013, 124 new cases of breast cancer were diagnosed which accounted for 15.9% (124 of 781 cancer cases) of all cancer registration in female of all ages.¹

The most important prognostic factor in breast cancer is lymph node status.² Axillary lymph node metastasis occurs in 30–40% of all patients with breast cancer. Traditionally lymph nodes have been evaluated surgically, either by axillary lymph node dissection or sentinel lymph node biopsy followed by axillary dissection in patients who have positive results. Detection and histologic evaluation of the sentinel node are more accurate and more expensive in terms of both time and money than axillary dissection, but SLNB is

clearly preferable in terms of women's discomfort and functional complications. Axillary dissection must be regarded as overtreatment in patients without node involvement. Surgical excision of lymph nodes is associated with multiple sequelae, such as lymphedema, pain, joint dysfunction, and numbness. Although sentinel lymph node biopsy has fewer sequelae, it still has a significant association with lymphedema.³ In addition; sentinel lymph node biopsy increases the complexity and cost of the surgical procedure and, in some patients, necessitates a second surgery for a completion axillary dissection. Neoadjuvant chemotherapy is now widely employed not only for locally advanced breast cancers, but also for primary breast cancers, and excellent results have been reported.^{4,5} Identifying the presence or absence of axillary LN metastases before and after neoadjuvant chemotherapy may be very important in determining whether or not sentinel LN biopsy is indicated after neoadjuvant chemotherapy. Different methods are used to detect metastases in axillary lymph nodes preoperatively. The imaging tests available are ultrasonography (USG), Magnetic Resonance Imaging, CT scan and Nuclear medicine based imaging.

The physical examination (PE) usually plays an initial role in axilla staging, but its accuracy is limited.⁶ Based on several morphological criteria, axillary ultrasonography (USG) is widely accepted as an elemental test to detect malignant nodes with acceptable sensitivity and specificity.⁷ It visualizes not only alteration in size, shape and contour of the LNs, but also changes in the cortical morphology and texture that can reflect the presence of underlying metastasis. However, sonographic signs of metastatic disease sometimes overlap those of benign reactive changes limiting the ability of this modality alone to accurately stage the axilla.⁸ Multiple reports in the literature suggest that axillary ultrasound (USG) is a potentially valuable technique for identifying axillary metastases.^{9,10} It visualizes not only alteration in size, shape and contour of the LNs, but also changes in the cortical morphology and texture that can reflect the presence of underlying metastasis. However, sonographic signs of metastatic disease sometimes overlap with those of benign reactive changes limiting the ability of this modality alone to accurately stage the axilla.¹¹ The addition of fine needle aspiration cytology (FNAC) has been shown to increase the specificity of nodal staging.¹²⁻¹⁴ Nowadays, with satisfactory accuracy, US combined with fine-needle aspiration cytology (US-FNAC) have been suggested to determine the pathological status of sonographically suspicious nodes to avoid unnecessary axillary dissection.¹⁵⁻¹⁷ Fine-needle aspiration cytology (FNAC) of axillary lymph nodes, typically under ultrasound guidance (US-FNAC), offers a less invasive alternative to sentinel lymph node biopsy.

The procedure can be performed by radiologists, pathologists, or other clinicians. Numerous studies have demonstrated moderate sensitivity and near-perfect specificity of this technique, thus allowing patients with a positive FNAC to proceed directly to axillary lymph node management of the axilla in breast cancer has gradually turned to less-invasive surgery. It has also proved to be the best approach in terms of the cost-benefit ratio among the various diagnostic scenarios.¹⁸ US-FNAC of the axillary lymph nodes may help guide the decision for or against neoadjuvant chemotherapy as well as providing the effectiveness of the therapy.^{19,20}

Hence the present study is being undertaken in our institute to determine the accuracy of ultrasound (USG) and ultrasound guided fine-needle aspiration cytology (US-FNAC) for staging of axilla in primary breast cancer, with a view to select the appropriate management for patients.

II. Material And Methods

This prospective comparative study was carried out on patients of Department of General Surgery attending Regional Institute of Medical Sciences and Hospital, Imphal, Manipur from August 2017 to July 2019. A total of 30 patients were included in this study.

Study design: Prospective observational study.

Study set up: This study was carried out in a tertiary care teaching hospital in the Department of General Surgery (both OPD and IPD), Regional Institute of Medical Sciences, Imphal, Manipur.

Duration of study: 1st August 2017 to 31st July 2019.

Sample size : 30 patients

Sample size calculation : Sample size were calculated using the formula " $n = z^2P(Q)/L^2$ ", where n = sample size, z = constant i.e. 1.96, P = prevalence of breast cancer amongst female in Manipur, Q = (100 - P), L = absolute allowable error at 95% confidence. As per the Population Based Cancer Registry report in 2013, the prevalence of breast cancer amongst female cancer patients is 8.2%.²¹ Degree of precision is 95 and standard error (L) is 10. Then, sample size $n = (1.96)^2 \times 8.2 (100 - 8.2) / 100 = 28.91$. Hence the calculated sample size is

29. The study was to be done on a minimum of 29 cases of breast cancer. However, 32 such patients were admitted and were eligible for the study during the study period. All of them were included in the study.

Subject and selection method: All patients with clinically diagnosed early invasive breast cancer ($T_{0-2} N_{0-1} M_0$) confirmed by FNAC/ Trucut biopsy of primary tumor in the Department of General Surgery during the study period were included.

Inclusion criteria:

1. Pathologically confirmed primary invasive breast cancer
2. Clinical staging $T_{0-2} N_{0-1} M_0$
3. Patients scheduled to undergo MRM/ BCS with axillary dissection
4. Patients giving consent for the study

Exclusion criteria:

1. Tumor size T_{3-4}
2. Nodal status N_{2-3}
3. Bilateral breast pathology
4. In situ carcinoma of breast
5. Aggressive histology type (Inflammatory type)
6. Presence of metastasis
7. Pregnant women
8. Patient(s) with recurrent disease
9. Patient(s) not undergoing surgery
10. Patient(s) not giving consent for the study

Procedure methodology :

All patients attending OPD and admitted in IPD of General Surgery ward of RIMS, with a diagnosis of primary breast cancer, were staged and completely worked up for metastasis. After written informed consent was obtained, a well-designed questionnaire was used to collect the data of the recruited patients. The questionnaire included socio-demographic characteristics such as age, gender, height, weight, side of affected breast, size of primary tumor, histology grade of tumor and axillary node status at presentation- Clinically, Ultrasonographically and US-FNAC. Data from patients without palpable nodes on physical examination (PE) was documented as cN_0 , whereas cN_1 referred to palpable mobile ipsilateral axillary lymph node. Axillary Ultrasound (AUS) was performed in all patients whether they have clinically palpable axillary nodes or not. US guided FNAC (US-FNAC), using a 22G needle from a suspicious lymph node was performed following abnormal US findings (both reactive and malignant findings). Smears of samples were interpreted by our pathologists. All early breast cancer cases got surgical treatment in the form of MRM/ BCS with Axillary clearance. Histopathology was done for all the surgical specimens.

Statistical analysis :

Data analysis was performed using SPSS software 21 version (IBM Corp., Armonk, NY, United States). Socio demographic variables were summarised by descriptive statistics like frequency, percentage and mean whenever appropriate. The Statistical analysis for the association between US and US-FNAC and HPE status of axilla was performed with chi square test and a p-value ≤ 0.05 was considered to be significant.

III. Result

The present study included 32 patients of newly diagnosed cases of early primary breast cancer with clinically negative axilla. After the study period was over the following data were obtained. The age of the patients with primary early breast cancer presented to us were categorized and the following result was obtained.

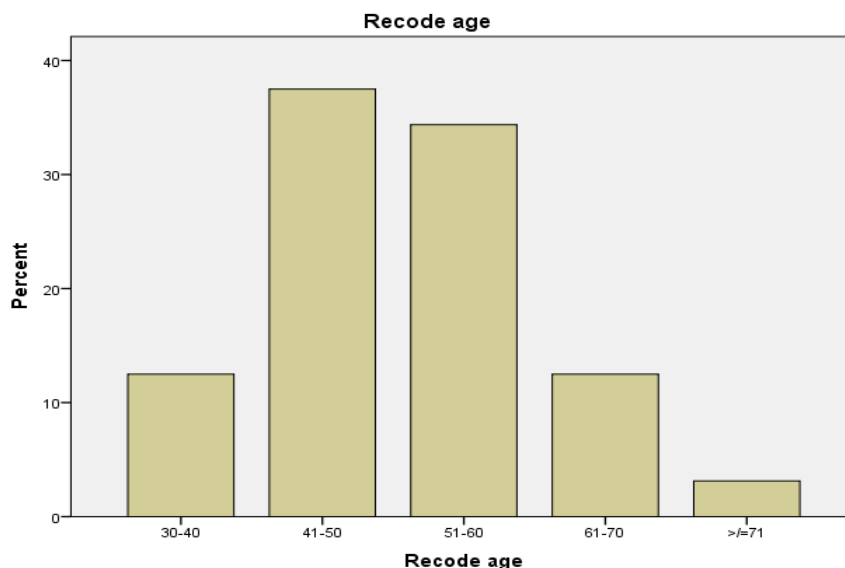


Fig 1: Age distribution pattern in early breast cancer

Present study shows the age of patients ranged from 38 to 71 years, with a mean age group of 51.4(\pm 8.6) years. Maximum number of cases were seen in the age group of 41-50 years (37.5%). All the 32 patients who presented to us during the study period with the diagnosis of primary early breast cancer were Female. Out of 32 cases of breast cancer studied, left breast was found to be more commonly involved comprising of 18 cases (56.3%).

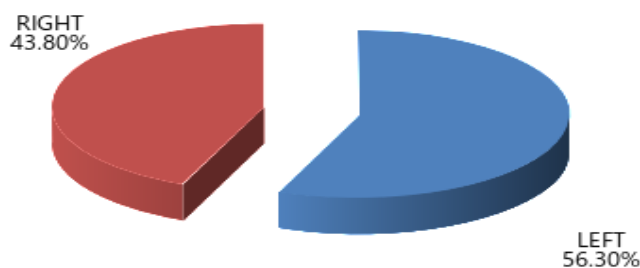


Fig2: Pie diagram showing distribution of breast carcinomas according to side of affected breast

Most of the tumour size were in 2-5 cms group (78.1%) which is pathological T₂ stage followed by pathological T₁ stage as shown below.

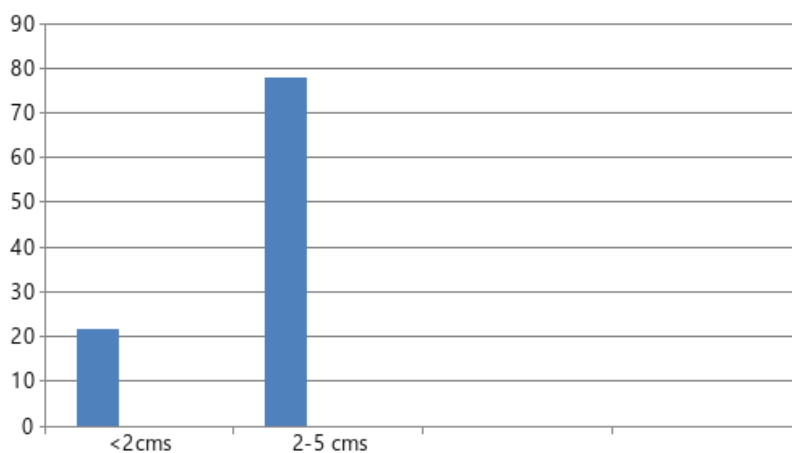


Fig. 3: Bar diagram showing tumour size distribution

Our study US showed 7 suspicious(malignant) lymph nodes (according to different characteristics of lymph nodes in AUS) and 13 benign lymph nodes in 32 study subjects. In 12 cases no enlarged lymph nodes were identified in AUS.

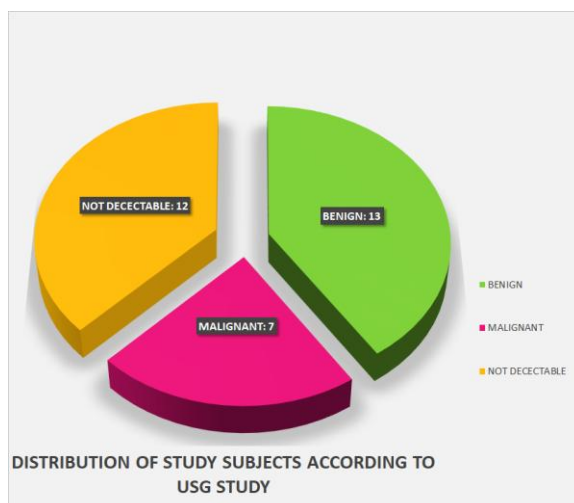


Fig 4: Pie diagram showing distribution of study subjects according to USG category

Among the 7 cases which were suspicious for malignancy in USG, the following characteristics which were defined as suspicious were recorded. The number of cases each characteristic was observed was taken into account. Findings suggestive of malignancy were concentric cortical thickening > 3mm, focal cortical thickening, loss of fatty hilum, loss of round shape (L/T axis < 2), micro calcification and non-hilar blood flow in Doppler. A node was considered suspicious even if any one of the described finding was present.

FINDING IN USG SUSPICIOUS OF MALIGNANCY	No. of Cases
Concentric cortical thickening > 3mm	7
Focal cortical thickening	6
Loss of fatty hilum	5
Loss of and round shape (L/T axis < 2)	7
Micro calcification	1
Nonhilar blood flow in Doppler	6

Table 1: Distribution of study subjects according study subjects according to USG finding

Out of the 32 cases, except for the 12 cases in which Axillary Lymph Nodes were negative, and which proceeded directly to surgery, US-FNAC was done in 20 AUS lymph node detected cases(Suspicious+ Benign). Surgery was done in all 32 of the study subjects. HPE was considered as the Gold Standard for identifying True Positives and True Negatives. HPE results were then correlated with US finding and US-FNAC finding for assessing the efficacy. Among 32 study subjects, HPE of 9 patients came positive for axillary lymph nodes.

ULTRASONOGRAPHY OF AXILLARY LYMPH NODES(USG)	HISTOPATHOLOGY OF AXILLARY LYMPH NODES(HPE)			
		POSITIVE	NEGATIVE	TOTAL
	POSITIVE (SUSPICIOUS/ MALIGNANT)	6	1	7
	NEGATIVE (BENIGN AND NOT DETECTED)	3	22	25
TOTAL	9	23	32	

Table 2: Distribution of study subjects according to USG and HPE status

In our study,among the 32 study subjects,AUS have detected 6 suspicious lymph nodes among the 9 study subjects with positive axillary Lymph Node status in Histopathology. Among 22 USG negative cases, 3 cases

shows positive axillary Lymph Node status in Histopathology. By applying chi-square test, the differences were significant at p value of 0.0001.

Descriptive Statistics:

1. Sensitivity = 66.67%
2. Specificity = 95.6%
3. PPV = 85.7%
4. NPV = 88%

Concentric cortical thickness>3 mm	Histopathology status of axillary lymph node	
	Malignant	Benign
7	6	1
Percentage (100%)	85.7%	14.3%

~~HPE was considered as the Gold Standard for identifying True Positives and True Negatives. Among 32 study subjects, HPE of 9 patients came positive for axillary lymph nodes.~~ **Table 3:** Concentric cortical thickness versus histopathology status of axillary lymph node, n =7

Out of 7 cases which showed Concentric cortical thickness>3 mm in AUS, HPE revealed axillary lymph node malignancy in 85.3 % of study subject and benign axillary lymph node in 14.3% study subject.

Focal cortical thickness	Histopathology status of axillary lymph node	
	Malignant	Benign
6	5	1
Percentage (100%)	83.3%	16.7%

Table 4: Focal cortical thickness versus histopathology status of axillary lymph node, n=6

Total 6 cases showed Focal cortical thickness in AUS, with final histopathology examination showing malignancy in 83.3% % study subject and benign changes in 16.7 % study

Loss of fatty hilum	Histopathology status of axillary lymph node	
	Malignant	Benign
5	4	1
Percentage (100%)	80%	20%

Table 5: Loss of fatty hilum versus of axillary lymph node, n = 5

Total 5 cases showed loss of fatty hilum in AUS, with final histopathology examination showing malignancy in 85.3 % study subject and benign changes in 14.3% study subject.

L/D Ratio<2	Histopathology status of axillary lymph node	
	Malignant	Benign
7	6	1
Percentage (100%)	85.7%	14.3%

Table 6: L/D Ratio<2 versus histopathology status of axillary lymph node, n = 7

Total 7 cases showed L/D Ratio<2 in AUS,with final histopathology examination showing malignancy in 85.3 % study subject and benign changes in 14.3% study subject.

Microcalcification	Histopathology status of axillary lymph node	
	Malignant	Benign
1	1	0
Percentage (100%)	100%	0%

Table 7: Microcalcification versus histopathology status of axillary lymph node, n=1

Only 1 case showed Microcalcification in AUS, with final histopathology examination revealing malignancy in the same.

Non Hilar blood flow	Histopathology status of axillary lymph node	
	Malignant	Benign
6	5	1
Percentage (100%)	83.3%	16.7%

Table 8: Non Hilar blood flow in color Doppler of lymph node versus histopathology status of axillary lymph node, n=6

A total of 6 cases showed Non Hilar blood flow in color Doppler, with final histopathology revealing malignancy in 83.3% % study subject and benign in 16.7 % study subject.

ULTRASOUND GUIDED FNAC OF AXILLARY LYMPH NODES (US-FNAC)	HISTOPATHOLOGY OF AXILLARY LYMPH NODES(HPE)			
		POSITIVE	NEGATIVE	TOTAL
	POSITIVE (MALIGNANT)	8	0	8
	NEGATIVE (BENIGN)	1	11	12
	TOTAL	9	11	20

Table 9: Distribution of study subjects according to US-FNAC and HPE status

Descriptive Statistics:

1. Sensitivity = 88.8%
2. Specificity = 100%
3. PPV = 100%
4. NPV = 91.67%

In the present study, among the 20 study subjects with AUS detected lymph nodes (7 suspicious and 13 benign), 8 study subjects have positive FNAC finding and all 8 had positive Histopathology axillary Lymph Node status. Among 12 FNAC negative subjects, one shows positive Histopathology axillary Lymph Node status.By applying chi-square test, the differences were significant at p value of 0.0001.

IV. Discussion

The most important prognostic factor in breast cancer is axillary lymph node status.The present study was conducted for the assessment of efficacy of ultrasound and guided fine needle aspiration cytology for preoperative evaluation of axillary metastasis in early carcinoma breast. Total 32 patients were assessed, results analysed and the relevant findings were compared with different literatures available on the similar subject. Ultrasound of axilla (AUS) permits the visualization of lymph node size, shape, contour and changes associated

with the presence of axillary metastases. However, sonographic signs in cortical morphology and texture that appear to be metastatic disease sometimes limits the ability of this modality alone to accurately stage the axilla. So, to avoid overlap with those of benign reactive changes and to increase the diagnostic accuracy of the AUS, the tissue diagnosis of that particular lymph node evaluated by AUS was essential and this was achieved by US Guided FNAC.

Age Distribution: The mean age of the study population was 51.4 (± 8.6) years and ranged from 38 years to 71 years. Maximum clustering of cases i.e. 37.5% was observed in the age group 41-50 years. According to Fletcher's Textbook, breast cancer can occur at any age, but incidence is rare in patients younger than 25 years and over 80 years. The peak incidence is between 45 and 60 years.²² In a study in SMS Medical College, Jaipur, Meena et al²³ observed that the average age of the population was 40-49 years. As per the article published by Tanuja Shetty et al²⁴ from TATA Memorial Hospital, Mumbai in 2009 in IJPM, the age of patients in the study ranged from 18-102, giving a mean age of 60 yrs. Hence, in this study the age group for peak frequency of occurrence of breast cancer corroborated with most of the studies.

Distribution according to the side affected: Out of 32 cases of breast cancer studied, left breast was found to be more commonly involved comprising of 18 cases (56.3%). Right breast was involved in 14 cases (43.8%).

Distribution according to the size of the tumor: Out of the 32 cases who presented with early breast cancer most of the tumour size were in 2-5 cm group 25 cases (78.1%) which is pathological T₂ stage followed by pathological T₁ stage 7 cases (21.9%).

Relation between AUS lymph node category and HPE: Of the 32 subjects in this study who had Axillary US, 12 cases had no sonographically visualized nodes in axilla and among the remaining, 13 had lymph nodes with benign criteria and 7 had suspicious axillary lymph nodes by sonographic criteria. Among 7 suspicious lymph nodes, 6 (85.7 %) show metastases deposits, remaining 1 (14.3%) had no metastases deposits in US-FNAC and HPE. Among 25 women with benign axillary lymph nodes and non-detected nodes in AUS, 3 (12%) of these women had metastatic disease identified in HPE and 22 (88 %) had no evidence of metastatic nodal disease in HPE. The sensitivity, specificity, positive predictive value and negative predictive value of AUS in correlation with US guided FNAC was found to be 66.7%, 95.6 %, 85.7 % and 88% respectively in our study. By applying chi-square test, the differences were significant at p value of <0.0001. A Moore et al²⁵ reported in their study in 112 patients that the overall sensitivity and specificity values for sonography alone were 81 % and 69% respectively. Adding fine needle aspiration improved the specificity of US to 100 %, leaving the sensitivity unchanged (82 %). Vaidya et al²⁶ reported results for AUS with high specificity and PPV of 90% each but low sensitivity and NPV of 69% each in predicting axillary metastases. Alvarez et al²⁷ in their study reported sensitivity of 56%, specificity of 77.5%, PPV of 60% and NPV of 74.2% for AUS in predicting axillary metastases. Kebudi²⁸ reported sensitivity, specificity, PPV and NPV for AUS in predicting axillary metastases to be 79.1 %, 77.7 %, 82.6 % and 73.6% respectively. Jung hee shin et al²⁹ reported the sensitivity, specificity and accuracy of ultrasonography in predicting axillary metastases to be 75%, 82.6 % and 78.7 % respectively in their study.

Relation between AUS characteristics of lymph node and HPE: Axillary Lymph nodes were evaluated for specific US characteristics like concentric cortical thickness, L/D ratio, presence or absence of fatty hilum, micro calcification and for non-hilar blood flow. Based on these specific characteristics of USG, lymph nodes were categorized as benign and suspicious. On correlation of specific AUS characteristics with HPE, the sonographic features most predictive of malignancy were Loss of round shape (L/T axis < 2) and concentric cortical thickening > 3mm. Both these features were most predictive and present in 85.7% of malignant lymph nodes. Focal cortical thickening (outward or inward) and Non-hilar blood flow both present in 83.3 % each, were the next best predictors, followed by Loss of fatty hilum present in 80% cases. Even though Micro calcification shows 100% (1 case) chance of malignancy, it is less commonly reported and hence cannot be relied upon. Sousa et al³⁰ reported a 100 % positive predictive value on thickness and non-hilar cortical vascular flow. Concentric cortical thickness of 3 mm to be the most useful predictor of finding of cortical malignancy (Deurloo et al; Mainiero et al)³¹⁻³². Martha B M et al³³ found in their study that the sonographic feature most predictive of a positive USG Guided FNA result was the absence of a fatty hilum. Bedi et al³⁴ suggested that hypoechoic cortex with focal cortical thickening is most predictive of malignancy.

Relation between US guided FNAC of lymph node and HPE: Of the 20 subjects in this study undergoing US guided FNAC of lymph nodes, a total of 8 subjects was positive for malignant changes. All 8 (100 %) showed metastases deposits in final surgical HPE. Whereas 1 of the 12 (8.33%) US guided FNAC negative subject had metastases detected in the axillary lymph nodes in final histopathology. The remaining 11 of the 12 (91.67 %) US-FNAC negative cases had no evidence of metastatic nodal disease on final surgical HPE. The sensitivity, specificity, positive predictive value and negative predictive value of US guided FNAC of axillary lymph node in correlation to histopathology was found to be 88.8 %, 100 %, 100 % and 91.67% respectively in our study. By applying chi-square test, the differences were significant at p value of <0.0001. A Moore et al reported²⁵ reported in their study in 112 patients that the overall sensitivity and specificity values for

sonography alone were 81% and 69% respectively. Adding fine needle aspiration improved the specificity of US to 100 %, leaving the sensitivity unchanged (82%). However, as shown by a raw data analysis of the mentioned studies by Leenders, sensitivities ranged from 6 to 63% if all patients were included and not only patients with suspicious AUS followed by FNAC or CNB (Leenders et al³⁵). That means their study reported sensitivity of 55.6 %, and addition of sonographically guided biopsy increases specificity and may help to identify patients with axillary lymph node metastases. But a negative FNA or CNB does not exclude lymph node metastases, since the proportion of false negatives reaches 37.1 %.(in this study false negative result is 8.33%). Adding fine needle aspiration improved the sensitivity, specificity, positive predictive value and negative predictive value of AUS from 66.7% to 88.8%, 95.6% to 100%, 85.7% to 100% and 88% to 91.7% respectively in present study.

Combining AUS with sonographically guided fine needle aspiration (US-FNAC) sensitivity varied between 30.6% (22.5-39.6 %) and 62.9 % (49.7-74.8 %) and specificity reached nearly 100% (94.8-100 %) (Alvarez et al²⁷).

V. Conclusion

Based on our study conducted on the patients with early breast cancer following conclusions have been drawn:

1. AUS and US guided FNAC of axillary lymph nodes is a simple, minimally invasive and reliable technique for the initial determination of axillary lymph node status in breast carcinoma patients.
2. US guided FNAC of nonpalpable axillary lymph nodes can improve markedly the specificity of both physical examination and AUS alone in detecting metastatic lymph nodes.
3. The positive predictive value of 100 % and the negative predictive value of 91.67% of US guided FNAC in our study indicate that the predictive power of a positive result is excellent. This indicate that it is a useful procedure in the initial staging of breast carcinoma and can be immensely valuable in planning the appropriate management of patients.
4. Patients with a positive US-FNAC can proceed directly to axillary lymph node dissection without need for SLND.
5. In cases proved to be US-FNAC negative, ALND can be avoided and even SLND can be avoided.
6. In this era of neo-adjuvant chemotherapy and adjuvant radio therapy, axillary metastasis can be managed less invasively

References

- [1]. Moore MA, Ariyaratne Y, Badar F, Bhurgrri Y, Datta K, Mathew A, et al. Cancer epidemiology in South Asia-past, present and future. *Asian Pac J Cancer Prev.* 2010 Sep 15;11(Suppl 2):49-66.
- [2]. Valagussa P, Bonadonna G, Veronesi U. Patterns of relapse and survival following radical mastectomy. Analysis of 716 consecutive patients. *Cancer.* 1978 Mar 1;41(3):1170-8.
- [3]. Purushotham AD, Upponi S, Klevesath MB, Bobrow L, Millar K, Myles JP, et al. Morbidity after sentinel lymph node biopsy in primary breast cancer: results from a randomized controlled trial. *Journal of Clinical Oncology.* 2005 Jul 1;23(19):4312-21.
- [4]. Bonadonna G, Valagussa P, Brambilla C, Ferrari L, Moliterni A, Terenziani M, Zambetti M. Primary chemotherapy in operable breast cancer: eight-year experience at the Milan Cancer Institute. *Journal of Clinical Oncology.* 1998 Jan;16(1):93-100.
- [5]. Pierga JY, Mouret E, Dieras V, Laurence V, Beuzebec P, Dorval T, et al. Prognostic value of persistent node involvement after neoadjuvant chemotherapy in patients with operable breast cancer. *British journal of cancer.* 2000 Dec;83(11):1480.
- [6]. Valente SA, Levine GM, Silverstein MJ, Rayhanabad JA, Weng-Grumley JG, Ji L, et al. Accuracy of predicting axillary lymph node positivity by physical examination, mammography, ultrasonography, and magnetic resonance imaging. *Annals of surgical oncology.* 2012 Jun 1;19(6):1825-30.
- [7]. Alvarez, Soledad, et al. Role of sonography in the diagnosis of axillary lymph node metastases in breast cancer: a systematic review. *American Journal of Roentgenology.* 2006;186.5:1342-8.
- [8]. Verbanck J, Vandewiele I, De Winter H, Tytgat J, Van Aelst F, Tanghe W. Value of axillary ultrasonography and sonographically guided puncture of axillary nodes: a prospective study in 144 consecutive patients. *Journal of clinical ultrasound.* 1997 Feb 1;25(2):53-6.
- [9]. Bruneton JN, Caramella E, Hery M, Aubanel D, Manzano JJ, Picard JL. Axillary lymph node metastases in breast cancer: preoperative detection with US. *Radiology.* 1986 Feb;158(2):325-6.
- [10]. Pamilo M, Soiva M, Lavast EM. Real-time ultrasound, axillary mammography, and clinical examination in the detection of axillary lymph node metastases in breast cancer patients. *Journal of ultrasound in medicine.* 1989 Mar 1;8(3):115-20.
- [11]. Esen G, Gurses B, Yilmaz MH, Ilvan S, Ulus S, Celik V, et al. Gray scale and power Doppler US in the preoperative evaluation of axillary metastases in breast cancer patients with no palpable lymph nodes. *European radiology.* 2005 Jun 1;15(6):1215-23.
- [12]. Mustonen P, Farin P, Kosunen O. Ultrasonographic detection of metastatic axillary lymph nodes in breast cancer. *In Annales chirurgiae et gynaecologiae.* 1990;79(1):15-8.
- [13]. Verbanck J, Vandewiele I, De Winter H, Tytgat J, Van Aelst F, Tanghe W. Value of axillary ultrasonography and sonographically guided puncture of axillary nodes: a prospective study in 144 consecutive patients. *Journal of clinical ultrasound.* 1997 Feb 1;25(2):53-6.
- [14]. Yang WT, Ahuja A, Tang A, Suen M, King W, Metreweli C. High resolution sonographic detection of axillary lymph node metastases in breast cancer. *Journal of ultrasound in medicine.* 1996 Mar 1;15(3):241-6.
- [15]. Ciatto S, Brancato B, Rizzo G, Ambrogetti D, Bulgaresi P, Maddau C, et al. Accuracy of fine needle aspiration cytology (FNAC) of axillary lymph nodes as a triage test in breast cancer staging. *Breast cancer research and treatment.* 2007 May 1;103(1):85-91.

A prospective study to evaluate the accuracy of axillary staging using ultrasound and USG-guided ..

- [16]. Sapino A, Cassoni P, Zanon E, Fraire F, Croce S, Coluccia C, et al. Ultrasonographically-guided fine-needle aspiration of axillary lymph nodes: role in breast cancer management. *British Journal of Cancer*. 2003 Mar 10;88(5):702.
- [17]. Krishnamurthy S, Sneige N, Bedi DG, Edieken BS, Fornage BD, Kuerer HM, et al. Role of ultrasound-guided fine-needle aspiration of indeterminate and suspicious axillary lymph nodes in the initial staging of breast carcinoma. *Cancer*. 2002 Sep 1;95(5):982-8.
- [18]. Genta F, Zanon E, Camanni M, Deltetto F, Drogo M, Gallo R, et al. Cost/accuracy ratio analysis in breast cancer patients undergoing ultrasound-guided fine-needle aspiration cytology, sentinel node biopsy, and frozen section of node. *World journal of surgery*. 2007 Jun 1;31(6):1157-65.
- [19]. Alvarez S, Añorbe E, Alcorta P, López F, Alonso I, Cortés J. Role of sonography in the diagnosis of axillary lymph node metastases in breast cancer: a systematic review. *American Journal of Roentgenology*. 2006 May;186(5):1342-8.
- [20]. Bedrosian I, Bedi D, Kuerer HM, Fornage BD, Harker L, Ross MI, et al. Impact of clinicopathological factors on sensitivity of axillary ultrasonography in the detection of axillary nodal metastases in patients with breast cancer. *Annals of surgical oncology*. 2003 Oct 1;10(9):1025-30.
- [21]. Nandakumar A, Gupta PC, Gangadharan P, Visweswara RN, Parkin DM. Geographic pathology revisited: development of an atlas of cancer in India. *International journal of cancer*. 2005 Sep 20;116(5):740-54.
- [22]. Pinder SE, Murray S, Ellis IO, Triharia H, Elston CW, Gelber RD, et al. The importance of the histologic grade of invasive breast carcinoma and response to chemotherapy. *Cancer* 1998 Oct 15;83(8):1529-39.
- [23]. Meena SP, Hemrajani DK, Joshi N. A comparative and evaluative study of cytological and histological grading system profile in malignant neoplasm of breast-an important prognostic factor. *Indian journal of pathology & microbiology* 2006 Apr;49(2):199-202.
- [24]. Shet T, Agrawal A, Nadkarni M, Palkar M, Havaladar R, Parmar V, Badwe R, Chinoy RF. Hormone receptors over the last 8 years in a cancer referral center in India: what was and what is. *Indian journal of pathology and microbiology* 2009 Apr 1;52(2):171-3.
- [25]. Moore A, Hester M, Nam MW, Brill YM, McGrath P, Wright H, et al. Distinct lymph nodal sonographic characteristics in breast cancer patients at high risk for axillary metastases correlate with the final axillary stage. *The British Journal of Radiology* 2008 Aug;81(968):630-6.
- [26]. Jung J, Park H, Park J, Kim H. Accuracy of preoperative ultrasound and ultrasound-guided fine needle aspiration cytology for axillary staging in breast cancer. *ANZ journal of surgery*. 2010 Apr 1;80(4):271-5.
- [27]. Jankowski C, Hudry D, Vaillant D, Varbedian O, Mejean N, Guy F, et al. Evaluation of axillary involvement by ultrasound-guided lymph node biopsy: a prospective study. *GynécologieObstétrique&Fertilité*. 2015 Jun 30;43(6):431-6.
- [28]. Feng Y, Huang R, He Y, Lu A, Fan Z, Fan T, et al. Efficacy of physical examination, ultrasound, and ultrasound combined with fine-needle aspiration for axilla staging of primary breast cancer. *Breast cancer research and treatment*. 2015 Feb 1;149(3):761-5.
- [29]. Vaidya JS, Vyas JJ, Thakur MH, Khandelwal KC, Mittra I. Role of ultrasonography to detect axillary node involvement in operable breast cancer. *European Journal of Surgical Oncology (EJSO)*. 1996 Apr 1;22(2):140-3.
- [30]. Alvarez S, Añorbe E, Alcorta P, López F, Alonso I, Cortés J. Role of sonography in the diagnosis of axillary lymph node metastases in breast cancer: a systematic review. *American Journal of Roentgenology*. 2006 May;186(5):1342-8.
- [31]. Kebudi A, Calişkan C, Yetkin G, Celebi S, Işgör A, MesrurHalefoglu A, et al. The role of pre-operative B mode ultrasound in the evaluation of the axillary lymph node metastases in the initial staging of breast carcinoma. *ActaChirurgicaBelgica* 2005 Jan 1;105(5):511-14.
- [32]. Shin JH, Hwang A, Choi HY, Baek SY. The value of ultrasonographic detection for metastatic axillary lymph nodes in breast cancer. *J Korean RadiolSoc* 2005 Jan 1;52(1):45-9.
- [33]. Sousa MT, Illescas MB, Rodríguez MR, Ortega MA, López LG, García JM, et al. Preoperative staging of axillary lymph nodes in breast cancer: ultrasonographic parameters and ultrasound-guided core needle biopsy. *Radiología (English Edition)*. 2011 Nov 1;53(6):544-51.
- [34]. Deurloo EE, Tanis PJ, Gilhuijs KG, Muller SH, Kröger R, Peterse JL, et al. Reduction in the number of sentinel lymph node procedures by preoperative ultrasonography of the axilla in breast cancer. *European Journal of Cancer*. 2003 May 1;39(8):1068-73.
- [35]. Mainiero MB, Cinelli CM, Koelliker SL, Graves TA, Chung MA. Axillary ultrasound and fine-needle aspiration in the preoperative evaluation of the breast cancer patient: an algorithm based on tumor size and lymph node appearance. *American Journal of Roentgenology*. 2010 Nov;195(5):1261-7.
- [36]. Misra J, Pradhan A, Kusta M. Axillary Ultrasound Examination in the Selection of Carcinoma of Breast Patients for Sentinel Node Biopsy-A Prospective Study. *ANTISEPTIC*. 2016 May.
- [37]. Bedi DG, Krishnamurthy R, Krishnamurthy S, Edeiken BS, Le-Petross H, Fornage BD, et al. Cortical morphologic features of axillary lymph nodes as a predictor of metastasis in breast cancer: in vitro sonographic study. *American Journal of Roentgenology*. 2008 Sep;191(3):646-52.
- [38]. Masood S. The expanding role of pathologists in the diagnosis and management of breast cancer: worldwide excellence in breast pathology program. *The Breast Journal* 2003 May;9(1):94-7.

Dr. Ashwin M,etal. "A Prospective Study To Evaluate The Accuracy Of Axillary Staging Using Ultrasound And USG-Guided Fine Needle Aspiration Cytology In Early Breast Cancer Patients In A Tertiary Level Centre In North East India." *IOSR Journal of Dental and Medical Sciences (IOSR-JDMS)*, 19(2), 2020, pp. 37-46.