

Traumatic Fibroma: A Case Report

Dr. Priyanka Mahawar¹, Dr. Sreedevi Reddy², Dr. Meenakshi Bhasin³, Dr. Ankur Kakkad⁴, Dr. Aditi Yadav⁵

¹(Post Graduate Student, Department of Oral Medicine and Radiology, Hitkarini Dental College and Hospital, India)

²(Professor & Head, Department of Oral Medicine and Radiology, Hitkarini Dental College and Hospital, India)

³(Reader, Department of Oral Medicine and Radiology, Hitkarini Dental College and Hospital, India)

⁴(Reader, Department of Oral Medicine and Radiology, Hitkarini Dental College and Hospital, India)

⁵(Post Graduate Student, Department of Periodontics and Implantology, Hitkarini Dental College and Hospital, India)

Abstract: Fibroma is the most common benign soft tissue neoplasm occurring in the oral cavity. Most of these lesions are intact hyperplasia or reactive proliferation of fibrous tissue. It develops due to chronic irritation to plaque, calculus, restorative, prosthetic or orthodontic appliances. The aim of this case report is to describe a case of traumatic fibroma in a 64 year old female patient in relation to hard palate of oral cavity. Patient was old denture wearer since 8 years whereas maxillary denture was fabricated with suction disk. Clinically the diagnosis of traumatic fibroma secondary to suction disk was rendered. Surgical excision was done followed by histopathological confirmation with emphasis on clinical aspect and as a dental practitioner, it is our responsibility to stop the dental quackery practice and educate the patient about the ill effects of dental quackery on their oral health.

Keywords: Traumatic fibroma, Neoplasm

Date of Submission: 11-03-2020

Date of Acceptance: 25-03-2020

I. Introduction

A general soft tissue reaction to strain from tooth/teeth or dental prostheses was first reported in 1846 as fibrous polyp and polypus.¹ Various terms have been used in oral pathology to describe a non-neoplastic fibrous lesion of oral mucosa like Irritation Fibroma, Irritational Fibroma, Fibrous Hyperplasia, Focal Fibrous Hyperplasia, Traumatic Fibroma, Localized Fibrous Hyperplasia and Fibro epithelial Polyp.² Fibroma, a benign neoplasm of fibroblastic origin, is reactive in nature and represents a reactive hyperplasia of fibrous connective tissue in response to local irritation or trauma rather than being a true neoplasm.³

Traumatic or irritation fibroma is the healed end product of the inflammatory hyperplastic lesion which can occur at any age from almost any soft-tissue site, tongue, gingiva, and buccal mucosa being the most common. It is usually characterized by a slow, painless growth accumulated over a period of months or years.⁴ They appear as broad based lesions, lighter in colour than the surrounding normal tissue, with the surface often appearing white because of hyperkeratosis or with surface ulceration caused by secondary trauma. The growth potential of fibroma does not exceed 10-20 mm in diameter.⁵ It is treated by surgical excision, and also the source of irritation must be eliminated. Conservative excisional biopsy is curative and its findings are diagnostic.⁶ Recurrences are rare and may be caused by repetitive trauma at the same site. These lesions do not have a risk for malignancy.⁷

II. Case Report

A 64 year old female patient was reported to Department of Oral Medicine and Radiology with chief complaint of missing teeth since 10 years and desired to get them replaced by artificial teeth and also complains of growth in upper front region of palate. A detailed case history was recorded wherein she gave no significant medical history whereas dental history revealed patient was old denture wearer since 8 years. Patient was apparently alright 1 year ago when she first noticed growth on anterior 1/3rd of hard palate, initially growth was of peanut size which was gradual in onset and slow in progression and increased to the present size and not associated with bleeding or any pus discharge and patient had not taken any treatment for the same. The growth had interfered in chewing and normal functioning of the mouth.

Intraoral examination of teeth and periodontium revealed completely edentulous maxillary and mandibular arches. Maxillary Ridge was moderately resorbed, U in shape and Mandibular ridge was also

Moderately Resorbed, V in shape. Saliva was watery in consistency with relatively normal flow. On Soft tissue examination a solitary pedunculated round to oval growth was seen on the anterior 1/3rd of the hard palate present in midline, approximately 1.3 cm x 1.2 cm in size, mucosa over the growth appeared mildly erythematous, surrounding mucosa appeared to be normal (Fig 1 & 2). Growth was hard and firm in consistency. Non tender, mobile, non-compressible, non-fluctuant, non-reducible and non-pulsatile in nature whereas on examination of denture, it was observed that the maxillary denture was fabricated with suction disk (Fig 3). So the provisional diagnosis Traumatic Fibroma of Hard Palate Secondary to Suction disk was given. The differential diagnosis was given such as ill fitting denture induced traumatic fibroma, Peripheral ossifying fibroma, Pyogenic granuloma of palate, Giant Cell Fibroma and Giant Cell Granuloma.

For the management of traumatic fibroma, surgical excision was done and on histopathological evaluation Hematoxylin and Eosin stained showed atrophic stratified squamous para-keratinized epithelium with flattened rete-ridges was seen covering the connective tissue stroma. The connective tissue stroma was collagenous with dense collagen fibers, fibroblasts along with plasma cells and sparse chronic inflammatory cell infiltration (Fig 4). Based on the microscopic findings a final diagnosis of Traumatic Fibroma was made which co-related the clinical findings.

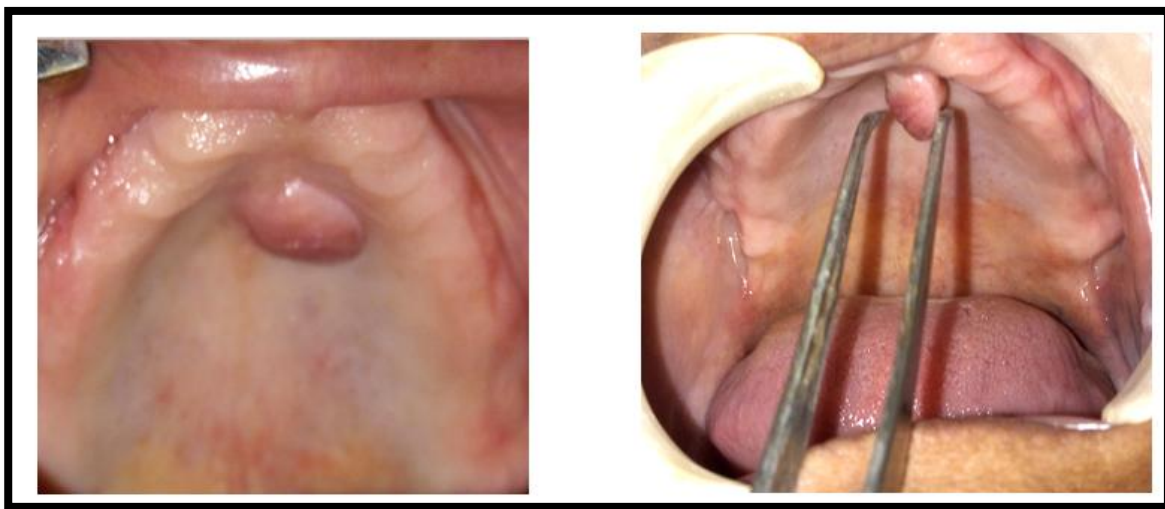


Fig 1. TRAUMATIC FIBROMA Fig 2. PEDUNCULATED GROWTH OF FIBROMA

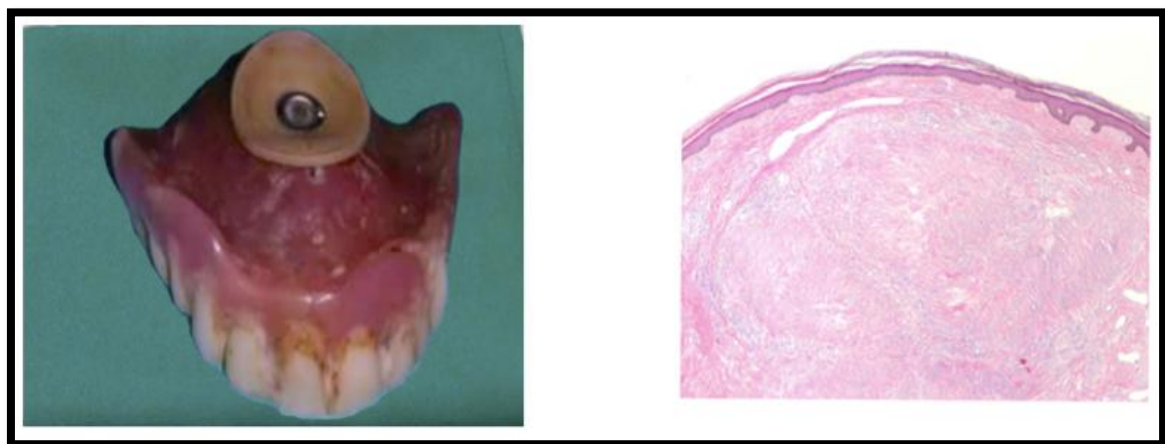


Fig 3. DENTURE WITH SUCTION DISC Fig 4. HISTOLOGIC APPEARANCE OF FIBROMA

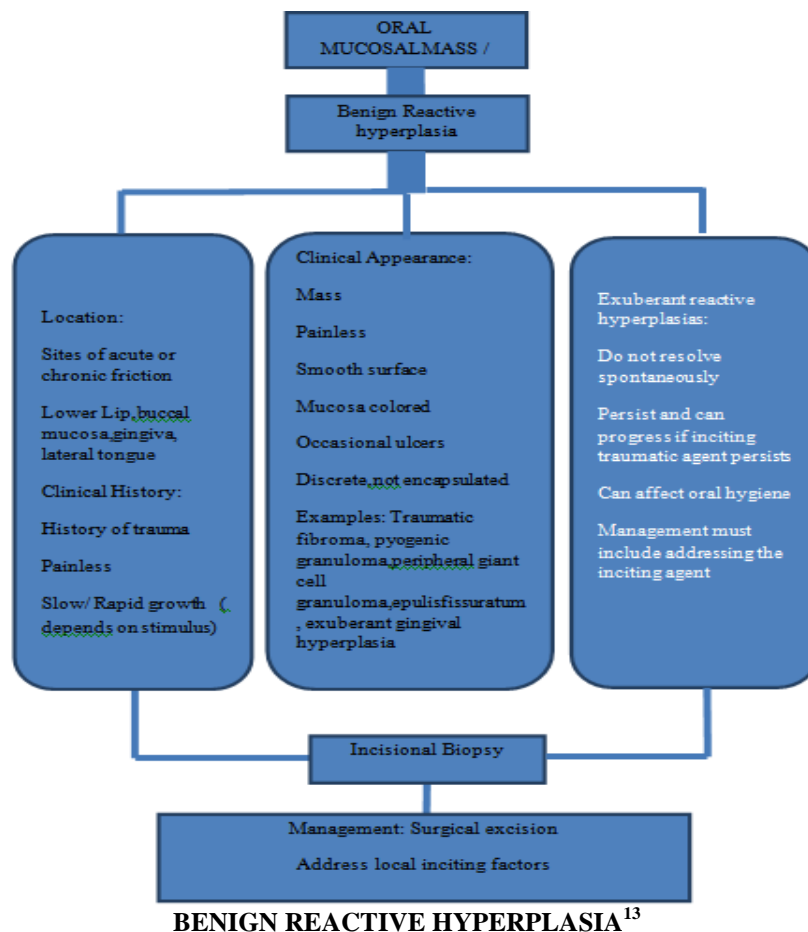
III. Discussion

Localized fibrous tissue overgrowths are very common in the oral mucosa. The etiology of an irritational fibroma is usually a source of irritation. In 1986, Bouquot & Gundlach examined 23,616 white persons over 35 years of age, and found out that the most common lesion of oral soft tissue was irritation fibroma. They found out that irritation fibroma accounted for 35.8% of the 791 benign soft tissue masses, which had a combined prevalence rate of 12.0 lesions per 1000 population.⁸ Study by Domingo *et al* (2007), of the 300 benign tumors of the oral mucosa studied, 53.3% were diagnosed as fibroma.⁹ In a retrospective study by

Martins *et al.*, 193 cases of focal fibrous hyperplasia of the oral cavity were reviewed and it was observed that the most commonly affected site was the buccal mucosa (61.7%), almost two-thirds of the cases were concentrated from the second to the fifth decade of life, females were more affected than men, and a history of trauma was related by 90.7% of the patients.¹⁰ According to Barker and Lucas, irritational fibromas exhibit a pattern of collagen arrangement depending on the site of the lesion and the amount of irritation. There are two types of patterns: (a) radiating pattern and (b) circular pattern. Thus, they hypothesized that when there is a greater degree of trauma, the former appears in sites which are immobile in nature (e.g., palate), while lesser trauma induces the latter and it occurs in sites that are flexible in nature (e.g., cheeks).³ Similar such lesions, which may also arise as a result of irritation due to plaque microorganisms and other local irritants, include pyogenic granuloma, peripheral giant cell granuloma, and peripheral ossifying fibroma. All the lesions have a similar clinical appearance.¹¹ The treatment of irritational fibroma consists of elimination of etiological factors, scaling of adjacent teeth, and total aggressive surgical excision along with involved periodontal ligament and periosteum to minimize the possibility of recurrence. Any identifiable irritant such as an ill-fitting dental appliance, root stumps, and rough restoration should be removed.¹²

IV. Conclusion

Fibroma is the most common, benign and self-limiting entity, diagnosed based on clinical and pathological examination. Denture fabricated with Suction discs provide needed retention by inducing negative pressure on the tissue surface which induces harmful effect on tissues of the contact area by reducing blood circulation, produces hypoxic state in the affected area and causes necrosis of tissue simultaneously underlying bony part also get affected by leading to tissues perforation. As in the other fields of the medicine, dentistry is also a science based and highly regulated health care profession. Dentistry is facing numerous challenges; one of the most important is the dental quackery. Due to this unethical practice of the quackery, the patient's oral health is in danger, as many complications can arise after such practice. As a dental practitioner, it is our responsibility to stop this dental quackery practice and educate the patient about the ill effects of suction disks on denture bearing tissues. The patient in the present case had reported with good prognosis and an uneventful post-operative recovery and had been advised every three months routine follow-up with recommendation for fabrication of new complete denture by qualified professional dentist.



References

- [1]. Singh A, Vengal M, Patil V, Sachdeva SK. Traumatic Fibroma A Saga Of Reaction Against Irritation. Dental Impact Vol. 4, Issue 1, June 2012.
- [2]. Jinal D, Krishna D, Gaurav B, Dharmesh V. Traumatic fibroma - A review and report of two cases. Int J Current Res. 2017; 9: 52004-52006.
- [3]. Barker DS, Lucas RB. Localised fibrous overgrowths of the oral mucosa. Br J Oral Surg 1967;5:86-92.
- [4]. Wood NK, Goaz PW. Differential Diagnosis of Oral and Maxillofacial Lesions. 5th ed. Missouri: Mosby; 2006.p.136-8.
- [5]. Regezi JA, Sciubba JJ, Jordan RC, Abrahams PH. Oral pathology: Clinical pathologic correlations. Saunders. 2003.6.
- [6]. López-Labady J, Villarroel M, Lázarde J, Rivera H. Fibroma traumático. Revisión de la literatura y reporte dos casos. Acta Odontol Venez. 2000; 38: 47-49.
- [7]. Esmeli T, Lozada-Nur F, Epstein J. Common benign oral tissue masses. Dent Clin North Am. 2005; 49: 223-240.
- [8]. Bouquot JE, Gundlach KK. Oral exophytic lesions in 23,616 white Americans over 35 years of age. Oral Surg Oral Med Oral Pathol. 1986; 62: 284-291.
- [9]. Oral Cir Bucal. 2008; 13: E161-E166.
- [10]. De Santana Santos T, Martins-Filho PR, Piva MR, de Souza Andrade ES. Focal fibrous hyperplasia: A review of 193 cases. J Oral MaxillofacPathol 2014;18:S86-9.
- [11]. Kolte AP, Kolte RA, Shirao TS. Focal fibrous overgrowths: A case series and review of literature. Contemp Clin Dent 2010;1:271-4.
- [12]. Jain G, Arora R, Sharma A, Singh R, Agarwal M. Irritation fibroma: Report of a case. J Curr Res Sci Med 2017;3:118-21.
- [13]. Natarajan E.,Goupil M.T. (2019) Soft Tissue Oral Pathology. In: Ferneini E., Goupil M. (eds) Evidence-Based Oral Surgery. Springer, Cham

Dr. Priyanka Mahawar, etal. "Traumatic Fibroma: A Case Report." *IOSR Journal of Dental and Medical Sciences (IOSR-JDMS)*, 19(3), 2020, pp. 37-40.