

Outcome of Laparoscopic Diaphragmatic Hernia Repair using expanded polytetrafluoroethylene(ePTFE) for Traumatic delayed Diaphragmatic Hernia

Dr. Jeevankankaria, Dr. SajalGupta,DrJitendraYadav

(Department of General surgery S.M.S Medical college and hospital jaipur, Rajasthan India.)

Corresponding Author: Dr. SajalGupta,PG resident general surgery, Sawaiman singhHospitaljaipur , Rajasthan

Abstract

Traumatic diaphragmatic hernia (TDH) is an uncommon surgical problem, and diagnosis is often delayed. However, the mortality from bowel necrosis can reach 80%.

Therefore, suspicion is needed and surgery is required to prevent complications. A 55-year-old female was transferred due to abdominal pain and vomiting. computed tomography (CT) scan showed herniation of the stomach through the right diaphragm. The patient had a history

of trauma with the horn of the cow and there after she had fallen down months ago. At that time patient showed to the local doctor, got

antispasmodics and was relieved with in 4-5 days. We diagnosed and treated herniation of TDH and the patient underwent laparoscopic

repair using an expanded polytetrafluoroethylene (ePTFE) mesh. Surgery was uneventful. We reported a delayed presenting TDH and used a laparoscopic approach to be safe and feasible during

the surgery. Moreover, use of an ePTFE mesh for the repair of large diaphragmatic hernia was also feasible.

Keywords: hernia, laparoscopic, diaphragm, expanded polytetrafluoroethylene.

Date of Submission: 22-02-2020

Date of Acceptance: 06-03-2020

AIM- the aim of this study was to evaluate right and left diaphragmatic hernias in terms of size of the defect, contents, ease of their reduction, and associated morbidities and complications.

I. Introduction

Traumatic diaphragmatic hernia is a rare surgical problem, and diagnosis is often delayed. At the time of the accident and in the emergency department, it is difficult to detect a small defect in the diaphragm using radiological findings, and related symptoms may not be recognized. Therefore, diagnosis of traumatic herniation is frequently delayed until complications occur, e.g., cardiopulmonary compromise or gastrointestinal obstruction with or without strangulation. In addition, it is not uncommon to suspect that symptoms are associated with trauma when symptoms occur later. The clinical manifestation of diaphragmatic hernia differs depending on the side involved. Dyspnea and tachycardia are symptoms of right-side herniation, and gastrointestinal symptoms of left-side herniation. This is because, in general, the herniated abdominal organs are the liver on the right side and the stomach, small intestine and large intestine on the left. In general, the treatment of diaphragmatic hernia has involved laparotomy or thoracotomy or both. Laparoscopic surgery is now widely accepted and laparoscopic diaphragmatic hernia repair is also performed. Several methods can be used to repair defects, e.g., primary repair and repair with mesh. No study has reported an improved method of repairing diaphragmatic defects. Also, there is no study of the need for treatment of diaphragmatic injury without symptoms or hernia.

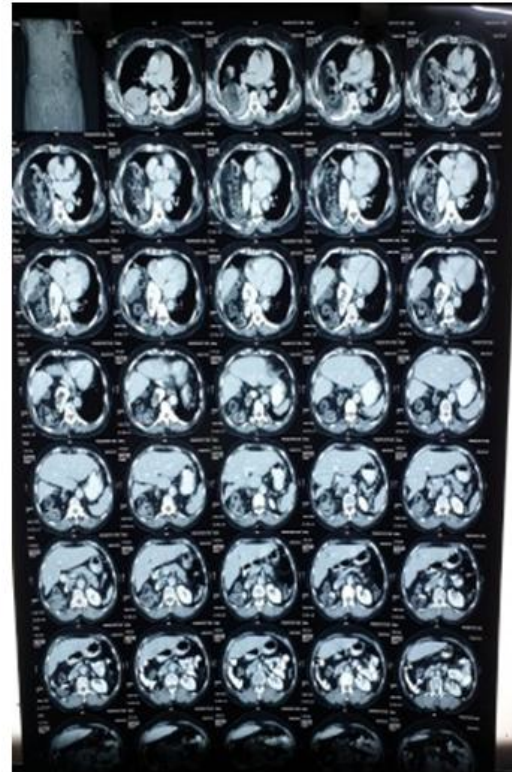
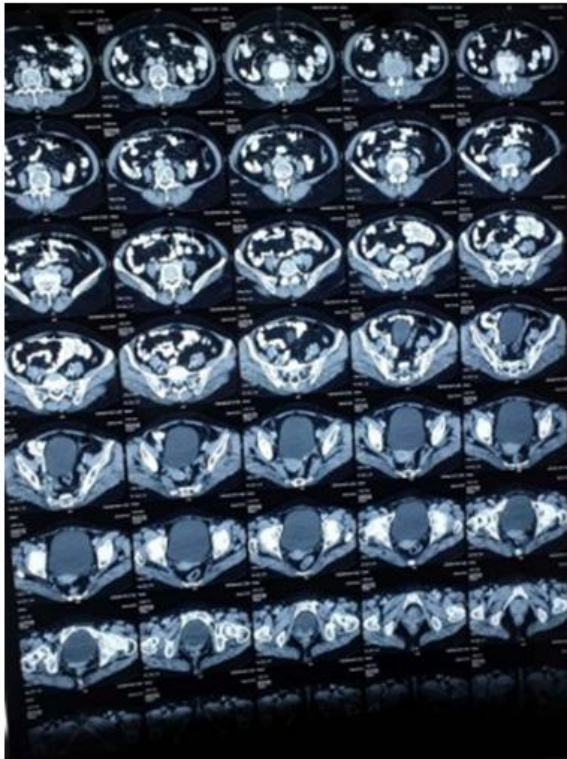
We reported successful treatment of a diaphragmatic hernia using an expanded polytetrafluoroethylene (ePTFE) mesh.

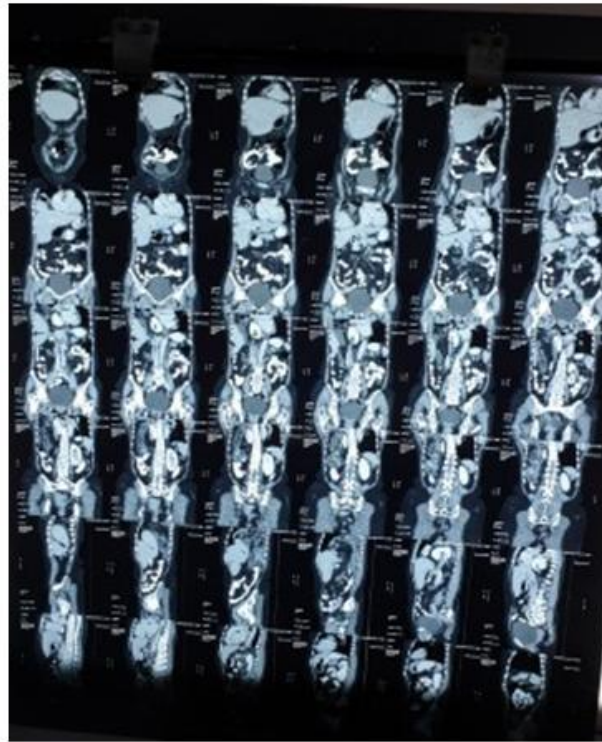
II. Case Report

A 55 year old female agriculturist by occupation came to our outpatient department with a complain of breathlessness since the past 1 month on doing day to day routine work and on walking. She said that she used to get breathless if she walks for around 50 meters or when she climb up and down 1 flight of stairs. Initially 1 month back the symptoms were mild in nature, but recently since the last 1 month her symptoms started aggravating. She also complains of having diarrhoea and cough since the last 1 and ½ month. She also gave a history of trauma by cow's horn to the right side upper abdomen which was around 18 months ago. After the

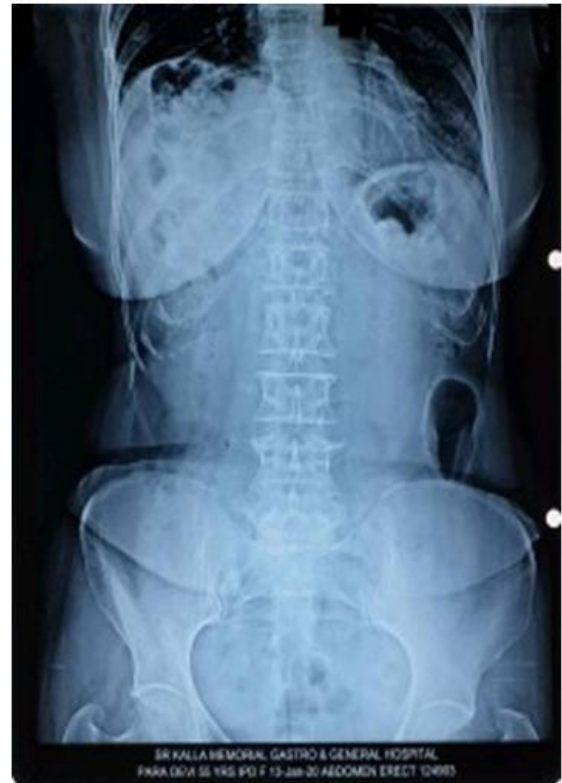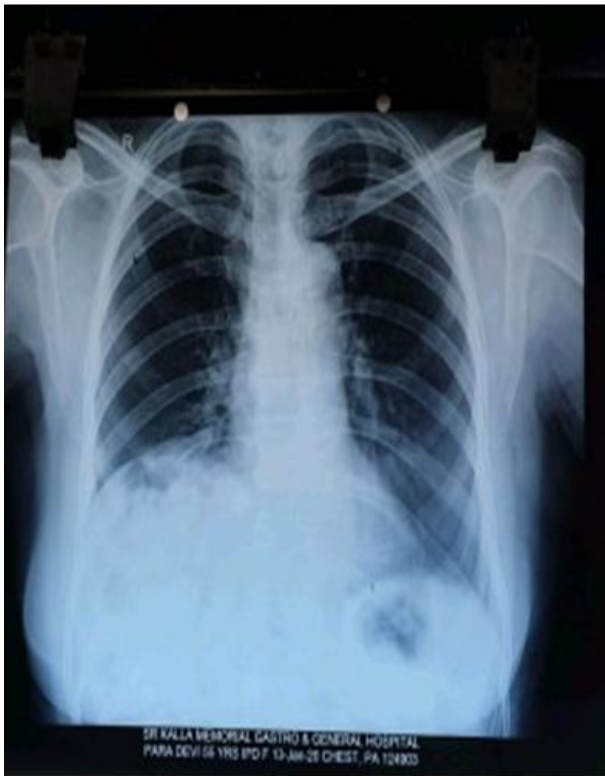trauma she said she had intense pain for about 1 hour . After about 1 and half hour of taking rest at home she consulted a local doctor , there he gave the patient some oral medications (antispasmodics) and a gel to be put on the local site of trauma , and after 5 days she got relived of the symptoms . She also said that after the trauma on the 2nd day there was blackish discoloration over the right upper abdomen which was around a size of the cricket ball. But after 5 days that skin colour also became normal. And here after she never had any problem until 1 and a ½ On ths back when she started having symptoms. Then on 25/11/2019 she got a CECT SCAN done which revealed 1)rightsided diaphragmatic hernia with herniation of colon, liver and right kidney is seen and the kidney is malrotated.

- 1) Changes of collapse - consolidation are seen in the right lung in lowerlobe.
- 2) Changes suggestive of colitis are seen in the large bowel.

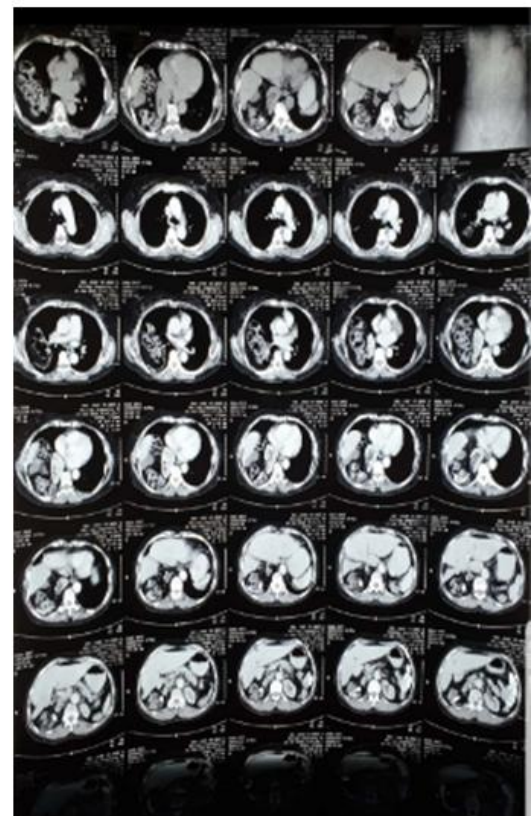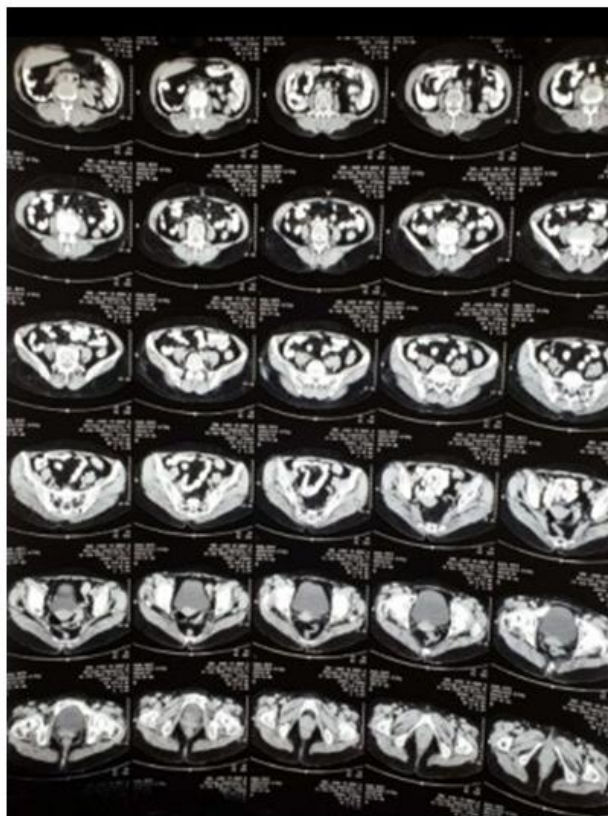


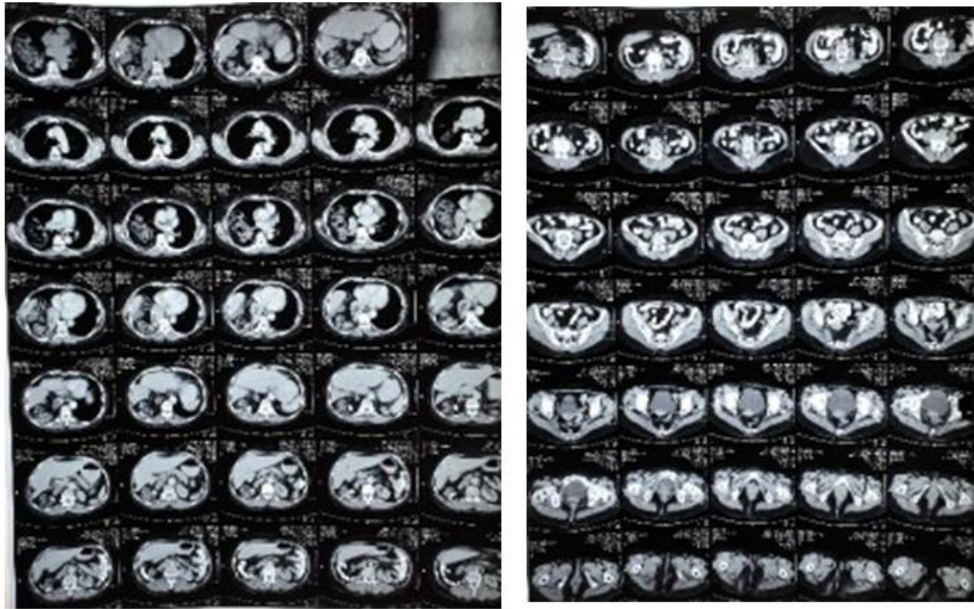


On 13/01/2020 she got a CHEST XRAY PA VIEW AND AN ABDOMINAL XRAY ERECT



On 14/01/2020 again a CECT SCAN was done which also revealed a defect seen in right diaphragm of about 65mm with herniation of colon, stomach, kidney, and small part of liver suggestive of diaphragmatic hernia.

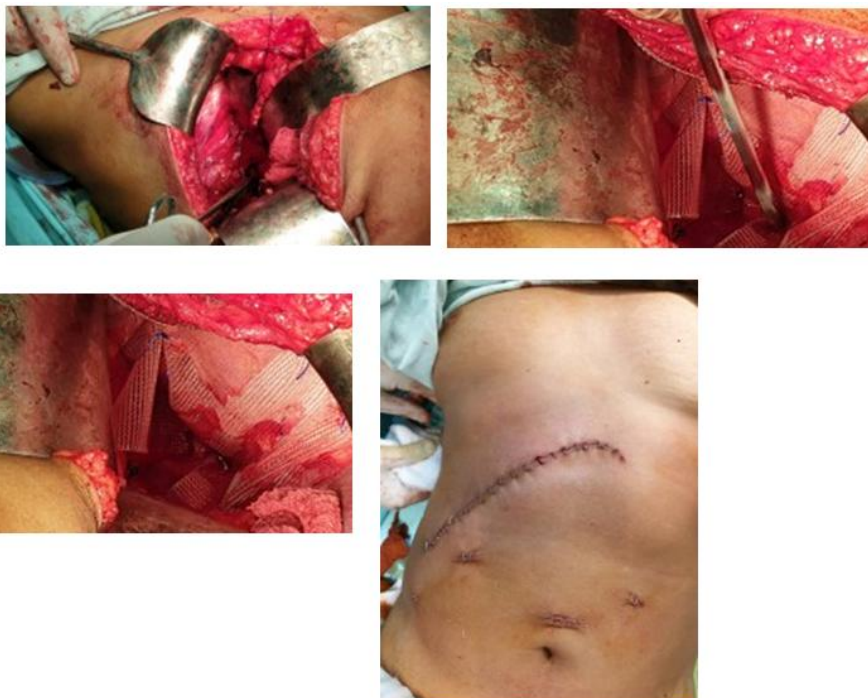


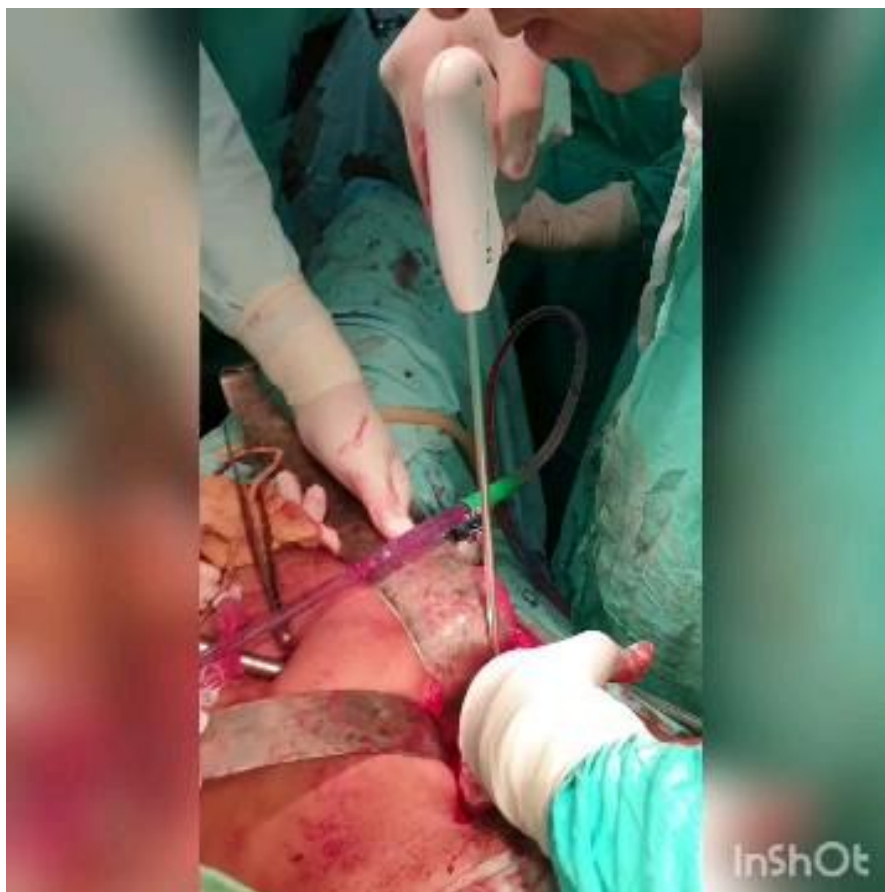
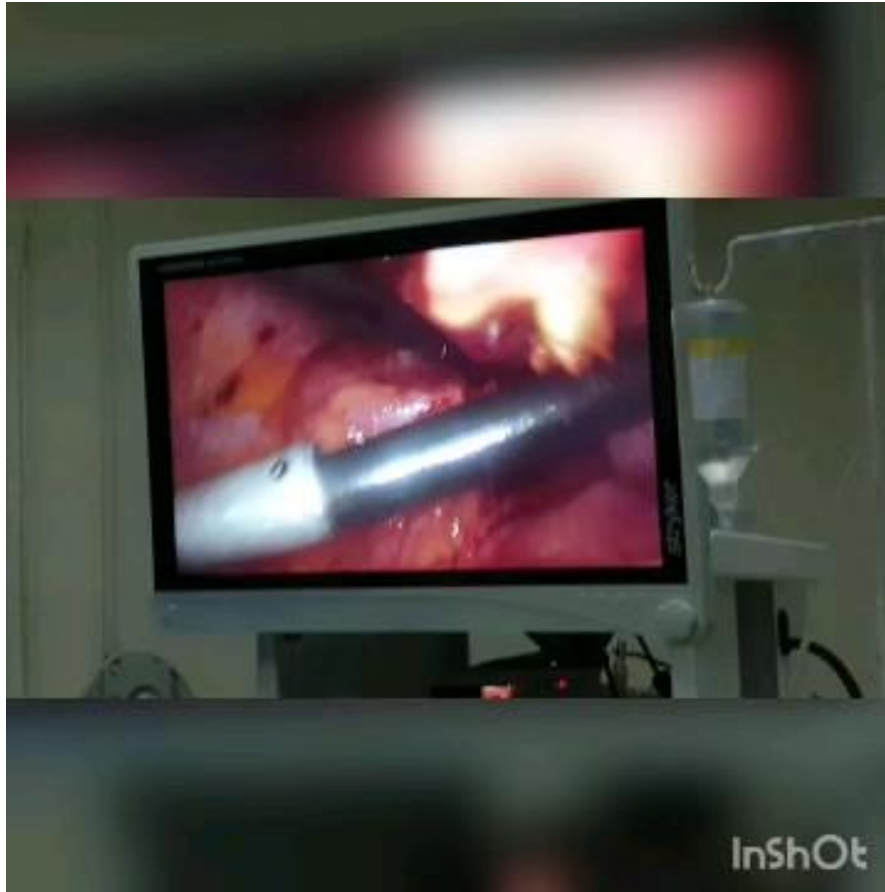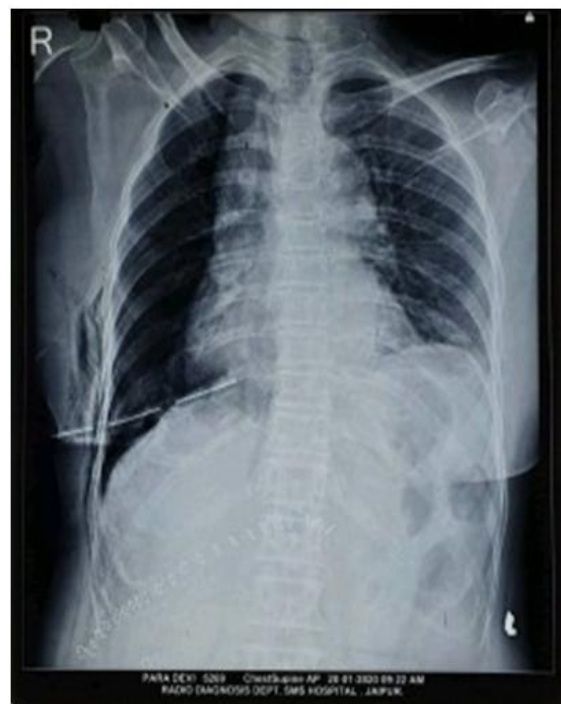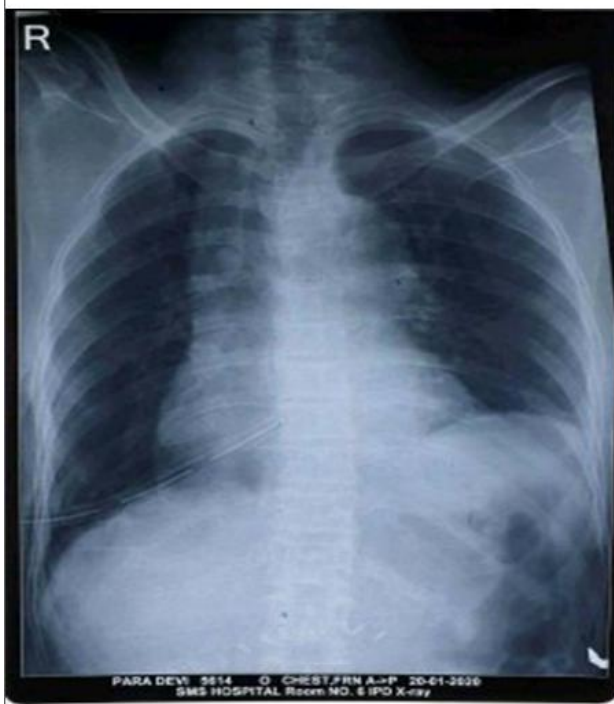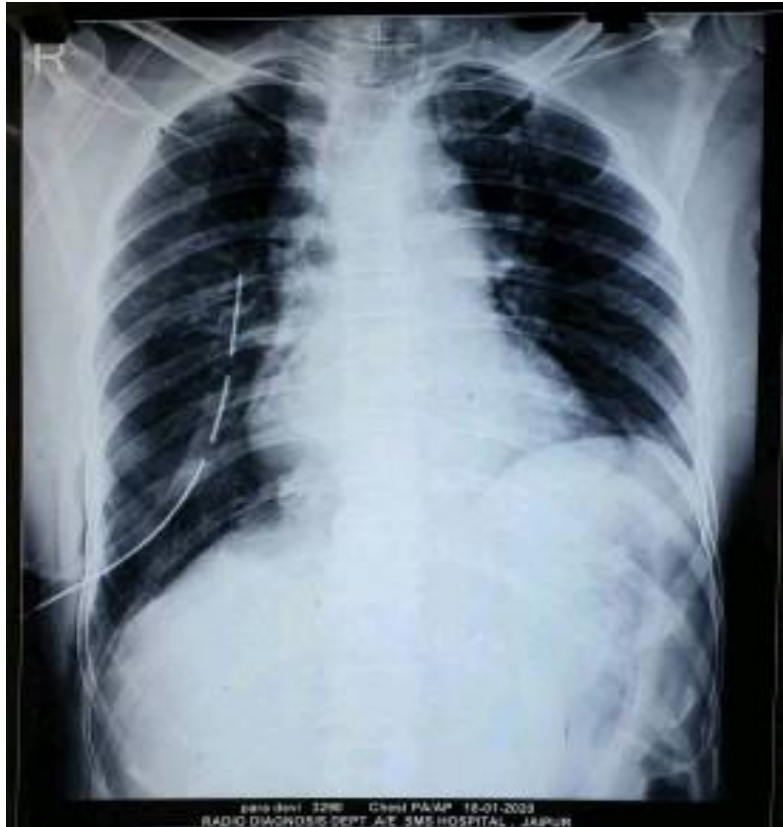Laboratory examination of the patient was unremarkable.

SURGERY

The patient was placed in supine -reverse trendelenberg position with the surgeon on the left side of the patient. A total of 4 ports were used one 10mm port at the umbilicus for the 30 degree rigid scope , one 12mm and one 5mm port at the right midcoastal for working port and one 5mm port at the left anterior axillary line . The stomach, part of the right lobe of liver , right kidney and part of the colon were seen herniating through the defect in the right diaphragm. We reduced most of the herniated contents back into the abdominal cavity except kidney because kidney is a retroperitoneal organ and there was a fear vascular injury so we could not retrieve it back into the abdomen laproscopically. And the defect in the diaphragm was so big that it could not be sutured laproscopically. So now we opened the abdomen by the right kochers incision. And now the kidney was retrieved to its original position in the abdomen and the defect was sutured and closed with the suture PDS no 1. After that the mesh was placed on the sutured defect and was fixed with the help of sutures and tacker. Recovery was uneventful and the patient was discharged at 5 days after the operation.







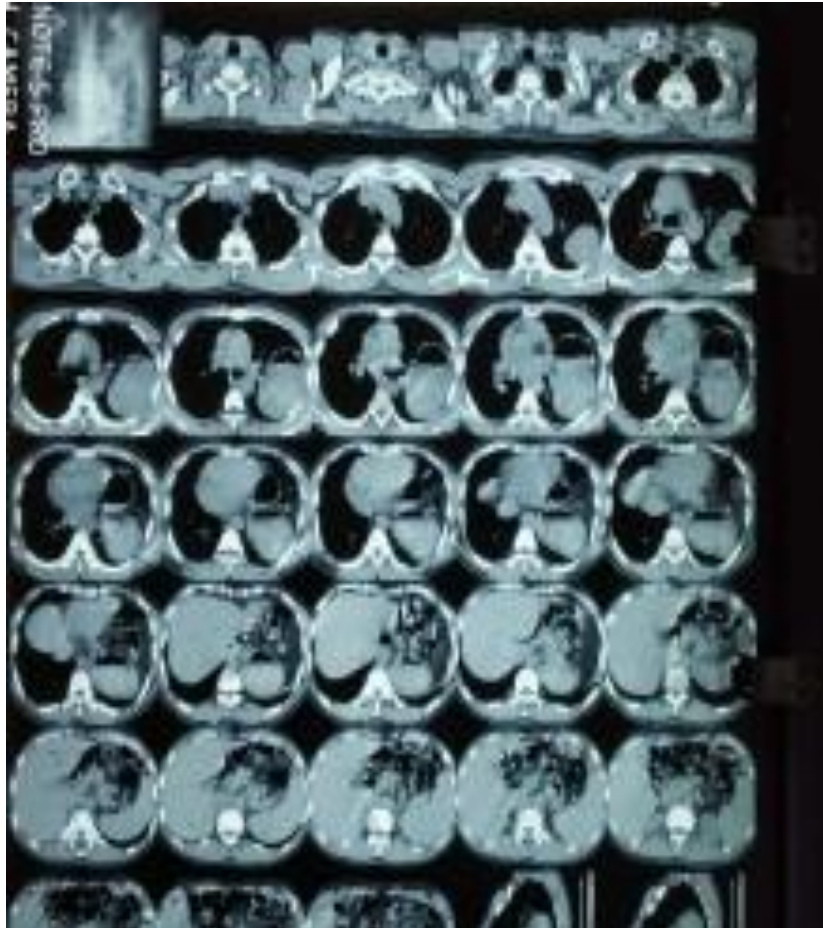CASE REPORT

A 30 year old male, clerk by occupation came to our outpatient department with a complaint of breathlessness since the last 4 months . Initially the symptoms were mild like he used get the breathlessness after 30 min to 1 hour of work and that too if he carried heavy load from one place to another , but it was only mild in nature and he also said that he used to take 30 min to eat 1 chapati. So then he went to a local doctor , got some medications and was used to get relief after it. So the patient had same routine for about one and half to two months after which the symptoms start ed aggravating like now the patient used to have sweating and get breathless after walking about 50 meters. He also said that now he was not able to carry heavy load as he was able to do previously , and was able to climb only one flight of stairs . The patient used to get relief after having one glass of water and after taking rest for sometime. No h/o of nausea , vomiting or any altered bowel habits was there. On further asking patient gave a history of trauma that was fall from bike 4 years back after which he got fracture in both his legs and left rib cage. He was hospitalised for 2 months there he got operated for his fracture but the patient was not told anything about his diaphragmatic defect. He also said that after about 2 years of trauma when he used to have his meal he used to have relief only after walking 3 to 4 round of his park .

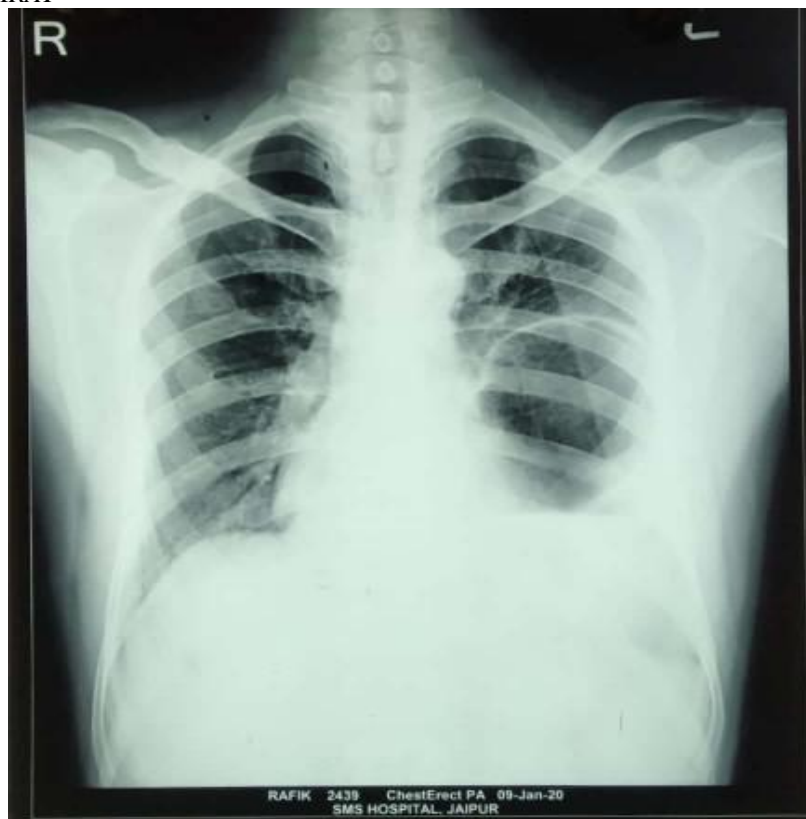so now he got a HRCT thorax on 07/01/2020-

- 1) left diaphragmatic hernia seen with herniation of stomach.
- 2) splenic flexure in left hemithorax.
- 3) Atelectatic bands and patchy consolidation seen in left lung upper and lower lobes.





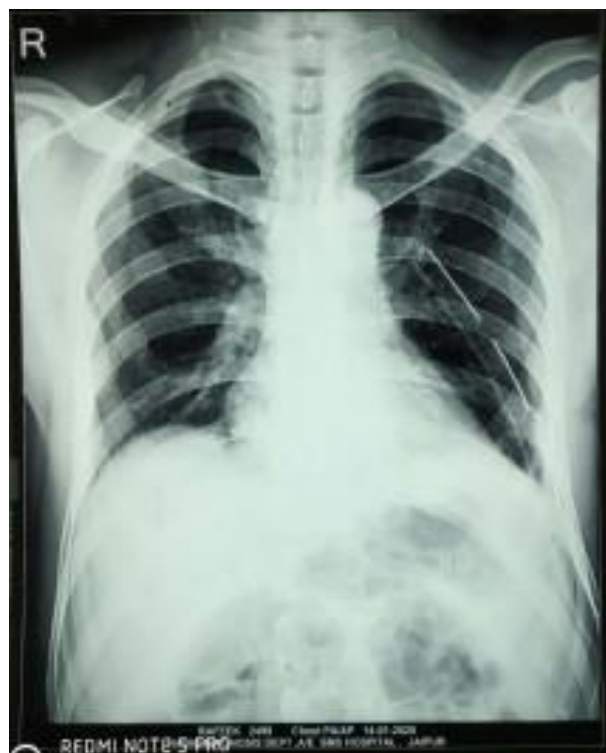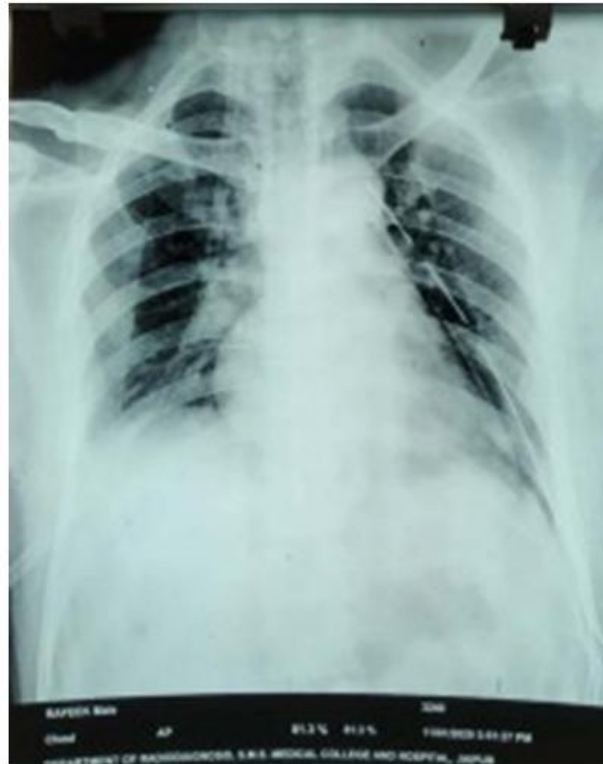PRE OP CHEST XRAY

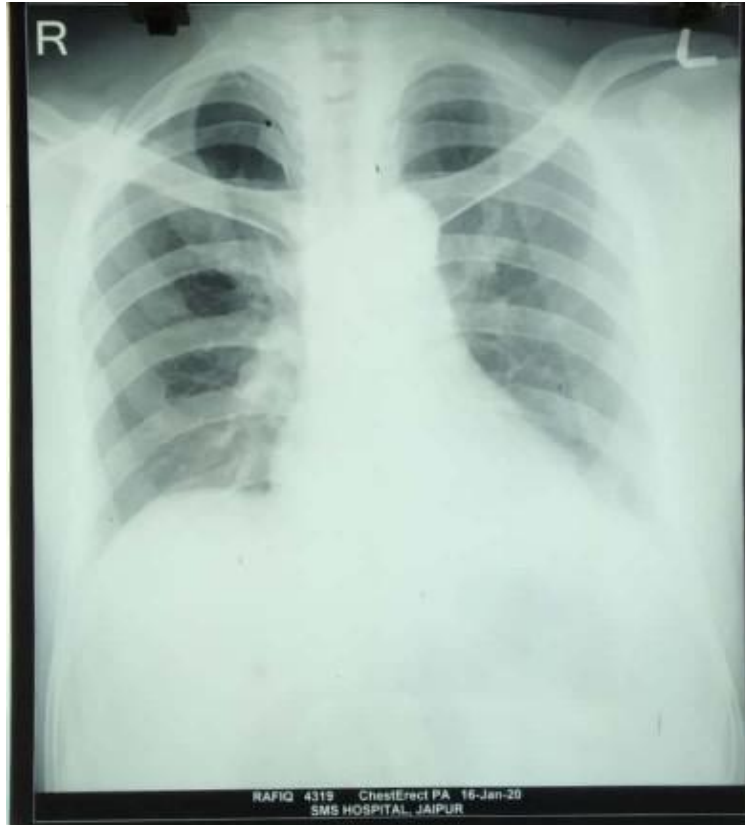

SURGERY

The patient was placed in the supine -reverse trendelenberg position with the surgeon on the left side of the patient. A total of 4 ports were used. There was a defect in the left diaphragm with herniation of stomach and splenic flexure of colon were seen as the contents in the left hemithorax . The contents i.e. stomach and splenic flexure were reduced back to the abdominal cavity. The defect was sutured with PDS no 1 and then the mesh was placed laproscopically and as fixed with the help of sutures and tacker.

POST OP XRAYS





Post op recovery of the patient was uneventful and was discharged on day 7 .

III. Discussion

The incidence of diaphragmatic rupture after thoraco- abdominal trauma is 0.8–5%, and more than 30% of diaphragmatic hernia cases present late. The time of late presentation varied from 24 h to 50 years after trauma.

There are three phases in the rupture of the diaphragm.

The acute phase is at the time of the injury to the diaphragm. The delayed phase is associated with transient herniation of the viscera, thus accounting for absent or intermittent non-specific symptoms. The obstruction phase involves complications of long-standing herniation, manifesting as obstruction, strangulation and rupture. The diaphragm is a septum that separates the abdominal cavity and the thoracic cavity. In normal patients, negative pressure was maintained in the thoracic cavity, and positive pressure in the abdominal cavity. This is important physiology of the abdominal cavity, thoracic cavity and diaphragm in terms of development of iaphragmatic hernia from small defects of the diaphragm. The gative pressure within the thoracic cavity draws intra-dominal contents into the chest for a prolonged period, even ugh small defects.

Therefore, if a diaphragmatic defect after trauma is detected on radiologic findings in the absence of hernia, surgery is mandatory regardless of symptoms.

In this case the diagnosis was missed at the time of trauma. Thus it is not easy to diagnose diaphragmatic hernia without suspicion.

The type of mesh used for repair of a diaphragmatic defect is controversial. Some authors have reported the use of prosthetic material as reinforcement, whereas other authors preferred simple suturing of the defect.

However, it is generally agreed that defects larger than 20–30 cm require a prosthesis. Various synthetic mesh products are available.

We used an ePTFE mesh because other types of mesh such as polypropylene induce excessive bowel adhesion and unacceptable rates of enterocutaneous fistula formation when placed intraperitoneally. Furthermore, ePTFE differs from other synthetic mesh materials in that it is flexible and smooth. Therefore, it is easy to handle during repair and fixation of diaphragmatic defects.

The mortality rate from elective repair is low, but that from ischemic bowel secondary to strangulation can reach 80%. Therefore, to prevent late, serious complications of diaphragmatic hernia, a high index of suspicion is needed and surgery is mandatory for late-presentation traumatic diaphragmatic hernia.

IV. Conclusion

A laparoscopic approach was safe during elective surgery, however in one of the case reports the defect in right sided diaphragmatic hernia was very large and there was a difficulty in retrieval of kidney so we had to go for open approach. The use of an ePTFE synthetic mesh in both the cases enabled the repair of the large diaphragmatic hernia.

References

- [1]. Carter BN, Giuseffi J, Felson B. Traumatic diaphragmatic hernia. *Am J Roentgenol Radium Ther.* 1951;65:56-72. [PubMed] [Google Scholar]
- [2]. Dwari AK, Mandal A, Das SK, Sakar S. Delayed presentation of traumatic diaphragmatic rupture with herniation of the left kidney and bowel loops. *Case Rep Pulmonol.* 2013;2013:814632. [PMC free article] [PubMed] [Google Scholar]
- [3]. Rashid F, Chakrabarty MM, Singh R, Iftikhar SY. A review on delayed presentation of diaphragmatic rupture. *World J Emerg Surg.* 2009;4:32. [PMC free article] [PubMed] [Google Scholar]
- [4]. Palnivelu C, Rangarajan M, Rajapandian S, et al. Laparoscopic repair of adult diaphragmatic hernias and eventration with primary sutured closure and prosthetic reinforcement: a retrospective study. *Surg Endosc.* 2009;23:978-85. [PubMed] [Google Scholar]
- [5]. Townsend CM, Beauchamp RD, Jr, Evers BM, Mattox KL. *Sabiston textbook of surgery: the biological basis of modern surgical practice.* 18th ed. Philadelphia: W.B. Saunders; 2008. p. 1174. [Google Scholar]
- [6]. Wardi G, Lasoff D, Cobb A, Hayden S. Traumatic diaphragmatic hernia. *J Emerg Med.* 2014;46:80-2. [PubMed] [Google Scholar]
- [7]. Gelman R, Mirvis SE, Gens D: Diaphragmatic rupture due to blunt trauma: sensitivity of plain chest radiographs. *AJR Am J Roentgenol.* 1991, 156 (1): 51-57.
- [8]. Slim K, Bousquet J, Chipponi J: Laparoscopic repair of missed blunt diaphragmatic rupture using a prosthesis. *Surg Endosc.* 1998, 12 (11): 1358-1360. 10.1007/s004649900857.
- [9]. Power M, McCoy D, Cunningham AJ: Laparoscopic-assisted repair of a traumatic ruptured diaphragm. *Anesth Analg.* 1994, 78 (6): 1187-1189. 10.1213/00000539-199406000-00031.
- [10]. Pross M, Manger T, Mirow L, Wolff S, Lippert H: Laparoscopic management of a late-diagnosed major diaphragmatic rupture. *J Laparoendosc Adv Surg Tech A.* 2000, 10 (2): 111-114. 10.1089/lap.2000.10.111.
- [12]. Wise L, Connors J, Hwang YH, Anderson C: Traumatic injuries to the diaphragm. *J Trauma.* 1973, 13 (11): 946-950. 10.1097/00005373-197311000-00002.
- [13]. Igai H, Yokomise H, Kumagai K, Yamashita S, Kawakita K, Kuroda Y: Delayed hepatothorax due to right sided traumatic diaphragmatic rupture. *Gen Thorac Cardiovasc Surg.* 2007, 55 (10): 434-436. 10.1007/s11748-007-0158-y.

Dr. Sajal Gupta, et al. "Experiences of Surgery in Traumatic Diaphragmatic Hernia Repair Using Expanded Polytetrafluoroethylene (Eptfe)." *IOSR Journal of Dental and Medical Sciences (IOSR-JDMS)*, 19(3), 2020, pp. 26-36.