

Case Report Associated With a Literature Review: Simple Bone Cyst

Gardene Paiva MAGALHÃES¹, Evanildo Canuto PAZ², Mariana de Carvalho LEAL³, Maria Karen Vasconcelos FONTENELE⁴, Niza da Costa ALVES⁵, Antonio Henrique Borges FERRO⁶

(Graduating in Dentistry, University Center UNINOVAFAPI, Brazil)¹

(Graduating in Dentistry, University Center UNINOVAFAPI, Brazil)²

(Graduating in Dentistry, University Center UNINOVAFAPI, Brazil)³

(Graduating in Dentistry, Universidade Estadual do Piauí (UESPI), Brazil)⁴

(Graduating in Dentistry, UniFacid/Wyden, Brazil)⁵

(Oral and Maxillofacial Surgeon and Mastering in TMD, SÃO LEOPOLDO –MANDIC, Fortaleza, Brazil)⁶

Abstract: Simple bone cysts are pseudocysts affecting long bones and, less frequently, the jaws, especially the mandible. These cysts are generally detected during routine radiography, with the frequent observation of a well-delimited radiolucent area sending projections between the roots of the teeth involved. Simple bone cysts are mainly diagnosed during the second decade of life and have an excellent prognosis, but their etiology is uncertain. The aim of this paper is to report the case of a simple bone cyst in a 15-year-old adolescent seen at the Stomatology Outpatient Clinic, School of Dentistry, Federal University of Bahia. The etiology, clinical course and prognosis of this lesion are discussed based on a systematic review of the literature.

Keywords: Bone cyst, jaw, xrays.

Date of Submission: 13-04-2020

Date of Acceptance: 28-04-2020

I. Introduction

Since 1992, the World Health Organization (WHO) has proposed the term “solitary bone cyst” for lesions initially described by Lucas in 1929 and by Blum in 1932. However, hemorrhagic cyst, traumatic cyst, pseudocyst, simple bone cyst, extravasation cyst and idiopathic bone cavity are terms referring to the same type of lesion [1], [5]. Although the WHO recommends the terms solitary bone cyst, simple bone cyst is the term most frequently found in the literature. This variation in terminology reflects the uncertainties regarding the etiology and pathogenesis of traumatic bone cysts [1], [2], [4], [6], [8]. Among the different etiological possibilities, the trauma-hemorrhage theory has been defended by most investigators. This theory suggests that trauma to a bone unable to provoke a fracture results in an intraosseous hematoma. If the hematoma does not undergo organization and repair it may liquefy, with the consequent formation of a cystic defect. [8]. Simple bone cysts have been reported in almost all bones of the body, notably long bones such as the humerus and femur [3], [4], [7], [16]. Involvement of the jaws is common and these cysts more frequently affect patients between 10 and 20 years of age. The prevalence of simple bone cysts is higher among men than women, with a male:female ratio of about 1. Among the facial bones, involvement of the maxilla is rare [9], [13], with simple bone cysts being more commonly found in the posterior portion (area of the molars) of the mandible [1], [2], [8]. There are reports of simple bone cysts at unusual sites such as the condylar and coronoid processes and zygomatic arc [2], [12].

Simple bone cysts normally do not produce symptoms and are discovered during radiographic exams requested for other reasons [1], [3], [8], [10], [13]. The presence of pain, edema, paresthesia, displacement and root resorption of the involved tooth, fistula and pathological fracture has been reported on rare occasions [14]. Pulp vitality is unlikely to be altered even in the case of teeth in which the roots are associated with the lesions. However, cystic expansion may increase the root pressure due to traumatic force, with a consequent temporary reduction in the response to the electric pulp test [13].

Periapical radiographs can be used for radiographic assessment but these radiographs do not encompass the whole extent of the lesion. Panoramic radiography, computed tomography and magnetic resonance are more precise imaging exams in the diagnosis of simple bone cysts [13]. Radiographically, most lesions appear as a well-delimited radiolucent defect [2], [9]. Simple bone cysts range in diameter from 1 to 10 cm [9]. Margins with good definition in contrast to areas with less precise limits might be observed in the same lesion [8], [12]. Cysts may become radiopaque over time, an event corresponding to new bone formation. This alteration has not

been observed in young individuals since it is a late finding during the healing process of the cyst. When the cyst involves various teeth, the radiolucent defect frequently shows projections resembling upward bent cupolas insinuating between the dental roots. This feature is highly suggestive of a simple bone cyst [8]. Although this is not a characteristic of these lesions, simple bone cysts may occasionally appear as amultilocular radiotransparency associated with corticalexpansion and tumefaction of slow growth [8], [14].

Computed tomography is an important auxiliary tool for the diagnosis of intraosseous lesions such as odontogenic tumors and cysts, as well as for the identification of the precise location of important related anatomical structures, such as the eminence of the mental foramen, mandibular canal, maxillary sinus, nasal cavities and proximity to the roots of adjacent teeth [15]. Magnetic resonance imaging provides a view of multiple planes with a contrast to soft tissue and permits the analysis of the interior of the lesions, showing the presence or absence of fluid and thus contributing to a better distinction between simple bone cysts and other odontogenic or non-odontogenic lesions [13].

The walls of the defect might be lined with a thin layer of vascular fibrous connective tissue or may demonstrate proliferation of a thickened myxofibromatous matrix frequently intermingled with cellular and reactional bone trabeculae. This lining may exhibit areas

of vascularization, fibrin, erythrocytes and occasional giant cells adjacent to the bone surface. There is no evidence of any epithelial lining. The bone surface close to the cavity frequently presents areas of resorption (Howship's lacunae) indicative of past osteoclastic activity [8], [12].

We report here the case of a simple bone cyst in a 15-year-old adolescent seen at the Stomatology Clinic, School of Dentistry, at Federal University of Bahia, Brazil. A systematic literature review is presented, discussing the etiology, clinical course and prognosis of this lesion.

II. Technique Description

Patient R.D.L., a 15-year-old white boy, a student, born in Salvador, Bahia, was referred to the Stomatology Clinic of Federal University of Bahia, by his orthodontist, who noticed the presence of a radiolucent area on the right side of the mandible during the examination of radiographs for orthodontic documentation. During anamnesis, the patient reported that he was unaware of the lesion which had been asymptomatic. When asked about his medical-dental history, the patient reported that he had had chicken pox and had been submitted to herniorrhaphy during childhood.

Clinical examination showed no swelling or other significant sign in the area. Radiographically, the lesion presented as a well-delimited unilocular radiolucent area in the periapical region of teeth 4.2 and 4.3. The lesion produced no resorption of the root or lamina dura and the teeth involved presented preserved pulp vitality (Figure 1 – A and B).

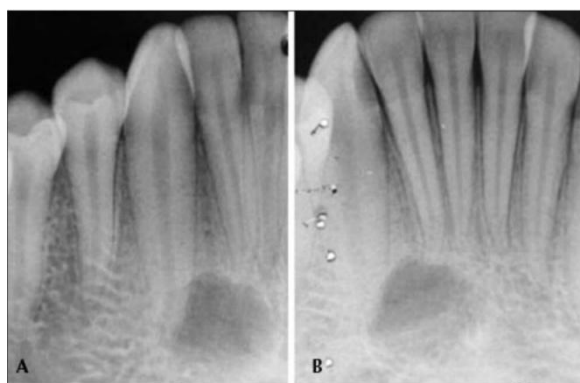

Figure 1 (A and B). Preoperative radiographic aspects

For better assessment computed tomography was performed which revealed a single-cavity lesion in the right anteroinferior region. The lesion presented a regular and well-defined, but not completely corticalized, contour and was associated with the roots of teeth 4.2 and 4.3 but did not promote root resorption. In addition, the lesion caused erosion of lingual cortical bone but without distending it. The intralésional density was inconclusive, with values indicating the presence of a thick fluid or fibrous tissue, thus raising doubts regarding the diagnosis of traumatic bone cyst or odontogenic keratocyst (Figure 2 – A and B).

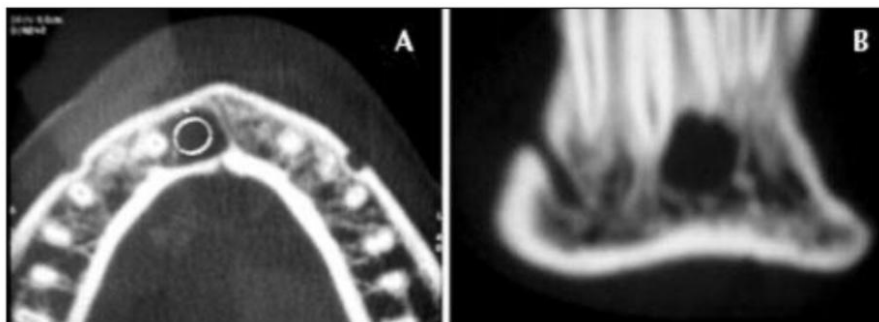


Figure 2. Sagittal (A) and coronal (B) computed tomography images

On the basis of the findings, surgical treatment was indicated. No cellularized lesion or cystic content was observed during the surgical procedure, with the observation of a clearly visible cavity with intact bone walls which led to the diagnosis of traumatic bone cyst (Figure 3).

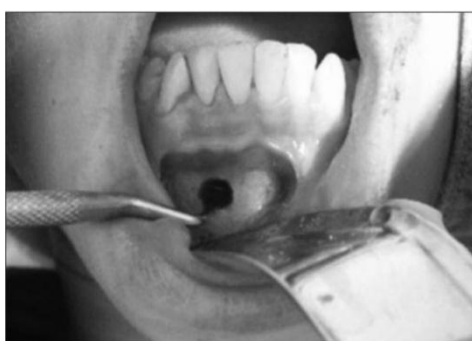

Figure 3. Transsurgical aspect

Material was collected for histopathological examination and bleeding induced inside the cavity showed the lack of a capsule or membrane. Histopathological analysis of the collected material showed the presence of small bone spicules usually next to the hemorrhagic exudate. This finding, together with the clinical data, permitted the definitive diagnosis of a simple bone cyst.

Six months after the surgical intervention a new radiograph was taken (Figure 4), which revealed a slightly radiopaque area, a finding indicating new bone formation.

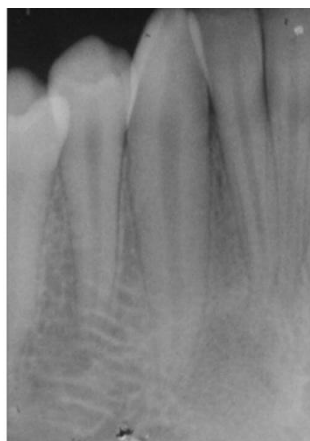

Figure 4. Radiograph obtained 6 months after surgical intervention

III. Discussion

The etiology of simple bone cysts is still uncertain, but some investigators have suggested an association with Trauma [8], [12]. However, no such association was observed in the present case. Some theories have been raised to explain the clinical and pathological characteristics of this disease [8]. The trauma-hemorrhage theory has been extensively defended, as demonstrated by the wide use of the term itself, i.e.,

traumatic bone cyst. This theory suggests that trauma to a bone unable to cause a fracture results in an intraosseous

hematoma. If the hematoma does not undergo organization and repair it may liquefy, with the consequent formation of a cystic defect. Some patients may recall an episode of trauma to the affected region, but the significance of this information is uncertain [8]. Other etiologic theories include the incapacity of interstitial fluid to leave the bone because of inadequate venous drainage, local disturbances in bone growth, ischemic necrosis of bone marrow and altered bone metabolism resulting in osteolysis, in addition to intraosseous vascular deformities, benign neoplastic degenerative lesions, altered calcium metabolism, low-grade infections, venous obstruction and bone tumors undergoing cystic degeneration [1].

The radiographic features of the present case agree with those reported by most investigators who characterize a simple bone cyst as a predominantly round or oval well-delimited radiotransparency with regular or irregular margins but well-defined by a delicate cortical layer. The lesion may extend between the roots of the erupted teeth, producing a characteristic jagged contour [8], [12].

Although frequently suggestive, the radiographic features of simple bone cysts are not definitive for the diagnosis [8], [12], with the need for a combined analysis of clinical history, physical exam, imaging findings, surgical exploration and histopathological results [13]. Otherwise, simple bone cysts might be confused with a wide variety of odontogenic and non-odontogenic radiolucent lesions of the jaws.

Matsumura *et al.* (1998) suggested that the size of the radiolucent lesion and the extent of cortical bone expansion of the cysts should be monitored by radiography and that these cysts should be treated surgically if the findings indicate growth. First, the diagnosis of a simple bone cyst (no growth) should be established and the lesions should be monitored radiographically. However, according to Castro and Paro [12] (2002) simple bone cysts cannot be identified positively only based on the history of the patient and on the clinical and radiographic features. Thus, these authors do not recommend that a lesion suspected to be a simple bone cyst be only radiographed periodically.

In the case of simple bone cysts, a differential diagnosis is necessary to exclude the possibility of other lesions such as a dentigerous cyst, odontogenic keratocyst, adenomatoid odontogenic tumor, ameloblastoma and central giant cell granuloma, or even the association with other diseases such as thrombocytopenic purpura [13]. The present case agrees with Castro and Paro [12] (2002) since computed tomography revealed inconclusive intralésional density values indicating the presence of thick fluid or fibrous tissue. In addition, the lesion presented a regular contour in the absence of root resorption and distension of cortical bone, raising doubts regarding the possible diagnosis of an odontogenic keratocyst or simple bone cyst. Thus, surgical exploration was necessary to establish the diagnosis. In the case of gnathic bone lesions, simple surgical exploration is normally sufficient for the establishment of the diagnosis. Although the bone walls of the cavity are frequently smooth and bright, curettage is recommended during surgical exploration for the collection of tissue specimens for microscopic examination in order to rule out the possibility of more severe diseases. A lesion classified as a simple bone cyst during surgical exploration will occasionally prove to be a lesion with a thin lining such as an odontogenic keratocyst or ameloblastoma during microscopic examination. Surgery was the treatment of choice in the present case, as recommended by other investigators [1], [4], [12] [13].

The treatment of simple bone cysts is based on surgical exploration to induce bone formation [2], [5], [13], [16]. Healing occurs about 6 to 24 months after bleeding and closure of the area, a fact justifying periodic radiographs performed at 6 and 12 months for the confirmation of bone repair, with the case being concluded after complete healing of the tissue [8], [16]. In the present case, 6 months after surgical intervention a new radiograph was taken which showed a mild radiopacity at the site of the lesion, indicating the occurrence of the healing process through new bone formation.

Although observed in some cases, recurrence or persistence of simple bone cysts is highly uncommon and the prognosis is therefore excellent. Follow-up at 1 or 2 years is sufficient in view of the slow growth of recurrent lesions. In most cases, cure or recurrence is confirmed within 3 years after surgery. Once access to the cavity is established, the surgeon only needs to promote bleeding of the lesion before its closure. Bone repair commonly occurs after formation of a clot, with few chances of recurrence. Aspiration prior to surgery has been performed to prevent accidents in cases of vascular intraosseous lesions. An antibiotic cover should be applied after surgical intervention in view of the possible formation of an intraosseous hematoma [12].

IV. Conclusion

On the basis of a literature review and clinical follow-up of a patient with a radiolucent lesion diagnosed as a simple bone cyst, we conclude that this lesion is of uncertain etiology and that it can be considered a pseudocyst because of the absence of epithelial lining. The final diagnosis should be established considering clinical-anamnesis, radiographic, imaging, surgical and histological findings. Surgical treatment is important for the establishment of the final diagnosis because, radiographically, simple bone cysts of the mandible resemble a series of other intraosseous lesions. Thus, radiographic follow-up for one or two years after surgical treatment is

necessary for the confirmation of a possible cure or recurrence. A review of the literature showed a low rate of recurrence and an excellent prognosis of simple bone cysts of the mandible not associated with other lesions.

References

- [1]. Matsumura S, Murakami S, Kakimoto N, Furukawa S, Kishino M, Takeshi I *et al.* Histologic and radiographic findings of the simple bone cyst. *Oral Surg Oral Med Oral Pathol Oral Radiol Endod.* 1998;85:619-25.
- [2]. Sverzut CE, Gomes PP, Sverzut AT, Tozetto ALG. Cisto ósseo solitário: relato de um caso clínico. *Rev Dent Press Ortodon Ortop Maxilar.* 2002;7:63-7.
- [3]. Copete MA, Kawamata A, Langlais RP. Solitary bone cyst of the jaws. Radiographic review of 44 cases. *Oral Surg Oral Med Oral Pathol Oral Radiol Endod.* 1998;85:221-5.
- [4]. Fregnani ER, Ramos FMM, Nadalin MR, Silva-Sousa YTC, Perez DEC. Simple bone cyst: possible misdiagnosis in periapical pathology. *Gen Dent.* 2007;55:129-31.
- [5]. Swei Y, Taguchi A, Tanimoto K. Simple bone cyst of the jaws: evaluation of treatment outcome by review of 132 cases. *J Oral Maxillofac Surg.* 2007;65:918-23.
- [6]. Azevedo RA, Marques JAF, Soares SS, Carneiro Júnior B, Santana SI. Cisto ósseo simples: relato de casos clínicos. *BCI.* 2002;9:139-43.
- [7]. González HJ, Moret CY. Quiste ósseo traumático bilateral asociado a tratamiento de ortodoncia. Presentación de un caso y revisión de la literatura. *Acta Odontol Venez.* 2001;40:116-6.
- [8]. Puricelli E, Chaves KDB, Ligocki AF, Moresco FC, Rovani G, Rosolen MA *et al.* Cisto ósseo traumático em área de rizogênese: relato de um caso. *Rev Fac Odontol Porto Alegre.* 1997;38:19-25.
- [9]. Neville BW, Dam DD, Allen CM, Bouquot JE. *Patologia oral emaxilofacial.* 2.^a ed. Rio de Janeiro: Guanabara Koogan; 2004. ALMEIDA, D. C. D.; MACHADO, W. A. S.; TOSTES, F. R. V.; SANTANA, R. B.; *Interrelação entre insuficiência renal crônica em hemodiálise e doença periodontal;* 2009.
- [10]. Teixeira RG, Bueno CES, Miranda ME, Höfling RTB, Bussadori SK. Cistos ósseos simples. Análise clínica e radiográfica de 22 casos na mandíbula. *Rev Gaúcha Odontol.* 2003;51:243-8.
- [11]. Ferreira Júnior FO, Damante JH, Lauris JR. Simple bone cyst versus odontogenic keratinocyst: differential diagnosis by digitized panoramic radiography. *Dentomaxillofac Radiol.* 2004;33:373-8.
- [12]. Castro AL, Paro MLC. Cisto ósseo traumático em mandíbula. *RFO UFP.* 2002;39-42.
- [13]. Lago CA, Cauás M, Pereira AMP, Portela L. Cisto ósseo traumático em mandíbula: relato de caso. *Rev Cir Traumatol Buco-Maxilo-Fac.* 2006;6:17-22.
- [14]. Swei Y, Taguchi A, Kurabayashi T, Kobayashi F, Nojiri M, Tanimoto K *et al.* Simple bone cyst: investigation on the presence of gas in the cavity using computed tomography. *Oral Surg Oral Med Oral Pathol Oral Radiol Endod.* 1998;86:592.
- [15]. Paiano GA, Chiarelli M, Dunker C. Tomografia computadorizada como método auxiliar no diagnóstico e tratamento de lesões intra-ósseas: caso clínico de odontoma composto. *Rev Odonto Ciênc.* 2006;21:292-6.
- [16]. Tong AC, Ng Io, Yan BS. Variations in clinical presentations of simple bone cyst: report of cases. *J Oral Maxillofac Surg.* 2003;61:1487-91.

Gardene Paiva MAGALHÃES, et al. "Case Report Associated With a Literature Review: Simple Bone Cyst." *IOSR Journal of Dental and Medical Sciences (IOSR-JDMS)*, 19(4), 2020, pp. 06-10.