

Results of Epithelium-On Crosslinking in Keratoconus

SERGHINI louai , KARMOUN souhayla , CHABBAR imane , LALAOUI
abdelkrim , ABDALLAH elhassan , BERRAHO Amina

Date of Submission: 25-03-2020

Date of Acceptance: 14-04-2020

I. Introduction :

Keratoconus is a fairly frequent progressive corneal dystrophy involving the stroma, crosslinking is one of the therapeutic means making it possible to slow or stop the progression of the disease, several techniques: EPITHELIUM-ON, EPITHELIUM-OFF OR by iontophoresis.

The aim of our work is to assess the effectiveness of crosslinking without removal of the epithelium (EPITHELIUM-ON) in the treatment of keratoconus

II. Materials And Methods :

This is a retrospective study on 12 patients followed for progressive keratoconus, all our patients benefited from a careful personal and family anamnesis, a complete ophthalmological examination with automated refraction and initial corneal topographies and controls .

They benefited from crosslinking without removal of the epithelium (EPI-ON technique), with instillation of topical anesthetic and Riboflavin trans-epithelial 01 drops every 05 minutes for 30 minutes, followed by a photo-exposure of ultraviolet for 30 minutes, our patients were put on topical antibiotic therapy based on Tobramycin for 07 days after.

III. Results:

The average age of our patients was 23 years, with extremes ranging from 14 to 32 years.

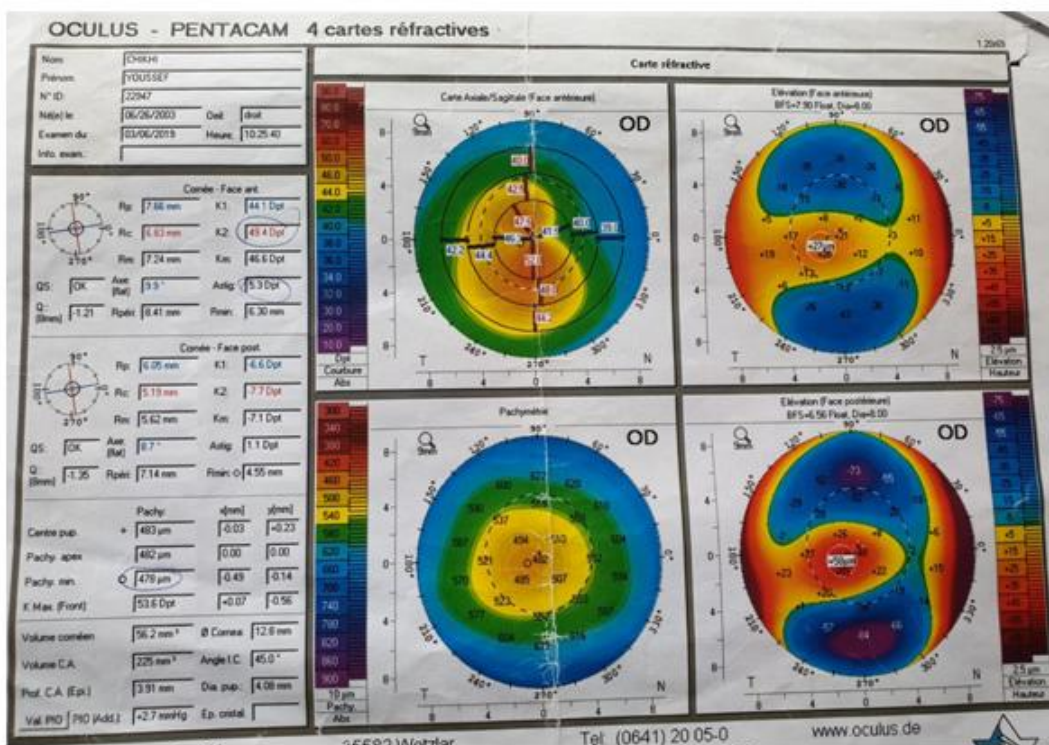
There is a female predominance at 72%.

It was stage 3 keratoconus in 25% of cases, stage 2 in 58.3% and stage 1 in 16.7%.

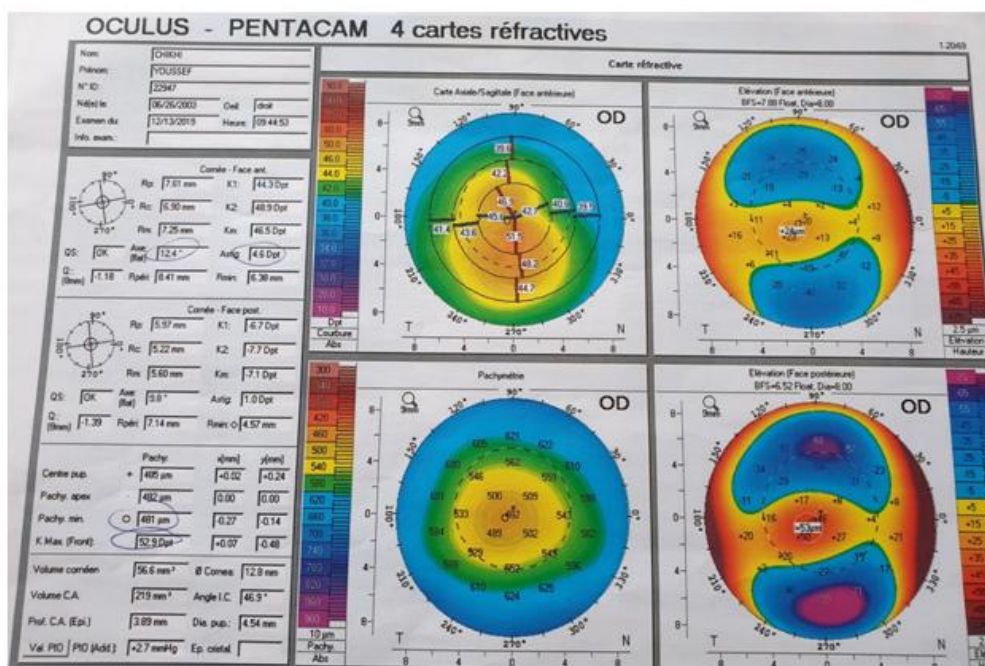
Keratoconus was secondary to allergic conjunctivitis in 87% of cases, idiopathic in the rest and in 02 cases it was a familial form.

83.3% of the patients had a stabilization of the maximum keratometry and the minimum pachymetry over a follow-up of 03 to 06 months.

The 02 patients with a familial form presented a worsening of their maximum keratometry and corneal thinning.



Corneal topography before crosslinking epi-on



Corneal topography after crosslinking epi-on

IV. Discussion

Crosslinking is an important tool allowing to stabilize the evolution of keratoconus, the effectiveness of the technique without removal of the epithelium is as effective on the pathology as this objectified our study.

It presents less risk of infections or corneal complications compared to the technique with epithelial removal. It represents an emergency in children and adolescents, as is the case for 03 of our patients.

Family forms remain difficult to manage and rebel against crosslinking, which can require more than one operation, and this was also shown by our study.

Trans-epithelial riboflavin gives us better results thanks to its significant diffusion power through the epithelium to the corneal stroma.

Corneal topography remains the only and best way to control efficiency and progress after crosslinking.

After the disease has stabilized, it is important to try to have the best correction for the best possible visual acuity.

V. Conclusion

Crosslinking EPI-ON like EPI-OFF has advantages and limits, hence the importance of adapting the best suitable means for each case.

SERGHINI louai,etal. " Results of Epithelium-On Crosslinking in Keratoconus." *IOSR Journal of Dental and Medical Sciences (IOSR-JDMS)*, 19(4), 2020, pp. 59-61.