

A Comparative Study of Changes in Rim Area, Cup Area and Intra Ocular Pressure In Primary Open Angle Glaucoma before and After Trabeculotomy.

Dr. Yash Pal Sharma, Dr. Vinod Sharma, Prof. Dr. M. L. Pandey,
Dr. Kalpana Sharma.

Correspondance: Dr. Yash Pal Sharma, Civil Hospital Rohru, Distt Shimla, H.P. 171214 India.

Abstract:

Purpose: To study the relation between Rim area, Cup area and intra ocular pressure within 1 week pre-operative and 1 week, 1 and 3 month post-operatively in a population of clinical patients with primary open angle glaucoma undergone trabeculectomy in the Sub-Himalayan region.

Methods: Patient sample size consisting of n=27 were accessed for primary open angle glaucoma. The sample population consists of adults with open anterior chamber angle and with demonstrative RNFL damage, with corresponding visual field loss. Average Rim area, Cup area measurements were taken on Topcon 3D OCT-1 Maestro. Intra ocular pressure is measured by using a Goldman's Applanation Tonometer. and intra ocular pressure within a week before surgery and at 1 week, 1 and 3 month post operatively. Pre and post operative value were analyzed using Repeated Measure ANOVA with Bonferroni correction.

Results: It was observed that the Mean Rim Area at 3rd month post operatively was 0.6707 ± 0.29319 ($p=.008$) and Mean Cup Area at third month post-operatively was observed to be 1.9393 ± 0.58619 ($p=0.027$). Cup Area showed significant improvement at 3rd month post-operatively. The Mean IOP in the pre-operative period was found to be 26.93 ± 2.786 . There was a decrease in the IOP at first week and first month of the post operative period. In the third month of the observation period the Mean IOP was observed 11.81 ± 3.552 ($p < 0.05$).

Conclusions: The present study showed a significant improvement in the rim area and cup area after reduction of IOP post-Trabeculectomy

Keywords: Optical Coherence Tomography; Trabeculectomy; Rim Area, Cup Area, Intra Ocular Pressure, Primary Open Angle Glaucoma;

Date of Submission: 07-04-2020

Date of Acceptance: 21-04-2020

I. Introduction:

Glaucoma is a group of acute and chronic, progressive, multi-factorial optic neuropathies in which intraocular pressure (IOP) and other contributing factors are responsible for a characteristic, acquired loss of retinal ganglion cell axons leading to atrophy of the optic nerve with demonstrable visual field defects. Prevalence of Glaucoma is 2.65% in people above 40 year of age globally. In India the estimated number of cases of Glaucoma is 12 million. Globally POAG is more prevalent than PACG and responsible for around ¾th of all glaucoma cases. Glaucoma is estimated to affect approximately 70 million people worldwide in the years to come, this disease is expected to affect even greater populations, and especially as the elderly population grows, disproportionately. Glaucoma is known to be multi-factorial in origin, with established genetic and biological risk factors ¹.

The glaucoma's are classified by the appearance of the irido-corneal angle. There are open angle, closed-angle, and developmental categories, which are further divided into primary and secondary types. Primary open-angle glaucoma can occur with or without elevated intraocular pressure; the latter is sometimes called normal-tension glaucoma. Primary open-angle glaucoma, in which the irido-corneal angle is open (unobstructed) and normal in appearance but aqueous outflow is diminished ².

The cardinal feature of glaucomatous optic neuropathy is the loss of NRR from the inner edge of the rim. This loss can occur in all sections of the disc with regional preference depending on the stage of glaucoma. The sequence of loss is usually first in the infero-temporal and supero-temporal disc regions. So for early diagnosis these areas should be carefully evaluated for glaucomatous changes. In moderate disease the temporal part of the horizontal disc is involved and in advanced glaucoma the rim remnants are located mainly in the nasal sectors. The neuro-retinal rim is the most important parameter of the optic disc evaluation. The optic disc is vertically oval and the cup is horizontally oval thus the rim has a characteristic configuration where the

inferior (I) rim is the widest, followed by the superior (S) and nasal rims (N) and the temporal (T) rim is the thinnest³.

OPTICAL COHERENCE TOMOGRAPHY:

Present machine that was used for study was Topcon 3D OCT-1 Maestro that is installed at the Department of Ophthalmology I. G. M. C Shimla. Optical coherence tomography (OCT) is a diagnostic imaging technique that provides cross-sectional images of human retinal morphology in vivo. Huang and associate first invented OCT in 1991, the first SD-OCT became commercially available in 2006. Optical coherence tomography (OCT) is the optical analogue to ultra-sonography and measures the echo time delay and magnitude of reflected or backscattered light using the principle of Michelson low-coherence interferometry. Cross-sectional images are obtained by measuring the backscattered light while scanning across multiple sites in a transverse fashion. Echoes from a single point on the retina represent an axial scan (A-scan), and optical cross-sections (B-scans) are obtained by directing the OCT beam in the transverse direction. The data obtained are displayed as false-colour or grey-scale images. The position of the reference mirror is altered in order to obtain reflected light from the retina at several different depths. Spectral domain OCT allows for unprecedented simultaneous ultrahigh speed and ultrahigh resolution ophthalmic imaging without a loss in image quality, and 2D images can be obtained in 1/29th of a second. Spectral domain OCT can image 14,600 to over 29,200 A-lines per second. Spectral domain OCT resolutions of about 2 µm can be achieved with the appropriate light source. Spectral domain OCT can create 3-dimensional (3D) images as well as videos of large areas of the posterior pole⁴.

TRABECULECTOMY

With its long-established history, remains widely practiced for glaucoma. Studies are robust in supporting its efficacy in lowering IOP²⁰. Trabeculectomy is a surgical operation which lowers the intraocular pressure (IOP) inside the eye in patients with glaucoma. This is achieved by making a small hole in the eye wall (sclera), covered by a thin trap-door in the sclera. The fluid inside the eye known as aqueous humour, drains through the trap-door to a small reservoir or bleb just under the eye surface, hidden by the eyelid. The trap-door is sutured (stitched) in a way that prevents aqueous humour from draining too quickly. By draining aqueous humour the Trabeculectomy operation reduces the pressure on the optic nerve and prevents or slows further damage and further loss of vision in glaucoma. Control of the eye pressure with a Trabeculectomy will not restore vision already lost from glaucoma⁵.

II. Materials And Methods

The present study was conducted in the Department of Ophthalmology, Indira Gandhi Medical College, Shimla. The number of patients undergoing trabeculectomy were n= 27. Data was collected from one eye only, if both eyes required surgery then the one with the greater intraocular pressure (IOP) and glaucoma progression was taken in study. The criteria for inclusion were patients aged 40–80 years with diagnosis of POAG. The patients with previous glaucoma surgery, cataract surgery, retinal, or neurological disease affecting VF were excluded from the study. While the patient was under maximally tolerant medication, the indication for surgery was optic nerve head parameter and RNFL which was high risk of glaucomatous progression as well as worsening of the VF. After trabeculectomy, the OCT scans of the patients were repeated at 1- week, 1- month, and 3- month postoperatively. The stimulus for this work was only ophthalmological for the exploration of RNFL and IOP by using the maximum means at our disposal. Informed consent was obtained from all recruited individuals. Each subject underwent extensive examination including Best Corrective Visual Acuity (BCVA) by using Snellen's chart. Slit lamp bio-microscopy was done to assess the ocular adnexa and the anterior segment (AC Depth using Van Herrick's Grading) of eye using a slit lamp bio-microscope (Haag Striet-900). Intra ocular pressure is measured by using a Goldman's applanation tonometer. An open anterior angle chamber using Gonioscopy by Shaffer's system using Goldman Single Mirror Gonioscopic Lens. Optic Disc Examination- for glaucomatous changes was performed in dilated pupil with slit lamp (Haag Striet-900) using 90D lens (Magnification= 0.76). Fundus examination was done by using the direct and indirect ophthalmoscope after pupillary dilatation using 5% phenylephrine and 1% tropicamide drops instilled once or twice as required. Perimetry for visual field analysis using octopus 900 automated perimetry machine. Optical Coherence Tomography (3D OCT-1MAESTRO) was used for studying RNFL thickness. The RNFL map represents a 6 x 6 mm cube of A-scan data centered over the optic nerve in which a 3.4 mm diameter circle of RNFL data is extracted to create what is referred to as the ISNT map (inferior, superior, nasal and temporal). Each resulting image will consist of RNFL thickness measurements along a 360-degree circle around the optic disc. It is displayed as a false color scale with the thickness values referenced to a normative database. All OCT scans were acquired by an experienced operator. OCT scans were obtained after pupillary dilatation using 5%

phenylephrine and 1% tropicamide drops instilled once or twice as required. All baseline scans was acquired within 1 weeks of the planned surgery. The parameters studied were RNFL Thickness in each quadrant.

Surgical Technique:

No pupillary dilatation and a bridle suture/corneal Traction Suture were inserted (commonly superior cornea). Site of Trabeculectomy was supero-nasal or supero-temporal. A fornix based flap of conjunctiva and Tenon capsule was fashioned superiorly. Epi-scleral tissue was cleared and major vessels cauterized. An incision was made through about 50% of sclera thickness to create a trap-door lamellar sclera flap. This flap was triangular according to preference. The superficial triangular flap was dissected forwards until clear cornea is reached. A paracentesis was made in temporal peripheral clear cornea and air injected. The anterior chamber was entered along most of the width of the trapdoor base. Sclerotomy incision was 1mm clear of either side of sclera flap. After the initial linear incision into anterior chamber sclerotomy is fashioned with sclera punch. A fistula 0.5mm to 1mm in height and 1.5 to 2mm in width created. Peripheral iridectomy was created. Superficial scleral flap was sutured to its underlying bed tightly with Apex sutures, using nylon 10-0 suture. Balanced salt solution was injected through the paracentesis to deepen the anterior chamber and test the patency of the fistula. Conjunctiva/Tenon capsule flap was sutured. Irrigation through the paracentesis was repeated to produce a bleb. Steroid and antibiotic was injected under the inferior conjunctiva. Postoperative analysis of IOP and RNFL were done at 1 week, 1 and 3 month respectively. All data was collected on data forms.

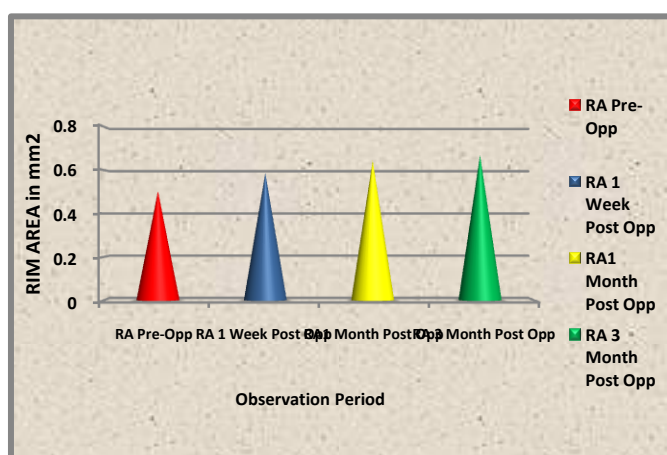
STATISTICAL ANALYSIS:

Data collected during the study was tabulated and analyzed by using Repeated Measure ANOVA with Bonferroni correction. The probability value ('p'-value) was calculated and a value of <0.05 was implied to be statistically significant.

III. Result:

In the current study the results were found to be significant. Rim Area found pre-operatively to be 0.5037 ± 0.27646 . The reading for the Rim Area was taken 1 week post operatively it was observed that the mean values was 0.587 ± 0.26172 ($p=0.124$). The Rim Area was then observed in the follow-up period of 1 month post operatively in this period it was seen that the mean value is 0.6452 ± 0.25913 ($p=.044$). Mean Rim Area in the 3 month post operatively of follow up period was observed to be 0.6707 ± 0.29319 ($p=.008$).

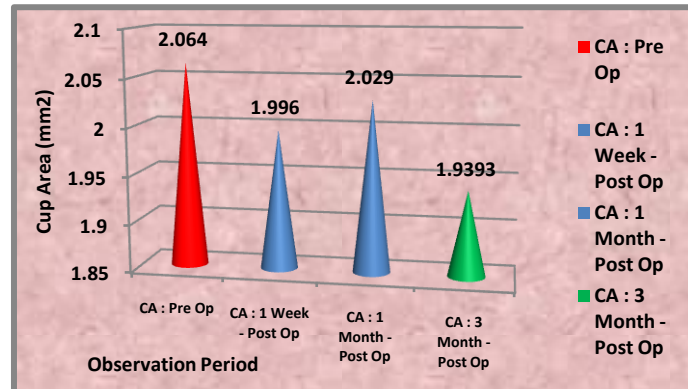
	MEAN	Standard Deviation	p-value
RA Pre-Op	0.5037	±0.27646	
RA 1 Week Post Op	0.587	±0.26172	(p=0.124)
RA1 Month Post Op	0.6452	±0.25913	(p=.044)
RA 3 Month Post Op	0.6707	±0.29319	(p=.008)



The mean Cup area during the first week of post-operative period came to be 1.996 ± 0.5082 ($p=0.951$). The Cup Area observed during the first month of the follow-up was 2.029 ± 0.5336 ($p=1.000$). During the third month of the follow-up the Mean Cup Area was observed to be 1.9393 ± 0.58619 ($p=0.027$).

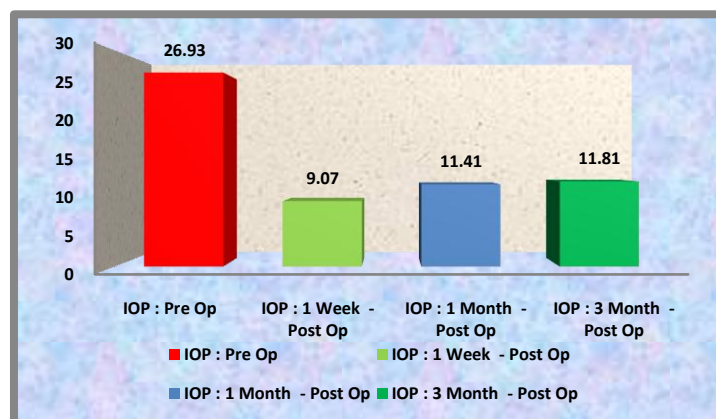
	Mean	Standard Deviation	p-value
--	------	--------------------	---------

CA : Pre Op	2.064	±0.5043	
CA : 1 Week - Post Op	1.996	±0.5082	P=0.951
CA : 1 Month - Post Op	2.029	±0.5336	p=1.000
CA : 3 Month - Post Op	1.9393	±0.58619	p=0.027



The Mean in the pre-operative period was found to be 26.93 ± 2.786 . There was a decrease in the post-operative first week and the Mean was observed to be 9.07 ± 3.43 ($p < 0.05$). In the first month of the post operative period was to be 11.41 ± 4.254 ($p < 0.05$). In the third month of the observation period the Mean was observed 11.81 ± 3.552 ($p < 0.05$).

	MEAN	Standard Deviation	p-value
IOP : Pre Op	26.93	± 2.786	
IOP : 1 Week - Post Op	9.07	± 3.43	($p < 0.05$)
IOP : 1 Month - Post Op	11.41	± 4.254	($p < 0.05$)
IOP : 3 Month - Post Op	11.81	± 3.552	($p < 0.05$)



IV. Discussions:

One of the main reasons for a perceptible improvement in optic nerve appearance with IOP reduction is a reduction in the posterior bowing of the lamina cribrosa, giving relief to the compressed nerve fibre bundles. Similarly increase in RNFL thickness postoperatively is the reversal or rebound of the physical compressive effect on the RNFL by the elevated pre intervention IOP, leading to a recovery of normal shape and size by the retinal ganglion cell axons.^{6, 7, 8, 9, 10, 11.}

The aim of trabeculectomy is constant maintenance of reduction of IOP in order to prevent further damage to visual function with the main goal to improve or preserve the patient's quality of life. The procedure of trabeculectomy has moderate success in controlling the IOP¹⁰. Trabeculectomy has become the standard filtering operation for uncontrolled glaucoma, and the beneficial effect of reducing the IOP has been shown in several studies^{10,17}.

In our study IOP decreased from 26.93 ± 2.786 mm Hg pre-operatively to 9.07 ± 3.43 mm Hg ($p < 0.05$) at one week Post-operatively. IOP then reduced to 11.41 ± 4.254 mm Hg ($p < 0.05$) at one month to 11.81 ± 3.552 mm Hg ($p < 0.05$) at third month respectively after Trabeculectomy. This corresponds to reduction of IOP to about 33.7% at one week and 42.3% and 43.8% at one month and third month respectively as compared to pre-operative IOP. The reduction in IOP was statistically significant in all post operative follow-up period. Similar results were also observed by Figus *et al* (2011) they studied that IOP decreased from 24.4 ± 5.0 mmHg pre-operatively to 12.1 ± 3.1 mmHg ($P < 0.001$) and 10.6 ± 2.8 mmHg ($P < 0.001$), respectively, at 3 and 6 months after trabeculectomy; this corresponded to a reduction of $48 \pm 18\%$ at 3 months and of $54 \pm 20\%$ at 6 months¹⁴. Bertrand *et al* (2014) observed in his study that trabeculectomy resulting in at least 36% reduction in IOP and was effective in considerably reducing the rates of change in the visual field in his study population¹⁷. Yildirim¹⁵, Sarkar⁹, Kotecha¹⁰, Lazaro¹⁶ Raghu⁶ appear to support the idea that pressure reduction in glaucoma patients invariably prevents the long-term progression of visual field defects.

The reduction in IOP was associated with an increase in the neural rim area and a decrease in the cup size, probably due to anterior shifting of the LC¹⁸.

Mean Rim Area within 1 week pre-operatively was 0.5037 ± 0.27646 at 1 week post operatively mean was 0.587 ± 0.26172 ($p=0.124$). The mean value at 1 month was 0.6452 ± 0.25913 ($p=.044$). Mean Rim Area at 3rd month post operatively of was 0.6707 ± 0.29319 ($p=.008$). The Rim area showed statistically significant improvement at 1st month and 3rd month post operatively. The Rim Area showed improvement in the follow-up period though significant improvement was observed at 1 month and 3rd month post-operatively. Similarly Rim Volume was analyzed and showed significant improvement during the follow-up period after Trabeculectomy. Similar results were observed by Figus *et al* (2011) he observed that borderline ONH changes and negligible functional changes were found. The lack of an absolute structure–function correlation may be due to the different levels of measurement noise displayed by the devices used to detect change, and it has been suggested that structural and functional methods can be considered as independent indicators of glaucoma damage. Irak *et al* (1996) observed that mean rim area and rim volume increased significantly after trabeculectomy.

In our study Cup Area pre-operative value within 1 week was 2.064 ± 0.5043 . The mean at first week post-operative period was 1.996 ± 0.5082 ($p=0.951$). The Mean value at first month was 2.029 ± 0.5336 ($p=1.000$). At third month the Mean Cup Area was observed to be 1.9393 ± 0.58619 ($p=0.027$). Cup Area showed significant improvement at 3rd month post-operatively. Cup Area decreased during the post-operative follow-up period but statistical significance was observed at third month. Whereas Cup Volume decreased consistently in post-operative period, showing statistical significance through-out the follow-up.

In the present study cup area showed similar results, Irak *et al* (1996) defines Mean cup area decreased significantly after surgery. In adult patients, reversal of glaucomatous optic disc cupping is not generally recognized in clinical practice. However, reports have noted evidence of optic disc cup reversibility after intraocular pressure reduction in some adult patients using a variety of diagnostic methods. Similar study was done by Raghu *et al* (2012) In his study Among the ONH parameters he observed that the cup area decreased significantly at 1 week from 2.33 ± 0.5 mm² preoperatively to 2.0 ± 0.61 mm² at 1 week ($P \leq 0.014$), but reverted close to baseline values by 3 months⁶. Paranhos *et al* (2006) studied Δ IOP and Δ IOP% had a statistically significant effect on Δ cup area. Changes in cup shape size were influenced significantly only by Δ IOP. Some optic disc parameters measured by HRT presented a significant improvement after filtering surgery, depending on the amount of IOP reduction¹³.

V. Conclusion:

The present study showed a significant improvement in the rim area and cup area after reduction of IOP post-Trabeculectomy. Although, long-term studies are needed to determine the usefulness of these findings as outcome in the management of glaucoma. The major constrain in this kind of study is small sample size and short observational period. We need to have long follow-up period to attain the authentication of the final results in management and improvement of Primary Open Angle Glaucoma post- Trabeculectomy.

FINANCIAL SUPPORT AND SPONSORSHIP The work was an original research work and was not a sponsored or financed in part or whole. **CONFLICTS OF INTEREST:** There are no conflicts of interest.

References:

- [1]. Manik Goel, Renata G Picciani, Richard K Lee, Sanjoy K Bhattacharya. Aqueous Humor Dynamics: A Review. *Open Ophthalmol J.* 2010; 4: 52–59
- [2]. Young H. Kwon, John H. Fingert, Markus H. Kuehn, Wallace L.M. Alward. Primary Open-Angle Glaucoma. *N Engl J Med.* 2009 March 12; 360(11): 1113–1124.
- [3]. Monica Gandhi, Suneeta Dubey. Evaluation of the Optic Nerve Head in Glaucoma. *Journal of Current Glaucoma Practice,* September-December 2013; 7(3):106-114 107.
- [4]. Teresa C. Chen. Spectral domain optical coherence tomography in glaucoma: qualitative and quantitative analysis of the optic nerve head and retinal nerve fiber layer (an AOS thesis). *Trans Am Ophthalmol Soc.* 2009; 107:254-281
- [5]. NHMRC Guidelines for the Screening, Prognosis, Diagnosis, Management and Prevention of Glaucoma 2010: 39-45, 65-88.

A Comparative Study of Changes in Rim Area, Cup Area and Intra Ocular Pressure In Primary Open

- [6]. N Raghu, SS Pandav, S Kaushik, P Ichhpujani and A Gupta. Effect of Trabeculectomy on RNFL thickness and optic disc parameters using optical coherence tomography. *Eye* (2012) 26, 1131–1137
- [7]. T Fujishiro, C Mayama, M Aihara, A Tomidokoro, M Araie. Central 10-degree visual field change following trabeculectomy in advanced open-angle glaucoma. *Eye* (2011) 25, 866–871
- [8]. Ali Aydin, MD, Gadi Wollstein, MD, Lori Lyn Price, MS, James G. Fujimoto, PhD, and Joel S. Schuman, MD. Optical Coherence Tomography Assessment of Retinal Nerve Fiber Layer Thickness Changes after Glaucoma Surgery. *Ophthalmology*. 2003 August ; 110(8): 1506–1511.
- [9]. Kumares Chandra Sarkar, Palash Das, Ranabir Pal, Chattaranjan Shaw. Optical coherence tomographic assessment of retinal nerve fiber layer thickness changes before and after glaucoma filtration surgery. *Oman Journal of Ophthalmology* 2014; 7: 3-8
- [10]. Aachal Kotecha, Alexander Spratt, Catey Bunce, David F. Garway-Heath, Peng T. Khaw, Ananth Viswanathan, MoreFlow Study Group. Optic Disc and Visual Field Changes after Trabeculectomy. *Investigative Ophthalmology & Visual Science*, October 2009, Vol. 50, No. 10. 4693-4699
- [11]. Peter T. Chang, Navneet Sekhon, Donald L. Budenz, William J. Feuer, Paul W. Park, Douglas R. Anderson. Effect of Lowering Intraocular Pressure on Optical Coherence Tomography Measurement of Peripapillary Retinal Nerve Fiber Layer Thickness, *Ophthalmology*, December 2007, Volume 114 (12), 2252-2258.
- [12]. Jagdish Bhatia. Outcome of Trabeculectomy Surgery in Primary Open Angle Glaucoma. *Oman Medical Journal*, April 2008; 23, (2): 86-89
- [13]. A. Paranhos Jr, M.C. Lima, S. Salim, J. Caprioli and M.B. Shields. Trabeculectomy and optic nerve head topography, *Brazilian Journal of Medical and Biological Research*, 2006, Vol. 39, 149-155.
- [14]. M Figus, S Lazzeri, M Nardi, MP Bartolomei, A Ferreras and P Fogagnolo Short-term changes in the optic nerve head and visual field after trabeculectomy, *Eye* (2011) 25, 1057–1063.
- [15]. Erol Yildirim, Ahmed H. Bilge, Sami Ilker. Improvement of Visual Field Following Trabeculectomy for Open Angle Glaucoma, *Eye*. 1990, 4,103-106.
- [16]. C. Lazaro, J. Garcia-Feijoo, A. Castillo, J. Perea1, J.M. Martinez-Casa, J. Garcia-Sanchez. Impact of intraocular pressure after filtration surgery on visual field progression in primary open-angle glaucoma, *European Journal of Ophthalmology* 2007; Vol. 17 (3); 357-362.
- [17]. Valerie Bertrand,Steffen Fieuw, Ingeborg Stalmans and Thierry Zeyen. Rates of visual field loss before and after trabeculectomy, *Acta Ophthalmol.* 2014: 92: 116–120.
- [18]. TS Prata, VC Lima, CG Vasconcelos de Moraes, LM Guedes, F P Magalhaes, SH Teixeira, R Ritch and A Paranhos Jr. Factors associated with topographic changes of the optic nerve head induced by acute intraocular pressure reduction in glaucoma patients, *Eye*, 2011, 25, 201–207.
- [19]. Inci Irak, Linda Zangwill, Valerie Garden, Sima Shakiba and Robert N. Weinreb. Change in Optic Disk Topography after Trabeculectomy, *American Journal of Ophthalmology* 1996 (Nov); 122:690-695.
- [20]. Shum JW, Leung DY. Surgical Decisions in Primary Open Angle Glaucoma with Low or Normal Tension. *Journal of Current Glaucoma Practice*, September-December 2013; 7(3):121-127.

Dr. Yash Pal Sharma,etal. “A Comparative Study of Changes in Rim Area, Cup Area and Intra Ocular Pressure In Primary Open Angle Glaucoma before and After Trabeculactomy.” *IOSR Journal of Dental and Medical Sciences (IOSR-JDMS)*, 19(4), 2020, pp. 42-47.