

Autologous corneal patch on perforated herpetic corneal ulcer

Dr I. Morsli, Pr B. Allali, Dr L.X. Kora, Dr T. Elongo, Dr S. BEL'hantier,
Pr L. El Maaloum, Pr A. ELkettani

(Pediatric ophthalmology department, CHU Ibn Rochd, Casablanca, Morocco)

Corresponding Author: I. Morsli

Abstract: A corneal perforation is a potentially visually devastating condition. Prompt closure or sealing of the perforation is crucial to prevent loss of vision as well as to maintain the integrity of the eyeball. The management of corneal perforations can be quite challenging. We report A 77-year-old male presented with Repeated red eye in the right eye for two years complicated By Preperforative corneal descemetocoele dating back two months before his admission of corneal perforation of herpetic origin. Therapeutic penetrating keratoplasty was not possible because of the unavailability of corneal tissue so the patient underwent autologous corneal patch grafting. There was gradual adherence and uptake of the corneal tissue into the surrounding cornea along with significant clearing over the next few months the examination at 2 months showed a BCVA of 2/10 with a quiet eye and a temporal corneal opacity. The current case shows that in the absence of corneal tissue and in selective emergency situations, an autologous corneal patch graft can be considered as a viable alternative in the treatment of full-thickness corneal perforations.

Key Word: Corneal patch; perforation ; herpes; Ulcer; .

Date of Submission: 13-05-2020

Date of Acceptance: 26-05-2020

I. Introduction

A corneal perforation is a potentially visually devastating condition. Prompt closure or sealing of the perforation is crucial to prevent loss of vision as well as to maintain the integrity of the eyeball. The management of corneal perforations can be quite challenging. Various modalities helpful in such scenarios are cyanoacrylate glue, amniotic membrane transplantation, conjunctival pedicle and therapeutic keratoplasty (16). However, lack of corneal tissue poses a big challenge in the management of this condition when other modalities fail. A corneal graft can be a globe-saving procedure in selected cases. Here, we report a case of corneal perforation managed successfully with an autologous lamellar corneal graft. (18)

II. Case Report

A 77-year-old male presented with Repeated red eye in the right eye for two years complicated By Preperforative corneal descemetocoele dating back two months before his admission of corneal perforation of herpetic origin.

On presentation, visual acuity was finger counting very closely With a remarkably soft eye. Slit-lamp examination revealed a large, vascularized corneal opacity involving the inferotemporal cornea with a paraxial perforation of 1.5x 1.5 mm and a shallow anterior chamber (Fig1).

There was no evidence of infection. Seidel test was positive. With opalescent lens.

Therapeutic penetrating keratoplasty was not possible because of the unavailability of corneal tissue so the patient underwent autologous corneal patch grafting. A partial thickness corneal patch measuring 2 mm x 2 mm was harvested with the help of crescent blade from the superotemporal quadrant of right eye. Anterior chamber was formed with viscoelastic injected from a side port. The recipient bed around the perforation was freshened up and the graft was sutured over the site of the perforation with multiple 10-0 nylon sutures. The anterior chamber was irrigated gently to remove the injected viscoelastic and an air bubble was injected.

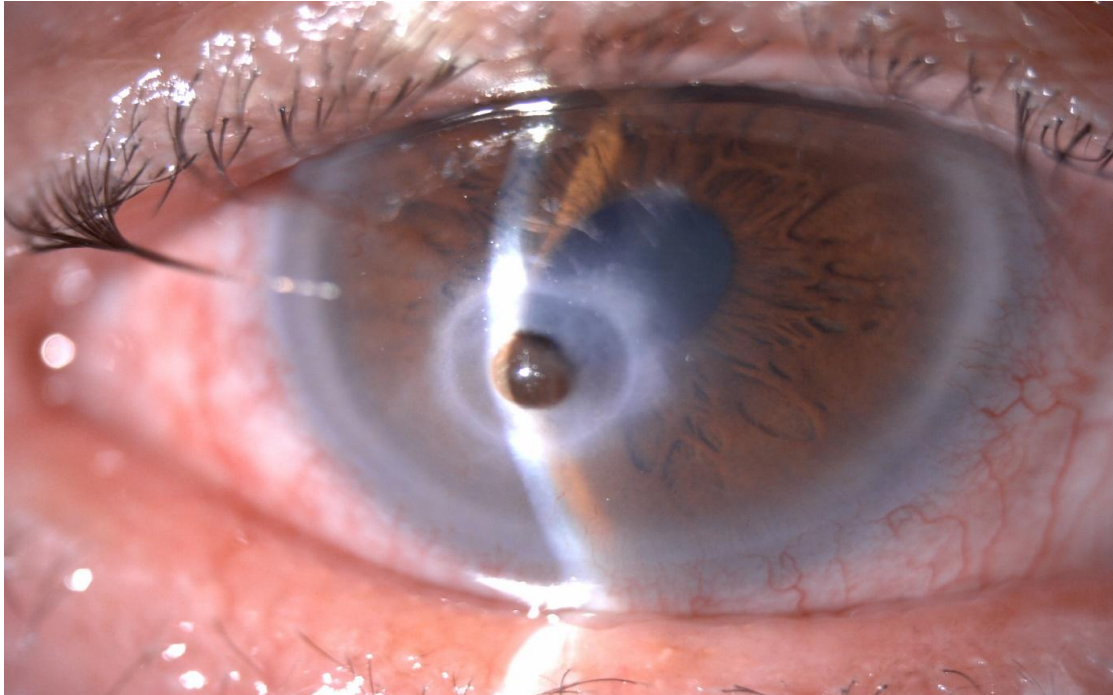


Figure 1: *Right Eye-Corneal perforation with iris prolapse and a shallow anterior chamber*

Postoperative treatment comprised oral and topical ciprofloxacin four times daily along in combination with Tablets antiviral and Cycloplegics atropine 1% eye drops to reduce pain and prevent synechiae Examination on the next day revealed (fig 2), Graft in place with no evidence of a leak and a well reformed anterior chamber

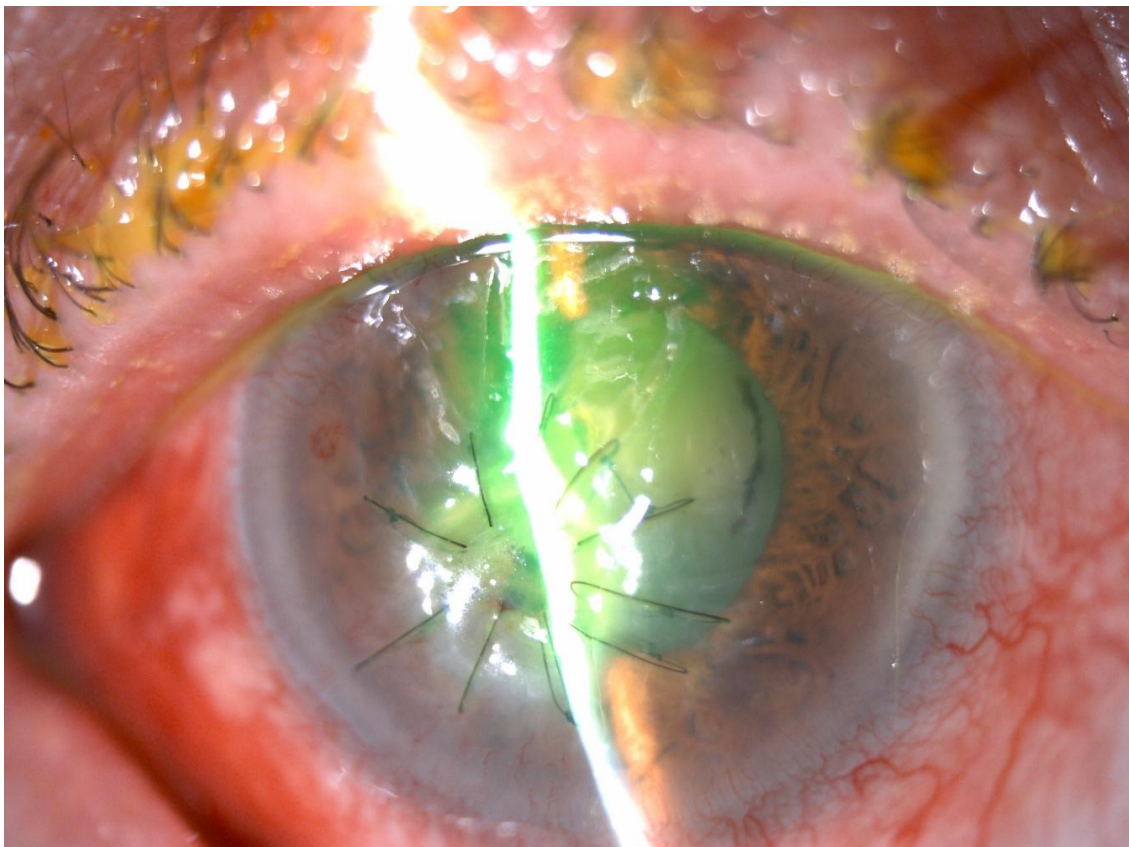


Figure 2: *Immediate post-operative corneal patch graft- Graft in place with no evidence of a leak and a well reformed anterior chamber*

There was gradual adherence and uptake of the corneal tissue into the surrounding cornea along with significant clearing over the next few months

The examination at 2 months showed a BCVA of 2/10 with a quiet eye and a temporal corneal opacity (Fig. 3). The anterior chamber was quiet. Examination of the lens showed nuclear cataract and pigment deposits on the anterior capsule. A band of iris tissue was seen extending posterolaterally from 2 to 4 o'clock within the lens substance (Fig.3). The patient was satisfied with the visual outcome and did not want any further surgical intervention at the time.

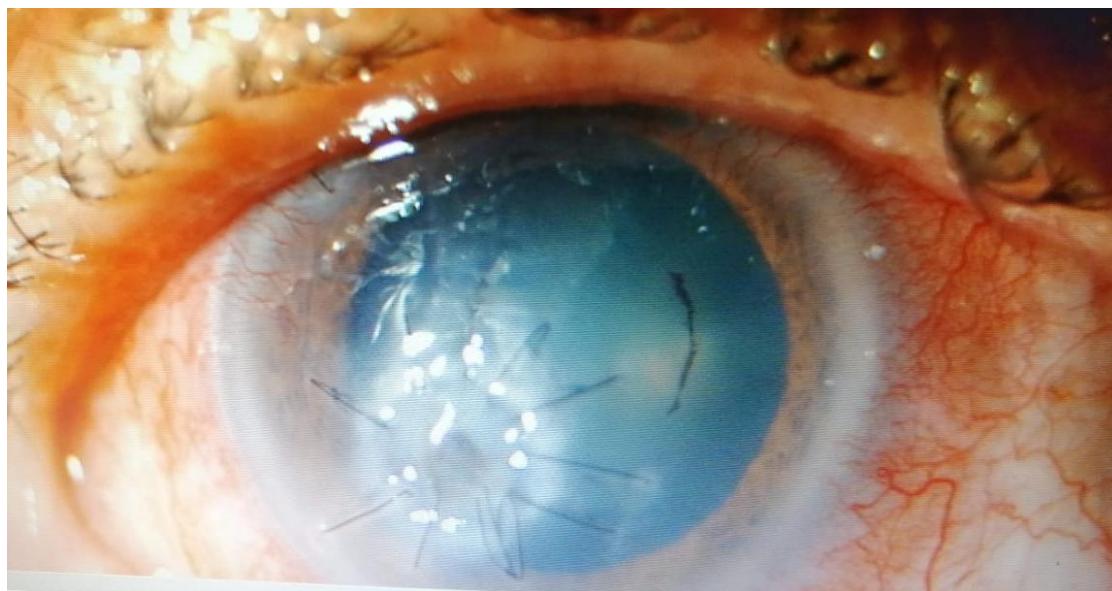


Figure 3: 4 months post -surgery - Graft in place, anterior chamber well reformed with nuclear cataract

III. Discussion

Corneal patch graft has been advocated as the surgical procedure to treat variety of anterior segment pathologies. It involves patching the affected area with full thickness or partial thickness corneal donor tissue. The aim is to restore globe integrity and prevent further inflammation that could lead to devastating complications such as endophthalmitis. Cornea perforation and melting can occur in infectious keratitis, autoimmune diseases such as rheumatoid arthritis, ocular trauma and ocular surface disorder. (10)

Corneal ulceration leading to perforation is the end result of many different infectious and non infectious destructive conditions of the cornea. Although its prevalence is relatively low in the general ophthalmic practice, corneal perforations are clinically important because of their high ocular morbidity. The prompt recognition and treatment of these difficult and challenging disorders may preserve useful vision. (14)

The initial event leading to corneal ulceration progressing to perforation begins with the breakdown of the corneal epithelial surface. Factors leading to the breakdown of the epithelial surface include infections, xerosis, trauma, and chemical injuries.

Herpes simplex keratitis frequently leads to corneal perforation. Recurrent disease leading to a chronic ulcerative keratitis predisposes the eye to a corneal perforation. Persistent epithelial defects may be the result of trophic (sterile) ulceration or active viral stromal necrosis. (1-2)

The primary goal in the management of corneal ulceration is to prevent progression of the condition to a descemetocele with perforation and to promote healing with reepithelialization.(18) Persistent corneal ulceration not responsive to medical treatment, including appropriate antibiotics and therapeutic hydrophilic soft contact lenses or tarsorrhaphy, requires more aggressive therapy.

Over the past 20 years the prognosis for corneal perforations has improved with advances in microsurgical technique, refinements in corneal grafting and the introduction of tissue adhesives. Improved medical management, including the recognition of systemic diseases and their role in the dry eye syndrome, has also contributed to a reduction in the complications associated with this disorder. Newer antimicrobial agents and potent immunosuppressives are routinely used to promote healing and prevent further tissue destruction. (9)

Various types of autologous and donor tissue have been used in the management of corneal perforations. The first reported case utilizing autologous tissue to close a corneal perforation was by Larsson in 1948(1)

Conjunctival recouvrement was the most used technique, because it is easy to perform and allows to obtain a good quality ocular surface. However, this technique is not very suitable in corneal perforations

complicating corneal infections since suppuration persists under the conjunctiva. In infectious or inflammatory processes, conjunctival recovery is sometimes the only treatment which reduces inflammation by providing anti-inflammatory cells and substances anti-collagenolytic(7). This technique requires the use of keratoplasty in a second step to restore corneal transparency.

Cyanoacrylate glue is indicated in the perforations with small size amniotic membrane grafting is a simple and straight forward surgical technique which has demonstrated its effectiveness efficiency in repairing corneal perforations in several studies and should form part of the therapeutic arsenal for the treatment of ocular surface disease.(21)

The therapeutic effect of the amniotic membrane (20) is due to its double synergistic action by suppressing the mediators of inflammation and promoting an EPITHELIALIZATION OF the corneal surface with good functional and anatomical recovery thus allowing to prepare a subsequent keratoplasty if necessary

Although use of a scleral graft to close a scleral defect is well documented, reports of its use to close corneal perforations are rare. Levartovsky et al. used a homologous scleral graft to close a corneal perforation in a child. Larsson used autologous sclera with conjunctival flap to close a corneal perforation secondary to lagophthalmos keratitis(12). Stilma used autologous scleral grafts in the management of corneal perforations associated with Mooren's ulcer. Prydal reported a case of successful closure of a traumatic corneal perforation with an autologous lamellar scleral graft(13)

The autologous corneal patch is used in patients WITH PERIPHERAL perforations less than 3 mm in diameter when other techniques prove impossible to perform.(5) However, when the origin of the perforation is immunological, the risk of failure is significant. It is therefore non indicated in case of immune keratitis to use the autologous corneal patch due to the strong may cause corneal necrosis of the graft.

In the case described here, the challenge was to repair a peripheral defect in the cornea with minimal disturbance to axial tissue

The advantages of corneal patch graft compared to others is that: it is translucent, less chances of graft melting and conjunctiva retraction. It can provide good tectonic support for the ocular wall as the tissue has good strength and rigidity(6).

IV. Conclusion

The current case shows that in the absence of corneal tissue and in selective emergency situations, an autologous corneal patch graft can be considered as a viable alternative in the treatment of full-thickness corneal perforations.

References

- [1]. Larsson S. Treatment of perforated corneal ulcer by autoplasic scleral transplantation. *Br J Ophthalmol* 1948; 32:54-7.1
- [2]. Spierer O., Waisbourd M., Golan Y., Newman H., Rachmiel R. Partial thickness corneal tissue as patch graft material for prevention of glaucoma drainage device exposure. *BMC pthalmology*. 2016;16(1) doi: 10.1186/s12886-016-0196-2.
- [3]. Yao Y., Jhanji V. Short term observation and management of scleral patch graft used in scleral defects. *Annals of Eye Science*. 2017;2: p. 30. doi:
- [4]. Raviv T., Greenfield D. S., Liebmann J. M., Sidoti P. A., Ishikawa H., Ritch R. Pericardial patch graft in glaucoma implant surgery. *Journal of Glaucoma*. 1998;7(1):27-32. doi: 10.1097/00061198-199802000-00006
- [5]. Schaab G., Clavell C., Goyal H. Corneal patch graft: a review of indication, technique and success rates. *ARVO annual meeting abstract. Investigative Ophthalmology & Visual Science*. 2012;53(14): p. 6044
- [6]. Soong H. K., Farjo A. A., Katz D., Meyer R. F., Sugar A. Lamellar corneal patch graft in the management of cornea melting. *Cornea*. 2000;19(2):126-134. doi: 10.1097/00003226-200003000-00002.
- [7]. Lal I., Shivanagari S. B., Ali M. H., Vazirani J. Efficacy of conjunctival resection with cyanoacrylate glue application in preventing recurrences of Mooren's ulcer. *British Journal of Ophthalmology*. 2016;100(7):971-975. doi: 10.1136
- [8]. de Farias C. C., de Sterlenich T., Souza L. B., Vieira L. A., Gomes J. A. P. Randomized trial comparing multilayer amniotic membrane transplantation with scleral and corneal graft for the treatment of scleral thinning after pterygium surgery associated with beta therapy. *Cornea*. 2014 ;33(11):1197-1204. doi: 10.1097/ico.0000000000000207
- [9]. Wu K. I., Chu H. S., Pai A. S. I., et al. Surgical management of limbal dermoid using anterior corneal button from descemet stripping automated endothelial keratoplasty donor tissue as patch graft. *Cornea*. 2017;36(1):64-67. doi: 10.1097/ico.0000000000001021.
- [10]. Portnoy SL, Inslar MS, Kaufman HE. Surgical management of corneal ulceration and perforation. *SurvOphthalmol*. 1989;34(1):47-58.
- [11]. Stilma JS. Conjunctival excision or lamellar scleral autograft in 38 Mooren's ulcers from Sierra Leone. *Br J Ophthalmol*. 1983;67(7): 475-8.
- [12]. Prydal JI. Use of an autologous lamellar scleral graft to repair a corneal perforation. *Br J Ophthalmol*. 2006;90(7):924.
- [13]. Prasher P. Use of an autologous lamellar scleral graft to repair corneal perforation. *Int Ophthalmol*. 2014;34(4):957-60.
- [14]. Winkelman JE. Optical behaviour of sclera transplanted into the cornea. *Am J Ophthalmol*. 1951;34(10):1379-97.
- [15]. Maurice DM, Singh T. The fate of scleral grafts in the cornea. *Cornea*. 1996;15(2):204-9.
- [16]. Hamill MB. Management of scleral perforation. In: Krachmer JH, Mannis MJ, Holland EJ, eds. *Cornea*. St. Louis, MO: Mosby; 1997:1969-1971.
- [17]. Johnson WA, Henderson JW, Parkhill EM, et al. Transplantation of homografts of sclera. *Am J Optom Arch Am AcadOptom*. 1962:1019-1030.
- [18]. Sainz de la Maza M, Tauber J, Foster CS. Scleral grafting for necrotizing scleritis. *Ophthalmology*. 1989; 96:306-310.
- [19]. Vanathi M, Sharma N, Titiyal JS. Tectonic grafts for corneal thinning and perforations. *Cornea*. 2002; 21:792-797.

- [20]. Sandinha T, Zaher SS, Roberts F. Superior forniceal conjunctival advancement pedicles (SFCAP) in the management of acute and impending corneal perforations. *Eye*. 2006; 20:84–89.
- [21]. Rodriguez-Ares MT, Tourino R, Lopez-Valladares MJ. Multilayer amniotic membrane transplantation in the treatment of corneal perforation. *Cornea*. 2004; 23:577–583.
- [22]. Sharma A, Kaur R, Kumar S. Fibrin glue versus N-butyl-2-cyanoacrylate in corneal perforations. *Ophthalmology*. 2003; 110:291–298.
- [23]. Kobayashi A, Shirao Y, Segawa Y. Temporary use of a customized, glued on hard contact lens before penetrating keratoplasty for descemetocele or corneal perforation. *Ophthalmic Surg Lasers Imaging*. 2003; 34:226–229.
- [24]. Duchesne B, Tahiri H, Galand A. Use of human fibrin glue and amniotic membrane transplant in corneal perforation. *Cornea*. 2001; 20: 230–232.

Dr I. Morsli, et. al. “Autologous corneal patch on perforated herpetic corneal ulcer.” *IOSR Journal of Dental and Medical Sciences (IOSR-JDMS)*, 19(5), 2020, pp. 47-51.