

## Regenerative Endodontics

Dr. Aji Markose

Dept of Conservative Dentistry, Vivekanadha Dental College  
Tiruchengode, Namakkal Dt, Tamilnadu, 637205

---

**Abstract:** Pulp Revascularization is the procedure to re-establish vitality in a non vital tooth to allow repair and regeneration of tissue. Revascularization will allow further development of root and dentin structure with a better long term prognosis. It is favored when apical foramen is not completely formed and the apical diameter exceeds 1mm.

**Key words:** Vitality, Root Apex, Stem cells, Triple Antibiotic paste

---

Date of Submission: 14-05-2020

Date of Acceptance: 29-05-2020

---

### I. Introduction

Regenerative endodontics is concerned with the development of biologically based treatment modalities that are used to replace diseased portion of the dental pulp or to allow complete formation of a dental pulp like tissue that will act as the original dental pulp. The purpose of pulp treatment ( maintaining the vitality of teeth damaged due to caries or trauma) is to maintain the tooth structure in order to preserve optimal function. Maintaining the pulp vitality is essential for continuous root development and apical closure, especially in case of immature permanent teeth.

### II. 11. Concept

Normal, sterile granulation tissue should be developed within the root canal for revascularization. This will stimulate the cementoblasts or the undifferentiated mesenchymal cells at the periapex and lead to formation of a calcific material at the apex and lateral dentinal walls. Conventional calcium hydroxide or mineral trioxide aggregate (MTA) - induced apexification resulted in the formation of a calcific barrier at the apex. On the contrary, regenerative procedures showed normal maturation of root in the radiograph.

### III. Historical Background of Regenerative Endodontics

Nygaard – Ostby (1961): Established a blood clot to use as a scaffold to revascularize tissue within root canals of teeth.

Rule (1966): Use of Double Antibiotic Paste

Hoshino (1993): Use of Triple Antibiotic Paste

Iwaya, (2001): Evoked Intracanal bleeding step

Branchs and Trope (2004) : Case Reports on Immature mandibular premolars

ADA (2011) : Adapted a new Procedure code to induce apical bleeding into the canal in immature permanent teeth

### IV. Definitions

- \* Regenerative endodontics are biologically based procedures designed to replace damaged structures, including dentin and root structures, as well as cells of the pulp- dentin complex.
- \* Revascularization, as defined by Andreasen is the restoration of the vascularity to a tissue or organ.
- \* Repair is the restoration of tissue continuity without the loss of original architecture and function.
- \* Revitalization is described as an in-growth of vital tissue that does not resemble the original lost tissue.

### V. Objectives of Regenerative Endodontics

The objective of regenerative treatment is to regenerate a fully functional pulp- dentin complex to aid in continued root development for immature teeth.

The goals of regenerative endodontic procedures are categorized as primary, secondary and tertiary: however, success of the treatment is confirmed by histological means.

**Primary Goal:** Elimination of Symptoms along with the evidence of bony healing.

**Secondary goal:** Increased root wall thickness and/or increased root length.

**Tertiary goal:** Positive response to vitality testing.

## VI. VI. Components of Regenerative Endodontics

The three key elements of tissue regeneration, are namely stem cells, growth factors and scaffold.

### Stem Cells

Stem cells are unspecialized cells in the human body that are capable of becoming specialized cells, each with new specialized function. A Stem cell is defined as “a cell that has the ability to continuously divide and produce progeny cells that differentiate (develop) into various types of cells or tissues”. The various types of stem cells are listed below.

### Types of Stem Cells

1. Stem cells of the apical papilla (SCAP)
2. Dental pulp stem cells (DPSCs)
3. Inflamed periapical progenitor cells (iPAPCs)
4. Periodontal ligament stem cells (PDLSCs)
5. Bone marrow stem cells (BMSCs)
6. Stem cells from human exfoliated deciduous teeth (SHED)
7. Tooth germ progenitor cells (TGPCs)
8. Dental follicle stem cells (DFSCs)
9. Salivary gland stem cells (SGSCs)

According to Hargreaves, the first five stem cells are the most commonly employed stem cells in regenerative endodontics. These cells have the ability of differentiating into odontoblast- like cells facilitating a progressive repopulation of the radicular space, promoting organized tissue repair, angiogenesis and reinnervation.

### Growth factors

Growth factors are proteins that bind to receptors on the cell and induce cellular proliferation and/or differentiation. There are many types of Growth factors. Mainly they are

- \* Bone Morphogenic protein (BMP)
- \* Epidermal Growth Factor (EGF)
- \* Fibroblast Growth Factor (FGF)
- \* Platelet derived growth factor (PDGF)
- \* Transforming growth factor (TGF)
- \* Nerve growth factor (NGF)

### Scaffold

Scaffold is a three-dimensional structure that contains growth factors. It has following functions:

- \* Supports cell organization and vascularization
- \* Aids stem cell proliferation and differentiation
- \* Leads to improved and faster tissue development
- \* Contains nutrients to promote cell survival and growth
- \* May contain antibiotics to prevent bacterial ingrowth in the canal systems
- \* Mechanical and biological functions

### Classification

Scaffolds can be classified as natural and synthetic.

- i. Natural: Collagen, platelet-rich plasma, fibrin, and glycosaminoglycans
- ii. Synthetic. Polylactic acid, polyglycolic acid (PGA), and poly(Lactic-co-glycolic)acid (PLGA)

## VII. Mechanism of Revascularization

According to Shah N, the possible mechanisms by which the process of revascularization takes place are as follows

- \* A few vital pulp cells remaining at the apical end of the root canal might proliferate into the newly formed matrix and differentiate into odontoblasts.
- \* Continued root development could be due to multipotent dental pulp stem cells, which are present abundantly in immature permanent teeth
- \* Stem cells in the periodontal ligament can proliferate and grow into the apical end and within the root canal.
- \* The fourth possible mechanism of root development could be attributed to SCAP or to the bone marrow. Instrumentation beyond the confines of the root canal to induce bleeding can also transplant mesenchymal stem cells from the bone into the canal lumen. These cells have extensive proliferating capacity.

\* The blood clot is a rich source of growth factors such as platelet-derived growth factor, vascular endothelial growth factor, platelet-derived epithelial growth factor, and tissue growth factor. These could play an important role in regeneration.

### **VIII. Indications**

- \* Teeth with necrotic pulp and immature apex
- \* Pulp space not needed for post/core, final restoration
- \* Patient compliance
- \* No allergy to the medicaments to be used.

### **IX. Advantages**

- \* Achieving continued root development (root lengthening) and strengthening due to reinforcement of lateral dentinal walls with deposition of new dentin/hard tissue are the biggest advantages.
- \* Obturation of the canal is not required unlike in calcium hydroxide-induced apexification
- \* After control of infection, the procedure can be completed in a single visit.
- \* Cost effective

### **Disadvantages**

- \* Discoloration due to minocycline in triple antibiotic paste
- \* Prolonged treatment period and more appointments (compared with one-visit MTA apical barrier technique)

## **X. Protocol for Regenerative Endodontics**

### **First Appointment**

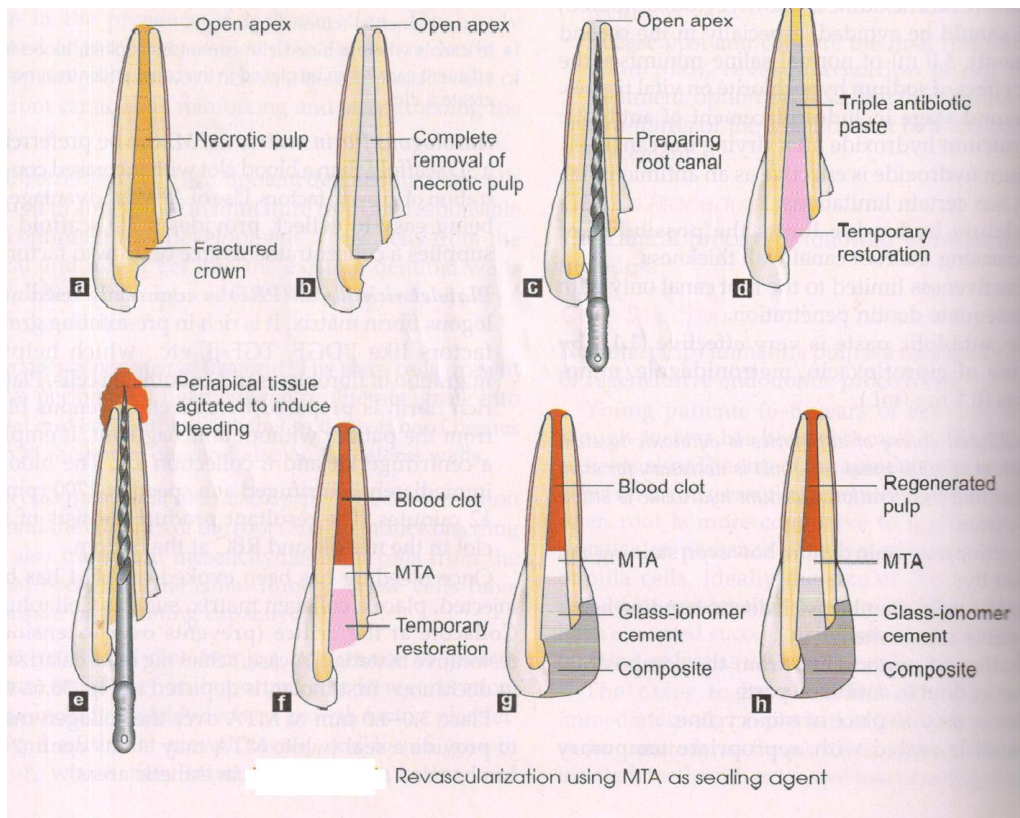
Local Anesthesia, Isolation under Rubber dam  
 Access cavity preparation  
 Irrigation with 1.5% NaOCl and saline  
 Dry the canal with paper points  
 Placement of Intracanal medicament  
 Triple antibiotic paste  
 Temporary seal with 3-4 mm of Cavit/IRM/Glass ionomer  
 Recall Patient after 1-4 weeks

### **Second Appointment**

No Signs/Symptoms  
 Local anesthesia (3% mepivacaine without a vasoconstrictor) & rubber dam isolation  
 Irrigation with 1.5% NaOCl & 17% EDTA  
 Intentionally evoked Intra canal bleeding (k-File is passively extended 2mm past the apical foramen)  
 Canal filled with blood to the level of C.E.J  
 Stop the bleeding at a level that allows for 3-4mm of the restorative material  
 Placement of a resorbable matrix over the blood clot  
 White MTA/CaOH as capping material covered with 3-4 mm layer of GIC

### **Antibiotic Pastes Employed in Regenerative Endodontics**

<b>Agent</b>	<b>Description</b>	
Triple antibiotic paste (1:1:1) in a macrogol/propylene glycol vehicle	Ciprofloxacin, metrodinazole,	minocycline
Modified triple antibiotic paste	Ciprofloxacin, metronidazole, Cefaclor	
Double antibiotic paste	Ciprofloxacin,metronidazole	
Calcium hydroxide	Calcium hydroxide paste	



### XI. Follow –up

- \* Clinical and radiological examination
- \* There should be no pain, soft-tissue swelling, or sinus tract formation
- \* Resolution of periradicular radiolucency (6-12 months after treatment)
- \* Increase in width of root canal walls (12-24 months after treatment)
- \* Increased root length
- \* Responsive Pulp vitality test

### XII. Conclusion

Regenerative endodontics holds promise of restoring pulp- dentin complex in teeth with immature roots and necrotic pulps. This procedure has potentials advantages versus traditional treatment procedures of increasing root wall thickness and root length while maintaining immune competency. From the conceptual standpoint, there is little doubt that the best material to replace tooth structure is tooth structure. Still significant hurdles need to be overcome with continued growth in knowledge and armamentarium.

### Bibliography

- [1]. Grossmans Endodontic practice, 13<sup>th</sup> Edition, Editors B.Suresh Chandra, V.Gopikrishna
- [2]. Principles of Endodontics, Second Edition, Vimal K Sikri
- [3]. Text Book of Endodontics, 3<sup>rd</sup> Edition, Nisha Garg, Amit Garg
- [4]. Diogenes, A.,etal.: Endodontic Topics **28**: 2-23, 2013
- [5]. Hargreaves,K.M., et al.: J. Endod, **39**: S30-S43, 2013
- [6]. Horst, O., et al.: Dent. Clin. N. Am., **56**: 495-520, 2012
- [7]. Kim, H.J., et al.: J Endod., **36**: 1086-91, 2010
- [8]. Naik ,B.: J.Conserv Dent., **16**(4): 284-293,2013
- [9]. Nosrat, A., et al.: J.Endod., **38**: 1428-1434, 2012
- [10]. Torabinejad, M., et al.: J. Endod., **38**: 6, 2012

Dr. Aji Markose. "Regenerative Endodontics." *IOSR Journal of Dental and Medical Sciences (IOSR-JDMS)*, 19(5), 2020, pp. 01-04.