

## Efficacy of Allogenic Block Graft in Lateral Augmentation of Human Anterior Maxilla-A Systematic Review

Dr. Shruti.S.Ligade, (MDS)<sup>1</sup>, Dr. Anita.Kulloli, (MDS)<sup>1</sup>,  
Dr. Sharath. Shetty, (MDS, Ph.D)<sup>1</sup>, Dr. Anisha. Yadav, (MDS)<sup>1</sup>,  
Dr. Santosh Martande, (MDS)<sup>1</sup>, Dr. Sukhada Deo, BDS (MDS)<sup>1</sup>

<sup>1</sup>Department of Periodontology,

Dr.D.Y. Patil Dental College & Hospital, Pimpri, Pune, INDIA.

Correspondence address: Dr. Shruti.S.Ligade

Dept. of Periodontology, Dr.D.Y.Patil Dental college & Hospital, Pimpri, Pune, INDIA

### Abstract

**Aim and background:** Augmentation of the lost ridge becomes a prime concern, before planning an implant procedure and its prognosis. This systematic review examines the published findings on the clinical effectiveness and predictability of allogenic bone block grafts for the correction of alveolar ridge deformities in anterior maxilla to support dental implants

**Materials & Methods:** The PRISMA guideline for systematic reviews was used and bibliographic search was conducted. Clinical trials with a minimum sample size of 10 patients and a minimum follow-up time of 6 months and interventions for maxillary anterior lateral ridge augmentation were considered. After the literature search of 392 articles, 11 articles which met the inclusion criteria, were taken into consideration, which assessed the outcome of the augmentation either clinically or by histomorphometric method.

**Result:** A success rate of 98.67% in the grafted block grafts with the native bone and osseointegration of 99.0% implants was seen when placed in the grafted allogenic blocks. Also, the histologic evidence on re-entry showed well vascularized grafts.

**Conclusion:** Allogenic block graft is biocompatible and good alternative for autogenous grafts. Their osteoconductive and osteoinductive properties permit new bone formation following lateral augmentation of extremely atrophic anterior maxillae and successive two-stage implant placement.

**Key words-** Allograft; DFDBA; lateral ridge augmentation; atrophic maxilla; Cortico-cancellous bone grafts; Fresh frozen onlay block grafts

Date of Submission: 14-05-2020

Date of Acceptance: 29-05-2020

### I. Introduction

A dental implant is an artificial tooth root that acts as replacement for lost tooth. The success and predictability of osseointegrated implants have forever changed the philosophy and practice of dentistry and perhaps largely, the field of periodontology. Statistics provided by the American Association of Oral and Maxillofacial Surgeons in 2014, show that 69% of adults ages 35 to 44, have lost at least one permanent tooth to an accident, periodontitis or dental caries<sup>1</sup>. Additionally, by age 74, 26% of adults have lost all of their permanent teeth. Therefore, the use of dental implants reveals that about 100,000-300,000 dental implants are placed per year, which approximates the numbers of artificial hip and knee joints placed per year. The increasing popularity of dental implant surgery has created a heavy demand for dentoalveolar reconstruction. In spite of the many technological advances in implant dentistry, bone availability is still the pre-requisite for safe and predictable implant placement. An inadequate alveolar ridge results, not only from trauma, pathology, infections, or the consequence of severe periodontitis, but also due to loss of mechanical impact following tooth extraction<sup>2</sup>. This physiologic bone loss after tooth extraction has been demonstrated in experimental studies, which reports vertical and horizontal bone resorption.<sup>2,3</sup> Approximately, 50% of the bone volume is lost after tooth extraction during the first year and these resorptive changes may alter the placement of dental implants<sup>4</sup>. Lateral bone/ridge augmentation procedures are necessary, when the width of the recipient alveolar ridge lacks the adequate dimensions.

Schropp<sup>2</sup> concluded that clinical loss in width of alveolar ridge, is 43% more than the loss in height. The placement of implant is critical in maxillary arch, than the mandible, because of variability in the bone density. There is a greater risk of implant failure and prosthetic complications in maxilla.

These procedures involve the use of bone grafting with different type of grafts (autografts, allografts, xenografts, bone substitutes), Guided Bone Regeneration (GBR) alone or in combination with grafting procedures, and ridge expansion techniques utilizing “split” ridge osteotomy<sup>5</sup>.

Autogenous bone, though is considered the “gold standard” for large defect augmentation, harvesting it brings along the disadvantages of a second surgery site and potential complications. Mandibular fracture has been reported during ramus and chin block harvest procedures.<sup>6</sup>

Allograft block grafts have showed the advantages of unlimited supply, limited antigenicity, and a record of safety regarding potential disease transmission.<sup>7</sup>

The compromised alveolar ridge in the anterior maxilla does not provide a natural cavity to contain the particulated graft material, as in sinuses in the lateral and posterior maxilla. Therefore, the graft must possess sufficient strength and rigidity to allow fixation in the recipient site and three-dimensional stability to withstand muscular forces.

Use of block allograft in conjunction with placement of a resorbable membrane may pose an acceptable alternative to the autogenous block graft for the treatment of compromised alveolar ridges<sup>8</sup>.

A systematic review is a type of literature review that collects and critically analyzes multiple research studies or papers. Scanning through a review of existing studies, is often quicker and cheaper than embarking on a new study. Researchers select the method prior to formulation of one or more research question, and then aim to analyze studies that relate to, and answer those questions. Hence, a systematic review determining the same is undertaken in this study.

### **Focused question:**

What is the clinical efficacy and predictability of allogeneic block graft for the correction of deficient maxillary anterior lateral ridge defect to support dental implant placement in humans?

### **Objectives:**

1. To clinically measure the gain in lateral dimension of maxillary anterior ridge, post augmentation with allogenic block graft.
2. To check the efficacy of the intervention of allogenic block graft through histomorphological assessment.
3. To quantify implant survival rate post ridge augmentation with allogenic block graft.

## **II. Material And Methods**

### **Information sources:**

Electronic databases—MEDLINE (PubMed 1997), Google and EBSCOhost—were searched for human studies published until December 2016 for search words as Atrophic maxilla, Cortico-cancellous bone grafts, and Lateral ridge reconstruction. A specific search strategy was developed for MEDLINE (Appendix) and revised for the other databases. All reference lists of the selected studies were checked for cross-references. A hand search of the most relevant journals was also performed in the college library. Search for gray literature was not attempted. The search terms included ‘Deficient Maxilla’, ‘Atrophic maxilla’, ‘Atrophic maxillary lateral ridge’ and intervention with ‘Allograft’, ‘Allogenic block grafting’, ‘Fresh frozen onlay block grafts’, ‘Lateral ridge reconstruction’ and ‘Ridge reconstruction’.

### **Study selection and collection:**

#### **Inclusion criteria:**

1. Articles having detailed summary in English.
2. Electronic databases—MEDLINE (Pubmed), Google and EBSCOhost—until December 2016.
3. Randomized Clinical trials with a minimum sample size of 10 patients and a minimum follow-up time of 6 months.
4. Patients >18 years and in good general health, requiring the placement of one or more implant in sites presenting ridge deficiencies.
5. Interventions aimed for lateral ridge augmentation.

#### **Exclusion criteria:**

1. Studies assessing the effectiveness of interventions aimed at vertical bone augmentation (distraction osteogenesis, orthognathic surgery etc.)
2. Studies aimed at regenerating extractions sockets, sinus augmentation with or without implant placement.
3. In-vitro studies, animal studies, retrospective studies
4. Reviews, case reports, case series, abstracts, letters to editors.

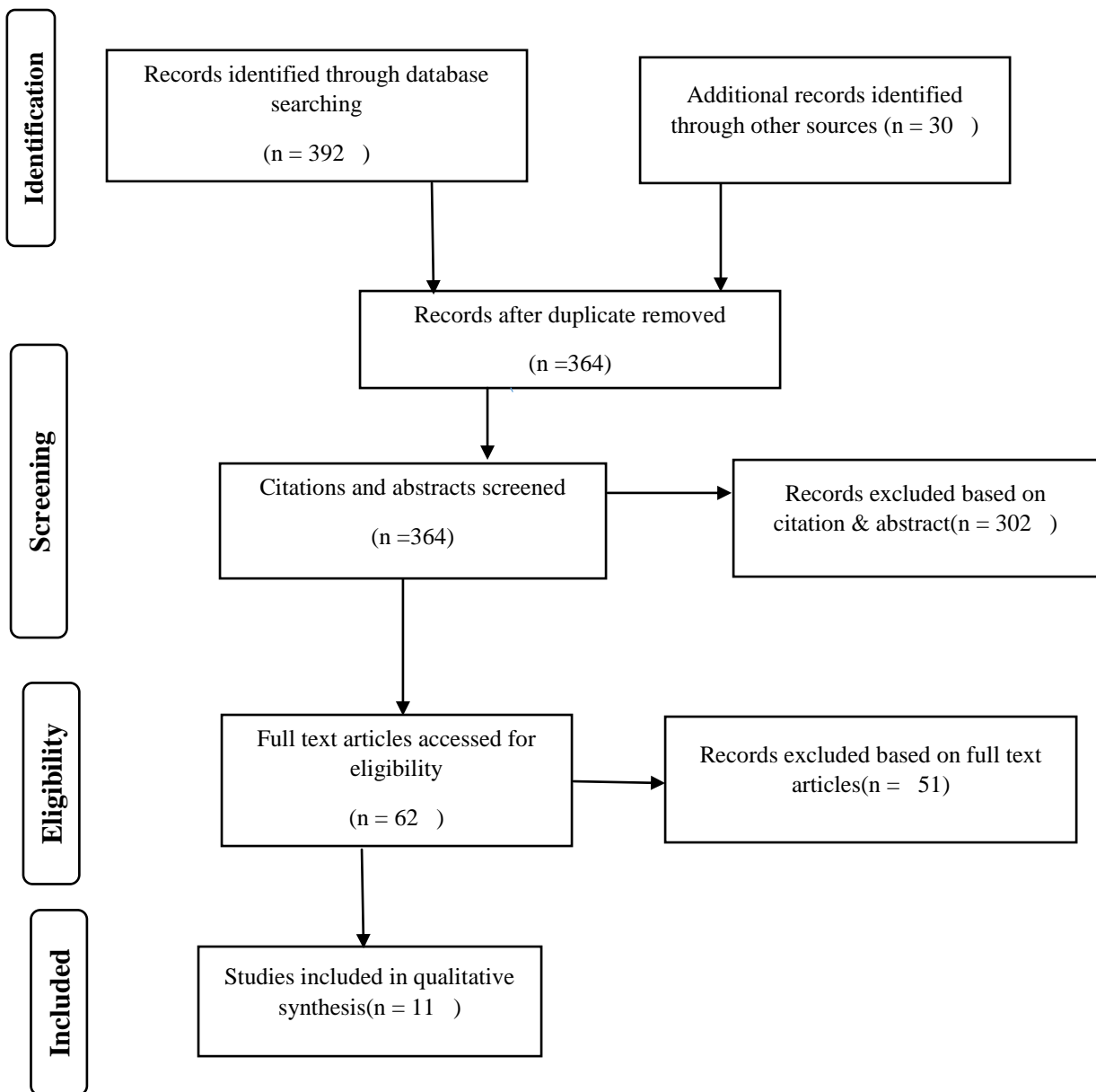
**Search and selection result:**

The criteria for including and excluding the articles, led to charting of the final studies to be included in this Systematic Review. The Selection process was in accordance with the Preferred Reporting Items for Systematic Reviews and Meta-Analyses guidelines given in 2009.

A three stage screening process was performed independently by 2 reviewers (Ligade & Kulloli). 392 titles were identified by the database electronic search, as well as 30 were found through other sources on the basis of the discussed key words. Among those, 58 studies which were found to be duplicate were eliminated from main search, to avoid the likely stronger impact of the same data on overall result. 364 articles were evaluated for titles, citations and abstracts, and 302 studies were discarded resulting in 62 studies. These 62 studies were subjected to full-text analysis of the manuscripts. Any disagreement to the study was resolved by the third reviewer. To prevent selection bias, the reviewers were blinded to the name of the authors, institutions and journal titles.

After this analysis, 11 final publications timed from 2009-2015, were included in this review, since 51 publications showed incompleteness in the data. (Fig 1. PRISMA flowchart)

**FIG. 1** **PRISMA FLOWCHART (2009)**



### **Quality assessment-**

To rate the quality of each of the studies, we reviewed all related articles describing the studies, but did not query study authors. Two investigators independently rated the quality of each study based on criteria created by the Third USPSTF (United States Preventive Services Task Force) and the found discrepancies were adjudicated by a third reviewer.

These criteria are as follows-

According to USPSTF Quality Rating Criteria for Randomized Controlled Trials and Cohort Studies

1. Good: Meets all criteria: Comparable groups are assembled initially and maintained throughout the study (follow-up at least 80 percent); reliable and valid measurement instruments are used and applied equally to the groups; interventions are spelled out clearly; important outcomes are considered; appropriate attention to confounders in analysis.

2. Fair: If any or all of the following problems occur, without the important limitations noted in the "poor" category below: Generally comparable groups are assembled initially but some question remains whether some (although not major) differences occurred in follow-up; measurement instruments are acceptable although not the best) and generally applied equally; some but not all important outcomes are considered; some but not all potential confounders are accounted for.

3. Poor: Studies will be graded "poor" if -Groups assembled initially are not close to being comparable or maintained throughout the study; unreliable or invalid measurement instruments are used or not applied at all equally among groups (including not masking outcome assessment); key confounders are given little or no attention.

Based on these domains, overall risk of bias was categorized as follows:

1) Low risk of bias if all criteria were met (adequate methods of randomization and allocation concealment, a "yes" answer to questions about completeness of follow-up and masking, and a "no" answer to selective reporting and other sources of bias)

2) Unclear risk of bias if one or more criteria were partially met

3) High risk of bias if one or more criteria were not met.

Different parameters were found to be fulfilled by this study as-

- Maintenance of comparable groups (includes attrition)
- Nonbiased selection of cases or controls with strong inclusion criteria applied equally to all patients and exclusion criteria as undergoing pregnancy, chemotherapy etc.
- Clear definition of interventions
- Clinical and histological measurements taken were equal, reliable, and valid
- Important outcomes considered, measurement of exposure accurate and applied uniformly without bias to each individual masking of outcome assessment bias
- Have more than 90% of follow-up
- Have acceptable follow-up period.

According to these criteria, all the studies included in this systematic review can be categorized as "good" and having a Low risk of bias.

### **III. Result:**

The results of this review were compiled based on different parameters for easy readability. All eligible articles were based on clinical trials conducted in time span of 2009-2012.

The included studies were categorized under different sub-headings as under: (Table.1 Data extraction)

#### **Primary Outcome:**

The outcome of all studies clinically showed a gain in the lateral dimension of the alveolar ridge approx. in a range 1.5 to 9.8mm with average gain by 4.6-5mm and success rate of 98.67% in the grafted block grafts with the native bone.

This gain in width was sufficient for management with implant placement which gave an osseointegration rate of 99.0% implants in the grafted allogenic blocks

#### **Secondary outcome:**

The study also concluded the secondary objectives with histological intervention which showed newly formed bone containing viable osteocytes, demonstrated intimate contact with the residual graft

**TABLE.1- DATA EXTRACTION OF THE INCLUDED ARTICLES**

Study ID	Product	Intervention	Evaluation technique	Outcome	Remarks
Barone A et al. (2009) Clinical Trial	Cortico-cancellous (FDDBA)	19 ridges were horizontally augmented with 19 onlay allografts and 27 implants were placed 5 months after grafting.	Clinical	Only 1 implant failed while other sites showed stabilized and well integrated grafts with recipient sites.	Allograft was proven clinically successful in lateral augmentation of deficient maxilla.
Contar C et al. (2009) Case control	FDDBA	Maxillary reconstruction performed with 34 human block grafts obtained from same hospital. 9 months later re-entry was done to obtain bone core from the graft and total 51 implants were placed.	clinical/histo	No block grafts were displaced during re-entry after 9 months. Grafts were well vascularized, firm in consistency and well-incorporated. Histology showed mature and compact tissue with marrow spaces. Viable bone seemed incorporated with grafted bone. No implants were lost in follow up after 35 months.	Allograft was proven clinically and histologically successful in lateral augmentation of deficient maxilla.
WallaceS et al. (2010) Clinical trial	Allograft	Maxillary deficient anterior region was grafted with cancellous block graft for implant placement.	Clinical	Mean pre-graft site measured 3.9mm and mean increase in width was 4.6mm. A gain of 41 to 190% (range 1.5 to 9.8 mm) was found in the augmented site in horizontal dimension.	Allograft was proven 100% clinically successful in lateral augmentation of deficient maxilla.
Peleg et al. (2010) Clinical trial	Cortico-cancellous (FDDBA)	14 atrophic ridges were augmented with 31 block grafts and after 5 months implant placement was done.	Clinical	Of 31 sites, only one site showed marginal bone resorption around the block graft while rest had successfully integrated. Mean increase in width is 3.7mm. Implant outcome was successful.	Allograft was proven clinically successful in lateral augmentation of deficient maxilla.
Contar C et al. (2011) Clinical trial	Allograft	Atrophic Max. anterior was augmented with 39 allografts and 58 implants were placed. Post 9 months, histology was examined by re-entry in the grafted site as well as the native maxillary site	Histo	Histology revealed a typical lamellar arrangement around Haversian canals interspersed with osteocytes. Student's t-test revealed no significant difference in collagen area or density percentage in test and control groups which is characteristic of mature collagen.	Similar histologic results seen in allograft and the native bone.
Acocella A et al. (2011) Clinical study	FDDBA	Deficient maxillary anterior region was augmented with FDDBA & after 9 months bone core was harvested and 34 implants were placed. Follow up 30 months.	clinical/histo	Mean pre-graft width of 3±0.5mm was gained to 8±1mm. Histology showed newly formed vital bone containing viable osteocytes, residual cancellous block allograft bone.	Allograft was proven clinically and histologically successful in lateral augmentation of deficient maxilla.
Giovana O et al. (2011) Clinical trial	Allograft	Deficient region was reconstructed with FDDBA & after 5 months bone core was harvested and 14 implants were placed.	clinical/histo	9 of 10 grafts showed successful osseointegration (width gain was 2.3mm to 6.8mm), spaces. 1 graft showed early exposure in 1 month. Viable bone seemed incorporated with grafted bone and formation of new bone by osteoblasts.	Allograft was proven clinically and histologically successful in lateral augmentation of deficient maxilla. Allograft was proven clinically successful in lateral augmentation of deficient maxilla.
Nissan J et al. (2011b) Clinical trial	Cortico-cancellous (FDDBA)	31 patients with atrophic maxilla were augmented with 46 block grafts and after 6 months 63 implants were placed.	Clinical	Avg gain in width was 5mm; 2 block grafts failed to integrate; 1 implant from 19 failed to integrate with 95.6% success rate of implant survival and avg buccal bone resorption around implant was 0.5mm	Allograft was proven clinically successful in lateral augmentation of deficient maxilla. Mean bone gain was 5 ± 0.5 mm horizontally.
Nissan J et al. (2011c) Clinical trial	Cancellous bone graft (FDDBA)	19 Congenitally missing anterior region was augmented with cancellous allograft	Clinical	19 ridges with congenitally missing teeth of 12 patients were grafted. 21 implants were placed in the augmented sites. Avg gain in width was 5mm and Bone block and implant survival rates were 100% and 95.2%. (One of 21 implants failed)	Allograft was proven clinically successful in lateral augmentation of deficient maxilla.
Nissan J et al. (2011a) Clinical trial	Cancellous bone graft (FDDBA)	post-traumatic anterior maxilla was augmented with cortico-cancellous allograft	Clinical	28 grafts in post-traumatic 20 patients were placed and later 31 implants were inserted. Avg gain in width was 5mm and 100% implants placed were successful in 2-stage procedure.	Allograft was proven clinically successful in lateral augmentation of deficient maxilla.
Nissan J et al. (2012) Clinical trial	Cancellous bone graft (FDDBA)	Severe atrophy in the anterior maxilla atleast 3 mm horizontally and up to 3 mm vertically, underwent	Histo	Of 83, 82 implants were osseointegrated (98.8% survival). Histologic Findings showed newly formed vital bone containing viable osteocytes, residual cancellous block allograft bone and marrow tissue. New bone formation mean was 33±18%.	Allograft was proven histologically successful in lateral augmentation of deficient maxilla.

augmentation with cancellous bone block allografts. After 6 months, 83 implants were placed & sample core from the graft area was collected for histologic examination.

---

**Study design:**

One study was Randomized Control Trial<sup>9</sup> while other were Clinical trials.

**Product intervention:**

All the studies have used the intervention as allogenic onlay graft. Of all the studies, 8 have used Freeze Dried Bone Allograft (FDBA) as intervention product while 3 articles<sup>10, 11, 12</sup> studies did not mention the type of allograft used was whether FDBA or DFDBA.

**Intervention Technique:**

The procedure followed in all the studies is similar as mentioned in the study by Nissan<sup>13</sup> with only difference in tenure for product intervention studied by Nissan et al. in 2011<sup>14</sup>.

**Evaluation time:**

The time period between the graft augmentation procedure and implant placement varied from 5 months<sup>15, 16, 17</sup> while others ranged from 6-9 months.

**Evaluation technique and outcome:**

All the studies were either assessed using clinical<sup>10, 13, 14, 15, 16, 18</sup> or histological<sup>11, 17</sup> or both techniques<sup>9, 12, 19</sup>.

The studies showed success rate of 98.67% in grafted blocks and 99.00% for the implants placed.

**Clinical evaluation technique:**<sup>9, 10, 12, 13-16, 18, 19</sup>

The grafted sites were re-evaluated after approx. 6 months and the success rate was assessed by checking<sup>15, 16</sup>

1. Absence of graft exposure and post-operative infection
2. Firm consistency
3. Bleeding from bone graft after removal of stabilization screw.
4. Absence of bone radiolucency
5. Stability and integration which was of primary concern, was checked by non-dislodgement of the graft and firm consistency.

Of the 302 grafted sites only 4 allogenic grafts were found to have not got integrated with the native bone.<sup>12, 16, 17</sup> The allograft used in maximum articles was cortico-cancellous FDBA.

In study by Peleg M.<sup>16</sup>, the blocks were exposed early and did not seem to have integrated with the native bone. Marginal bone resorption was seen around the block graft. Peripheral infection was observed and these blocks were recommended to have got removed in 5 months. No re-infection was seen after the graft removal in those sites.

The average gain in lateral ridge width was found ranging between 3 mm<sup>17</sup> to 5 mm<sup>10, 12, 18, 13</sup>. An average gain of 41%- 190% (range 1.5 to 9.8 mm) was found in the augmented site in horizontal dimension<sup>10</sup>. This wide range in width augmentation was dependent on many factors as graft processing and rehydration, the screw compressibility and removal of dead space, proper decortication of native bone and preparation of bur-created channels.

Overall, 402 implants were placed and all but 4 implants osseointegrated and matched the required initial stability<sup>13, 14, 15, 17</sup>

In evaluation by Nissan J.<sup>14</sup>, the only failed implant was removed at the time of implant exposure. After 3 months of undisturbed healing, a new implant was placed which successfully osseointegrated after a span of 3 months.

Nissan<sup>18</sup> evaluated allogenic block graft over post-traumatic alveolar ridge for lateral width requirement of >3mm. Average gain in width was 5 mm and 100% implants placed were successfully placed in 2-stage. Post traumatic ridges pose a challenge for the surgeon because dental trauma is accompanied by a loss of either bone or soft tissue (or both). Moreover, post-traumatic bone and soft tissue scarring combined with vascular compromise adds to the complexity of an esthetic implant-supported restoration.<sup>20, 21</sup>

Another exclusive study undertaken by Nissan<sup>13</sup> was restoration of congenitally missing teeth, using cancellous block-allografts. Average gain in width was 5mm and 95.4% implants placed were successfully placed for 2-stage. One implant failed which was immediately loaded. Implementation of an implant-supported

restoration was not always feasible in patients with congenitally missing teeth, owing to lack of patient willingness to undergo complex harvesting procedures and so absence of teeth results in undeveloped hard tissue. Bone grafting and implant treatment approach cannot be considered at young age, leading to further atrophy of the alveolar process with time. This study determined that there was no morbidity in augmentation of ridge in congenitally missing teeth.

**Histological technique:**<sup>9, 11, 12, 17, 19</sup>

To evaluate the graft's incorporation histologically, the surgery was carried out by re-entering the grafted site at a mean of 6-9 months after bone grafting where bone core from the graft was removed with a trephine bur and the specimens were stained with hematoxylin-eosin & Masson trichrome stain for the histologic analysis. The sections were examined by light microscopy.

In all the studies, newly formed vital bone, residual cancellous block allograft bone, and marrow/connective tissue were observed in all augmented sites. Residual cancellous block allograft was identifiable by the presence of empty lacunae and separation lines. Newly formed bone containing viable osteocytes, demonstrated intimate contact with the residual graft. Osteoblasts were present in conjunction with newly formed bone around the residual graft. There was no evidence of acute or chronic inflammatory infiltrate.

Contar et al.<sup>11</sup> histologically evaluated the suitability of fresh-frozen bone graft (test group), used in maxillary ridge augmentation, comparing it with autogenous (native) bone (control group) from the same patient. Histology revealed a typical lamellar arrangement around Haversian canals interspersed with osteocytes in lacunae, characteristic of secondary bone, in all specimens of the test group. Similar histologic aspects were observed in the control group. In Picrosirius staining, the arrangement of collagen fibers in test and control groups remained stable after 6-9 months.

In another study, younger patients < 40 years showed a statistically significant increase in new bone formation (38.6% versus 19.8%;  $P = .04$ ) and remodeling of the residual cancellous block allograft (20.1% versus 38.4%;  $P = .05$ ) than the elder age group. No differences in the percentage of the connective tissue were seen with regard to age.<sup>17</sup>

#### **IV. Discussion**

Anterior maxilla is the commonest region for a thin, narrow ridge as it is the area most prone for facial trauma due to road traffic accidents, traumatic extractions and in some cases, due to congenitally missing incisors. The augmentation of this area, becomes a crucial concern as it directly affects the patient's functional and psychological well-being. The regeneration requirement is higher because a 3-dimensional growth is expected.

Engquist<sup>22</sup> reported that 6-7% of implant failure takes place in mandible as compared to 19-35% in maxillary arch.

For this treatment, many different types of grafting materials come into consideration which include autografts, allografts, xenografts and the alloplasts. Autogenous bone is considered the "gold standard" for bone grafts<sup>6</sup>, since it provides 4 desirable properties of an ideal graft - osteoconduction, osteoinduction, and osteogenicity and osseointegration. However, the harvesting of mandibular block grafts from intraoral donor sites during outpatient procedures involves several potential risks and drawbacks, including blunting of papillae, injury to the inferior alveolar and mental nerves, chin ptosis, damage to the submental and sublingual arteries, limited graft size & shape and post-operative trismus<sup>23-29</sup>.

To overcome these complications, the use of allografts was started. The first bone allograft was performed in 1880 by Scottish surgeon to reconstruct humerus of a 4-yr old boy. For many years, allogenic bone in particulate form, either alone or in combination with other graft materials has served as a viable alternative to autogenous grafts. Allografts as Fresh frozen bone (FFB) and Freeze Dried Bone Allograft (FDBA), simply serve as an osteoconductive scaffold for new bone growth.<sup>30, 31</sup>

When demineralized freeze dried bone allograft (DFDBA) is used, it provides osteoinduction by the release of bone morphogenetic proteins from the graft. The process of osteoinduction determines the 3-dimensional growth of capillary vessels, peri-vascular tissues, and osteoprogenitor cells from the patient to the graft. The incorporation process of the graft happens through the gradual replacement of bone until the formation of new bone occurs, beginning with the acute inflammatory process and finished with a gradual substitution called as "creeping substitution".<sup>30, 32</sup>

The recipient site provides the mesenchymal cells that invade and produce the new bone, thereby augmenting the alveolar ridge. The augmentation is often complemented by the use of barrier membranes through guided bone regeneration.<sup>33-38</sup>

The advantages of using bone allografts include convenience of the surgeon, decreased operative trauma for the patient, almost unlimited supply of reconstructive material, absence of donor site morbidity, and decreased operative time.

The common concern of patients and providers, involves the incidence of disease transmission from tissue bank allografts, including HIV, hepatitis B and C viruses & human T-lymphotropic virus. The incidence of HIV transmission through tissue allografts was stated in 1990 to be at 1 in 1.5 million. Following the process of freeze drying the allograft, the incidence decreases to 1 in 8 million.<sup>39</sup>

Moreover, cryopreservation at -20 degree (lyophilization) of FFB using dimethyl sulfoxide and glycerol may preserve up to 80% of viable cells by removing water during the freezing process, and osteoblast-related cells can be grown from FFB.<sup>40</sup>

The use of cortico-cancellous allograft provides the most predictable results than cortical or cancellous alone; the cancellous component allows for vascular infiltration leading to integration, and the cortical component allows for rigid fixation and resistance to resorption. Consequently a block graft is recommended in augmentation exceeding 3mm width or height.<sup>10, 41</sup>

The aim of the present review was to evaluate the efficacy of allogenic block graft in lateral ridge augmentation in anterior maxilla. At the same time, the success of the augmentation procedure, per se, was evaluated by the changes in ridge dimension over time and the survival rate of implants placed in grafted bone. This systematic review studied 11 articles and the main findings supported the use of allografts in lateral augmentation. The results of these 11 articles agree with a previous systematic review<sup>42</sup> reporting that dental implants placed in augmented bone had survival rates >95% similar to those of implants placed in pristine bone which reviewed the efficacy of different grafting materials as xenografts, allografts and alloplasts in various regions of oral cavity. The most distinctive outcome of this systematic review, however, was the assessment of the exclusive usage of types of onlay block allografts for ridge augmentation in specifically maxillary anterior region along with histomorphometric data of intervention.

## V. Conclusion

The procedure of bone augmentation for implant placement is an integral part of dentistry today and usage of allogenic graft can be sought as an excellent alternative for autogenous grafts. Allogenic block allograft FDA is primarily osteoconductive while DFDBA possesses osteoinductive properties. This permits new bone formation following augmentation of extremely atrophic anterior maxillae which can be followed by two-stage implant placement. The studies showed success rate of 98.67% in allogenic grafted blocks and 99.00% for the implants placed. The deficient maxilla due to congenitally missing teeth can be successfully augmented with block graft. It was also inferred that new bone formation was age-dependent.

This review overcame the drawback of previous similar systematic review which had included studies with shorter follow-up period whereas this review has included the follow-up ranging 36-60 months.

### Limitations:

The initial and post graft dimensions were evaluated by means of a surgical template and the Weighted Mean Difference (WMD) was calculated<sup>12</sup>, while use of template was not made in any other study. So there was no uniformity in all the studies for measuring the clinical efficacy. The procurement and processing technique of the allogenic block graft in each study was mentioned only in some studies while other articles do not comment on the processing. The difference in processing can lead to difference in the graft quality and stability<sup>11, 15, 19</sup>. Although all studies examined the clinical and histologic outcome of graft, none study gave a radiological basis or precise bone development by use of CBCT (Cone Beam Computed Tomography) to assess the bone augmentation which is a determining factor for hard tissue examination. Another drawback of this study was its limited search due to inclusion of articles only in English language.

### Future implications:

This review further implies allogenic graft intervention by radiographic means as CBCT which can give most sensitive results.

As this review included all the clinical trials, efforts should be made to perform more Randomized Control Trials for the same intervention.

## Bibliography

- [1]. Laura G, John PS, Teja G & Joo O. Current trends in dental implants. *J Korean Assoc Oral Maxillofac Surg*. 2014; 2: 50-60.
- [2]. Schropp L. Bone healing and soft tissue contour changes following single-tooth extraction: a clinical and radiographic 12-month prospective study. *Int J Periodontics Restorative Dent* 2003; 23: 313-23.
- [3]. Seibert JS. Reconstruction of deformed, partially edentulous ridges, using full thickness onlay grafts. Part I. Technique and wound healing. *Compend Contin Educ Dent* 1983; 4: 437-53.
- [4]. VonArx T, Buser D. Horizontal ridge augmentation using autogenous block grafts and the guided bone regeneration technique with collagen membranes: a clinical study with 42 patients. *Clin Oral Implants Res* 2000; 4: 359-366.
- [5]. Donos N, Mardas N, Chadha V. Clinical outcomes of implants following lateral bone augmentation: systematic assessment of available options (barrier membranes, bone grafts, split osteotomy). *J Clin Periodontol* 2008; 35: 173-202.
- [6]. Listrom R, Symington J. Osseointegrated dental implants in conjunction with bone grafts. *Int J Oral Maxillofac Surg* 1988; 17: 116-118



- [7]. Silva F, Cortez A, Moreira R, Mazzone R. Complications of introral donor site for bone grafting prior to implant placement. *Implant Dent* 2006;15:420–426.
- [8]. Bavetta G, Licata ME. The use of human allogenic graft (HBA) for maxillary bone regeneration: review of literature and case reports. *Curr Pharm Des.* 2012;18: 5559-68
- [9]. Contar C, Sarot J, Bordini J, Galvão G, Nicolau G, Machado M. Maxillary ridge augmentation with fresh-frozen bone allografts. *J Oral Maxillofac Surg.* 2009; 67: 1280-5
- [10]. Wallace S, Gellin R. Clinical evaluation of freeze-dried cancellous block allografts for ridge augmentation and implant placement in the maxilla. *Implant Dent.* 2010; 19: 272-9
- [11]. Contar C et al. Fresh-Frozen Bone Allografts in Maxillary Ridge Augmentation: Histologic Analysis. *J Oral Implantol.* 2011; 37: 223-231
- [12]. Orsini G. Clinical and histologic evaluation of fresh frozen human bone grafts for horizontal reconstruction of maxillary alveolar ridges. *Int J Periodontics Restorative Dent.* 2011; 31: 535-44.
- [13]. Nissan J, Mardinger O, Strauss M, Peleg M, Sacco R, Chaushu G. Implant-supported restoration of congenitally missing teeth using cancellous bone block-allografts. *J Oral Surg Oral Med Oral Pathol Oral Radiol Endod.* 2011; 111: 286-91.
- [14]. Nissan J, Mardinger O, Calderon S, Romanos G, Chaushu G. Cancellous bone block allografts for the augmentation of the anterior atrophic maxilla. *Clin Implant Dent Relat Res.* 2011; 13: 104-11.
- [15]. Barone A, Varanini P, Orlando B, Tonelli P, COvani U. Deep-Frozen Allogeneic Onlay Bone Grafts for Reconstruction of Atrophic Maxillary Alveolar Ridges: A Preliminary Study. *J Oral and Maxillofac Surg* 2009; 67: 1300–06.
- [16]. Peleg M et al. Use of cortico-cancellous allogeneic bone blocks for augmentation of alveolar bone defects. *Int J Oral Maxillofac Implants.* 2010; 25: 153-62.
- [17]. Nissan J, Marilena V, Gross O, Mardinger O, Chaushu G. Histomorphometric analysis following augmentation of the anterior atrophic maxilla with cancellous bone block allograft. *Int J Oral Maxillofac Implants.* 2012; 27: 84-9.
- [18]. Nissan J, Gross O, Mardinger O, Ghelfan O, Sacco R, Chaushu G. Post-traumatic implant-supported restoration of the anterior maxillary teeth using cancellous bone block allografts. *J Oral Maxillofac Surg.* 2011; 69: 513-8.
- [19]. Acocella A, Bertolai R, Ellis E, Nissan J, Sacco R. Maxillary alveolar ridge reconstruction with monocortical fresh-frozen bone blocks: a clinical, histological and histomorphometric study. *J Craniomaxillofac Surg.* 2012; 40: 525-33.
- [20]. Andersson L, Emami-Kristiansen Z, Högström J. Single-tooth implant treatment in the anterior region of the maxilla for treatment of tooth loss after trauma: A retrospective clinical and interview study. *J Dent Traumatol* 2003; 19: 126
- [21]. Schwartz-Arad D, Levin L. Post-traumatic use of dental implants to rehabilitate anterior maxillary teeth. *J Dent Traumatol* 2004; 20: 304
- [22]. Engquist B, Bergendal T, Kallus T, Linden U. A retrospective multicenter evaluation of osseointegrated implants supporting overdentures. *Int J Oral Maxillofac Implants* 1988; 3: 129- 34.
- [23]. Clavero J, Lundgren S. Ramus or chin grafts for maxillary sinus inlay and local onlay augmentation: Comparison of donor site morbidity and complications. *Clin Implant Dent Relat Res* 2003; 5: 154–160.
- [24]. Misch C. Comparison of intraoral donor sites for onlay grafting prior to implant placement. *Int J Oral Maxillofac Implants* 1997; 12: 767–776.
- [25]. Nkenke E, Radespiel-Troger M, Wiltfang J, Schultze S, Winkler G, Neukam F. Morbidity of harvesting of retromolar bone grafts: A prospective study. *Clin Oral Implants Res* 2002; 13: 514–521.
- [26]. Joshi A. An investigation of post-operative morbidity following chin graft surgery. *Br Dent J* 2004;196:215–218.
- [27]. VonArx T, Hafliger J, Chappuis V. Neurosensory disturbances following bone harvesting in the symphysis: A prospective clinical study. *Clin Oral Implants Res* 2005;16:432–439.
- [28]. Booiij A, Raghoobar G, Jansma J, Kalk W, Vissink A. Morbidity of chin bone transplants used for reconstruction alveolar defects in cleft patient. *Cleft Palate Craniofac J* 2005; 42: 533–538.
- [29]. VonArx T. Lateral ridge augmentation using different bone fillers and barrier membrane application. A histologic and histomorphometric pilot study in the canine mandible. *Clin Oral Implants Res* 2001; 12: 260–269.
- [30]. Hellem S, Astrand P, Strenstrom B, Engquist B, Bengtsson M, Dahlgren S. Implant treatment in combination with lateral augmentation of the alveolar process: A 3-year prospective study. *Clin Implant Dent Relat Res* 2003; 5: 233–240.
- [31]. Mulliken J, Glowacki J, Kaban L, Folkman J, Murray J. Use of demineralised allogeneic bone implants for the correction of maxilla-craniofacial deformities. *Ann Surg* 1981; 194: 366-72.
- [32]. Köndell P, Mattson T, Astrand P. Immunological responses to maxillary onlay allogeneic bone grafts. *Clin Oral Implants Res* 1996; 7: 373-377.
- [33]. Trentz OA, Hoerstrup SP, Sun L, Bestmann L, Platz A, Trentz O. Osteoblasts' response to allogeneic and xenogenic solvent dehydrated cancellous bone in vitro. *Biomaterials* 2003; 24: 3417–26.
- [34]. Block M, Finger I, Lytle R. Human mineralized bone in extraction sites before implant placement: Preliminary results. *J Am Dent Assoc* 2002;133:1631–1638.
- [35]. Feuille F, Knapp C, Brunsvold M, Mellonig J. Clinical and histologic evaluation of bone-replacement grafts in the treatment of localized alveolar ridge defects. Part 1: *Int J Periodontics Restorative Dent* 2003; 23: 29–35.
- [36]. Minichetti J, D'Amore J, Hong A, Cleveland D. Human histologic analysis of mineralized bone allograft (Pur-oss) placement before implant surgery. *J Oral Implantol* 2004; 30: 74–82.
- [37]. Tadic D, Epple M. A thorough physicochemical characterization of 14 calcium phosphate-based bone substitution materials in comparison to natural bone. *Biomaterials* 2004; 25: 987–994.
- [38]. Buck B, Resnick L, Shah S, Malinin T. Human immunodeficiency virus: An estimate of risk of acquired immunodeficiency syndrome (AIDS). *Clin Orthop* 1989; 240: 129–136.
- [39]. Egli R, Wingenfeld C, Hölzle M. Histopathology of cryopreserved bone allo and isografts: Pretreatment with dimethyl sulfoxide. *J Invest Surg* 2006;19:87–96.
- [40]. Palacci P, Ericsson I. Minor bone augmentation procedures. *Esthetic Implant Dentistry in Soft and Hard Tissue Management.* Quintessence 2001:137–158.
- [41]. Chiapasco M, Abati S, Romeo E, Vogel G. Clinical outcome of autogenous bone blocks or guided bone regeneration with e-PTFE membranes for the reconstruction of narrow edentulous ridges. *Clin Oral Implants Res* 1999; 10: 278–288.
- [42]. Sanz-Sánchez I, Ortiz-Vigón A, Sanz-Martín, Figuero E, Sanz M. Effectiveness of Lateral Bone Augmentation on the Alveolar Crest Dimension: A Systematic Review and Meta-analysis. *J Dent Res.* 2015; 94: 128-42.