

## Effect of Metformin on Alveolar Bone Loss in Type 2 Diabetic Rat Model with Experimental Periodontitis

Dr Neethu Mercy James<sup>1</sup>, Dr Thomas George V<sup>2</sup>, Dr Nebu George Thomas<sup>3</sup>,  
Dr Yogesh Bharat Dalvi<sup>4</sup>, Dr Ruby Varghese<sup>5</sup>, Dr Prameetha George Ittycheria<sup>6</sup>

<sup>1</sup>(Post graduate student, Dept. of Periodontology and Implantology, Pushpagiri College of Dental Sciences, India)

<sup>2</sup>(Professor and Head of the Department, Dept. of Periodontology and Implantology, Pushpagiri College of Dental Sciences, India)

<sup>3</sup>(Professor, Dept. of Periodontology and Implantology, Pushpagiri College of Dental Sciences, India)

<sup>4</sup>(Scientist & Research Co-Ordinator, Pushpagiri Research Center, India)

<sup>5</sup>(Research associate, Pushpagiri Research Center, India)

<sup>6</sup>(Senior lecturer, Dept. of Periodontology and Implantology, Pushpagiri College of Dental Science India)

### Abstract:

#### Background:

Because of the established two-way relationship of diabetes and periodontitis, the research involving a drug that can reduce both alveolar bone loss in periodontitis and hyperglycemia in diabetes mellitus is of prime importance. Metformin is an antihyperglycemic drug used for the management of type 2 diabetes mellitus. To the best of our knowledge, there have been no studies investigating the effect of metformin on the association of these two diseases which emphasizes the novelty of this study. Thus, the aim of the study is to assess the effect of metformin on alveolar bone loss histologically in a type 2 diabetic rat model with experimental periodontitis.

#### Materials and Methods:

Thirty - five Sprague Dawley rats were divided into five groups: Group 1: normal control animals, Group 2: periodontitis only, Group 3: diabetes only, Group 4: diabetes with periodontitis, Group 5: diabetes with periodontitis receiving metformin. Diabetes mellitus was induced by nicotinamide (230 mg/kg, ip) and streptozotocin (65 mg/kg, iv). One day after diabetes confirmation, group 5, received metformin 100 mg/kg body weight intraperitoneally. Silk ligatures was tied subgingivally around upper right first molar tooth to induce periodontitis. On day 30, all the animals were euthanized and effect of metformin on alveolar bone loss were histologically examined to assess the differences among the study groups.

**Results:** Metformin administration had reduced the inflammation and increased the osteoblastic activity in group 5, which was significantly higher than all other groups.

**Conclusion:** The findings confirm that metformin reduces alveolar bone loss and the inflammatory response in diabetic rats with periodontitis receiving metformin.

**Key Word:** Periodontitis, Diabetes Mellitus, Metformin, Alveolar bone

Date of Submission: 18-05-2020

Date of Acceptance: 03-06-2020

### I. Introduction

Periodontitis is a chronic inflammatory disease characterized by the progressive destruction of cementum, periodontal ligament and alveolar bone and subsequent loss of teeth.<sup>1</sup> Periodontitis in its severe forms, affect approximately 10% of the global population accounting for nearly 750 million people worldwide.<sup>2</sup> Alveolar bone loss is the hallmark of periodontitis progression and its prevention is the key challenge in the treatment. Diabetes mellitus (DM) is a metabolic disorder due to defects in insulin production, insulin action or both and is characterized by hyperglycemia. The vast majority (90%- 95%) of these metabolic hyperglycemic diseases are type 2 diabetes mellitus (T2DM). DM had reached epidemic levels worldwide, now affecting 425 million people and accounting for 4 million deaths in 2017.<sup>3</sup>

Periodontitis and diabetes mellitus are two complex chronic diseases that mutually and adversely affect each other. Large body of evidence had confirmed that diabetes can aggravate the severity of periodontitis. Hyperglycemia plays a crucial role in the pathogenesis of periodontitis.<sup>4</sup> Uncontrolled or poorly controlled diabetes is associated with increased susceptibility to and severity of infections, including periodontitis<sup>5</sup> and is

now considered as the sixth complication of DM.<sup>6</sup> On the other hand, periodontitis adversely affects glycemic control in patients with diabetes mellitus and contributes to the development of diabetic complications.<sup>7</sup>

Because of the bidirectional relationship between periodontitis and diabetes mellitus, research involving a drug that can reduce both blood glucose levels and alveolar bone loss is of extreme importance. Metformin is one of the most widely prescribed antihyperglycemic agent and is considered as the gold standard among oral antidiabetic drugs. An epidemiological study reported that metformin significantly reduced the risk of diabetes associated fractures at any site.<sup>8</sup> Over the years, the effect of metformin on bone has been thoroughly investigated and provided a considerable body of in vitro<sup>9</sup>, ex vivo<sup>10</sup> and in vivo<sup>11</sup> as well as clinical evidence<sup>12</sup> for the protective effect of metformin on bone in diabetes. In an experimental periodontitis model, the beneficial effect of metformin on alveolar bone was demonstrated after 10 days.<sup>11</sup> Most of the studies had focused predominantly on the effects of metformin on bone formation in diabetes and only one study had investigated the effect of metformin in an experimental periodontitis model. Till date, no study has evaluated the effect of metformin on inflammation in the gingival tissue and alveolar bone loss in a diabetic animal model with experimental periodontitis which emphasizes the novelty of this study. Although clinical and radiographic models are a good alternative, histologic analysis is considered as the gold standard to determine cellular events associated with the disease progression. Therefore, the aim of this study, is to assess the effect of metformin on alveolar bone loss histologically in a type 2 diabetic rat model with experimental periodontitis.

## **II. Material and Methods**

### **In vivo experimental design**

Thirty-five male Sprague-Dawley rats, aged 8-10 weeks and weighing 150-200 g procured from Small Animal Breeding Section at Kerala Agricultural University (Mannuthy, Thrissur) were used. They were housed in plastic cages labeled with cage cards and maintained in an air-conditioned room under uniform husbandry condition of temperature ( $25 \pm 5^\circ\text{C}$ ), humidity ( $55 \pm 5\%$ ) controlled room with a 12/12-hour light /dark cycle. Animals were maintained on a standard rat pellet diet and water ad libitum. Thirty days after periodontitis induction, all the animals were euthanized using a CO<sub>2</sub> chamber. Protocol for the experimental procedures and animal treatment was reviewed and approved by Institutional Ethics Committee, Pushpagiri College of Dental Sciences (Reference No. PCDS/IEC/K4/10/17) and Institutional Animal Ethics Committee, Pushpagiri Institute of Medical Sciences and Research Centre, Tiruvalla, India and were in compliance with the guidelines of the Committee for the Purpose of Control and Supervision of Experiments on Animals (CPCSEA), India.

At the end of the 2-week acclimatization period, the animals were randomly divided into five groups with seven rats in each group : (i) Group 1, normal control rats ,(ii) Group 2, periodontitis control rats,(iii) Group 3, diabetic control rats, (iv) Group 4, diabetic rats with periodontitis,(v) Group 5, diabetic rats with periodontitis receiving metformin.

### **Induction of diabetes**

After a 15 hour fast, nicotinamide (230 mg/ kg; Himedia) was given intraperitoneally, 15 minutes before the administration of streptozotocin (65 mg/kg; Sigma-Aldrich) intravenously to rats from group 3,4 and 5. Nicotinamide and streptozotocin were freshly prepared in 0.9% sodium chloride solution and citrate buffer (pH 4.5), respectively.<sup>13</sup> Blood samples were obtained from the tip of the tail of rats from groups 3,4 and 5 before and 10 days after diabetes induction and blood glucose levels were measured using glucometer.<sup>14</sup> Blood glucose of all rats was monitored at regular intervals. A glucose level greater than 150 mg/dl confirmed the presence of diabetes.

### **Metformin treatment**

One day after diabetes confirmation, the rats from group 5 received metformin 100mg/kg body weight (Metformin hydrochloride, Sigma-Aldrich) intraperitoneally once daily until the day of euthanasia.<sup>15</sup>

### **Induction of experimental periodontitis**

When the blood samples confirmed that the glycemic control was succeeded in the rats from group 5, then the rats from groups 2,4 and 5 were anesthetized with intraperitoneal injection of 10% ketamine (70 mg/kg;Aneket) and 2% xylazine (10 mg/kg;Xylaxin) and 5-0 silk ligature (Centinal surgical sutures, India) was tied subgingivally around upper right first molar tooth to induce periodontitis<sup>16</sup> and this day was considered as the day 0.<sup>17</sup> Ligatures were checked on every three days by reflecting the cheeks and tongue using retractors and ensured that it remained in placed throughout the experimental period in all animals. If the ligatures are lost or loosened, then it was replaced.

### **Euthanasia and tissue processing**

After thirty days of periodontitis induction, all animals were euthanized using a CO<sub>2</sub> chamber under deep anesthesia. The maxilla was excised and sectioned into two halves using a physiodispensor (Nobel Biocare, Switzerland) with water irrigation. The block section was fixed in 10% neutral buffered formalin and demineralized in 10% formic acid. Histological evaluation was performed by a one calibrated examiner who was blinded to the experimental groups.

**Histological evaluation**

For haematoxylin - eosin staining, specimens were dehydrated, embedded in paraffin blocks and histologic sections of 6 µm thickness, corresponding to the mesial root of the upper right first molar was taken and evaluated by light microscopy with an optical microscope. Inflammatory cell infiltration (ICI) was evaluated by counting inflammatory cells (lymphocytes) in connective tissue and scored according to the following system: 0 = no inflammation; 1 = <15 inflammatory cells per field; 2 = 15 to 50 inflammatory cells per field; and 3 = >50 inflammatory cells per field.<sup>18</sup> Osteoblastic activity was determined, by semiquantitative scoring in the visible active bone formation surfaces which was limited by osteoid and cuboidal osteoblasts as no activity (0), mild/moderate activity (1), high activity (2). Osteoclasts were counted based on their morphology. Multi-nucleated giant cells with existing resorption lacunae, ruffled border and an eosinophilic view were counted as osteoclasts.<sup>19</sup>

**Statistical analysis**

The number of inflammatory cell infiltrate scores, osteoblastic score and osteoclastic numbers were determined. Data were entered using Microsoft Excel and were expressed as mean ± standard deviation. The differences in inflammatory cell infiltrate scores, osteoblastic score and osteoclastic numbers will be compared using the Kruskal Wallis test followed by Bonferroni’s test. A p-value of <0.05 indicated a significant difference. The SPSS statistical package, version 20.0 was used for all statistical analyses.

**III. Results**

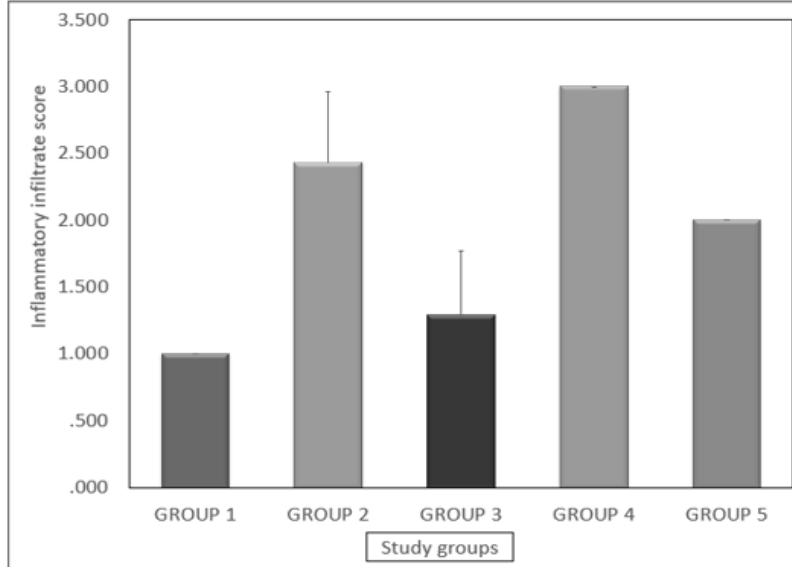
**Inflammatory cell infiltration (ICI) scoring**

To estimate the degree of inflammation, the infiltration of inflammatory cells (lymphocytes) were counted (Figure 1; Table 1).

**Table 1:** Descriptive statistics of inflammatory cell infiltrate in the study groups

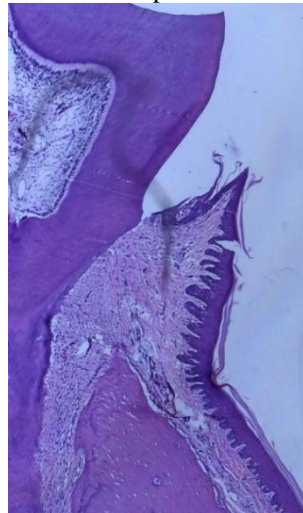
Group	Group 1	Group 2	Group 3	Group 4	Group 5
N	7	7	7	7	7
Mean	1.000	2.429	1.286	3.000	2.000
Std. Deviation	0.0000	0.5345	0.4880	0.0000	0.0000
Median	1.000	2.000	1.000	3.000	2.000
Minimum	1.0	2.0	1.0	3.0	2.0
Maximum	1.0	3.0	2.0	3.0	2.0

**Figure 1:** Graph demonstrating inflammatory cell infiltrate in the study groups

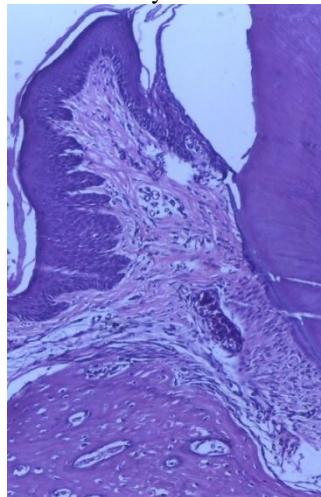


The ICI in the group 4 was significantly higher than the ICI in groups 1,2, and 3 ( $p < 0.0001$ ) (Figure 2A,2B).

**Figure 2A:** Normal periodontium of a rat



**Figure 2B:** Inflammatory cell infiltration in group 2



The ICI in group 5 was lower than the ICI in group 4 and group 2, but there was no statistically significant difference between group 5 and group 2 ( $p>0.0001$ ). There was also no significant difference in ICI between group 3 and group 1 ( $p>0.0001$ ).

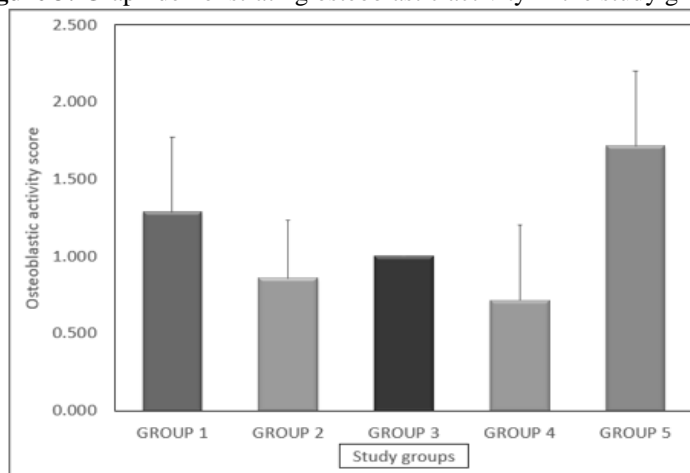
**Osteoblastic activity score**

The mean osteoblastic activity in group 1 was higher than that of groups 2, 3 and 4, but was not statistically significant. ( $p>0.0001$ )(Figure 3; Table 2).

**Table 2:** Descriptive statistics of osteoblastic activity in the study groups

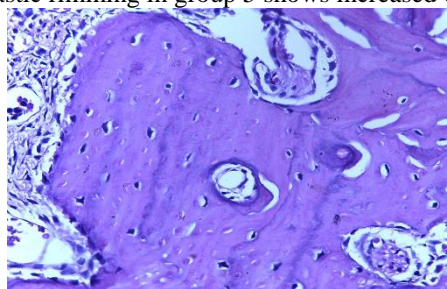
Group	Group 1	Group 2	Group 3	Group 4	Group 5
N	7	7	7	7	7
Mean	1.286	0.857	1.000	0.714	1.714
Std. Deviation	0.4880	0.3780	0.0000	0.4880	0.4880
Median	1.000	1.000	1.000	1.000	2.000
Minimum	1.0	0.0	1.0	0.0	1.0
Maximum	2.0	1.0	1.0	1.0	2.0

**Figure 3:** Graph demonstrating osteoblastic activity in the study groups



The presence of diabetes and periodontitis had decreased the osteoblastic activity in group significantly when compared to all other groups. Also, there was no significant difference in osteoblastic activity between group 4, group 3 and group 2 ( $p>0.0001$ ). A statistically significant osteoblastic activity in group 5 was observed when compared to all other groups ( $p<0.0001$ )(Figure 4).

**Figure 4:** Osteoblastic rimming in group 5 shows increased osteoblastic activity



However, there was no significant difference in osteoblastic activity between the group 5 and groups 1( $p>0.0001$ ).

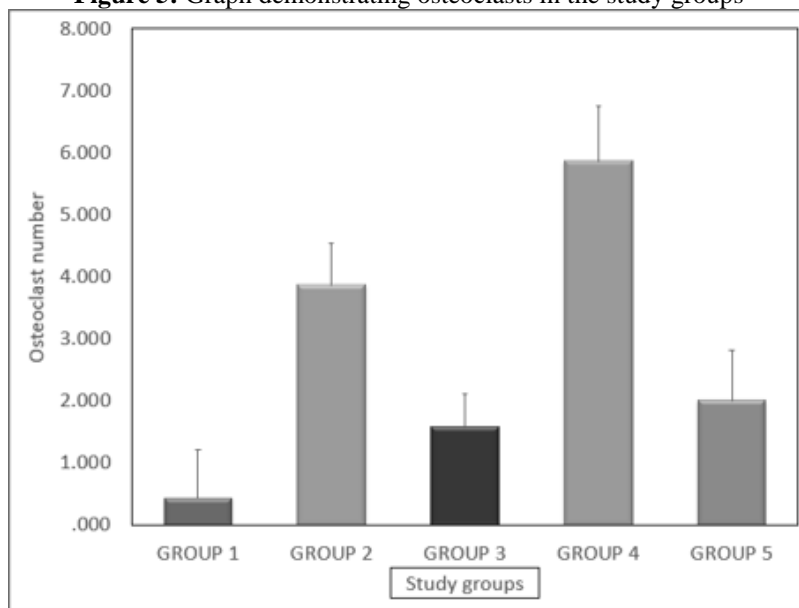
**Osteoclast number**

There was a significantly higher number of osteoclasts in the group 4 than in the groups 1, 2, 3 and 5 (Figure 5; Table 3).

**Table 3:** Descriptive statistics of osteoclasts in the study groups

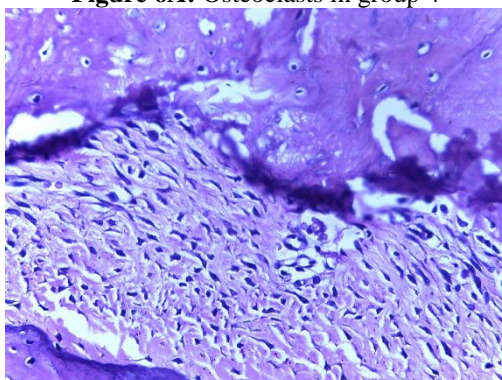
Group	Group 1	Group 2	Group 3	Group 4	Group 5
N	7	7	7	7	7
Mean	0.429	3.857	1.571	5.857	2.000
Std. Deviation	0.7868	0.6901	0.5345	0.8997	0.8165
Median	0.000	4.000	2.000	6.000	2.000
Minimum	0.0	3.0	1.0	5.0	1.0
Maximum	2.0	5.0	2.0	7.0	3.0

**Figure 5:** Graph demonstrating osteoclasts in the study groups

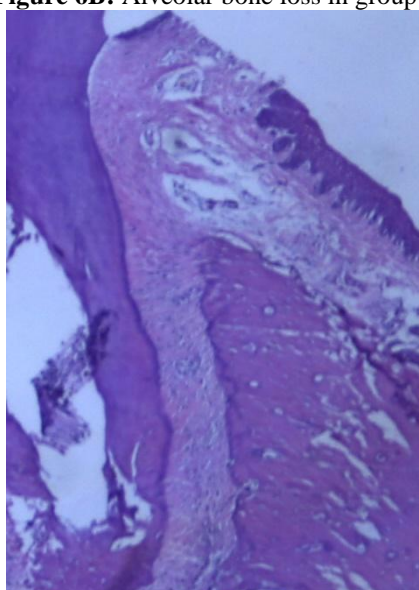


The number of osteoclasts in group 5 is significantly lower than in group 4 and group 2 ( $p<0.0001$ ). There was a higher number of osteoclasts in group 5 than in group 3, but this was not statistically significant ( $p>0.0001$ ) (Figure 6A,6B). Also, no statistical differences ( $p<0.0001$ ) were found among groups 3 and 1 regarding the osteoclast numbers.

**Figure 6A:** Osteoclasts in group 4



**Figure 6B:** Alveolar bone loss in group 4



#### **IV. Discussion**

The bidirectional link between the periodontitis and diabetes mellitus had been well established. Patients with type 2 diabetes mellitus have an increased prevalence and severity of periodontal disease than those without diabetes. Hyperglycemia has the potential to alter the local environment in the periodontal pockets, increase the glucose concentration in the gingival crevicular fluid (GCF) and leads to qualitative changes in the microflora.<sup>20</sup> The function of neutrophils is often impaired in diabetes and the hyperresponsiveness of monocytes/macrophages results in significantly increased production of proinflammatory cytokines like TNF- $\alpha$  and IL-1 $\beta$  and IL-6. Downregulation of proliferation and differentiation of periodontal osteoblasts has been demonstrated in diabetic animals.<sup>21</sup> Elevated blood sugar results in higher levels of accumulation of advanced glycation end products (AGEs) in diabetic gingival tissues. It is this interaction between the receptor of AGE (RAGE) and AGEs in periodontal tissues results in the marked elevation in gingival crevicular fluid levels of IL-1 $\beta$ , TNF- $\alpha$ , and PGE<sub>2</sub> seen in diabetic subjects compared to non-diabetic individuals.<sup>22</sup> All these changes account for periodontal destruction in patients with diabetes, especially when glycemic control is poor, while periodontitis has been shown to have a significant impact on diabetes and increases the risk of worsening glycemic control.<sup>7</sup>

Metformin is an antidiabetic drug commonly used to treat type 2 diabetes mellitus. A number of pleiotropic effects of metformin have been identified, including improved lipid metabolism, an angioprotective effect, beneficial effects on diabetic cardiomyopathy and improved vascular reactivity. The activation of adenosine monophosphate activated protein kinase (AMPK) appears to account for many of these effects of metformin.<sup>23</sup> Studies have shown that the use of metformin had significantly decreased the risk for bone fractures associated with diabetes<sup>8</sup> and dose-dependently increased osteoblastic proliferation, differentiation, and mineralization by activation of extracellular-regulated kinases.<sup>9</sup> *In vitro* experiments have demonstrated that AMPK activation enhances osteogenesis.<sup>24</sup> This evidence suggests a critical role for AMPK in bone

metabolism. *In vivo* studies have demonstrated that metformin prevents bone loss in ovariectomized rats<sup>25</sup> and exerts a beneficial effect on alveolar bone in ligature induced periodontitis by increasing osteoblast differentiation.<sup>11</sup> The therapeutic effect of systemic administration of metformin on the association of these two diseases has not been elucidated to date. In this study, we assess the effect of metformin on alveolar bone loss histologically in a type 2 diabetic rat model with experimental periodontitis.

The ICI in the group 1 was significantly lower than the ICI in the other groups. Histological analysis in group 1 showed that the structure of the periodontium is normal. In group 2, periodontitis induced by ligatures had significantly raised the inflammatory cells infiltration. As in human periodontitis, the destruction of periodontal tissues in experimental periodontitis is mainly caused by host response.<sup>26</sup> Diabetes had also increased inflammation in the periodontal tissues. Also, there was no significant difference in ICI between group 1 and group 3. The number of inflammatory cells infiltrating the connective tissue were increased in group 4 when compared to other groups. The periodontium of the animals in group 4 revealed significant inflammatory cell infiltration coupled with severe destruction of the cementum and alveolar process. The ICI in the group 5 was lower than the ICI in the group 4 and group 2. The metformin administration had reduced the inflammation induced by diabetes and periodontitis. Previous studies reported that metformin also exerts anti-inflammatory effects beyond its function on glucose metabolism.<sup>27</sup> This result is in agreement with that of a recent study which had investigated the role of metformin on the LPS- influenced inflammatory response.<sup>28</sup> The ICI in group 5 was lower than the ICI in group 2, but this was not statistically significant ( $p > 0.05$ ).

Osteoblasts are the key cells in bone formation. The mean osteoblastic activity in group 1 was higher when compared to groups 2, 3 and 4. The ligation causes mechanical trauma to the dentogingival area and reduces the tissue integrity and favors the formation of bacterial plaque.<sup>16</sup> In group 2, bacterial plaque accumulation induced a local inflammatory response in the periodontium. The resultant influx of inflammatory cells produced a host of cytokines that promote resorption through osteoclasts. Though, the fine balance between protective and destructive processes gets disturbed and this accounts for the reduction in osteoblastic score in group 2 when compared to groups 1 and 3, this difference was not statistically significant. Persistent hyperglycemia in group 3 had also resulted in a reduction in the number of osteoblasts. The accumulation of AGEs in diabetic tissues had contributed to increased apoptosis of osteoblasts.<sup>21</sup> Diabetes also reduces the expression of transcription factors that regulate osteoblast differentiation.<sup>29</sup> AGEs had shown to prevent the differentiation of mesenchymal stem cells to osteoblasts.<sup>21</sup> In diabetic animals, an increase in osteoblast apoptosis is also caused by elevated levels of inflammatory mediators, particularly TNF- $\alpha$ . The presence of diabetes and periodontitis had decreased the osteoblastic activity in group 4 when compare to all other groups. Evidence exists that both diabetes and bacterial infection in periodontitis alters the normal bone coupling process. Diabetes also increases the apoptosis of periodontal ligament cells that are induced by periodontal infection by increasing the apoptosis of these cells<sup>30</sup> and prevents the differentiation into osteoblasts. Elevated AGE-RAGE interaction also results in an increase in pro-inflammatory cytokine expression and induces osteoblast apoptosis.<sup>31</sup> In the present study, osteoblastic activity in group 5 was significantly higher when compared to group 2, group 3 and group 4. The osteogenic effect of metformin observed on alveolar bone was explained by the increased proliferation of osteoblasts.<sup>9</sup> These results are similar to the increased osteoblast proliferation observed following intraperitoneal injections of metformin in a study using the periodontitis model.<sup>11</sup> In an another study that evaluated the effect of metformin on tibial bone loss in ovariectomized rats had demonstrated that osteoblast genes determined the proliferation and differentiation of osteoblast.<sup>26</sup>

Osteoclasts are the principal bone resorptive cells and stimulation of their activity is an essential requirement for alveolar bone loss. There was a significantly higher number of osteoclasts in group 2 when compared to group 1 and group 3. In group 2, the formation of osteoclasts is driven by the proinflammatory cytokines (IL-1 and IL-6, TNFs) in periodontitis. The interaction of RANKL with receptors (RANK) on the surface of osteoblasts is one of the most potent inducers of osteoclast formation and activity.<sup>32</sup> The binding of RANKL to its receptor RANK results in the activation of the c-jun terminal kinase and the subsequent activation of nuclear factor-kappa B, leading to osteoclast formation. In group 3, hyperglycemia had shown to enhance osteoclast formation. *In vitro* studies suggest that hyperglycemia directly promote osteoclast differentiation and activation. Statistically, significant difference was observed in group 4 when compared to groups 2,3 and 5. In group 4, periodontitis and diabetes have significantly induced the production of higher levels of local inflammatory mediators such as IL1 $\beta$ , TNF- $\alpha$  and prostaglandin E<sub>2</sub>, which in turn resulted in more prolonged osteoclast formation and activity.<sup>33</sup> Studies with animals suggest that RANK-RANKL/OPG ratios and the level of other inflammatory cytokines, such as TNF, are critical mediators of the enhanced osteoclastogenesis in diabetes with periodontal disease.<sup>34</sup> Histological observations indicated that there was a significant reduction in the presence of multinucleated osteoclasts in group 5 when compared to groups 2 and 4. It was observed that exposure to metformin led to a decrease in osteoclast and bone formation. In a study, metformin had a negligible effect on osteoclasts but decreased RANKL/OPG ratios and, hence, inhibited proliferation of osteoclasts. Metformin significantly reduced the number of osteoclasts in the proximal tibiae of ovariectomized rats, which was accompanied by a decrease in RANKL and an increase in OPG expression.<sup>35</sup> There was no statistically



significant difference observed between group 5 and group 3. A higher number of osteoclasts in group 5 is due to the presence of both diabetes and periodontitis whereas group 3 animals were only diabetic.

## V. Conclusion

Within the limitations of this study it can be concluded that in periodontitis and diabetic animal model, the use of metformin reduced inflammatory cell infiltrate and the alveolar bone loss. In addition, metformin also increased osteoblastic activity, thereby increasing bone formation. These findings suggest that the use of metformin can be offered as a potential therapeutic mode for alveolar bone loss, particularly for periodontitis patients with type 2 diabetes mellitus.

## Acknowledgments

This work was supported by the Indian Council of Medical Research (ICMR), Government of India, New Delhi, under the scheme MD/MS/DM/MCH/MDS thesis grant [Ref. No.3/2/June-2017/PG-Thesis-HRD (56)]

## References

- [1]. Socransky, S.S. and Haffajee, A.D. Periodontal microbial ecology. *Periodontol* 2000 2005; 38:135-87
- [2]. Kassebaum, N. J., Bernabé, E., Dahiya, M., Bhandari, B., Murray, C. J. L., & Marcenes, W. Global burden of severe periodontitis in 1990–2010: A systematic review and meta- regression. *J. Dent. Res* 2014; 93: 1045-53
- [3]. International Diabetes Federation .IDF Diabetes Atlas.;2017.
- [4]. World Health Organization. Definition and Diagnosis of Diabetes Mellitus and Intermediate Hyperglycaemia; Report of a WHO/IDF Consultation. Geneva, Switzerland: World Health Organization, International Diabetes Federation; 2006.
- [5]. Safkan-Seppala B, Ainamo J. Periodontal conditions in insulin-dependent diabetes mellitus, *J Clin Periodontol* 1992;19:24-9
- [6]. Løe H. Periodontal disease: the sixth complication of diabetes mellitus. *Diabetes care*. 1993;16(1):329-34
- [7]. Grossi SG, Genco RJ. Periodontal disease and diabetes mellitus: a two-way relationship. *Ann Periodontol* 1998;3(1):51-61
- [8]. Vestergaard P, Rejnmark L, Mosekilde L. Relative fracture risk in patients with diabetes mellitus, and the impact of insulin and oral antidiabetic medication on relative fracture risk. *Diabetologia* 2005;48(7):1292-9
- [9]. Cortizo AM, Sedlinsky C, McCarthy AD, Blanco A, Schurman L. Osteogenic actions of the anti-diabetic drug metformin on osteoblasts in culture. *Eur J Pharmacol*.2006 ;536(1):38-46
- [10]. Molinuevo MS, Schurman L, McCarthy AD, Cortizo AM, Tolosa MJ, Gangoiti MV, Arnol V, Sedlinsky C. Effect of metformin on bone marrow progenitor cell differentiation: in vivo and in vitro studies. *J Bone Miner Res* 2010; 25: 211-21
- [11]. Bak EJ, Park HG, Kim M, Kim SW, Kim S, Choi SH. The effect of metformin on alveolar bone in ligature-induced periodontitis in rats: a pilot study. *J Periodontol*. 2010;81(3):412-9
- [12]. Pradeep AR, Rao NS, Naik SB, Kumari M. Efficacy of varying concentrations of subgingivally delivered metformin in the treatment of chronic periodontitis: a randomized controlled clinical trial. *J Periodontol* 2013 ;84(2):212-20
- [13]. Furman, B.L Streptozotocin-induced diabetic models in mice and rats. *Curr. Protoc. Pharmacol*. 2015; 70:5.47.1-5.47.20
- [14]. Donovan J and Brown,P. Blood Collection.*Curr.Protoc.Immunol*.2006;73:1.7.1-1.6.10
- [15]. Sun J, Du J, Feng W, Lu B, Liu H, Guo J. Histological evidence that metformin reverses the adverse effects of diabetes on orthodontic tooth movement in rats. *J Mol Hist* 2017; 48:73-81
- [16]. Graves DT, Fine D, Teng Y-TA, Van Dyke TE, Hajishengallis G. The use of rodent models to investigate host–bacteria interactions related to periodontal diseases. *J Clin Periodontol*. 2008; 35: 89-105
- [17]. Holzhausen M, Garcia DF, Pepato MT, Marcantonio E. The influence of short- term diabetes mellitus and insulin therapy on alveolar bone loss in rats. *J Periodontal Res*. 2004;39(3):188-9327
- [18]. Özdemir SP, Kurtiş B, Tüter G, Bozkurt Ş, Gültekin SE, Sengüven B et al., Effects of low-dose doxycycline and bisphosphonate clodronate on alveolar bone loss and gingival levels of matrix metalloproteinase-9 and interleukin-1β in rats with diabetes: A histomorphometric and immunohistochemical study. *J Periodontol*. 2012 ;83(9):1172-82
- [19]. Toker H, Ozdemir H, Balcı H, Ozer H. N- acetylcysteine decreases alveolar bone loss on experimental periodontitis in streptozotocin- induced diabetic rats. *J Periodontal Res*. 2012 ;47(6):793-9
- [20]. Ficara AJ, Levin MP, Grower MF. A comparison of the glucose and protein content of gingival fluid from diabetics and nondiabetics. *J Periodontal Res* 1975; 10:171-5
- [21]. Liu R, Bal HS, Desta T. Diabetes enhances periodontal bone loss through enhanced resorption and diminished bone formation. *J Dent Res* 2006;85: 510-4
- [22]. Engebretson SP, Hey-Hadavi J, Ehrhardt FJ. Gingival crevicular fluid levels of interleukin-1β and glycemic control in patients with chronic periodontitis and type 2 diabetes. *J Periodontol* 2004;75:1203-08
- [23]. Zhou G, Myers R, Li Y. Role of AMP-activated protein kinase in mechanism of metformin action. *J Clin Invest* 2001; 108: 1167-74
- [24]. Kanazawa I, Yamaguchi T, Yano S, Yamauchi M, Yamamoto M, Sugimoto T. Adiponectin and AMP kinase activator stimulate proliferation, differentiation, and mineralization of osteoblastic MC3T3-E1 cells. *BMC Cell Biol* 2007; 8: 51
- [25]. Gao Y, Li Y, Xue J, Jia Y, Hu J. Effect of the anti-diabetic drug metformin on bone mass in ovariectomized rats. *Eur J Pharmacol*. 2010;635(1):231-36
- [26]. Gyorfı, A., Fazekas, A., Suba, Z., Ender, F. & Rosivall, L. Neurogenic component in ligature-induced periodontitis in the rat. *J Clin Periodontol* 1994;21, 601-5
- [27]. Takemura Y, Osuga Y, Yoshino O. Metformin suppresses interleukin (IL)-1 induced IL-8 production, aromatase activation, and proliferation of endometriotic stromal cells. *J Clin Endocrinol Metab* 2007; 92:3213-8
- [28]. Kang W, Wang T, Hu Z, Liu F, Sun Y, Ge S Metformin Inhibits Porphyromonas gingivalis Lipopolysaccharide-Influenced Inflammatory Response in Human Gingival Fibroblasts via Regulating Activating Transcription Factor-3 Expression. *J Periodontol*. 2017 ;88(10):e169-e178
- [29]. Lu H, Kraut D, Gerstenfeld LC. Diabetes interferes with the bone formation by affecting the expression of transcription factors that regulate osteoblast differentiation. *Endocrinology* 2003; 144(1): 346-52

*Effect of metformin on alveolar bone loss in type 2 diabetic rat model with experimental periodontitis*

- [30]. Liu R, Bal HS, Desta T. Tumor necrosis factor- $\alpha$  mediates diabetes-enhanced apoptosis of matrix-producing cells and impairs diabetic healing. *Am J Pathol* 2006; 168(3): 757–764.
- [31]. Taylor JJ, Preshaw PM, Lalla E. A review of the evidence for pathogenic mechanisms that may link periodontitis and diabetes. *J Clin Periodontol* 2013; 40 (14): S113–S134
- [32]. Taylor GW, Burt BA, Becker MP. Glycemic control and alveolar bone loss progression in type 2 diabetes. *Ann Periodontol* 1998; 3(1): 30-39
- [33]. Duarte PM, deOliveira MC, Tambeli C H. Overexpression of interleukin-1  $\alpha$  and interleukin-6 may play an important role in periodontal breakdown in type 2 diabetic patients. *J Periodont Res* 2007; 42(4): 377–381.
- [34]. Silva, J. A., Ferrucci, D. L., Peroni, L. A., Abrahao, P. G., Salamene, A. F., RossaJunior, C., Carvalho, H. F. & Stach-Machado, D. R. Sequential IL-23 and IL17 and increased MMP 8 and MMP 14 expression characterize the progression of an experimental model of periodontal disease in type 1 diabetes. *J Cell Physio* 2012; 227:2441-50
- [35]. Mai QG, Zhang ZM, Xu S. Metformin stimulates osteoprotegerin and reduces RANKL expression in osteoblasts and ovariectomized rats. *J Cell Biochem* 2011; 112:2902-9

Dr Neethu Mercy James, et. al. “Effect of Metformin on Alveolar Bone Loss in Type 2 Diabetic Rat Model with Experimental Periodontitis.” *IOSR Journal of Dental and Medical Sciences (IOSR-JDMS)*, 19(5), 2020, pp. 58-67.