

## Changes in RNFL Thickness Using OCT in Primary Open Angle Glaucoma Before and After Trabeculectomy in Sub-Himalayan Region.

Dr. Yash Pal Sharma, Dr. Vinod Sharma, Prof. Dr. M. L. Pandey,  
Dr. Kalpana Sharma.

Correspondance: Dr. Yash Pal Sharma, Civil Hospital Rohru, Distt Shimla, H.P. 171214 India.

---

### **Abstract:**

**Purpose:** To study the Quadrant wise changes in RNFL thickness within 1 week pre-operative and 1week, 1 and 3 month post-operatively in a population of clinical patients with primary open angle glaucoma undergone trabeculectomy in the Sub-Himalayan region.

**Methods:** Patient sample size consisting of n=27 were accessed for primary open angle glaucoma. The sample population consists of adults with open anterior chamber angle and with demonstrative RNFL damage, with corresponding visual field loss. Average RNFL measurements were taken on Topcon 3D OCT-1 Maestro within a week before surgery and at 1 week, 1 and 3 month post operatively. Pre and post operative value were analyzed using Repeated Measure ANOVA with Bonferroni correction.

**Results:** It was observed that the Mean values for Inferior Quadrant thickness on an OCT machine in the pre-op period came to be equal to  $63.3 \pm 8.978$ . The Mean values of inferior quadrant observed at 1 week post operatively came to be  $69.48 \pm 9.002$  ( $p= 0.000$ ). The consecutive period of observation showed no significant improvement in inferior or other three quadrants.

**Conclusions:** The present study showed minor changes in the quadrant-wise thickness analysis post-Trabeculectomy. Although, for a short period of time minor fluctuations in Inferior Quadrant thickness showed significant improvement. Other Quadrants did not show any fluctuations in the thickness values observed.

**Keywords:** Optical Coherence Tomography; Trabeculectomy; Inferior Quadrant, Superior Quadrant, Nasal Quadrant, Temporal Quadrant, Intra Ocular Pressure, Primary Open Angle Glaucoma.

---

Date of Submission: 02-05-2020

Date of Acceptance: 16-05-2020

---

### **I. Introduction:**

The human eye and its adnexal structures develop from the neuro-ectoderm of the neural groove and the adjoining surface ectoderm, mesoderm and cells of neural crest origin. The eye is a complex anatomical structure consisting of delicate tissues. It is a sense organ which is designed to capture and focus light to form a retinal image which is translated into electrical signals and transmitted to the central nervous system via the optic nerve. The basic concept that impairment in aqueous humor outflow results in elevation of the IOP is a central tenet of glaucoma pathology and treatment. Glaucoma is described by the morphological changes in the intra-papillary and para-papillary regions of the optic nerve head and the retinal nerve fiber layer (RNFL) <sup>1,2</sup>. Although glaucoma frequently occurs without an elevation of intraocular pressure, the disease is nonetheless classified according to anterior-segment variations that can elevate intraocular pressure. The anterior segment of the eye has its own circulatory system, which nourishes the crystalline lens and cornea, both of which lack a blood supply. Aqueous humor, produced by the ciliary body, circulates throughout the anterior chamber and drains through the trabecular meshwork in the irido-corneal angle, which is the angle formed by the iris and cornea. Elevated intraocular pressure does not result from increased aqueous humor production but rather from reduced aqueous outflow <sup>3</sup>.

The Retinal Nerve Fibre Layer is formed by the expansion of the fibers of optic nerve; it is thickest near the porus opticus gradually diminishing towards the ora serrata <sup>4</sup>. In normal eyes the RNFL is most visible in the temporal inferior and temporal superior sectors and least visible in the nasal sectors. This has correlation with the histology of the RNFL which is thicker in inferior and superior peripapillary areas than the temporal and nasal. The NRR is wider and the lamina cribrosa pores and diameter of the retinal arterioles is larger in these areas. The visibility of RNFL decreases with age. To examine the RNFL dilate the pupil and see the fundus with a noncontact lens in red free illumination of the slit lamp. The normal pattern of the fiber bundles can be detected as bright striations in the retinal reflex. In fundus the RNFL is markedly better detectable in the temporal superior sector one can carefully observe the temporal inferior region to find a loss of RNFL. Various

studies demonstrate that OCT can measure Peripapillary RNFL thickness. Also observe the vessels as the retinal vessels are normally embedded in the retinal nerve fibers and when there is diffuse RNFL loss the vessels are covered only by the thin inner limiting membrane so are better visible. The RNFL defects could be localized or generalized depending on the stage of the disease and because localized defects are very rare in normal eyes they are highly specific for optic nerve damage. But localized defects are not pathognomic of glaucoma and can occur in other types of optic disc atrophies. In glaucoma, they are more common in normal tension glaucoma followed by POAG and then secondary open angle cases <sup>1</sup>.

Optical coherence tomography (OCT) is a diagnostic imaging technique that provides cross-sectional images of human retinal morphology in vivo. Huang and associate first invented OCT in 1991, the first SD-OCT became commercially available in 2006. Optical coherence tomography (OCT) is the optical analogue to ultrasonography and measures the echo time delay and magnitude of reflected or backscattered light using the principle of Michelson low-coherence interferometry. Cross-sectional images are obtained by measuring the backscattered light while scanning across multiple sites in a transverse fashion. Echoes from a single point on the retina represent an axial scan (A-scan), and optical cross-sections (B-scans) are obtained by directing the OCT beam in the transverse direction. The data obtained are displayed as false-colour or grey-scale images. The position of the reference mirror is altered in order to obtain reflected light from the retina at several different depths. Spectral domain OCT allows for unprecedented simultaneous ultrahigh speed and ultrahigh resolution ophthalmic imaging without a loss in image quality, and 2D images can be obtained in 1/29th of a second. Spectral domain OCT can image 14,600 to over 29,200 A-lines per second. Spectral domain OCT resolutions of about 2 µm can be achieved with the appropriate light source. Spectral domain OCT can create 3-dimensional (3D) images as well as videos of large areas of the posterior pole (16). Present machine that was used for study was Topcon 3D OCT-1 Maestro that is installed at the Department of Ophthalmology I. G. M. C Shimla.

Various study demonstrate that OCT measure RNFL as thinner in older person with decline of 2µm per decade. The human RNFL losses approximately 5000 axons per year from birth to death. Approximately 2500 per year before 50 years and approximately 7500 per year after 50 years of age. It is not surprising that RNFL thickness decrease with age.

The OCT can also measure optic disc topography. Although there are inherent limitations in the measurement algorithm, the discriminating ability of some parameters for glaucoma has been shown to be nearly as good as the RNFL thickness measurements. OCT may be more advantageous over HRT in having a higher axial resolution and automated outlining of optic disc margin, thus eliminating operator variability. One added advantage of the OCT ONH analysis is that, one can get a cross-sectional view of the ONH rather than the 'enface' view provided by the HRT. If cup reversal following IOP reduction is due to the forward movement of the lamina cribrosa, then OCT may be able to demonstrate this phenomenon better. <sup>5</sup>

Trabeculectomy is a surgical operation which lowers the intraocular pressure (IOP) inside the eye in patients with glaucoma. This is achieved by making a small hole in the eye wall (sclera), covered by a thin trap-door in the sclera. The fluid inside the eye known as aqueous humour, drains through the trap-door to a small reservoir or bleb just under the eye surface, hidden by the eyelid. The trap-door is sutured (stitched) in a way that prevents aqueous humour from draining too quickly. By draining aqueous humour the Trabeculectomy operation reduces the pressure on the optic nerve and prevents or slows further damage and further loss of vision in glaucoma. Control of the eye pressure with a Trabeculectomy will not restore vision already lost from glaucoma <sup>6</sup>.

The rationale for the current study was, to prospectively study RNFL (by using Topcon 3D OCT-1 Maestro) before and after Trabeculectomy in Primary Open –Angle Glaucoma, in patients attending Department of Ophthalmology, I. G. M. C Shimla. The stimulus for this work was only ophthalmological for the exploration of RNFL by using the maximum means at our disposal.

## **II. Materials And Methods**

The present study was conducted in the Department of Ophthalmology, Indira Gandhi Medical College, Shimla. The number of patients undergoing trabeculectomy were n= 27. Data was collected from one eye only, if both eyes required surgery then the one with the greater intraocular pressure (IOP) and glaucoma progression was taken in study. The criteria for inclusion were patients aged 40-80 years with diagnosis of POAG. The patients with previous glaucoma surgery, cataract surgery, retinal, or neurological disease affecting VF were excluded from the study. While the patient was under maximally tolerant medication, the indication for surgery was optic nerve head parameter and RNFL which was high risk of glaucomatous progression as well as worsening of the VF. After trabeculectomy, the OCT scans of the patients were repeated at 1-week, 1-month, and 3-month postoperatively. The stimulus for this work was only ophthalmological for the exploration of RNFL and IOP by using the maximum means at our disposal. Informed consent was obtained from all recruited individuals. Each subject underwent extensive examination including Best Corrective Visual Acuity (BCVA) by using Snellen's chart. Slit lamp bio-microscopy was done to assess the ocular adnexa and the anterior segment

(AC Depth using Van Herrick's Grading) of eye using a slit lamp bio-microscope (Haag Striet-900). Intra ocular pressure is measured by using a Goldman's applanation tonometer. An open anterior angle chamber using Gonioscopy by Shaffer's system using Goldman Single Mirror Gonioscopic Lens. Optic Disc Examination- for glaucomatous changes was performed in dilated pupil with slit lamp (Haag Striet-900) using 90D lens (Magnification= 0.76). Fundus examination was done by using the direct and indirect ophthalmoscope after pupillary dilatation using 5% phenylephrine and 1% tropicamide drops instilled once or twice as required. Perimetry for visual field analysis using octopus 900 automated perimetry machine. Optical Coherence Tomography (3D OCT-1MAESTRO) was used for studying RNFL thickness. The RNFL map represents a 6 x 6 mm cube of A-scan data centered over the optic nerve in which a 3.4 mm diameter circle of RNFL data is extracted to create what is referred to as the ISNT map (inferior, superior, nasal and temporal). Each resulting image will consist of RNFL thickness measurements along a 360-degree circle around the optic disc. It is displayed as a false color scale with the thickness values referenced to a normative database. All OCT scans were acquired by an experienced operator. OCT scans were obtained after pupillary dilatation using 5% phenylephrine and 1% tropicamide drops instilled once or twice as required. All baseline scans was acquired within 1 weeks of the planned surgery. The parameters studied were RNFL Thickness in each quadrant.

### III. Surgical Technique:

No pupillary dilatation and a bridle suture/corneal Traction Suture were inserted (commonly superior cornea). Site of Trabeculectomy was supero-nasal or supero-temporal. A fornix based flap of conjunctiva and Tenon capsule was fashioned superiorly. Epi-scleral tissue was cleared and major vessels cauterized. An incision was made through about 50% of sclera thickness to create a trap-door lamellar sclera flap. This flap was triangular according to preference. The superficial triangular flap was dissected forwards until clear cornea is reached. A paracentesis was made in temporal peripheral clear cornea and air injected. The anterior chamber was entered along most of the width of the trapdoor base. Sclerotomy incision was 1mm clear of either side of sclera flap. After the initial linear incision into anterior chamber sclerotomy is fashioned with sclera punch. A fistula 0.5mm to 1mm in height and 1.5 to 2mm in width created. Peripheral iridectomy was created. Superficial scleral flap was sutured to its underlying bed tightly with Apex sutures, using nylon 10-0 suture. Balanced salt solution was injected through the paracentesis to deepen the anterior chamber and test the patency of the fistula. Conjunctiva/Tenon capsule flap was sutured. Irrigation through the paracentesis was repeated to produce a bleb. Steroid and antibiotic was injected under the inferior conjunctiva. Postoperative analysis of IOP and RNFL were done at 1 week, 1 and 3 month respectively. All data was collected on data forms.

### IV. Statistical Analysis:

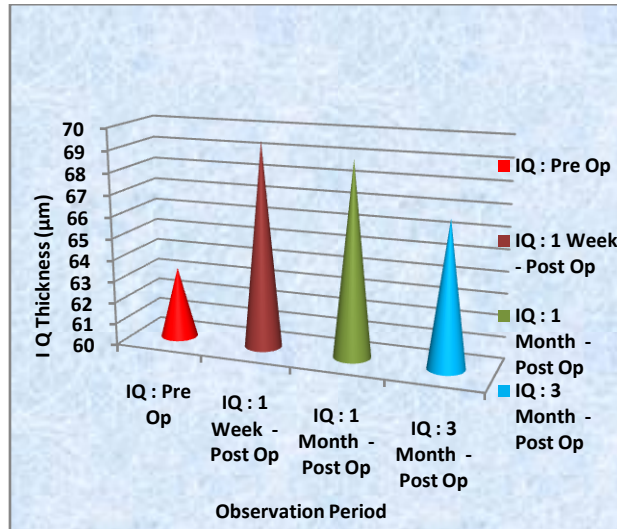
Data collected during the study was tabulated and analyzed by using Repeated Measure ANOVA with Bonferroni correction. The probability value (p-value) was calculated and a value of <0.05 was implied to be statistically significant.

### V. Result:

The result of the current study was found as following:

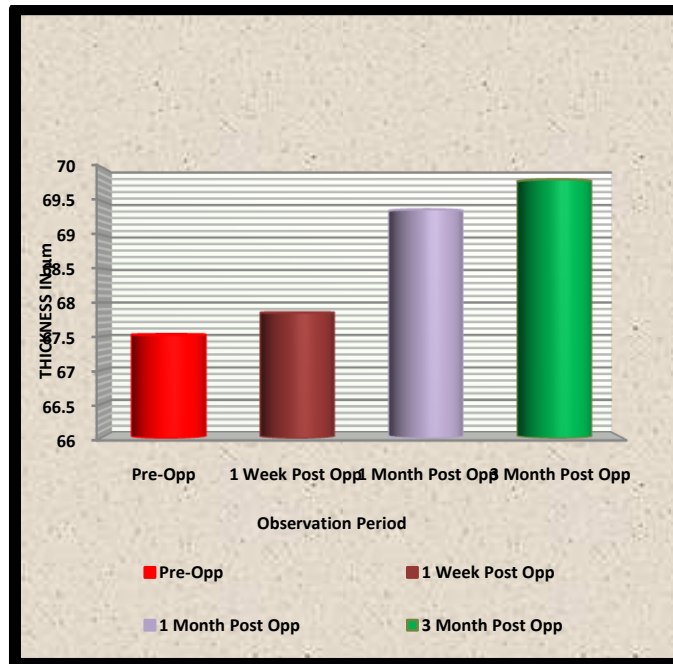
The readings for Inferior Quadrant was observed on an OCT machine in this the pre-op Mean value came to be equal to  $63.3 \pm 8.978$ . The Mean values of inferior quadrant observed at 1 week post operatively came to be  $69.48 \pm 9.002$  ( $p= 0.000$ ). The consecutive period of observation was at 1 month in which the Mean value of Inferior Quadrant came to be  $68.93 \pm 11.19$  ( $p = 0.096$ ). The final readings of the Inferior Quadrant were observed to be equal to  $66.67 \pm 9.919$  ( $p=0.144$ ).

Inferior Quadrant	Mean	Std. Deviation	p-value
IQ : Pre Op	63.3	±8.978	
IQ : 1 Week - Post Op	69.48	±9.002	0.000
IQ : 1 Month - Post Op	68.93	±11.19	0.096
IQ : 3 Month - Post Op	66.67	±9.919	0.144



Mean values of Superior quadrant. In the pre-operative period the Mean value for study group came to be equal to  $67.52 \pm 12.801$ . The Superior Quadrant was then observed post operatively at 1 week and the Mean values came to be  $67.85 \pm 13.640$  ( $p= 1.000$ ). At 1 month post operatively the Mean value came to be  $69.37 \pm 12.122$  ( $p =0.880$ ). At 3 month Post operatively the Mean value were observed to be  $69.81 \pm 13.270$  ( $p=1.000$ ).

Superior Quadrant	Mean	Standard Deviation	P-Value
Pre-Operative	67.52	$\pm 12.801$	
Post-Op 1 Week	67.85	$\pm 13.640$	1.000
Post-Op 1 Month	69.37	$\pm 12.122$	0.880
Post-Op 3 Month	69.81	$\pm 13.270$	1.000



The mean and standard deviation of the Nasal quadrant at pre-operative period was equal to  $62.63 \pm 8.317$ . 1 Week post-operatively the Mean value was observed to be equal to  $63.22 \pm 9.112$  ( $p=1.000$ ). The Nasal

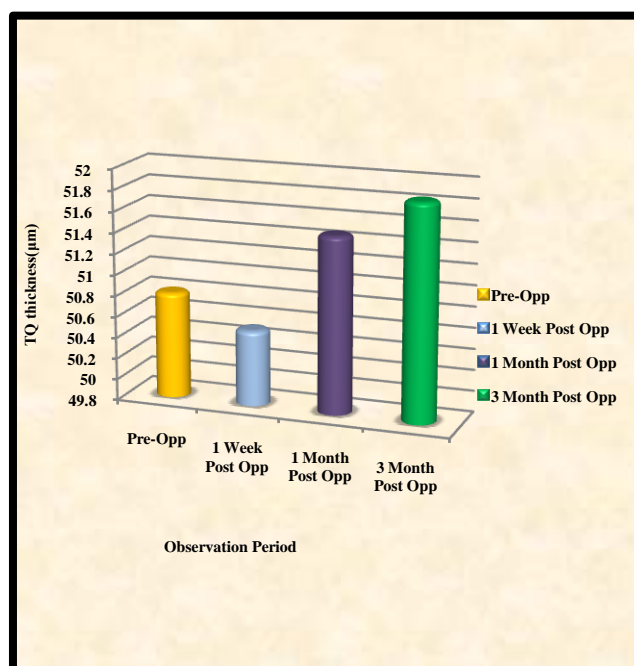
Quadrant then was observed at 1 month post-operatively the Mean values were  $64.22 \pm 9.316$  ( $p = 1.000$ ). The follow-up was then done at 3<sup>rd</sup> month; the Mean values came to be equal to  $65.33 \pm 8.256$  ( $p = 0.846$ ).

Nasal Quadrant	Mean	Standard Deviation	p-Value
Pre-Operative	62.63	$\pm 8.317$	
Post-Op 1 Week	63.22	$\pm 9.112$	1.000
Post-Op 1 Month	64.22	$\pm 9.316$	1.000
Post-Op 3 Month	65.33	$\pm 8.256$	0.846

The Nasal quadrant Mean value at pre-operative period was equal to  $62.63 \pm 8.317$ . 1 Week post-operatively the Mean value was observed to be equal to  $63.22 \pm 9.112$  ( $p = 1.000$ ). The Nasal Quadrant then was observed at 1 month post-operatively the Mean values were  $64.22 \pm 9.316$  ( $p = 1.000$ ). The follow-up was then done at 3<sup>rd</sup> month; the Mean values came to be equal to  $65.33 \pm 8.256$  ( $p = 0.846$ ).

TEMPORAL QUADRANT	Mean	Standard Deviation	p-Value
Pre-Operative	50.81	$\pm 9.915$	
Post-Op 1 Week	50.52	$\pm 9.345$	1.000
Post-Op 1 Month	51.48	$\pm 9.267$	1.000
Post-Op 3 Month	51.85	$\pm 10.117$	1.000

The temporal quadrant Mean value at pre-operative period was equal to  $50.81 \pm 9.915$ . 1 Week post-operatively the Mean value were observed to be equal to  $50.52 \pm 9.345$  ( $p = 1.000$ ). The Temporal Quadrant then was observed at 1 month post-operatively the Mean values were  $51.48 \pm 9.267$  ( $p = 1.000$ ). The follow-up was then done at 3<sup>rd</sup> month; the Mean values came to be equal to  $51.85 \pm 10.117$  ( $p = 1.000$ ).



### VI. Discussion:

In the present study all the four quadrants were analyzed, differences between normal and Glaucomatous eye has been well documented. The changes in four quadrants Inferior, Superior, Nasal and Temporal were analyzed. Inferior Quadrant of RNFL pre-op Mean value was  $63.3 \pm 8.978$ , 1 week post

operatively was  $69.48 \pm 9.002$  ( $p= 0.000$ ), 1 month the Mean value of Inferior Quadrant was  $68.93 \pm 11.19$  ( $p = 0.096$ ) and at 3<sup>rd</sup> month reading of Inferior Quadrant was  $66.67 \pm 9.919$  ( $p=0.144$ ). Hence Inferior quadrant thickness showed significant improvement in the first week post operatively, but were tending to pre-operative values in the 1 month and 3<sup>rd</sup> month of follow-up. Similar results were observed by N Raghu *et al* (2012) in their study the RNFL parameters, average and inferior and temporal quadrant RNFL thickness measurements increased significantly at 1 week after surgery, but reverted to baseline levels at the subsequent follow-up visits. Aydin *et al* (2003) in his study found a significant increase in the peripapillary NFL thickness, as determined by OCT, after glaucoma filtration surgery.

In our study the Mean value of Superior Quadrant pre-operatively was  $67.52 \pm 12.801$ , post operatively at 1 week the Mean values was  $67.85 \pm 13.640$  ( $p= 1.000$ ), 1 month the Mean value was  $69.37 \pm 12.122$  ( $p = 0.880$ ) and at 3 month the Mean value was  $69.81 \pm 13.270$  ( $p=1.000$ ). There was only numerical improvement in RNFL superior quadrant thickness but the thickness was not statistically significant.

In our study the thickness of Nasal quadrant Mean value at pre-operative period was equal to  $62.63 \pm 8.317$  and post-operatively at 1 Week the Mean value was  $63.22 \pm 9.112$  ( $p=1.000$ ), at 1 month the Mean values was  $64.22 \pm 9.316$  ( $p = 1.000$ ) and at 3<sup>rd</sup> month the Mean values was  $65.33 \pm 8.256$  ( $p = 0.846$ ). The results showed improvement of (RNFL) Nasal Quadrant thickness at 3<sup>rd</sup> month as compared to pre-operative value. Similar study done by Sarkar, *et al.* (2014) shows that the RNFL thickness changes among the patients of pre-operative and post-operative glaucoma ( $52.56 \pm 17.40$  and  $58.48 \pm 20.20$ , respectively) cases were statistically significant. There was an increased RNFL thickness (superior quadrant:  $4.45 \pm 7.61 \mu\text{m}$ , nasal quadrant  $6.57 \pm 11.19 \mu\text{m}$ , inferior quadrant  $7.57 \pm 12.16 \mu\text{m}$ , and temporal quadrant  $3.27 \pm 12.32 \mu\text{m}$ ) in all quadrants, but more changes were found in nasal quadrant. The improvement was confined to the nasal quadrant and the adjacent RNFL thickness because this area might be least affected by the disease.

Temporal quadrant thickness of the present study shows the Mean value at pre-operative period as  $50.81 \pm 9.915$  and post operatively at 1 Week the Mean value was  $50.52 \pm 9.345$  ( $p=1.000$ ), at 1 month post-operatively the Mean values was  $51.48 \pm 9.267$  ( $p=1.000$ ). The 3<sup>rd</sup> month Mean values came to be equal to  $51.85 \pm 10.117$  ( $p=1.000$ ). Though no statistical significance was shown yet numerical improvement in thickness was observed. Aydin *et al* (2003) studied that NFL thickening was significant for the overall measurement and in all quadrants except the inferior quadrant. Segmental analysis should be performed cautiously because the reproducibility decreased for quadrant measurements in glaucoma subjects, especially in the temporal and nasal quadrants. He found a significant increase in the NFL thickness was found for the overall measurement and in all quadrants except the inferior quadrant<sup>8</sup>. Figus *et al* (2011) in his study observes that Mean RNFL thickness showed statistically significant changes and said thickness increased by 0.05mm out of  $0.19 \pm 0.034$ mm baseline at 3 months ( $P/40.05$ ), and 0.03mm at 6 months ( $P/40.05$ ). The mean value of RNFL in normal elderly patients is  $0.23 \pm 0.07$ mm; On the basis of his results he raised the hypothesis that the increase of RNFL thickness may reflect the recovery of the compressed RNFL, which would regain its original shape thanks to IOP reduction. As compression on the axons is relieved by IOP reduction, the axons may recover their normal shape and size, with resultant increase in RNFL thickness.

Other studies that showed similar results were Bowd *et al*, Chang *et al*, Figus *et al*, Hong Lee *et al*, Leung *et al*, Lin *et al*, Soliman *et al*, Xu *et al*, Yung *et al*.

## VII. Conclusion:

The present study showed minor changes in the quadrant-wise thickness analysis post-Trabeculectomy. Although, for a short period of time Inferior Quadrant showed significant improvement during first week of post-surgical observational period. Other Quadrants did not show any fluctuations in the values observed. The values post operative third month reverted back to pre-operative values. Long-term studies are needed to determine the usefulness of these findings as outcome in the management of glaucoma. The major constrain in this kind of study is small sample size and short observational period. We need to have long follow-up period to attain the authentication of the final results in management and improvement of Primary Open Angle Glaucoma post- Trabeculectomy.

**FINANCIAL SUPPORT AND SPONSORSHIP** The work was an original research work and was not a sponsored or financed in part or whole.

**CONFLICTS OF INTEREST:** There are no conflicts of interest.

## References:

- [1]. Monica Gandhi, Suneeta Dubey. Evaluation of the Optic Nerve Head in Glaucoma. *Journal of Current Glaucoma Practice*, September-December 2013; 7(3):106-114 107.
- [2]. Manik Goel, Renata G Picciani, Richard K Lee, Sanjoy K Bhattacharya. Aqueous Humor Dynamics: A Review. *Open Ophthalmol J.* 2010; 4: 52-59

- [3]. Young H. Kwon, John H. Fingert, Markus H. Kuehn, Wallace L.M. Alward. Primary Open-Angle Glaucoma. *N Engl J Med.* 2009 March 12; 360(11): 1113–1124.
- [4]. R. Rand Allingham, Shields Textbook of Glaucoma, Sixth Edition. 2012.
- [5]. N Raghu, SS Pandav, S Kaushik, P Ichhpujani and A Gupta. Effect of Trabeculectomy on RNFL thickness and optic disc parameters using optical coherence tomography. *Eye* (2012) 26, 1131–1137
- [6]. NHMRC Guidelines for the Screening, Prognosis, Diagnosis, Management and Prevention of Glaucoma 2010: 39-45, 65-88.
- [7]. Ali Aydin, MD, Gadi Wollstein, MD, Lori Lyn Price, MS, James G. Fujimoto, PhD, and Joel S. Schuman, MD. Optical Coherence Tomography Assessment of Retinal Nerve Fiber Layer Thickness Changes after Glaucoma Surgery. *Ophthalmology.* 2003 August ; 110(8): 1506–1511.
- [8]. Kumaresh Chandra Sarkar, Palash Das, Ranabir Pal, Chattaranjan Shaw. Optical coherence tomographic assessment of retinal nerve fiber layer thickness changes before and after glaucoma filtration surgery. *Oman Journal of Ophthalmology* 2014; 7: 3-8
- [9]. M Figus, S Lazzeri, M Nardi, MP Bartolomei, A Ferreras and P Fogagnolo Short-term changes in the optic nerve head and visual field after trabeculectomy, *Eye (2011)* 25, 1057–1063.
- [10]. 10. Christopher Bowd, Robert N. Weinreb, Julia M. William, Linda M. Zangwill. The Retinal Nerve Fiber Layer Thickness in Ocular Hypertensive, Normal, and Glaucomatous Eyes with Optical Coherence Tomography, *Arch Ophthalmol.* 2000; 118 (1), 22-26.
- [11]. Peter T. Chang, Navneet Sekhon, Donald L. Budenz, William J. Feuer, Paul W. Park, Douglas R. Anderson. Effect of Lowering Intraocular Pressure on Optical Coherence Tomography Measurement of Peripapillary Retinal Nerve Fiber Layer Thickness, *Ophthalmology*, December 2007, Volume 114 (12), 2252-2258.
- [12]. Vincent Wing-hong Lee, Kwok Hei Mok. Retinal Nerve Fiber Layer Measurement by Nerve Fiber Analyzer in Normal Subjects and Patients with Glaucoma, *Ophthalmology.* 1999 (May), Volume 106: 5: 1006-1008.
- [13]. Christopher Kai-Shun Leung, Marco Yu, Robert N. Weinreb, Gilda Lai, Guihua Xu, Dennis Shun-Chiu Lam. Retinal Nerve Fiber Layer Imaging with Spectral-domain Optical Coherence Tomography: Patterns of Retinal Nerve Fiber Layer Progression, *Ophthalmology* 2012; 119:1858–1866.
- [14]. Shan C. Lin, Kuldev Singh, Henry D. Jampel, Elizabeth A. Hodapp, Scott D. Smith, Brian A. Francis, David K. Dueker, Robert D. Fechtner, John S. Samples, Joel S. Schuman, and Don S. Minckler. Optic Nerve Head and Retinal Nerve Fiber Layer Analysis, *Ophthalmology.* 2007 (October); 114(10): 1937–1949.
- [15]. Mohamed A. E. Soliman, Thomas J.T.P. Van Den Berg, Al-Araby A. Ismaeil, Leo A.M.S. De Jong, and Marc D. De Smet. Retinal Nerve Fiber Layer Analysis: Relationship between Optical Coherence Tomography and Red-free Photography, *Am J Ophthalmol* 2002; 133: 187–195.
- [16]. Guihua Xu, Robert N. Weinreb, Christopher K.S. Leung. Retinal Nerve Fiber Layer Progression in Glaucoma a Comparison between Retinal Nerve Fiber Layer Thickness and Retardance, *Ophthalmology.* 2013; 1-8.
- [17]. Edward Stephen Yung, Eileen Linda Chang, Marlene R. Moster. The Use of Optic Disc and Retinal Nerve Fiber Imaging in Detecting Structural Damage Before the Onset of Functional Loss, *Advances in Ophthalmology and Optometry* 2017 (2) 243–260.

Dr. Yash Pal Sharma, et. al. "Changes in RNFL Thickness Using OCT in Primary Open Angle Glaucoma Before and After Trabeculectomy in Sub-Himalayan Region." *IOSR Journal of Dental and Medical Sciences (IOSR-JDMS)*, 19(5), 2020, pp. 10-16.