

## A Study on Histopathological Spectrum of Lesions in Surgically Resected Specimens of Fallopian Tube: A Case Series.

Dr. Nishat Ahmad<sup>1</sup>, Dr. M. A. Ansari<sup>2</sup>, Dr. A. K. Sinha<sup>3</sup>

<sup>1</sup>Junior Resident, Department of Pathology, Rajendra Institute of Medical Sciences, Ranchi

<sup>2</sup>Associate Professor, Department of Pathology, Rajendra Institute of Medical Sciences, Ranchi

<sup>3</sup>Professor, Department of Pathology, Rajendra Institute of Medical Sciences, Ranchi

### Abstract

**BACKGROUND:** Although Fallopian tubes are common surgical specimen in the pathology laboratory, data to describe the frequency of various histopathological findings are lacking.

**MATERIALS AND METHODS:** A total of 439 cases were included in this study, consisting of specimens of fallopian tubes of all age groups obtained by salpingectomy, tubal ligation, salpingo-oophorectomy or along with hysterectomy. The specimens were processed by routine method and histopathological features were studied on Haematoxylin and Eosin stained sections.

**RESULTS:** Out of total 439 fallopian tube specimens, 269 cases (61.28%) were normal, whereas 170 cases (38.72%) fallopian tubes were abnormal. Of the abnormal fallopian tube specimens, the most common histopathological finding observed were tubal ectopic seen in 77/170 (17.54%) of cases, most commonly in the age group of < 30 years. Chronic salpingitis accounting for 55 cases (12.53%), paratubal cysts 22 cases (5.01%), hydrosalpinx 3 cases (0.68%), haematosalpinx 2 (0.46%), pyosalpinx 1 case (0.23%), fimbrial cysts 5 (1.14%), Walthard cell rest in one case (0.23%), granulomatous salpingitis and endometriosis 1 case each (0.23%). No primary neoplasm of the fallopian tube was observed, however, there were two cases of secondary involvement of the tube by serous adenocarcinoma of ovary.

**Key Words:** Fallopian tubes, Salpingectomy, Tubal ligation, Salpingo-oophorectomy, Hysterectomy

Date of Submission: 04-05-2020

Date of Acceptance: 18-05-2020

### I. Introduction

The fallopian tubes are complex structures which connects ovary to uterine cavity.<sup>(1)</sup> A variety of interactions occurs in the fallopian tubes that results in a normal implanted gestation.<sup>(1)</sup> Fallopian tube specimen is received after salpingectomy, tubal ligation or as part of hysterectomy or oophorectomy. It is one of the most common surgical specimens in pathology laboratory to be examined.

Very few studies, documenting histological changes in fallopian tube removed for all above cited reasons, have been done, though fallopian tube is affected by a wide array of diseases.

As this is a common specimen in the general surgical pathology laboratory, knowledge of the frequency of these variations in a histopathology practice can be valuable to the pathologist who identifies a potentially unusual histological finding.<sup>(2)</sup> Thus the data to describe the frequency of various histological findings in fallopian tube pathology is lacking as revealed by various literature search.<sup>(3)</sup> The aim and objective of this study is to describe the various histomorphological findings of fallopian tubes and to study the incidence of various pathological lesions of fallopian tubes.

### II. Aims And Objectives

1. To study the various histopathological patterns in surgically-resected specimens of fallopian tube
2. To study the histological spectrum of lesions of the fallopian tube and the age distributions of the patients.

### III. Materials And Methods

The data was collected retrospectively in the Department of Pathology, Rajendra Institute of Medical Sciences, Ranchi between periods of January 2019 to December 2019 and includes analysis of surgically removed fallopian tubes during tubal ligation, salpingectomy or along with total abdominal hysterectomy with unilateral or bilateral salpingo-oophorectomy done on a sample size of 439 cases. The clinical notes of all cases were reviewed for the patient's age, clinical history and diagnosis. The resected samples received were subjected to gross examination noting their appearance and any obvious gross pathology. Representative gross sections were taken from each tube, processed routinely and paraffin embedded tissue blocks were made. 4-5  $\mu$  size sections were cut; slides were made and then stained with haematoxylin and eosin. The histopathology

slides were then examined and final diagnosis was made. Findings of this study were tabulated and statistically analysed.

#### IV. Results

The present study was based on a sample size of 439 cases. All age groups (youngest 10 year old and oldest being 80 year old female) were analysed in the study. Fallopian tube pathologies were diagnosed by detailed histopathological examination of tissue sections. The study describes the broad spectrum of lesions in fallopian tube and their incidence, where majority of the lesions comprised predominantly of inflammatory lesions. Grossly, majority of the fallopian tubes were unremarkable. The average length of the tube when received was 4 cm (3-6 cm). In tubectomy specimens, average length was 0.75 cm (0.5-1.5 cm).

Si. No.	Age(Years)	Frequency	Percentage
	<30	134	30.52%
	31-40	128	29.16%
	41-50	142	32.35%
	51-60	25	5.69%
	>60	10	2.28%
	<b>Total</b>	<b>439</b>	<b>100%</b>

**Table 1: Age Distribution of Patients with Pathological Lesions**

The salient observations noted in the study were as follows. Out of 439 fallopian tube cases, 269 cases were normal (61.28%). Abnormal cases were 170 (38.72%). The most common lesion was tubal ectopic pregnancy 77(17.54%) with chronic nonspecific salpingitis contributing 55 (12.53%) being the second most common, next is paratubal cyst accounting for 22 (5.01%), fimbrial cyst 5 (1.14%), hydrosalpinx 3 cases (0.68%), followed by cases of haemosalpinx 2 (0.46%), pyosalpinx 1 (0.23%), Walthard cell nest 1 (0.23%), endometriosis 1 (0.23%), granulomatous salpingitis 1 (0.23%) and metastatic deposits 2 (0.46%).

Si. No.	Histopathological Diagnosis	Frequency	Percentage
1.	Chronic salpingitis	55	12.53%
2.	Tubal ectopic	77	17.54%
3.	Hydrosalpinx	3	0.68%
4.	Haemosalpinx	2	0.46%
5.	Pyosalpinx	1	0.23%
6.	Fimbrial cyst	5	1.14%
7.	Paratubal cyst	22	5.01%
8.	Walthard cell nests	1	0.23%
9.	Endometriosis	1	0.23%
10.	Granulomatous salpingitis	1	0.23%
11.	Metastatic deposition	2	0.46%
	<b>Total Pathological</b>	<b>170</b>	<b>38.72%</b>
	<b>No significant Pathology</b>	<b>269</b>	<b>61.28%</b>

**Table 2: Histopathological Diagnosis of Patients (Fallopian tubes)**

As fallopian tubes are subjected to a variety of inflammatory and neoplastic lesions, knowledge about the spectrum of lesions in the fallopian tube is the principle aim and objective of this study.

Ectopic tubal gestation accounted for maximum number of cases 77 (17.54%) and was the most frequent tubal pathology to be encountered in our study. All these cases were received as salpingectomy specimens and majority of the patients were below 30 years of age. Majority of the cases were diagnosed as ectopic pregnancy clinically and radiologically and presented with ruptured fallopian tube

According to a study conducted by Brown and Algren, about 15% of ectopic pregnancies occur after the first episode and 50% occur after the third episode of salpingitis. <sup>(6, 7)</sup>

Chorionic villi or trophoblastic tissue identified microscopically either in the wall of the tube or in the accompanying blood clot confirms tubal ectopic pregnancy [Figure 2]. In as many as 77 cases, a presumptive diagnosis of tubal pregnancy was made on the basis of the presence of decidual tissue in the wall of the tube with accompanying haemorrhage with suggestive clinical history and radiological finding. Tubal congestion, hemorrhage and oedema were evident in all the cases

Salpingitis is the pathologic correlate of the clinical entity Pelvic Inflammatory Disease (PID), which is the generic term used for inflammatory processes of this region in which fallopian tube is the epicentre and presumably the source of the inflammation. <sup>(3, 4, 5)</sup>

Salpingitis is seen commonly in the reproductive age group and is due to ascending infection or via haematogenous route. Salpingitis or inflammation of the fallopian tube was the next common histological pattern of tubal pathology to be seen in the present study accounting for 55 cases (12.53%), termed as chronic

nonspecific salpingitis. Majority of the cases (52) belonged to <40 years age group, i.e. the period when females are likely to be sexually active.

Si No.	Pathological Findings	Total No. of Cases	Age Group (Yrs)				
			<30	31-40	41-50	51-60	>61
	Tubal ectopic	77	54	20		3	
	Chronic salpingitis	55	12	40	3		
	Hydrosalpinx	3	1		1	1	
	Haemosalpinx	2	1	1			
	Pyosalpinx	1		1			
	Fimbrial cyst	5	2	2	1		
	Paratubal cyst	22		8	12	2	
	Walthard cell nests	1	1				
	Endometriosis	1	1				
	Granulomatous salpingitis	1			1		
	Metastatic deposition	2			1		1
	<b>Total Cases (No.)</b>	<b>170</b>	<b>72</b>	<b>72</b>	<b>19</b>	<b>6</b>	<b>1</b>
	<b>Total Abnormal (%)</b>	<b>100%</b>	<b>42.35%</b>	<b>42.35%</b>	<b>11.18%</b>	<b>3.53%</b>	<b>0.59%</b>

**Table 3: Age wise distribution of Histopathological Diagnosis of Tubal Lesions**

Microscopically it is characterised by a variable morphology ranging from blunted plicae with a dense lymphocytic infiltrate in the wall to marked fibrotic lesions showing complete flattening of the epithelial lining and luminal narrowing

One case (0.23%) presented as granulomatous (tuberculous) salpingitis showing the presence of caseating epithelioid granuloma in the wall of the tube, which had the clinical history of primary infertility.

One case was of pyosalpinx (0.23%) wherein the fallopian tube was distended and filled with pus and microscopically showed swelling and edema in plicae of tube with infiltration of acute and chronic inflammatory cells.

Hydrosalpinx accounted for 3 cases (0.68%) showing distended, elongated and tortuous tubes often located in the ampulla with thin wall and clear fluid. Microscopically, the mucosal folds are atrophied and lined by low cuboidal to columnar epithelium devoid of cilia. Haemosalpinx was found in only 2 cases (0.46%).

22 cases (5.01%) of paratubal cysts were observed. They were seen as small round cysts with papery thin walls and diameters ranging from 1 cm to 8 cm attached to the tube and mostly filled with clear watery fluid. Most were discovered incidentally during surgery. Microscopically, the cysts were lined by flattened to cuboidal epithelium surrounded by thin fibrous walls. [Figure 1]

One case of Walthard cell rests (0.23%) is being reported in our study. Microscopically, they are benign epithelial cell clusters seen commonly in the perifallopian tube tissue, but also seen in the mesovarium, mesosalpinx and ovarian hilus, appearing as white to yellowish nodules or cysts measuring less than 2 mm.

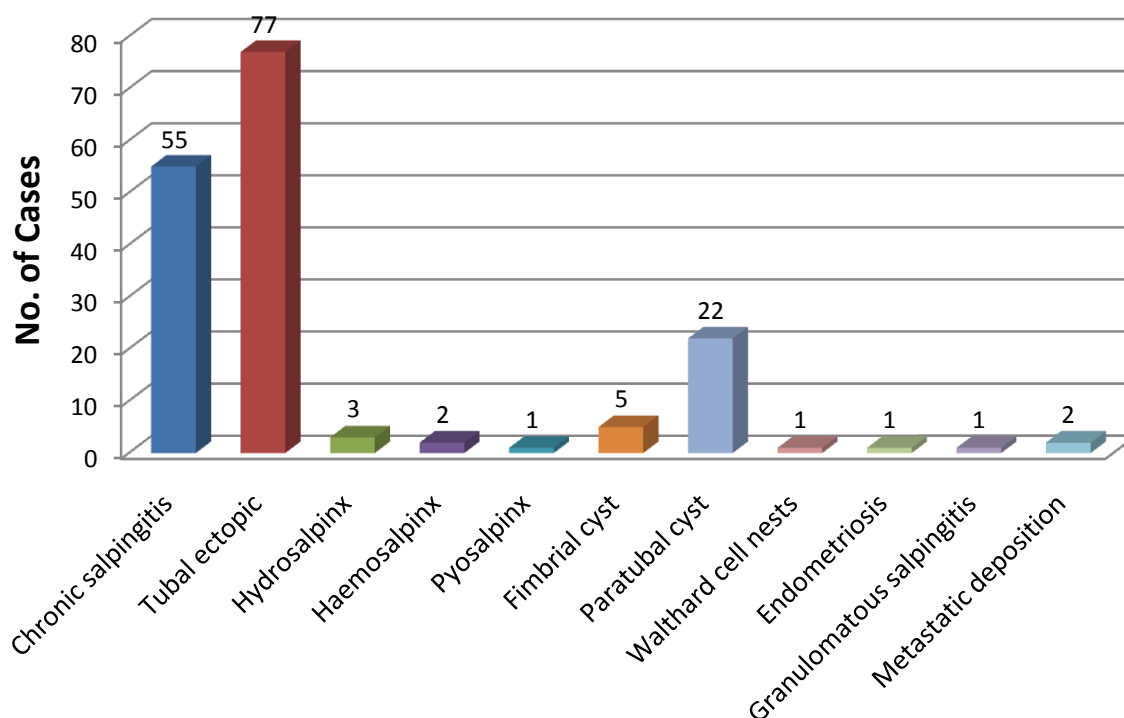
It is a common incidental microscopic finding and appears as well circumscribed solid nests of cuboidal to transitional cells with coffee bean nuclei. Cystic Walthard rests show eosinophilia secretion within the lumina.

Many studies have shown Brenner tumour to be associated with Walthard cell nests in 40% of the cases. In our study, no associated Brenner tumour was noticed. <sup>(8)</sup>

Tubal endometriosis [Figure 3] was seen as presence of endometrial glands with stroma in the wall. One case (0.23%) was observed in a 28 year female who presented as a left iliac fossa mass.

There was no case of a primary benign or malignant neoplasm of the fallopian tube in our study. Nonetheless, two cases (0.46%) showed secondary involvement of the fallopian tubes by tumours. The cases were that of a serosal metastasis from serous papillary adenocarcinoma of right ovary in a 50-year-old female and serous cystadenocarcinoma of right ovary in a 67 year old female.

## Incidence of Spectrum of Tubal Lesions



### V. Discussion

Rarely fallopian tubes are sites of primary disease, rather affected commonly by inflammation, as part of pelvic inflammatory disease.<sup>(9)</sup> Tubal disease has been held accountable for 30-40% of the cases of female infertility.<sup>(10)</sup>

In this study, 269 (61.28%) cases were reported unremarkable and 170 (38.72%) cases were reported to have tubal pathology. In most of the studies, cases with unremarkable tubes were far more than the cases with tubal pathology.<sup>(11,15,16,17,18)</sup>

In the present study, the percentage of normal fallopian tube specimens was 61.28%. Study done by Bagwan et al<sup>(11)</sup> and Gon S et al<sup>(15)</sup> showed similar findings with percentage of normal fallopian tube specimens being 66.52% and 69%, respectively. Study conducted by Jha R et al<sup>(22)</sup> showed a higher percentage of normal fallopian tubes that is 84.3% of the specimens. Our study was in concordance with other studies. Prachi et al<sup>(23)</sup> Deepthi et al<sup>(24)</sup> Gon S et al<sup>(15)</sup> Jha R et al<sup>(22)</sup> Bagwan et al<sup>(11)</sup> Jennifer L. Hunt et al<sup>(2)</sup> all the studies had normal histology cases outnumbered the cases with tubal pathology.

The incidence of ectopic tubal pregnancy has increased markedly in recent times and it is often the consequence of chronic salpingitis, found in nearly half the patients with a reported range of 29-88%.<sup>(12,13)</sup>

Ampulla is the most common site of ectopic gestation & majority of the cases in the present study presented with ruptured ectopic pregnancy. These findings are similar to those observed by Job Spira et al.<sup>(21)</sup>

In this study, ectopic pregnancy was seen in 77 (17.54%) cases. The incidence of ectopic pregnancy was higher in this study. Bagwan et al observed almost similar incidence of ectopic pregnancy (11.79%). Most of the patients in this study were in the age group of 21-30 years, which was consistent with the study by Dahiya et al<sup>(19)</sup> in which, most of the cases were between the age group of 25 and 29 years.

Cases of primary genital tuberculosis are rare. The most common site is the fallopian tubes accounting to approximately 5%, seen most commonly in the ampullary region. Tuberculosis of fallopian tube develops commonly by hematogenous spread of the organism, usually from a primary pulmonary infection and rarely by direct extension from adjacent organs or lymphatic spread from intestinal tuberculosis.

In this study, granulomatous (tubercular) salpingitis is seen in 1 case (0.23%). Lakshmi et al<sup>(16)</sup> observed an incidence of tuberculous salpingitis (0.59%).

Agarwal and Gupta<sup>(15)</sup> in their study of female genital tract tuberculosis found the incidence declining from 1.8% in 1974 to 0.8% in 1989 and onward. They noted the involvement of endometrium in 99.5%, fallopian tubes in 94.7%, cervix in 81.5%, ovaries in 62.5% and vagina in 0.2% cases. In the study conducted by

Bagwan et al <sup>(11)</sup> majority of the cases belonged to the age group of 36-45 years. Gon S et al <sup>(15)</sup> showed same findings with majority of the cases belonging to the age group of 36-45 years.

Endometriosis is defined as the presence of ectopic endometrial tissue outside the lining of the uterine cavity and is fairly common in childbearing women. Endometriosis frequently involves the tubes in the form of nodules located in the wall or serosa.<sup>(20)</sup> Microscopically, foci of endometriosis were found located within the wall of the tubes in our case, which presented as a lump in right iliac fossa in a 28 year old female.

In study conducted by Jennifer L. Hunt et al <sup>(2)</sup> and Bagwan et al <sup>(11)</sup> most common lesions were non-neoplastic, comprised of salpingitis in 10.19%, pyosalpinx in 0.29% and hydrosalpinx in 7.86% of fallopian tube specimens. In the present study, the most common lesions were also non-neoplastic lesions.

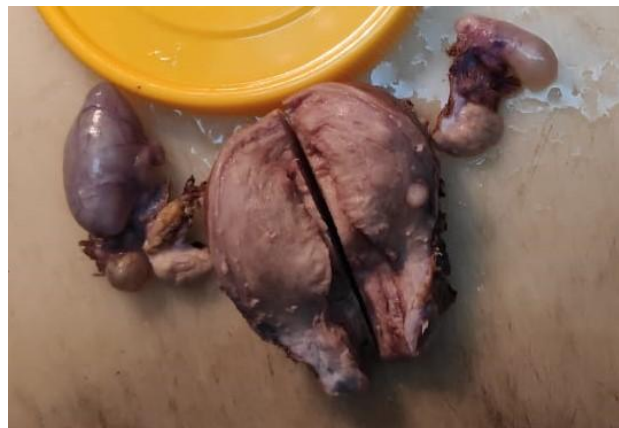In all the studies, neoplastic lesions of fallopian tubes were rare finding. In study conducted by Jennifer L. Hunt et al <sup>(2)</sup> metastatic lesions were seen in 1.4% of the specimens. In Bagwan et al <sup>(11)</sup> study secondary malignancy was seen in 0.29% of fallopian tube specimens. Jha R et al <sup>(22)</sup> reported secondary malignancies in 3.4% of the specimens. In study conducted by Gon S et al <sup>(15)</sup> secondary malignancies were reported in 0.2% of the specimens. In the present study, secondary malignancy accounted for 0.3% of specimens.

## VI. Conclusion

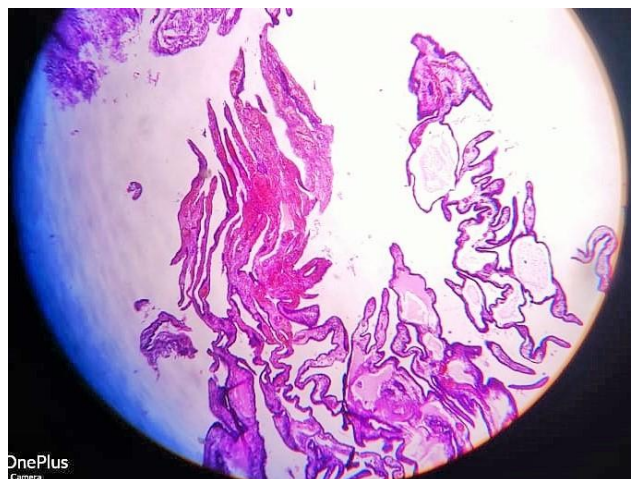
Fallopian tubes are common surgical specimens in pathology laboratory to be examined. Ectopic tubal gestation (17.54%) was the most common pathology to be encountered during histopathological examination of fallopian tubes. Followed by chronic salpingitis (12.53%), majority of which were non-specific (Tubercular being the rare cause, 0.23% in our study). Metastatic deposits are rare but should be sought by serial sections of the fallopian tubes. We found 2 cases (0.46%) of metastasis from ovarian adenocarcinoma.

Fimbrial end of fallopian tube is also common site of high-grade serous adeno-carcinoma of the ovary and peritoneum that is curable if the precursor pathology is detected and treated promptly.

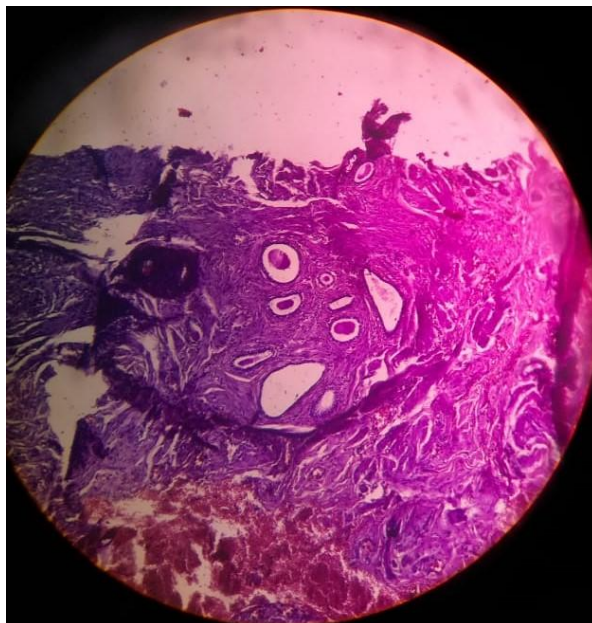
Thus, a serial and meticulous histopathological examination of fallopian tube should be done to demonstrate any pathological lesion.



**Figure 1:** Gross specimen showing Paratubal cyst



**Figure 2:** H and E showing Tubal Ectopic (10X)



**Figure 3:** H and E showing Endometriosis (10X)

### References

- [1]. Anderson MC. The fallopian tube. In: Symmers WS, ed. Systemic pathology female reproductive, system. London: Churchill Livingstone 1991:241-261.
- [2]. Hunt JL, Lynn AA. Histologic features of surgically removed fallopian tubes. Arch Pathol Lab Med 2002;126:951-955.
- [3]. McCormack WM. Pelvic inflammatory disease. N Engl J Med 1994;330(2):115-119.
- [4]. Paavonen J. Pelvic inflammatory disease. From diagnosis to prevention. Dermatol Clin 1998;16(4):747-756.
- [5]. Washington AE, Aral SO, Wolner-Hanssen P, et al. Assessing risk for pelvic inflammatory disease and its sequelae. JAMA 1991;266(18):2581-2586.
- [6]. Algren S, Strickland J. Beta haemolytic streptococcus group f causing pelvic inflammatory disease in a 14 year-old girl. J Pediatr Adolesc Gynecol 2005;18(2):117-119.
- [7]. Brown-Harrison M, Christenson JC, Harrison AM, et al. Group A streptococcal salpingitis in a prepubertal girl. Clin Pediatr 1995;34(10):556-558.
- [8]. Roma AA, Masand RP. Ovarian Brenner tumours and Walthard nests: a histologic and immunohistochemical study. Hum Pathol 2014;45(12):2417-2422.
- [9]. Kumar V, Cotran RS, Robbins SL. Female genital system and breast. In: Kumar V, Cotran RS, Robbins SL eds. Basic pathology. 6th edn. Harcourt Asia 2001:597-636.
- [10]. Margara RA, Trew GH. Tubal disease. In: Shaw RW, Soutter WP, Stanton SL, eds. Gynaecology. 2nd edn. Churchill Livingstone 1997:319-328.
- [11]. Bagwan IN, Harke AB, Malpani MR, et al. Histopathological study of spectrum of lesions encountered in the fallopian tube. J Obstet Gynecol Ind 2004;54(4):379-382.
- [12]. Barnhart KT. Ectopic pregnancy. N Engl J Med 2009;361(4):379-387.
- [13]. Green LK, Kott ML. Histopathologic findings in ectopic tubal pregnancy. Int J Gynecol Pathol 1989;8(3):255-262.
- [14]. Agarwal J, Gupta JK. Female genital tuberculosis - A retrospective clinicopathologic study of 501 cases. Indian J Pathol Microbiol 1993;36(4):389-397.
- [15]. Gon S, Basu A, Majumdar B, et al. Spectrum of histopathological lesions in the fallopian tubes. J Pathol Nepal 2013;3(1):356-360.
- [16]. Lakshmi K, Baleswari G, Mallikarjun C, Rao LB. Histopathological study of spectrum of lesions in the fallopian tubes. J Evol Med Dent Sci 2015;1:350-5.
- [17]. Arora KV, Sreenivasulu K, Janaki M, Harish V, Raja V. Study of histopathomorphological lesions of fallopian tube. Infertility 2015;2:32.
- [18]. Patel J, Iyer RR. Spectrum of histopathological changes in fallopian tubes—a study of 350 cases. Int J Sci Res 2016;5:180-1.
- [19]. Dahiya N, Singh S, Kalra R, Sen R, Kumar S. Histopathological changes associated with ectopic tubal pregnancy. IJPSR 2011;2:929-33.
- [20]. Sheldon RS, Wilson RB, Dockerty MB. Serosal endometriosis of fallopian tubes, Am J Obstet Gynecol 1967;99:882-4.
- [21]. Job Spira N, Fernandez H, Bouyer J et al. Ruptured tubal ectopic pregnancy: risk factors & reproductive outcome: results of population based study in France, Am J Obstet Gynecol 1999;180:938-44.
- [22]. Jha R, Pant AD, Jha A, et al. Histopathological analysis of hysterectomy. JNMA J Nepal Med Assoc 2006;45(163):283-290.
- [23]. Kukreja P, Shetty KJ. Histopathological spectrum of lesions in fallopian tube. IOSR-JDMS 2017;16(1):75-80.
- [24]. Deepti M, Jyotsna S, Kaul KK. Histological patterns in fallopian tube pathology - A retrospective study of 200 consecutive cases. JK Science Journal of Medical Education and Research 2016;18(2):71-75.

Dr. Nishat Ahmad, et. al. "A Study on Histopathological Spectrum of Lesions in Surgically Resected Specimens of Fallopian Tube: A Case Series." *IOSR Journal of Dental and Medical Sciences (IOSR-JDMS)*, 19(5), 2020, pp. 09-14.