

Reduction Technique for Valgus Impacted Femoral Neck Fractures: A Case Series

Praful Kilaru, Pushpak Reddy Chada, Ashok Raju Gottemukkala,
Annapareddy Venkata Gurava Reddy
Department of orthopaedics, Sunshine hospitals, India

Abstract:

Introduction: Valgus impacted femoral neck fractures present considerable difficulty in achieving anatomical reduction and therefore the management of these fractures remain an area of considerable controversy. Conventionally, in situ fixation without displacement of the fracture fragments has been advocated which sometimes is known to be associated with kinking of lateral epiphyseal vessels, inferomedial opening of fracture and hence progressing to AVN femoral head and nonunion. We therefore describe our technique of achieving anatomic reduction of fracture neck femur without disturbing the vascularity leading to good clinical outcome.

Materials & methods:

Between March 2017 to March 2019, forty-five cases of valgus impacted neck femur fractures with mean age of 37 years were included in the study. An indigenous reduction technique was used wherein the proximal head fragment was manipulated using 3mm Schanz pin as a joystick through mini-open approach to achieve anatomic reduction of the fracture site and fixed with 6.5mm titanium lag screws.

Results:

All forty-five patients had complete union of fractures with anatomical alignment. The average time for radiological fracture union was 12 weeks. No patient had any infection or implant related problems and complete pain free ambulation was achieved in 16 weeks. The average Harris hip score in the patients was 93.33.

Conclusion:

Our technique of Schanz pin mediated technique of reducing valgus impacted femoral neck fracture is easy to use and allows for anatomical reduction of fracture surfaces resulting in excellent functional outcomes.

Key Words: Neck of femur fracture, Valgus impacted, Reduction technique.

Date of Submission: 06-05-2020

Date of Acceptance: 19-05-2020

I. Introduction:

The occurrence of femoral neck fractures are nearly half of all hip fractures. Majority of these fractures occur in elderly patients after a trivial fall¹. These fractures are uncommon in adults younger than 50 years and often resulted due to high-energy trauma.^{2,3,6} The occurrence is only 2-3% of all femoral neck fractures.^{2,5,6}

These fractures are challenging as both proximal and distal fragments are mobile, achieving anatomical reduction is difficult as there's no control over proximal fragments in close reduction. Repeated forceful closed manipulations may break the remaining retinacular vessels⁷. These fractures have high chances of progressing to osteonecrosis of femur head (36%) and non union (20%)⁸ which may need re-surgery and salvage procedures such as osteotomy, which have high failure rates and arthroplasty procedures are not ideal for young age and higher levels of activity patients⁹. Hip preservation surgery is preferred in younger age group. Proper anatomical reduction and internal fixation is needed for increasing the union rate and a better clinical outcome.

The purpose of this study is to show the results of minimally invasive reduction technique of valgus impacted fracture to anatomical position.

Relevant anatomy and fracture classification:

The blood supply of the femoral head and neck has three distinct components: (a) an extracapsular arterial ring that arises from the lateral circumflex femoral artery anteriorly and the medial circumflex femoral artery posteriorly, (b) Ascending intracapsular cervical branches of the extracapsular ring, known as retinacular arteries, and (c) The artery of the ligamentum teres¹⁰. The retinacular arteries course superiorly along the surface of the femoral neck and form a subsynovial ring at the articular margin¹¹. The intracapsular course of the retinacular vessels and the subsynovial ring, and the intraosseous course of the lateral epiphyseal and inferior

metaphyseal branches of the subsynovial ring predispose the hip to vascular compromise in the setting of femoral head-neck fracture¹².

The Garden's classification is the most commonly used classification system and is based on degree of displacement¹³.

Stage 1: incomplete fracture line , undisplaced

Stage2: complete fracture line , undisplaced

Stage3: complete fracture line ,partially displaced

Stage 4: complete fracture line , completely displaced

II. Materials And Methods

Between march 2017 to march 2019, forty-five cases of valgus impacted neck offemur fractures with mean age of 37 years were included in the study. Fractures were evaluated using garden classification. Gardens alignment index was used to evaluate femoral neck angulation and alignment. An indigenou reduction technique was used wherein the proximal head fragment was manipulated using 3mm Schanz pin as a joystick through mini-open approach to achieve anatomic reduction of the fracture site and fixed with 6.5mm titanium lag screws.

Inclusion criteria :

- Age less than 50 years .
- Garden's type 1 and 2 fractures.
- Operated within 24 hours of injury.

Exclusion criteria :

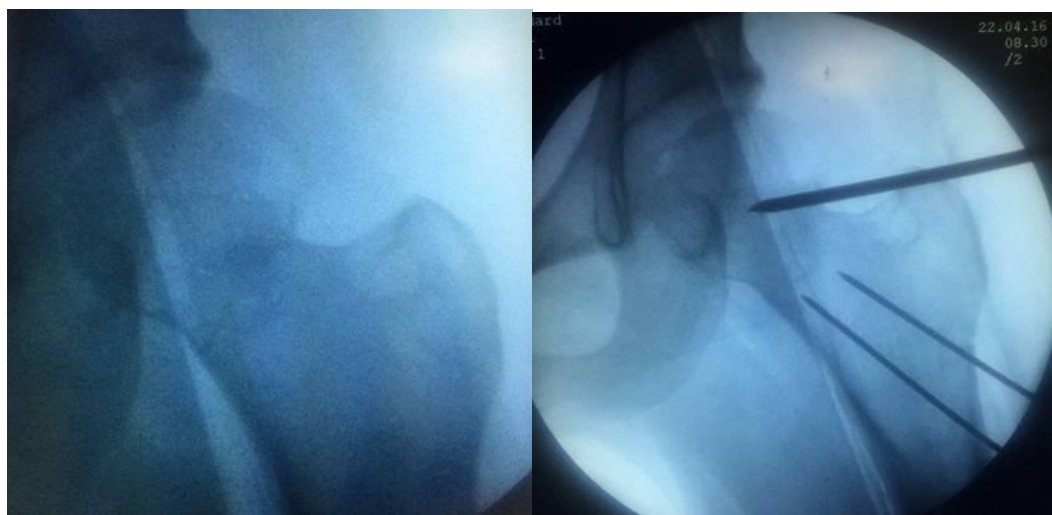- Age more than 50 years .
- Gardens type 3 and 4 fractures.
- Pathological fractures
- Ipsilateral femur shaft fractures
- Polytrauma

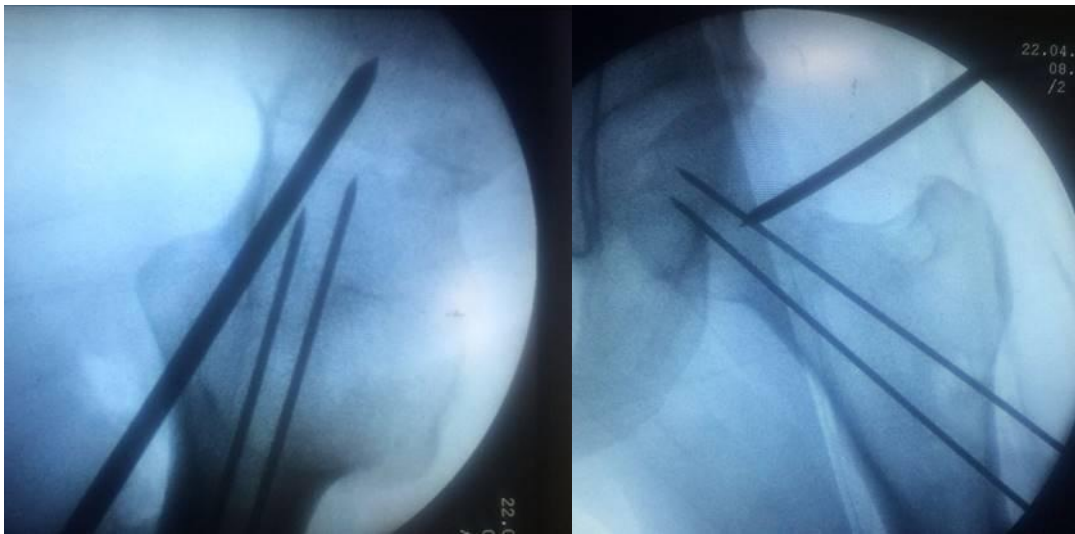
Surgical procedure and postoperative care :

Minimally invasive reduction and percutaneous fixation with cannulated cancellous screws done for fracture neck of femur . Procedure done under spinal anaesthesia with patient positioned supine on the fracture table. Single attempt of closed reduction tried , if the reduction was unsatisfactory ,we performed our method of reduction.

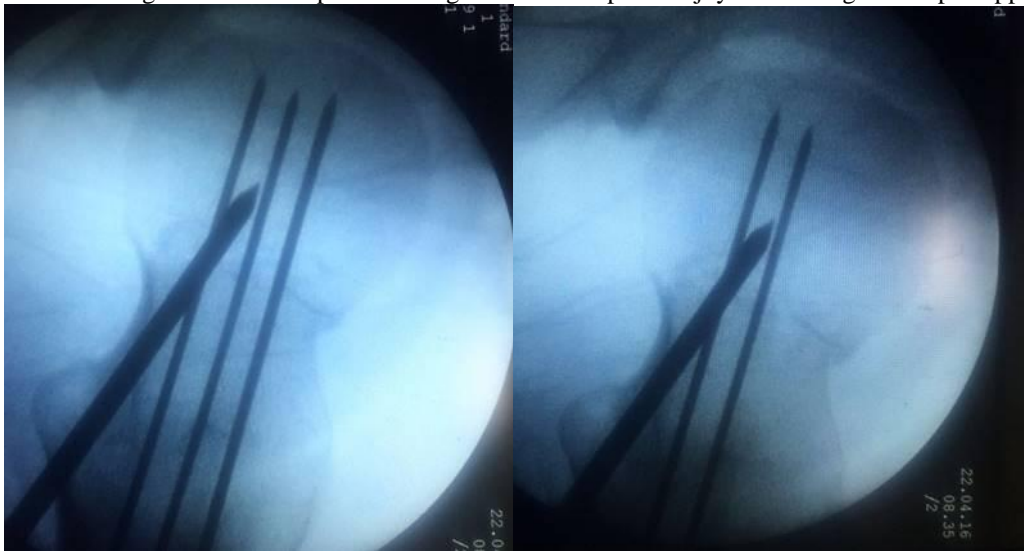
After scrubbing and draping ,procedure done as follows under the fluoroscopy guidance .(a) A stab incision was given at the level above fracture line anteriolaterally (b) A 3mm schanz pin was passed to the near adjacent centre region of femoral head [Fig;2](c) During disimpaction traction was applied (d) This schanz pin is used as a joystick to achieve anatomical reduction followed by temporary stabilization by three 2mm guide wires (e) We usually use 6.5 mm partially treaded cannulated cancellous screws in an inverted triangle configuration , starting with inferiocentral wire followed by posterosuperior and anterosuperior and the wires were replaced with screws in same order .

Intra Operative fluoroscopy pictures:

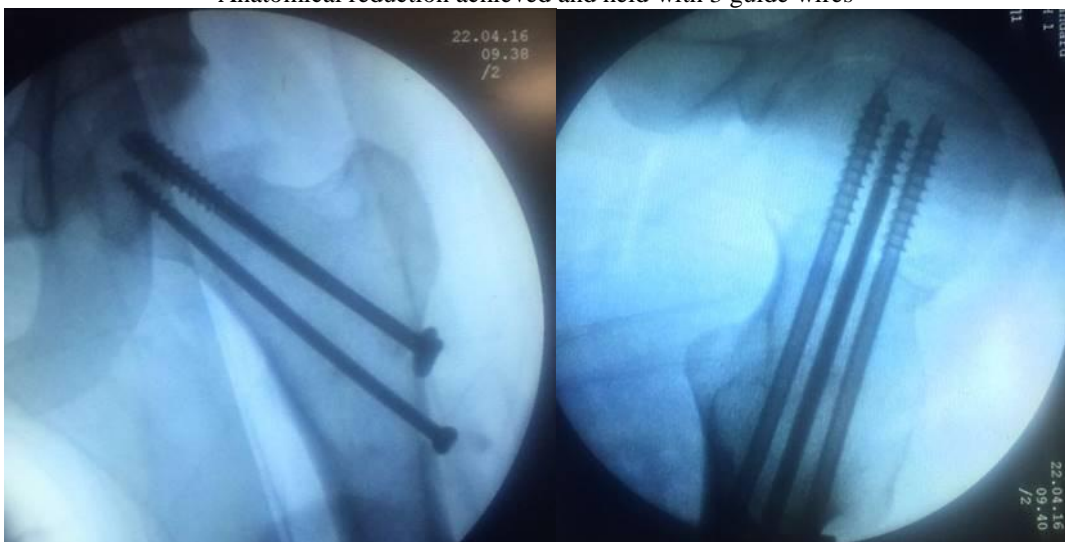



Proximal head fragment was manipulated using 3mm schanz pin as a joystick through miniopen approach



Anatomical reduction achieved and held with 3 guide wires

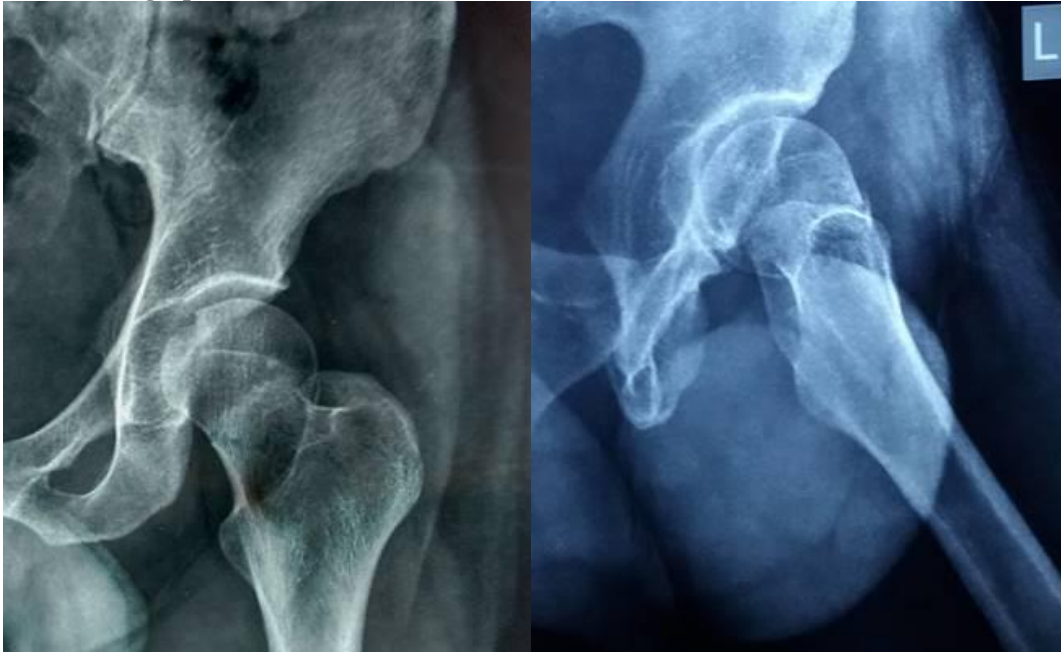

Guide wires replaced with 6.5 mm cannulated cancellous screws .

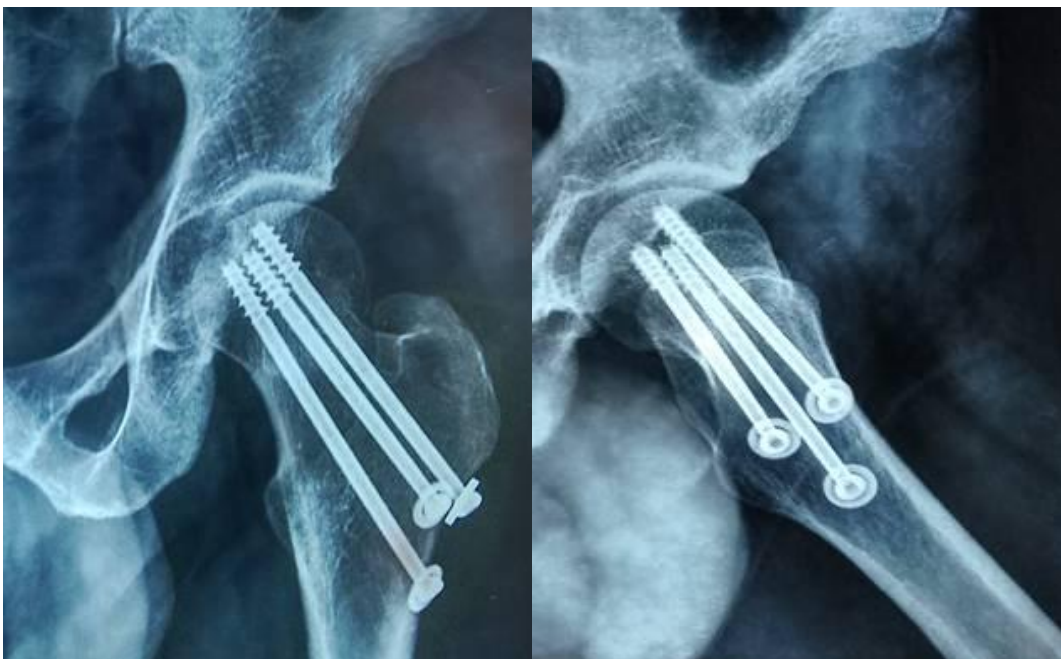Knee and hip range of motion was started on postop day 1 . Patient was put on non weight bearing walking withwalker support for 6 weeks and partial weight bearing was initiated from 6th week with sequential increase

ofweight every 2 weeks .we performed a standard AP and lateral views of hip immediately after surgery , 6 weeks,3 months , 6 months ,and 1 year postoperatively.

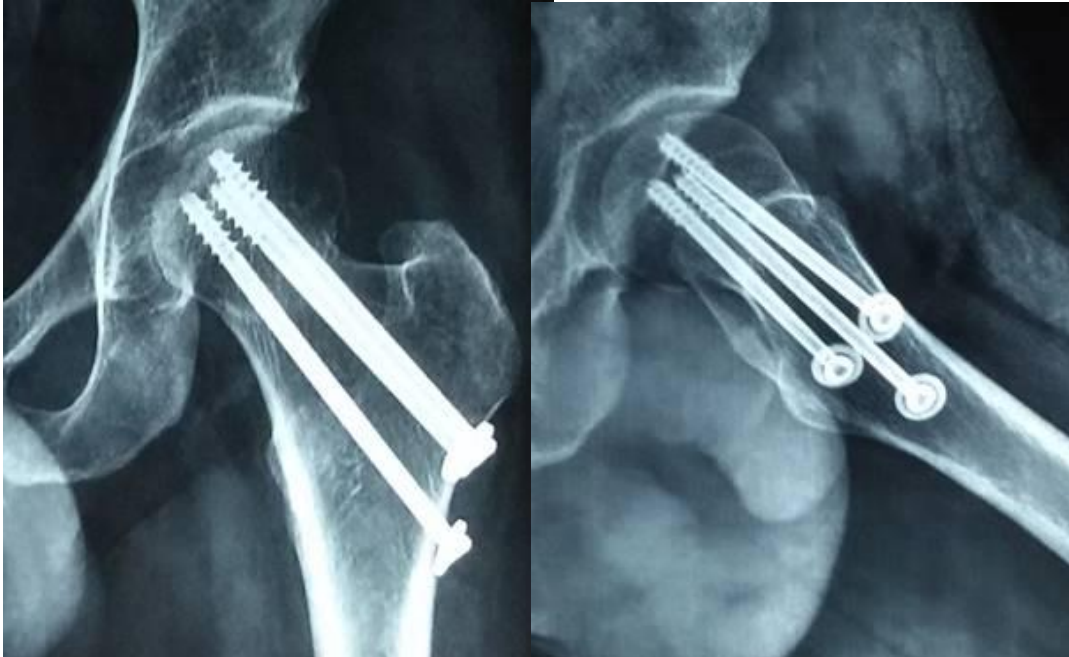
Preoperative radiograph



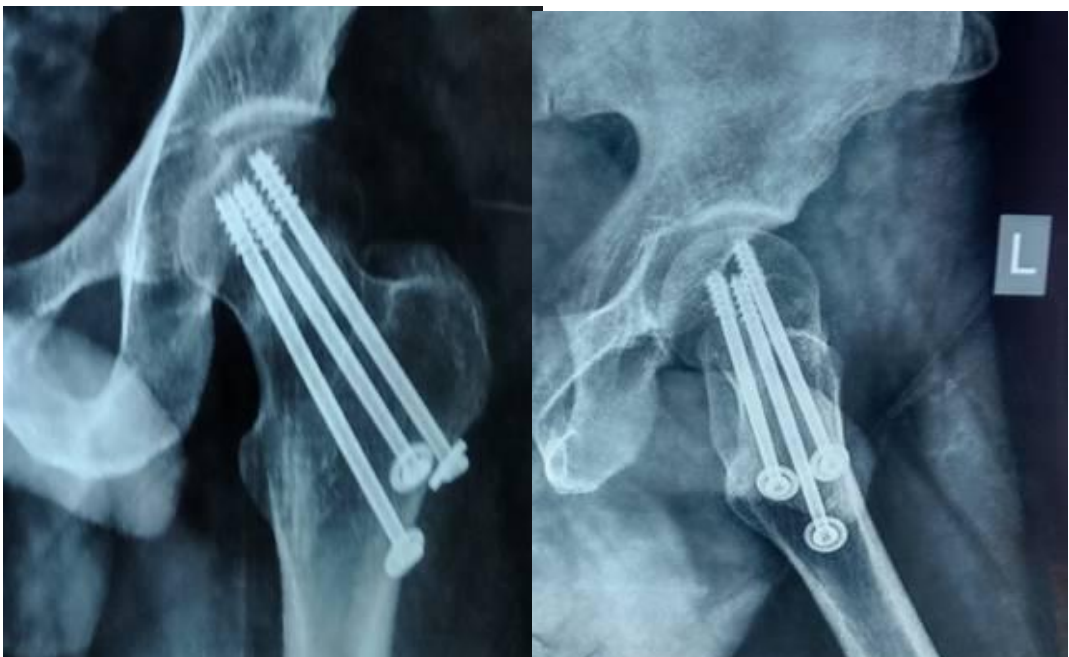
Immediate postoperative radiograph



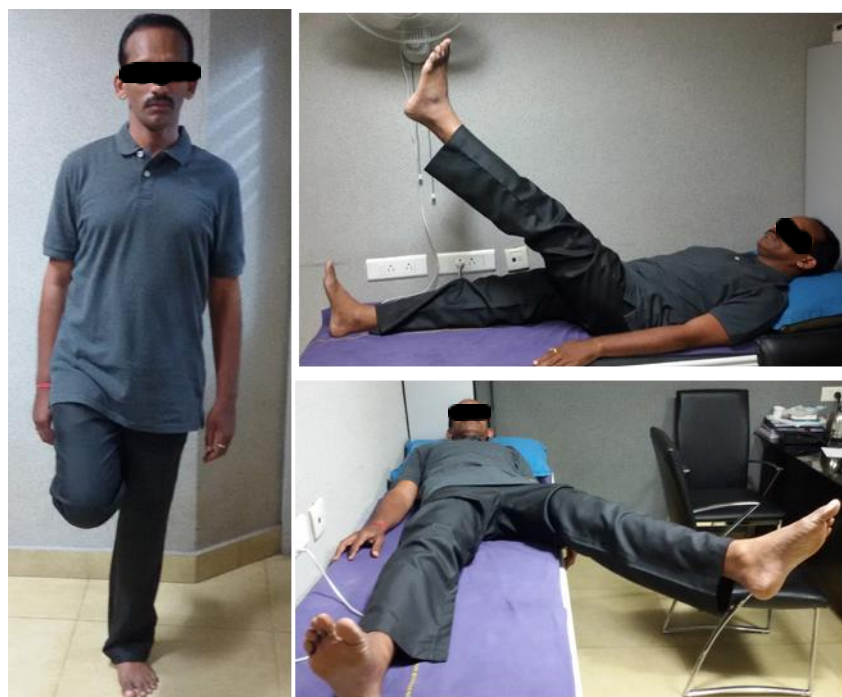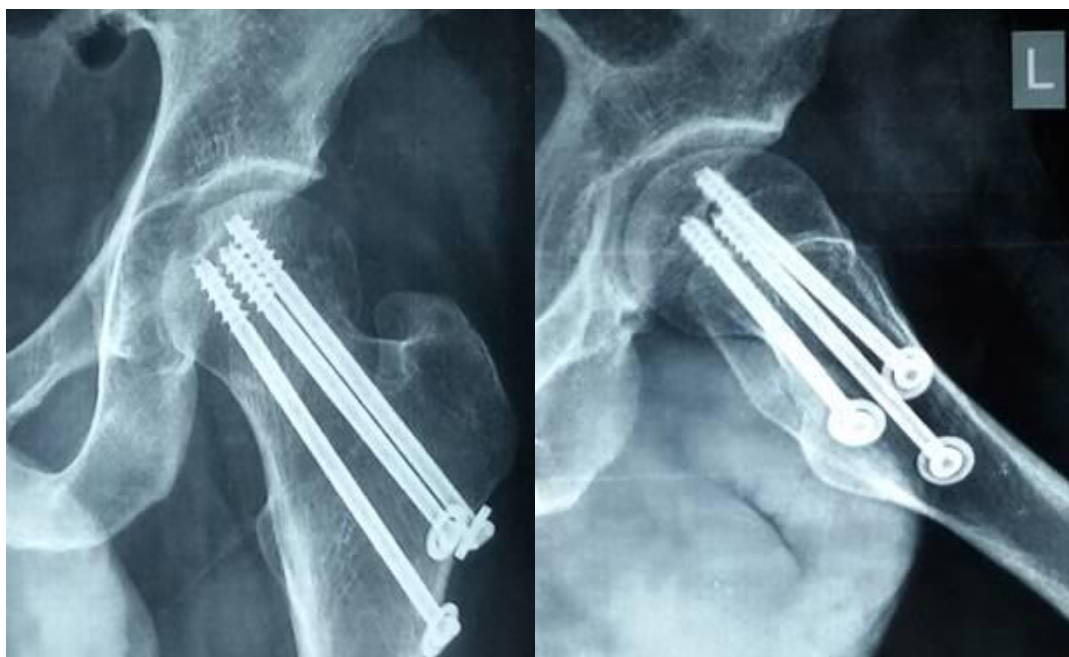
6 week postoperative radiograph



3 months postoperative radiograph



6 months post operative radiograph



Functional results were evaluated using Harris hip score(HHS).

III. Results :

We have achieved anatomical reduction in all patients. The mean age of the patients was 37 years (range 23-48 years) and all patients were followed up for more than 12 months. Majority of the patients were males i.e. 68.88% and 31.11% were females. Mode of injury was high energy trauma (either RTA or fall from height) in majority of the cases.

All 45 patients had union by the end of 16th week and 93.33% patients had HHS more than 90 with 42 patients achieving excellent functional results and there were no cases of non union, early arthritis, iatrogenic fractures, infections or implant related problems.

Variable	Number of patients (n=20)	Number of patients with union within 16 weeks	HHS >90 at 20 th week	Infection implant related problems
Age				
20-30 years	7	7	7	0
30-40 years	23	23	21	0
40-50 years	15	15	14	0
Gender				
Female	14	14	12	0
Male	31	31	30	0

IV. Discussion:

Garden classification system is the most widely used system for femoral neck fractures. Valgus impacted fractures are classified as type 1 in garden classification and believed to be innocent requiring no manipulation. OTA/AO classification of femoral neck fractures includes subgroups in 31B1 according to valgus impaction of 15° or more¹⁵.

Conventional insitu fixation without disimpaction of fracture is advocated as bony impaction at fracture site contribute to heal^{15,16}. But this technique may cause kinking of lateral epiphyseal vessels and inferomedial opening of fracture, hence progressing to avascular necrosis of femoral head, non-union. In a study done by Song et al concluded that femoral neck shortening and less functional recovery is expected in valgus impacted femoral neck fracture¹⁵. Mitsuaki Noda et al stated that valgus impacted fracture may cause muscular impairment that can possibly lead to postoperative functional disorder²⁰.

Achieving an anatomical reduction and stable fixation is crucial for a better patient outcome and successful union. Reduction is the key to avoid avascular necrosis (AVN) of head of femur¹⁷. Byung-woo min et al in his study of 163 intracapsular femoral neck fractures concluded that quality of reduction, adequacy of fixation and degree of displacement were significantly associated¹⁸. George J Haidukewych et al concluded that fracture displacement and quality of reduction has influenced the survival of native femoral head¹⁹.

In our study, we conclude that our method of reduction is simple and able to achieve anatomical reduction in all cases with union.

V. Conclusion:

Our technique of shanz pin mediated technique of reducing valgus impacted femoral neck fracture is easy to use and allows anatomical reduction of fracture surface resulting in excellent functional outcome.

References :

- [1]. Karagas MR, Lu-Yao GL, Barrett JA, Beach ML, Baron JA. Heterogeneity of hip fracture: age, race, sex, and geographic patterns of femoral neck and trochanteric fractures among the US elderly. *Am J Epidemiol.* 1996;143:677-682. [PubMed] [DOI]
- [2]. Robinson CM, Court-Brown CM, McQueen MM, Christie J. Hip fractures in adults younger than 50 years of age: Epidemiology and Results. *ClinOrthopRelat Res.* 1995;312:238-46. [PubMed] [Google Scholar]
- [3]. Askin SR, Bryan R. Femoral neck fractures in young adults. *ClinOrthopRelat Res.* 1976;114:259-64. [PubMed] [Google Scholar]
- [4]. Protzman RR, Burkhalter WE. Femoral-neck fractures in young adults. *J Bone Joint Surg Am.* 1976;58:689-95. [PubMed] [Google Scholar]
- [5]. Zetterberg CH, Elmerson S, Andersson GB. Epidemiology of hip fractures in Goteborg, Sweden, 1940-1983. *ClinOrthopRelat Res.* 1984;191:43-52. [PubMed] [Google Scholar]
- [6]. Thuan V Ly and Marc F Swiontkowski. Management of femoral neck fractures in young adults **Indian J Orthop.** 2008 Jan-Mar; 42(1): 3-12.
- [7]. Gautam, V. K., Anand, S., & Dhaon, B. K. (1998). *Management of displaced femoral neck fractures in young adults (a group at risk).* *Injury*, 29(3), 215-218. doi:10.1016/s0020-1383(97)00184-8
- [8]. DEDRICK, D. K., MACKENZIE, J. R., & BURNEY, R. E. (1986). *Complications of Femoral Neck Fracture in Young Adults. The Journal of Trauma: Injury, Infection, and Critical Care*, 26(10), 932-937. doi: 10.1097/00005373-198610000-00013
- [9]. Chandler HP, Reineck FT, Wixson RL, McCarthy JC. Total hip replacement in patients younger than thirty years old. *J Bone Joint Surg Am.* 1981;63:1426-34. [PubMed] [Google Scholar]
- [10]. Crock HV. An atlas of the arterial supply of the head and neck of the femur in man. *ClinOrthopRelat Res* 1980;(152):17-27. Medline, Google Scholar
- [11]. Chung SM. The arterial supply of the developing proximal end of the human femur. *J Bone Joint Surg Am* 1976;58(7): 961-970. Crossref, Medline, Google Scholar
- [12]. Claffey TJ. Avascular necrosis of the femoral head: an anatomical study. *J Bone Joint Surg Br* 1960;42-B:802-809. Crossref, Medline, Google Scholar
- [13]. Jillian M. Kazley, MD, Samik Banerjee, MBBS, and Andrew J. Rosenbaum, MD, Classifications in Brief: Garden Classification of Femoral Neck Fractures, *ClinOrthopRelat Res.* 2018 Feb; 476(2): 441-445. Published online 2018 Jan 17. doi: 10.1007/s11999-0000000000000066
- [14]. Song, H. K., Lee, J. J., Oh, H. C., & Yang, K. H. (2013). *Clinical Implication of Subgrouping in Valgus Femoral Neck Fractures. Journal of Orthopaedic Trauma*, 27(12), 677-682. doi:10.1097/bot.0b013e31828e18c5.
- [15]. CALANDRUCCIO, R. A., & ANDERSON, W. E. (1980). *Post-Fracture Avascular Necrosis of the Femoral Head. Clinical Orthopaedics and Related Research*, &NA;(152), 49??84. doi:10.1097/00003086-198010000-00008.

- [16]. Mitsuaki Noda¹, Masayasu Takahashi², Koji Nukuto², Masahiro Fujita², Issei Shinohara², Yoshihito Suda² and Shin Ohsawa², Innovative technique of minimally invasive closed reduction for impacted femoral neck fractures (MICRIF), *Journal of Orthopaedic Surgery* 27(1) 1–4 DOI: 10.1177/2309499019832418.
- [17]. Wang C, Xu GJ, Han Z, et al. Correlation between residual displacement and osteonecrosis of the femoral head following cannulated screw fixation of femoral neck fractures. *Medicine (Baltimore)*. 2015;94:e2139.
- [18]. Min BW, Kim SJ. Avascular necrosis of the femoral head after osteosynthesis of femoral neck fracture. *Orthopedics*. 2011;34:349 Cited Here .PubMed
- [19]. Haidukewych GJ, Rothwell WS, Jacofsky DJ, et al. Operative treatment of femoral neck fractures in patients between the ages of fifteen and fifty years. *J Bone Joint Surg Am*. 2004;86:1711–1716.Cited Here |View Full Text | PubMed | CrossRef
- [20]. Diminished abductor muscular strength in patients with valgus-impacted femoral neck fractures treated by internal fixation: Clinical study and biomechanical considerationsMitsuaki Noda, Yasuhiro Saegusa, Masayasu Takahashi, <https://doi.org/10.1177/2309499017716070>.

PrafulKilaru, et. al. "Reduction Technique for Valgus Impacted Femoral Neck Fractures: A Case Series." *IOSR Journal of Dental and Medical Sciences (IOSR-JDMS)*, 19(5), 2020, pp. 07-14.