

Forensic medical examination in a case penetrating neck injury

Taufik Suryadi^{1,*}, Kulsum Kulsum²

¹Department of Forensic Medicine and Medicolegal,

²Department of Anesthesiology and Intensive Therapy,

Faculty of Medicine, Universitas Syiah Kuala, Banda Aceh, Indonesia

Abstract: A reported case of death of a 51-year-old male victim from a stab wound to the back of the neck. When the victim was taken to the hospital, a knife still stuck in the back of the neck. According to the testimony of residents who found the victim, the victim was injured in a gold mining barracks, there were no eyewitnesses who saw the incident. In forensic medical examinations, stab wounds were found in the neck and chest and several incised wounds on the back and arms. On the X-ray photograph, a knife appears through the inner chest wall causing pneumothorax. The victim was treated at the intensive care unit, but in the end was not helped because the victim suffered pneumothorax and subcutaneous emphysema which caused the victim to die. Cause of death of the case is penetrating neck injury, the mechanism of death due to asphyxia and bleeding, the manner of death is maybe homicide.

Key Words: Penetrating neck injury, asphyxia, bleeding, forensic medicine.

Date of Submission: 26-05-2020

Date of Acceptance: 13-06-2020

I. Introduction

Injury due to contact with a sharp weapon occurs when the force of violence exceeds the threshold of endurance of body tissue that can be in the form of incised wounds, stab wounds and cut wounds.¹ From the type and nature of the injury, it can be seen the type of violence, the direction of the violence, the distance of the victim from the perpetrator, the habits of the perpetrator, the mental condition and the manner of death.^{2,3} Stab wounds to the neck contribute significantly to mortality even though they have a small percentage compared to the overall wound. Of the total number of stab wounds in the neck, 25% affected the arteries, 80% of them affected the carotid artery and 43% affected the vertebral artery. It was reported that stab wounds to the neck affecting one or several blood vessels were significantly related to death and disability. Deaths caused by stab wounds affecting extracranial blood vessels have a prevalence of 21.2% and the resulting disability can be in the form of severe neurological deficits if the blood vessels are obstructed in flow.⁴ Chest was the most common location affected by puncture, which was 72.5%, stomach 42.9%, arm 27.9%, limb 22.0%, head 20.9% and neck 19.8%. In sharp stabbings, 84.6% of murder cases and 25.3% resulted in death.⁵ In this article reported a forensic medical examination of unique case of suspected to be homicide by multiple stab wounds over the neck, chest, and incised wounds in other of the body.

II. Case report

A 51-year-old male victim was taken to the emergency room (ER) in a state of severe tightness after being stabbed in the neck, back and chest. According to witness testimony, the victim was found by some people in the gold mining barracks. On arrival at the hospital, the victim was conscious, blood pressure 150/70 mmHg, heart rate 92 times per minute, respiratory rate 32 times / minute, body temperature 36°C. On the medical forensic examination, a total of 8 wounds were found localized as follows: stab wound in the back of the neck with a length of eight centimeters and a width of one centimeter, the depth cannot be assessed. There was a knife still stuck in the neck (figure 1). Several other wounds were found in the body, namely incised wound on the right shoulder in the vertical direction, incised wound in the right shoulder in the horizontal direction, the stab wound in the left chest in the vertical direction, the incised wound in the left upper arm, and the incised wound in the left back. X-ray examination of the neck with a lateral position, obtained a drawing of a knife stuck in the back of the patient's neck, the tip of the blade inserted about one centimeter behind the spine (figure 2). The victim was treated at the intensive care unit (ICU), but in the end was not helped because the victim suffered pneumothorax and subcutaneous emphysema which caused the victim to die.

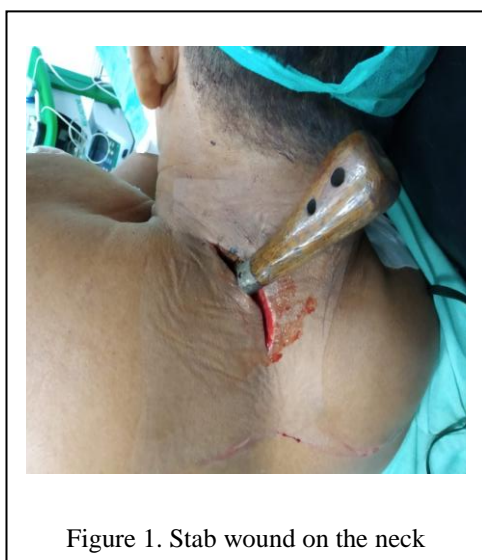

Figure 1. Stab wound on the neck

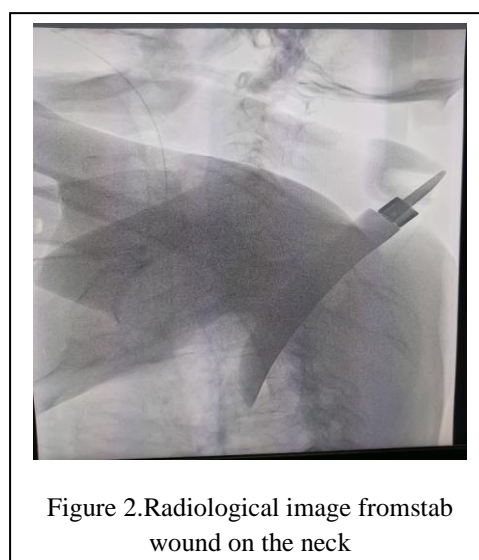


Figure 2. Radiological image from stab wound on the neck

III. Discussion

Stab wounds are one part of a sharp pointy object that goes into the body's tissues which causes injuries that tend to be small on the skin. The factors that influence the severity of the stab wound are the location of the wound and the strength of the puncture. If a part of the body hits a stab wound some of the organs contained in it will be prone to penetration trauma. In general, solid organs respond to trauma in the form of bleeding. If it occurs in the neck it will hit several large blood vessels which will cause massive bleeding. Stab wounds involving the thorax can cause several complications including pneumothorax depending on the depth of the wound caused by a stab wound.^{6,7} Stab wounds to the neck are usually associated with damage to blood vessels, bleeding will fill the trachea and airway cavity. Asphyxia can occur due to blood from stab wounds to the neck and trachea or air emboli that enter the circulation.^{8,9} Neck injuries zone and associated with risk structure can be seen in table 1.

Stab wounds to the chest can affect vital organs such as the heart and aorta. While deaths caused by stab wounds to the lungs are rare. Stab wounds that occur in the right chest will be a serious problem if it affects the right ventricle, aorta or right atrium. Meanwhile, if the wound on the left chest can penetrate the left ventricle. The most common cause of death is pericardial hemorrhage which causes cardiac tamponade, however if a stab wound penetrates the lungs it will cause pneumothorax.⁸

Stab wounds have a greater depth of wound compared to the width of the wound, the sharp and blunt edge of the stab wound comes from a knife that has a sharp side to one side. A knife that has two sharp edges will produce cuts with both sharp edges as well. The width of the wound will be smaller than the width of the knife if the wound is transverse to the muscle. Measuring the width of the wound after it is closed, because this can represent the width of the instrument used to make the wound. However, a situation that is often found is the width of the wound exceeds the width of the knife because of the pull to the side when thrusting and pulling the knife.^{10,11}

In the examination of wounds there are two things that need to be considered, namely defective injuries and self-inflicted injury. This needs to be known for medicolegal purposes. Defective injuries are usually found on the back of the hand, fingers, elbows and palms which usually occurs due to resistance from the perpetrators attack. Self-inflicted injury have superficial injuries, with a relatively large number of repetitive results that are almost parallel to the location and between those wounds one deep wound or another fatal site, such as in the neck affecting an artery the carotid and the wrists which affect the radial arteries.¹¹ In this case no self-inflicted injury was found.

Table 1. Neck injury zones⁹

Zone	Anatomical location	Risk structure
I	Clavicle and inferior of the cricoid cartilage	- Proximal carotid arteries - Large blood vessels in the superior mediastinum, pulmonary apex - Esophagus, trachea and thoracic duct
II	Cricoid and inferior cartilage from the angle of the mandible	- Carotid and vertebral arteries and internal jugular veins - Tracheal larynx and esophagus - Cranial nerves X, recurrent laryngeal nerve and spinal cord

III	Mandibular angle and base of skull	-	Distal carotid artery and vertebral artery
		-	Salivary glands, pharynx
		-	Spinal cord and cranial nerves IX-XII

From the results of the history of the victim while in the ER, the victim claimed to have been persecuted by someone who was not clearly seen because of the dark place. The perpetrator suddenly attacked the victim using a knife. This results in stab wounds to the neck and chest. After that incident the victim was immediately taken to the hospital for treatment. The victims were thoroughly examined systematically for medicolegal purposes.^{12,13} Interpretation of wounds examined must be based on actual conditions and should not be influenced by the statements of victims or families because in some cases victims or families tend to dramatize stories and injuries for personal gain.¹⁴

The things that are assessed in describing a wound are the number of wounds, the location of the wound, the direction of the wound, the size of the wound (length, width and depth), the type of violence, the shape of the instrument, the qualification or the severity of the wound, the medicolegal wound, the ante-mortem or post-mortem wound. In determining the location of the wound, it is necessary to explain the area adjacent to the anatomical lines of the body and the position of certain tissues. The shape of the wound is illustrated through a sketch that indicates damage to the surface of the skin, underlying tissue and internal organs. If the examiner is in doubt whether the injury occur ante mortem or post mortem, tissue samples can be taken for microscopic examination.^{7,9,11}

Determination of medicolegal wounds can be determined by collecting all examination data of victims both in acts of suicide, murder and accident. There are several factors as a support including the location and number of injuries, the type of wound, the area of the wound, the direction of the wound, the location and position of the weapon, the presence of blood or foreign objects on the weapon, the location and nature of the blood on the victim and on the clothes and the situation around the incident. Tears in clothing and their relationship to wounds on the victim's body and signs of resistance that can be seen from clothing or body and the situation of the scene.^{11,12,13}

Suicide attempts are generally carried out using sharp force. The location of the wound is usually found on the wrist which can be a cut, or the left chest is a stab wound in the heart. Suicide wounds with sharp weapons are usually found on the left side of the body, but on left-handed people will get the opposite. If during a cadaveric spasm, this is an indication of a suicide. Besides the direction of the wound can also help determine the reconstruction of events, for example cuts in the neck starting from the left to the bottom right is a direction that is not commonly used in people who commit suicide. If a trial wound is found on a person's body this indicate a suicide attempt. The form, location, pattern and number can be used to distinguish between suicides or homicides. In trial wounds the only part of the weapon that penetrates the skin is the superficial part and only affects the epidermis layer or deeper, the dermal layer. Based on several studies stab wounds were found in 62% -88% of suicide attempts.^{12,13,14}

Homicide usually uses sharp, blunt force and gunshot wounds. The number of injuries and the location of many injuries can occur in all parts of the body, especially in locations that are difficult to reach the victim's hand. In the examination it is very important to find resistance wounds or defects.^{8,11} Accidents generally occur due to blunt force but do not rule out the possibility of sharp violence or gunshot wounds. Usually a location on one side of the body. Examination of crime scene is very helpful to determine medicolegal from injury.^{11,12}

The cause of death in this case can occur due to extensive bleeding and many that occur inside or outside the thorax cavity. Sudden blood loss of 1/3 of the volume can cause death because the body cannot compensate. Bleeding in the body cavity can be found in cases of stab wounds that often affect vital organs such as the heart, and lungs. If more than one wound is found, then the injury that can cause death to the victim must be determined.^{11,13,14} Injuries to vital organs in this case can be the heart, lungs, spleen, liver, kidneys, large blood vessels and others can cause death more quickly. Bleeding that occurs in the pericardial sac as much as 300-400 cc can cause heart tamponade which ends in death.^{4,5,8,11} Hypovolemic shock can occur in the injury. Hypovolemic shock is caused by a lot of sudden bleeding and leads to death.¹¹ Penetrating neck injuries have the potential to cause death and are in urgent need of immediate emergency action. Examination of the wound must be careful because it could injure internal organs.¹⁵ According to medical records- the victim was treated in an ICU with a diagnosis of pneumothorax and subcutaneous emphysema. Subcutaneous emphysema is detected a few days after being treated in the ICU. These conditions aggravate the patient's condition so they are unable to survive.

IV. Conclusion

A 51-year-old man had been examined, one stab wound in the left chest of the victim that caused heavy congestion, and one stab wound in the back of the neck that was still stuck with a knife and caused heavy bleeding, and six other injuries to the right shoulder, left arm, back, and back of the left hand. The victim was treated in the intensive care unit, but due to heavy bleeding and pneumothorax, the victim's life was not saved.

In the above case it can be concluded: The cause of death of the victim is penetrating neck trauma causing bleeding and asphyxia. The manner of death of the victim is estimated to be due to severe physical abuse that caused death, maybe a homicide.

References

- [1]. Nerchan E, Mallo JF, Mallo NTS. Wound Patterns in Deaths due to Sharp Violence in the Division of Forensic Medicine and Medicolegal RSUP Prof.Dr.R.D.Kandou Manado Period 2013. *J e-Clinic*. 2015;3.
- [2]. Solarino B, Buschman CT, Tsokos M. Suicidal cut-throat and stab fatalities: three case reports. *Rom J Leg Med*. 2011; 9: 161-166.
- [3]. Putri DFA, Kusuma SE. Sharp Violence In Abdomen That Cause Death. *Proceeding in National Congress of Indonesian Association of Forensic Medicine*. 2017:107–10.
- [4]. Perinjelij V, Mercer L, Daoud F AL, Ligate to Live : Stab Wound to the Neck with Major Vascular Injuries. *Bs TN, Bs BM. iMedPub Journals*. 2017:1–5.
- [5]. Nirmalasari N, Bagus I, Putra G, Kusparwati RAY, Pristianti I, et al. Penetrating Heart Injuries and Pancreas Causing Deadly DIC (A Case Report). *Indones J Leg Forensic Sci*. 2013;3(1):14–20.
- [6]. Di Vella G, Grattagliano I, Catasei R, Sullivan MK, Tattoli L. Multiple stab wound: understanding the manner of death through the psychological autopsy. *Clin Ter*.2017;168(4): 233-239.
- [7]. Sonmez E, Ozkan A, Gulen B, Metin H, Akdemir OC. Two self-stabbing pneumothorax case. *Bezmialem Science*. 2018; 6(3): 217-219.
- [8]. Syarifah MC, Yudianto HA. Autopsy Findings in Cases of Sharp Violence. *Proceeding in National Congress of Indonesian Association of Forensic Medicine*. 2017:
- [9]. Gulia J, Yadav S, Singh K, Khaowas A. Penetrating Neck Injury: reports of two case. *J Emerg Med*. 6.
- [10]. Nishimura T, Sakata H, Yamada T, Terashima M, Shirai K, Yamada I, et al. Different patterns in abdominal stab wound in the self-inflicted and assaulted patients: an observational analysis of single-center experience. *Kobe J Med Sci*. 2017; 63(1): 17-21.
- [11]. Ahn S, Kim DJ, Paik KY, Chung JH, Park WC, Kim W, et al. A comparison of self-inflicted stab wounds versus assault-induced stab wounds. *Tauma Mon*. 2016; 21(5): e25304.
- [12]. Viel G, Cecchetto G, Montisci M. An Unusual Case of Suicide by Sharp Force. *Forensic Sci Int*. 2009;184:12–5.
- [13]. Srisont S. An Autopsy Case Report of Suicide by Multiple Self-Cutting and Self-Stabbing over the Chest and Neck. 2009;92(6):861–864.
- [14]. Jha S, Parajuli SR, Subedi ND. Suicide by self-inflicted stab wound to the heart: a rare case of suicide from Nepal. *Journal of College of Medical Science-Nepal*. 2014; 10(2): 33-35.
- [15]. Suzuki T, Takada T, Fujodi J. Traumatic pneumothorax associated with penetrating neck injury caused by a stringray: a case report. *Wilderness & Environmental medicine*. 2017; 28: 119-121.

Taufik Suryadi, et. al. "Forensic medical examination in a case penetrating neck injury." *IOSR Journal of Dental and Medical Sciences (IOSR-JDMS)*, 19(6), 2020, pp. 13-16.