

Sectional Collapsible Complete Denture for a Patient with Microstomia: A Case Report

Dr. JuheeNaresh Mehta¹, Dr. Maya Dalaya²

¹(Prosthodontist, BharatiVidyapeeth Dental College Mumbai, India)

²(Former Head of Prosthodontics Department, BharatiVidyapeeth Dental College Mumbai, India)

Abstract:

Microstomia is a condition of limited mouth opening which may result by multiple factors like neoplasms, burns, traumatic surgery, scleroderma, Plummer-Vinson syndrome, etc. A dentist faces a challenge to make impressions in such cases. This case-report describes a technique to fabricate a sectional collapsible complete denture for a patient with microstomia by using sectional trays.

Keywords: Collapsible denture, Sectional trays, Microstomia

Date of Submission: 09-07-2020

Date of Acceptance: 26-07-2020

I. Introduction

Microstomia is a relatively common condition that has variety of causes. Dentists face this challenging situation while treating patients with orofacial malignancies, trauma, burns, Plummer-Vinson syndrome or scleroderma that results in limited mouth opening¹. The maximum oral opening that is smaller than the size of complete denture can make the prosthetic treatment challenging. Several techniques have been described for use when either standard impression trays or the denture itself becomes too difficult to place and remove from the mouth². Treatment options for managing microstomia include surgical correction to enlarge the mouth³ and dental implants⁴, but if these options are not available, sectional complete removable denture can be an alternative treatment.

This case-report describes an innovative technique of fabricating sectional collapsible complete removable dental prosthesis using sectional trays for recording impressions.

II. Case-Report

A female patient, aged 52 years, reported to BharatiVidyapeeth Dental College & Hospital (Navi-Mumbai), Department of Prosthodontics with the chief complaint of missing teeth in upper and lower arch (Fig. 1a). No relevant medical history recorded. Past dental history revealed that she had undergone extractions of her teeth 2 months back due to mobility associated with them. Intraoral examination showed completely edentulous maxillary and mandibular arch. Extraoral examination showed limited mouth opening of 29mm (Fig. 1b). Various treatment options were discussed. Complete maxillary and mandibular collapsible dentures were finalized as the appropriate treatment option.

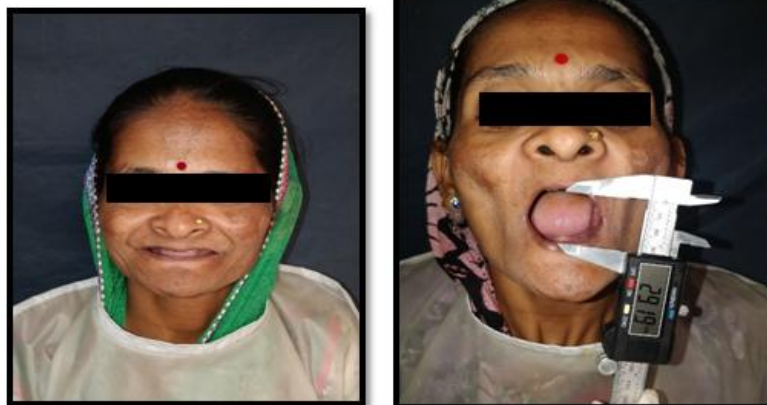

Fig. (1a) Pre-Operative photograph Fig. (1b) Limited mouth opening

III. Procedure

1. Treatment execution began by making preliminary impression of maxillary and mandible using Type-I Impression compound. The primary casts were poured. (Fig. 2)
2. An auto-polymerizing acrylic resin tray was prepared on each primary cast. For each tray, 2 metal pins were attached, each of 2.5mm in diameter and 15mm long. In maxillary tray, the resin block of 35mm was made on the sectioned half and attached with press stud buttons for rearranging the impression. The trays were cut into two pieces with a steel disc and then joined with the acrylic resin block. (Fig. 3)
3. Border molding was carried out with Type II Impression compound. The right and left sections were inserted in the mouth separately for border molding. The final impression was made using Light Body PVS material. The two halves of the impression was re-arranged using acrylic block and the master cast was poured. (Fig.4)
4. The maxillary and mandibular denture bases were prepared in two pieces: right and left. These pieces were joined by overlapping one on the other by 2mm in the midline. A stainless steel hinge was fitted with auto-polymerizing acrylic resin in the centre of the axis connecting the denture bases.(Fig. 5)
5. Recording of maxillo-mandibular relation was carried out and the rims were mounted in the centric relation.(Fig. 6)
6. Denture try-in was carried out to evaluate occlusion, speech and esthetics.
7. Heat cure acrylization was carried out and to preventflow of resin into the connecting area, transparent cellophane separator sheet was placed into the gap in the hinge design.
8. Thedenture was deflasked, trimmed, and polished (Figure 7).Home care instructions (oral hygiene instruction, insertion,and removal of prosthesis) were and imparted to thepatient, routine followup appointments were scheduled.

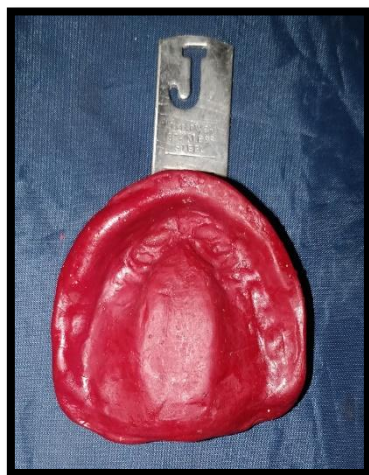

Fig. (2a) Maxillary primary impression

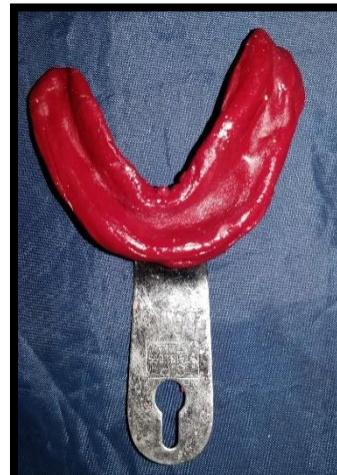

Fig. (2b) Mandibular primary impression



Fig. (3a) Maxillary sectional custom tray with resin block and pins

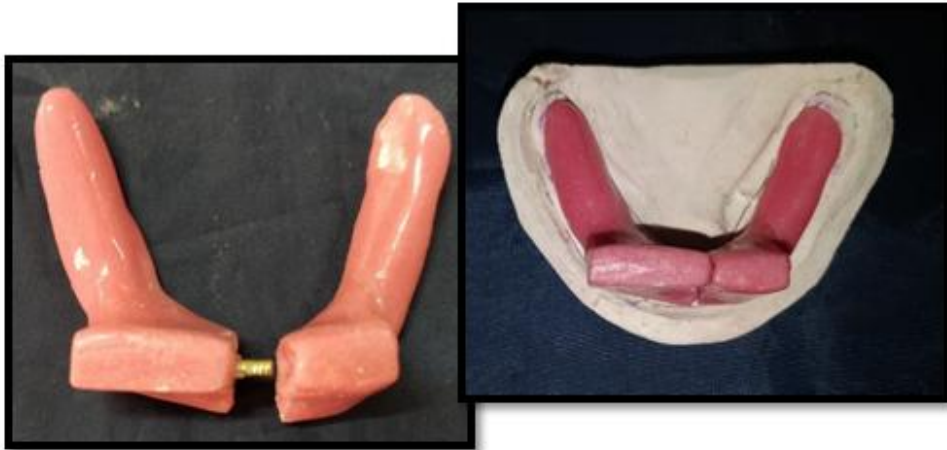

Fig. (3b) Mandibular sectional custom tray with pins

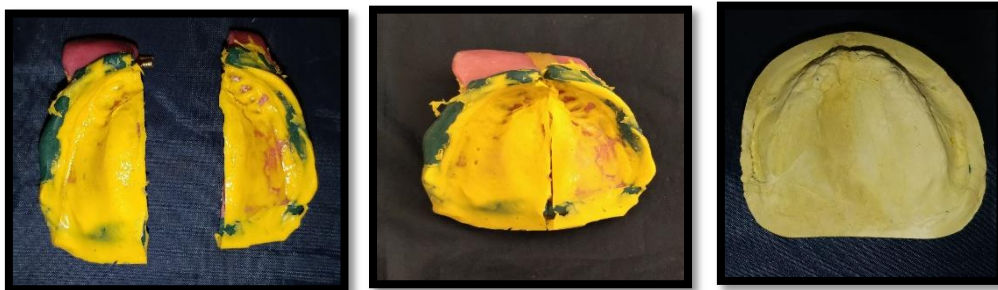


Fig. (4a) Maxillary border molding, final impression and master cast




Fig. (4b) Mandibular border molding, final impression and master cast



Fig. (5) Collapsible baseplates with stainless steel hinge




Fig. (6) Mounting of occlusal rims

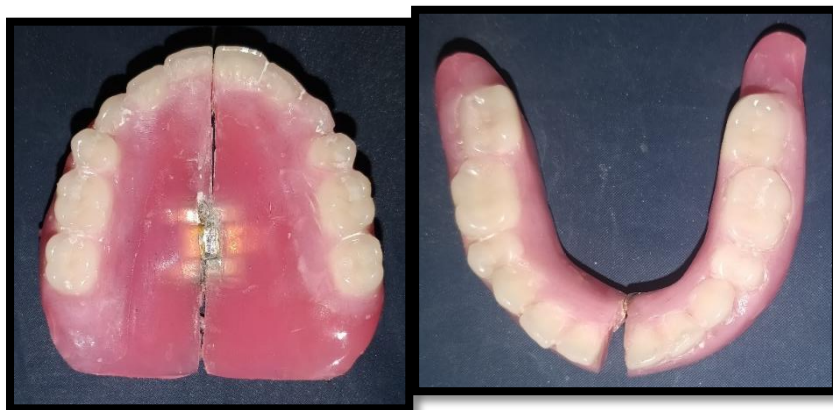

Fig. (7) Collapsible complete dentures

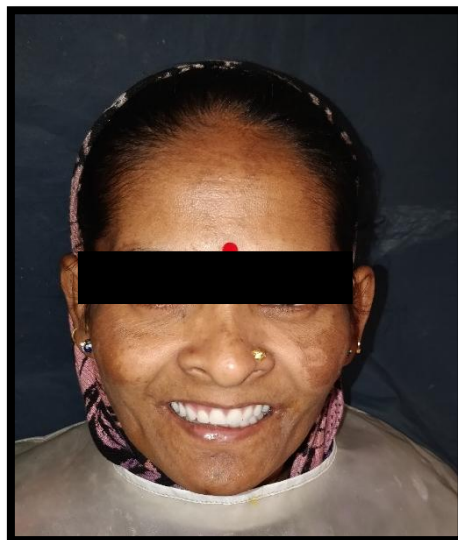

Fig. (8) Post-operative photograph

IV. Discussion

Many authors have advised sectional custom trays and collapsible denture systems with complicated attachment devices, for example, locking levers (various pins, bolts, and Lego pieces),⁵ hinges⁶, orthodontic expansion screws, magnet systems, and so forth. For the patient described here, 2 parallel pins and an acrylic resin block fitted on these pins serve as a locking mechanism. When the oral opening is limited, joining the pieces of a sectional denture base intraorally may be problematic. For this reason, we preferred to fabricate the collapsible design of maxillary and mandibular complete denture.

Oral exercises and mouth stretching as recommended by Naylor and Manor⁷ were suggested to maintain the oral aperture and enhance the flexibility of the facial skin. This was to avoid further fibrosis, which could make dental treatment impossible.

V. Conclusion

Severe reduction of oral opening renders access to the oral cavity difficult for dental procedures. The limitations of the treatment procedure and the need for continuous maintenance must be emphasized to the patient to avoid tissue ulceration and further fibrosis. This paper describes the impression procedure for a patient with restricted mouth opening using a sectional impression tray and fabrication of sectional maxillary and mandibular denture. Figure 8 presents a patient who has been wearing such prosthesis successfully for the past 2 years.

References

- [1]. Siwach S., Siwach V. An innovative design of collapsible complete denture in a patient with scleroderma: a case report. *JPFA* 2011;25:154-158.
- [2]. Sandeep Kumar, Aman Arora, and Reena Yadav. Foldable Denture: For Microstomia Patient. *Case Reports in Dentistry* 2012:1-3
- [3]. Lopez J Jr. Surgical management of microstomia in the dental office. *J Am Dent Assoc* 1978;97:840-2.
- [4]. Haas SE. Implant-supported, long-span fixed partial denture for a scleroderma patient: a clinical report. *J Prosthet Dent* 2002;87:136-9.
- [5]. S. Dhanasomboon and K. Kiatsiroj. Impression procedure for a progressive sclerosis patient: a clinical report. *JPD* 2000;83:279-282.
- [6]. C. Cura, H. S. Cotert, and A. User. Fabrication of a sectional impression tray and sectional complete denture for a patient with microstomia and trismus: a clinical report. *JPD* 2003;89:540-543.
- [7]. Naylor WP, Manor RC. Fabrication of a flexible prosthesis for the edentulous scleroderma patient with microstomia. *J Prosthet Dent* 1983;50:536-8.

Dr. Juhee Naresh Mehta, et. al. "Sectional Collapsible Complete Denture for a Patient with Microstomia: A Case Report." *IOSR Journal of Dental and Medical Sciences (IOSR-JDMS)*, 19(7), 2020, pp. 32-36.