

Flummoxed small bowel Volulus- a Case Report

Dr.Marenika, Dr.Sampath kumar, Dr.Rahul Raj

Date of Submission: 13-07-2020

Date of Acceptance: 27-07-2020

I. Background:

Intussusception is a rare form of bowel obstruction in adults which is defined as telescoping of the proximal segment of the gastrointestinal tract into the lumen of the adjacent distal segment ¹.The overall incidence of intussusception in adults is 2-3 cases per 1 million general population annually²

This article describes a case of male patient with no previous operation,no pathology of intestinal tract and no malignancy- CT reveals ileo-ileal intussusception with secondary volvulus. Exploratory laparotomy reveals gangrene bowel .Intussusception and Volvulus found approximately 10 -15cm away from ileocecalvalve.The gangrenous bowel segment resected using stapler.The patient had an uneventful recovery .

II. Case Details

- A 19-year-old male, who presented to emergency department with complaints of 2days history of Lower abdomen pain,bilious vomiting ,red currant jelly stool.

- General examination:

Patient was conscious, oriented and afebrile

Vitals - BP: 130/90 mmHg , Pulse :130/min

Abdominal examination:

Abdomen was slight distended

Diffuse tenderness

Bowel sounds absent

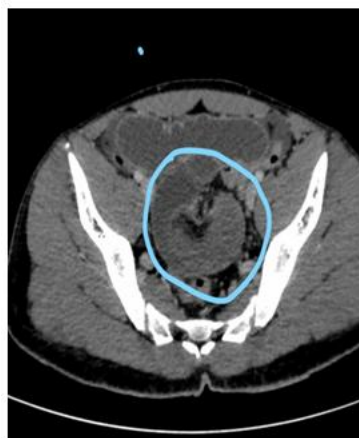Digital rectal examination:

Blood staining stool present

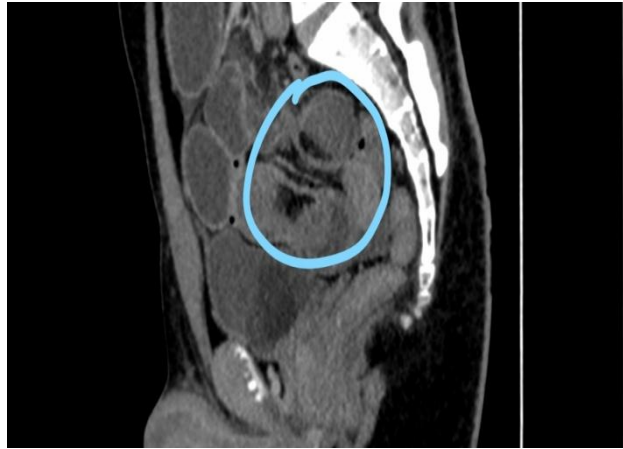
Differential diagnosis:

1. On the basis of clinical history and examination Acute appendicitis and peritonitis was ruled out. There were no features suggestive ofHence with the above clinical features and examination the diagnosis was more in favour of Intussusception.

Investigations :

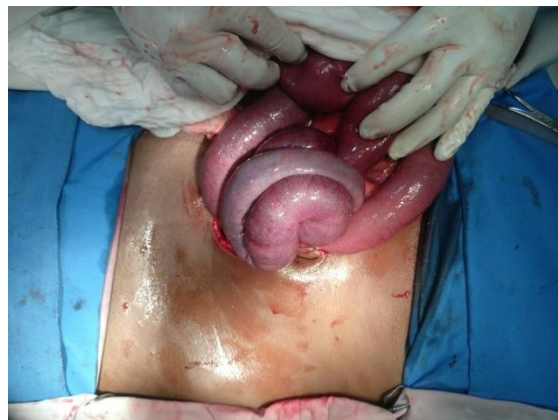

Computed tomography of abdomen and pelvis, which reveals ileoileal intussusceptions with secondary volvulus, small bowel obstructions

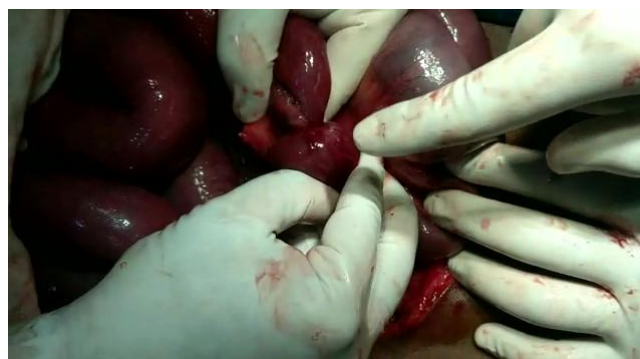

Intraoperative findings :

Gangrenous bowel ,Intussusception and Volvulus found approximately 10 -15cm away from ileocecalvalve.Bothintussusception part and intussucipiens part was Gangrenous .The Gangrenous bowel segment was resected .

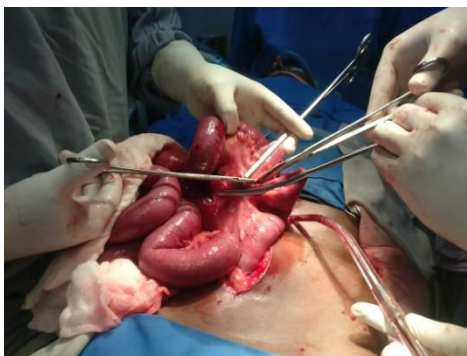

Volvulus 1



Intussusception 1

Gangrenous bowel 1



Histopathological examination of the specimen: Haemorrhagic transmural infarct .

III. Discussion

- In our case patient do not present with classical triad of abdomen pain, recurrent jelly stool and palpable abdominal mass. Diagnosis made by radiological imaging.
- Intussusception can be divided in four groups: a) tumor related, b) postoperative, c) miscellaneous (Meckel's diverticulum, celiac disease) d) idiopathic
- Although the mechanism that leads to an intussusception is still unknown, any lesion or irritation of bowel wall or lumen that desynchronizes the peristaltic waves, could provide the mechanical base for invagination of one part of the intestine into another.
- Since the existence of a tumor, polyps, Meckel diverticulum, appendiceal stump⁶
- However, one possibility is that if a lesion is present within the lumen, with the presence of food and peristaltic activity, would cause a narrowing above the stimulus and relaxation below; as a result, the lead point would telescope to the distal bowel⁷.
- The treatment of adult intussusception remain controversial depending upon whether etiology is known. There is some evidence to suggest that CT scan diagnoses does not always require further evaluation⁵.

Abdominal CT Scan is considered the best tool for the diagnosis of adult intussusceptions, as its accuracy reportedly range from 58%-100% according to various studies⁴.

- Volvulus of ileum is much less common than that occurring in the large intestine where it is most commonly seen affecting the sigmoid colon.
- Delay in diagnosis and operation greatly increase the mortality rate; Zollinger et al⁸ noted that any delay in surgery longer than 12 hours doubled the rate.

IV. Conclusion

In Intussusception, a gastrointestinal tract slides into another neighbouring portion. It's rare in adult and varies in presenting symptoms making diagnosis more difficult. The best diagnostic tool is CT scan. Surgical Resection is preferred modality of treatment in adult and should not be delayed.

References

- [1]. Barbette p. *Quevres Chirurgiques et Anatomiques*. Geneva, Switzerland: Francois Meige 1674
- [2]. Velse C. *De Mutuo Intestini Rumingress. Lugduni Batavorum*. JLuzac 1742
- [3]. Abdulaziz Almutawae et al. *Adult intussusception Bahrain Med Bull* 2016;38(4):245-246.
- [4]. Duncan L, Sandeepalsidhu et al. *Missed case of intussusceptions, a rare cause of abdominal pain in adult*. Elsevier journal 2019
- [5]. Daneman A, Navarro O (2004) *Intussusception Part 2: An update on the evolution of management*. *Pediatr Radiol* 34:97-108
- [6]. Patton KR, et al. *Intussusception of a normal appendix Am J Emerg Med* 2000;30:58-63
- [7]. Yakan S, Caliskan C, Makay O, et al. *Intussusception in Adult: Clinical Characteristic, Diagnosis and Operative Strategies*. *World J Gastroenterol* 2009;15(16):1985-9.
- [8]. Catalano O. *Transient small bowel intussusception: CT findings in adults*. *Br J Radiol*. 1997;70:805-8
- [9]. Zollinger RM, Kinsey DL, Grant GN. *Intestinal obstruction*. *postgrad Med* 1963;33:165-171.

Dr. Marenika, et. al. "Flumoxed small bowel Volulus- a Case Report." *IOSR Journal of Dental and Medical Sciences (IOSR-JDMS)*, 19(7), 2020, pp. 37-39.