

## A Simplified Technique of Fabrication of Custom Ocular Prosthesis

Dr.Aparna.P.M<sup>1</sup>, Dr. HarshaKumar.K<sup>2</sup>, Dr. R. Ravichandran<sup>3</sup>,  
Dr.Noxy George Manjuran<sup>4</sup>

<sup>1</sup>Junior Resident, Dept. of Prosthodontics, Govt. Dental College, Thiruvananthapuram

<sup>2</sup>Professor and Head, Dept. of Prosthodontics, Govt. Dental College, Thiruvananthapuram

<sup>3</sup>Professor, Dept. of Prosthodontics, Govt. Dental College, Thiruvananthapuram

<sup>4</sup>Assistant Professor, Dept. of Prosthodontics, Govt. Dental College, Thiruvananthapuram

Corresponding Author: Dr.Aparna.P.M

---

### Abstract

Trauma or disease may result in enucleation or evisceration of the eye which can have a negative effect on the quality of life. An ocular prosthesis given in such situations not only improves esthetics but also protects the eye cavity, thereby preventing infections. The combined efforts of the ophthalmologists and the maxillofacial prosthodontist can provide a cosmetically acceptable ocular prosthesis. An ocular prosthesis is either pre-fabricated or custom-made. This case report describes a simple and less time-consuming method for the fabrication of custom ocular prosthesis by selecting iris from stock eye and characterization of the scleral portion.

**Keywords:** Enucleation, Stock eye, Custom ocular prosthesis, Putty index

---

Date of Submission: 09-08-2020

Date of Acceptance: 23-08-2020

---

### I. Introduction

The loss of a part of the face, particularly the eye requires early replacement so that the patient may return to a normal life. The unfortunate loss or absence of an eye may be caused by a congenital defect, irreparable trauma, tumour, a painful blind eye, sympathetic ophthalmia or the need for histological confirmation of a suspected diagnosis.<sup>1</sup>

Loss of an eye can have a crippling effect on the physical appearance as well as the day-to-day activities of the individual concerned. The psychological effect of this loss or damage to a vital organ can far outweigh the physical effect.

Surgical procedures in the removal of an eye can be broadly classified as: evisceration (the contents of the globe are removed leaving the sclera intact), enucleation (the complete removal of the eyeball severing the muscles and the optic nerve) and exenteration (the entire contents of the orbit including the eyelids and the surrounding tissues are removed).<sup>2</sup> Not all such defects are amenable to surgical correction. In such cases, a prosthetic eye can prove beneficial. This may involve replacing the entire eye or simply an indwelling eye that replaces the outer scleral portion.

The combined efforts of the ophthalmologist and the maxillofacial prosthodontist are needed to provide a satisfactory ocular prosthesis. Indwelling eyes are made to fit precisely the confines of the ocular socket of the patient. They mainly comprise of the sclera and iris and are colored and polished to make the prosthesis look natural. They not only provide esthetics, but also protect the eye cavity, thereby preventing infections.

Techniques for making these ocular prostheses vary from simple to complicated. These eyes can be prefabricated or custom made, the latter offering better fit and esthetics.<sup>3</sup>

This article describes a simple yet time and cost-effective method of fabricating custom ocular prosthesis with iris incorporated from stock eye.

### II. Case Report

A 55-year-old female patient was referred to the Department of Prosthodontics, Government Dental College Thiruvananthapuram from the Department of Ophthalmology for the replacement of her missing right eye. The patient had a history of enucleation of right eye following a thorn prick and subsequent infection. On examination, the socket was healed and the surrounding tissues appeared normal. No inflammation was present. The muscle function of both the upper and lower eyelid seemed normal. There was adequate depth between the fornices, which could be utilized for better retention of the prosthesis. So, it was decided to replace the missing eye with a custom-made ocular prosthesis.

### **III. Method Of Fabrication Of The Ocular Prosthesis**

#### ***Impression procedure***

Silicon putty index of a stock eye was made and cast poured (Fig. 3, 4,5). This was used for making impression tray with autopolymerising clear acrylic resin. Needle cap with a patent opening was attached on to its surface which served as a handle and a channel for injecting the light body elastomeric impression material into the socket (Fig. 6). Modifications were made to achieve the correct shape and contour of the eye by reducing the overextensions. The margins were smoothed with the help of a finishing bur to prevent any irritation to the tissues inside the socket.

The tray was gently inserted into the socket and the patient was instructed to look straight and keep all facial muscles relaxed. Light body PVS impression material was injected through the inlet. It was slowly filled into the defect to prevent overfilling. A little amount flowing out through the inner canthus indicates adequate material filling of the socket. Once the impression was set, the lower eyelid was held downwards and the impression tray was removed by sliding it out from the upper eyelid (Fig.7).

The impression was checked for an accurate recording of the posterior wall, the position of palpebrae in relation to the posterior wall, and the greatest extent of superior and inferior fornices of the palpebrae denoting precise impression.

#### ***Fabrication of wax pattern***

A silicone putty index was made of the impression (Fig.8). Once set, an incision was made on the sides of the mould with a sharp scalpel. The mould was spread apart and the impression tray was removed and modelling wax was flown through it for the fabrication of scleral wax pattern (Fig. 9). On hardening, the wax pattern was gently retrieved, contoured and smoothed with the help of a carver and gauze (Fig. 10).

The tissue/fitting surface of the wax pattern was not manipulated at this stage. The wax pattern was then tried in the patient's eye for fit, comfort, bulkiness of the pattern and drape and mobility of the eyelids. Necessary adjustments were made. Corneal prominence was checked by standing behind the patient, retracting her eyelids and making her look downward.

#### ***Attaching the iris***

A stock eye with iris matching closely with the patient's contralateral eye was selected. Iris was carefully trimmed out from the stock eye and was positioned in the wax pattern to replicate the 'normal gaze position'. The patient was made to look slightly medial and downward at this stage. Positioning was done by trial and error method. The position of the iris was checked and verified by standing behind the patient and in front, about 9 feet away (Fig. 11, 12).

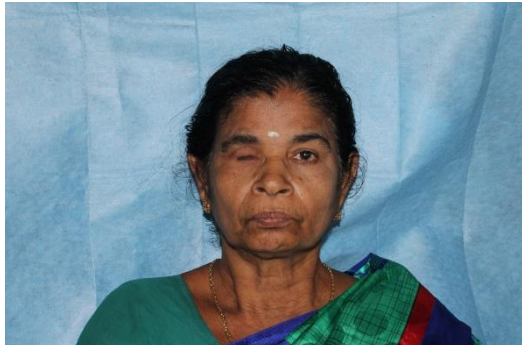#### ***Investing, dewaxing, and packing***

The investment of wax pattern was done in three-piece flask using dental stone. A needle cap was attached to the iris disc of wax pattern for proper orientation of the iris disk after the dewaxing procedure (Fig. 13). After dewaxing, clear heat cure acrylic resin powder was mixed with tooth coloured acrylic in different proportions to match the colour of sclera of contralateral eye and was packed and acrylicised following long curing cycle. The processed ocular prosthesis was retrieved, finished, and reduced at about 1mm on the external surface (Fig.15).

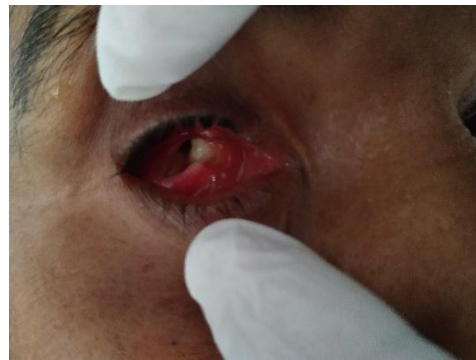#### ***Characterisation of scleral portion***

The characterization of the scleral shell was done using suitable stains in the presence of the patient and was matched with the contralateral eye. Red nylon fibres resembling blood vessels were added to give it a natural look. After colour matching, the acrylic shell was packed with clear acrylic resin and was subsequently cured again. The prosthesis was retrieved, finished and margins were rounded off. It was polished using buff and pumice to give it a natural glossy finish.

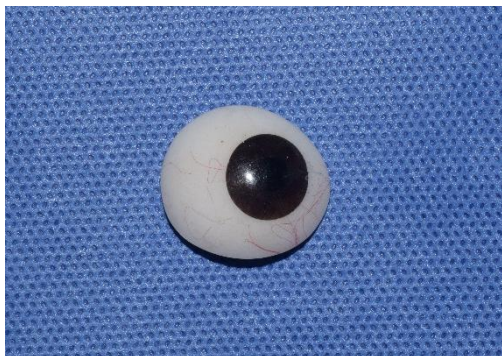The final ocular prosthesis was tried in the socket (Fig.16). Home care instructions regarding the insertion and removal of the prosthesis, proper care and hygiene were imparted to the patient. Follow-up evaluation was performed once in three months, and the prosthesis was found to be functioning well.



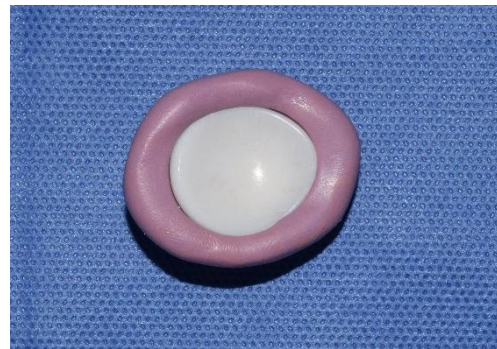**Fig 1: Pre-operative view**



**Fig 2: Enucleated right eye**



**Fig 3: Stock eye**



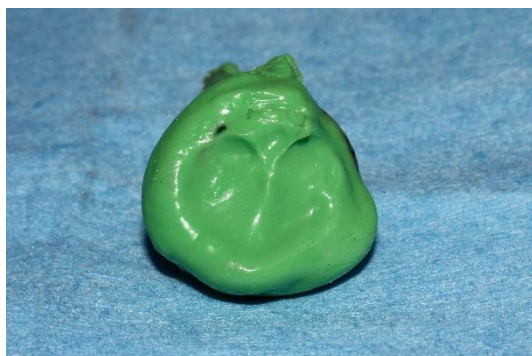**Fig 4: Putty Index**



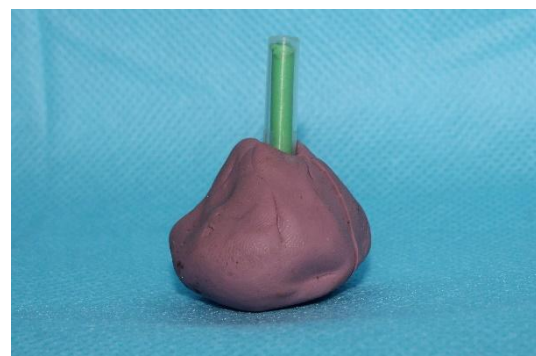
**Fig 5: Die stone mould**



**Fig 6: Acrylic stock tray**

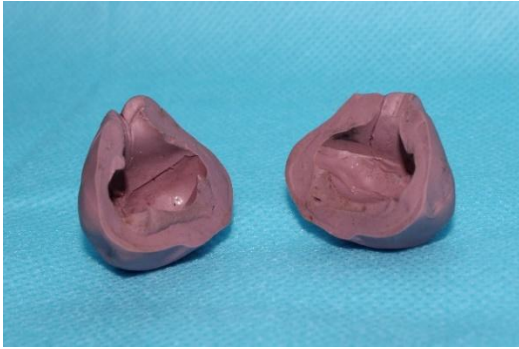


**Fig 7: Impression of eye socket**



**Fig 8: Putty index of impression**

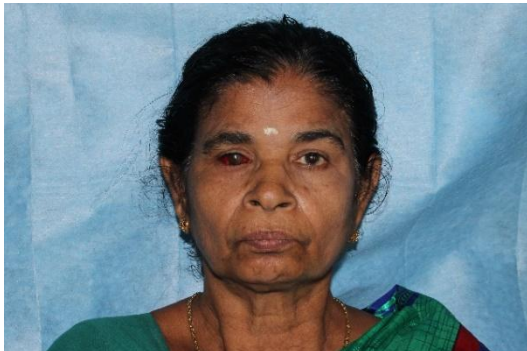



**Fig 9: Opened putty index**



**Fig 10: Wax pattern**



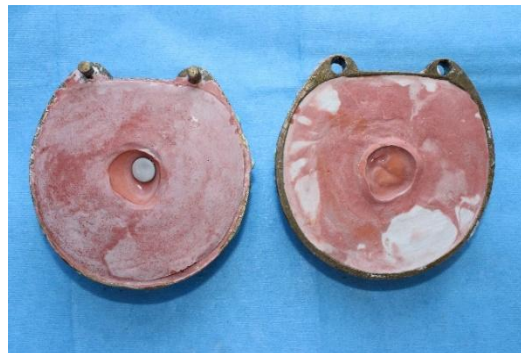**Fig 11: Iris positioned**



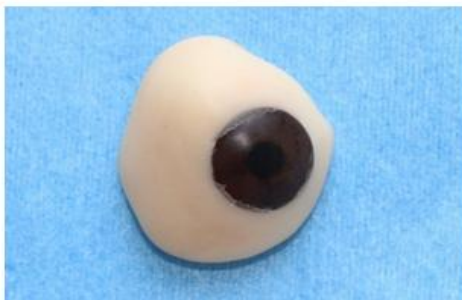**Fig 12: Completed wax pattern of ocular prosthesis with iris**



**Fig 13: Needle hub positioned**



**Fig 14: After dewaxing**



**Fig 15: Finished prosthesis before characterisation**



**Fig 16: Post insertion extraoral view after characterisation**

#### **IV. Discussion**

Ocular defects constitute an important maxillofacial deficiency which requires prosthetic replacement<sup>4</sup>. Surgical procedures for removal of an eye are classified by Peyman, Saunders, and Goldberg (1987) into three categories as Evisceration (where the contents of globe are removed leaving the sclera intact), Enucleation (most common where the entire eyeball is removed after severing the muscle and optic nerve) and Exenteration (where the entire contents of the orbit including eyelid and surrounding tissues are removed)<sup>5</sup>.

Two options for artificial eye prosthesis, include pre-fabricated ocular prosthesis and the custom-made prosthesis. The custom-made ocular prosthesis conforms accurately to the socket as the prosthesis fabrication is based on the existing anatomy of the patient, thus giving benefits of increased adaptation, movement of the eye ball, and the exact match of the iris position as that of the adjacent natural eye<sup>6</sup>.

According to Beumer et al.<sup>7</sup> intimate contact between the ocular prosthesis and the tissue bed is needed to distribute even pressure, so a prefabricated prosthesis should be avoided. Moreover, the voids in the prefabricated prosthesis collect mucus and debris, which can irritate mucosa and act as a potential source of infection, which are minimized in custom-made prosthesis.

Proper alignment of iris in the custom ocular prosthesis is very important for a natural appearance. Various methods have been proposed by several authors. Most of them are time consuming and not always provide the desired results. According to Benson visual judgment itself can give better results. If a closely matching iris disc is available from a prefabricated stock eye, custom ocular prosthesis can be fabricated without much time-consuming procedures. It also eliminates the very challenging iris painting procedure which requires high artistic expertise of the operator. Along with the characterization of scleral portion, the custom ocular prosthesis can be made to look like natural eye.

In this article a simple method of fabricating custom ocular prosthesis from a closely matching iris disc from stock eye with visual judgement method has been described. The characterisation of scleral portion with stains and nylon fibres simulating blood vessels with a lamination of clear acrylic further improved the cosmetic appearance. The total time required for fabrication is very less and also no special equipment are needed. One of the disadvantages is that if matching iris discs are not available this method is of no use. In such situations conventional method by iris painting will be the best alternative.

#### **V. Conclusion**

In this case report, a simple technique for the fabrication of ocular prosthesis was described. This technique is cost-effective, affordable and one which can be carried out in a small clinical setup. This method provides good results in terms of retention, aesthetics, and function. The use of an ocular prosthesis of appropriate size, colour and contour can prove to be of value functionally as well as aesthetically. It promotes physical and psychological healing for the patient and improves social acceptance.

#### **References**

- [1]. Raflo GT. Enucleation and evisceration. In: Tasmun W, Jaeger E eds. Duane's Clinical Ophthalmology, Revised edn, Vol. 5. Philadelphia: Lippincott-Raven, 1995: 1–25.
- [2]. Parr GR, Goldman BM, Rahn AO. Surgical considerations in the prosthetic treatment of ocular and orbital defects. *J Prosthet Dent* 1983;49:379-85.
- [3]. Bartlett SO, Moore DJ. Ocular prosthesis: A physiologic system. *J Prosthet Dent*. 1973;29:450–9.
- [4]. Shivji AR, Bhat S, Shetty P. Prosthodontic management of an ocular defect – a case report. *J Indian Prosthodont Soc* 2001; 1: 33–35.
- [5]. Allen L, Webster HE. Modified impression method of artificial eye fitting. *Am J Ophthalmol* 1969;67:189-218
- [6]. Cain JR. Custom Ocular Prosthetic. *J Prosthet Dent*. 1982;48:690–4.
- [7]. Beumer J, editor. Maxillofacial rehabilitation-prosthodontics and surgical considerations. St Louis (MO): Isiyaku Euro America Publication; 1996.

Dr. Aparna.P.M, et. al. "A Simplified Technique of Fabrication of Custom Ocular Prosthesis." *IOSR Journal of Dental and Medical Sciences (IOSR-JDMS)*, 19(8), 2020, pp. 20-24.