

Management of A Dental Patient on Bisphosphonates: All That A Dentists Needs to Know

A.GAUTHAM¹, DEEPAK BABY², BABITHA THOMAS³, ISMAIL P.M⁴

¹Post Graduate student, Dept. of Conservative Dentistry & Endodontics, PSM Dental College, Akkikavu, Thrissur, Kerala.

²Professor and Head of the Department, Dept. of Conservative Dentistry & Endodontics, PSM Dental College, Akkikavu, Thrissur, Kerala.

³Post Graduate student, Dept. of Conservative Dentistry & Endodontics, PSM Dental College, Akkikavu, Thrissur, Kerala.

⁴Post Graduate student, Dept. of Conservative Dentistry & Endodontics, PSM Dental College, Akkikavu, Thrissur, Kerala.

Abstract:

The aim of this review is to give an update on the protocols to be followed by the dentists for dental procedures for patients on bisphosphonate therapy. Presently there is an increasing prevalence of patients receiving bisphosphonate therapy. This review has included the pathological effects on alveolar bone, epithelium, variations in healing time, angiogenesis, and the risk factors associated with Bisphosphonate related osteonecrosis of the jaw (BRONJ) development. The consensus management protocols as recommended by experts is presented comprehensively. It is envisaged that dental practitioners should have a better understanding of bisphosphonate therapy and the complications associated with various dental procedures so as to enable them to render care with confidence and to improve the quality of life of their patients on bisphosphonate therapy.

Key words: Bisphosphonates, BRONJ, tooth extraction, tooth implants, prevention of BRONJ

Date of Submission: 16-08-2020

Date of Acceptance: 02-09-2020

I. Introduction

With increasing life expectancy, dentists come across many patients with dental problems who take bisphosphonate therapy (BP). BP are group of drugs which are used in skeletal conditions like osteoporosis, osteopenia, Paget's disease, multiple myeloma and metastatic cancer. Patients on BP, when they undergo tooth extraction, placement of implants, maxillofacial surgery and those with periodontal diseases are more prone to develop Bisphosphonate related osteonecrosis of the jaw (BRONJ). This is a serious problem both clinically as well as legally and hence it is imperative for all the dentists to know the pathological effect of BP on oral cavity and treatment protocols in a patient on BP.

II. Bisphosphonates in brief

Bisphosphonates (BP) are stable structural analogs of pyrophosphates and suppress the activity of osteoclasts which leads to reduced bone resorption which are deposited in bone surface in the first few minutes of uptake. The unbound BP are removed renally^{1,2}. BP can be classified into 3 generations:

First generation: They are non-nitrogen containing BP. Etidronate, Clodronate and tiludronate

Second generation: They are alkyl amino nitrogen containing BP. Alendronate, Ibandronate and Pamidronate

Third generation: They are heterocyclic nitrogen containing BP. Minodronic acid, Risdrionate and Zoledronic acid.

Side effects of BP: Nausea, epigastric pain, oesophagitis and gastric ulcer^{3,4}

Myalgia, arthralgia, low grade fever, headache, bone pain due to acute phase response occur during the first 24 hours after IV BP⁵.

Atrial fibrillation has also been reported^{6,7}.

Oesophageal and gastric cancer⁸, Uveitis, Scleritis and Orbital inflammatory diseases^{9,10}, Atypical proximal femoral fracture¹¹ has also been reported after long duration of BP.

III. Pathophysiology of the effects of BP in oral cavity

Effect of BP on alveolar bone:

After the administration of both oral and IV BP, a large amount of the drug is deposited in the maxillofacial bones¹². In the jaw, the bone undergoes high turnover modelling to maintain biomechanical competence and this is accelerated after tooth extraction¹³. The greater the turnover of the bone, the greater the amount of BP deposited¹⁴. The mandibular alveolar bone turnover rate is higher when compared to the other bones in the maxillofacial region and this explains the increased incidence of BRONJ in the mandibular molar areas. The BP deposited, decreases the osteoblast and osteoclast recruitment. There is a decrease in osteoclast adhesion, inhibition of osteoclast differentiation, osteoclast apoptosis, empty lacunae, the absence of matrix and presence of unorganised fibrillar structures¹⁵. This decreases bone resorption and reduces the new bone multicellular units. This induces bone matrix necrosis¹⁶. The alveolar bone matrix loses the required regenerative ability following tooth extraction, thereby predisposing the bone to necrosis when trauma is applied¹⁷.

Effect of BP on oral epithelium:

Dental extraction or other intraoral trauma release BPs locally from the adjacent injured bone, thereby exposing oral epithelial cells to the adverse effects of BPs¹⁸. BPs is directly toxic to epithelial cells and inhibit the proliferation of adjacent epithelial cells¹⁹. BPs also reduces sacroglycan and integrin transmembrane proteins, which are necessary for cell and cell matrix adhesion²⁰. This results in delay of soft tissue healing²¹. BPs decreases P63 positive basal epithelial progenitor, which is necessary for initiation of epithelial stratification during the development and maintenance of basal keratinocytes²². BPs block collagen expression by oral fibroblasts and cause delay in oral soft tissue healing²³. Apoptosis of epithelial cells is also increased by the BPs²⁴.

Effect of BP on angiogenesis:

The major cause of delay in healing after tooth extraction is due to ischemic changes in the vascular bed. BP inhibits angiogenesis by interacting with vascular endothelial growth factor (VEGF) and inhibits endothelial cell function leading to avascular necrosis²⁵. Low doses of BP inhibit the differentiation of endothelial progenitor cells, while high doses induce apoptosis of these cells²⁶. BP decreases the serum level of VEGF and other cytokines like IL-17, which are involved in angiogenesis²⁷. Endothelial cell proliferation and pro-angiogenic factors such as fibroblast- growth factor 2 (FGF2) are inhibited²⁸.

Infection, inflammation and wound healing in patients on BP:

Prolonged exposure of the underlying bone after tooth extraction in patients on BP, expose to oral microorganisms²⁹, like *Actinomyces*, *Eibonella* and *Moraxella*, which are common organisms implicated in BRONJ. Pre – existing inflammatory dental disease such as periodontitis and periapical pathology aggravates the colonisation of bacteria and increases the incidence of BRONJ. Teeth that are extracted because of pre-existing periodontal or periapical disease are associated with tooth infection and inflammation³⁰. Keratinocyte Growth Factor (KGF) in the gingival fibroblast play an important role in epithelial wound healing. Bacterial infection in periodontal diseases decrease KGF and cause delay in wound healing³¹. Wound healing is longer in patients receiving BP. The mean healing time for patients with BP is 5 weeks, compared to 2 weeks without BP³². Corticosteroids suppresses osteoblasts, increase apoptosis of osteoclasts, osteoblasts and osteocytes and increased bioavailability of concurrently used BPs³³ and increase the risk of BRONJ.

IV. BP and BRONJ

BRONJ (as defined by the American Society For Bone and Mineral Research) is an exposed area of bone in the upper and lower jaw, in the maxillofacial region, which does not resolve within 8 weeks after diagnosis in a patient taking BP, who has not received radiation therapy in the maxillofacial region³⁴. BP gets highly concentrated in jaw because of high vascularity. BP has an antiangiogenic effect and hence aggravate ischemia. The cytotoxic effect of BP on osteoclasts and periodontal ligament cells suppress bone marrow turnover^{35,36}

Prevalence: 0 – 28% in patients receiving nitrogen containing BP³⁷
4% chances on patients on oral BP³⁸

Dental extraction and trauma trigger BRONJ in 64%³⁹

Periodontitis accompanies 84% of BRONJ⁴⁰

The incidence of BRONJ in patients with malignant diseases on BP range from about 1 to 21%⁴¹

Mandible is more affected than the maxilla (2:1 ratio)

V. Clinical signs,symptoms and treatment

The traditional sign is exposed necrotic bone. The symptoms include pain in the tooth, bone purulence, swelling, fistula and sinus in the affected jaw, teeth mobility, trismus, nonhealing extraction sockets, ulcer in soft tissue and gross deformation in lower jaw. The American Association of Oral and Faciomaxillary Surgeons has staged BRONJ.

- **At risk category:** Here there is no exposed necrotic bone. These patients do not require treatment⁴². Patient should be educated regarding the risks of BRONJ. Periodic follow-up and radiological check-ups should be done.

- **Stage 0:** Non-specific clinical findings and symptoms like mandibular pain, with no clinical evidence of exposed bone. Treatment is mainly medical treatment and management of local risk factors. Medical treatment include antiseptic, analgesic, antibiotics and antiphlogostic treatment. Low level laser therapy can help⁴³.

A careful follow up is necessary.

- **Stage 1:** Exposed/ necrotic bone in asymptomatic patients with no evidence of infection. The exposed and necrotic bone or fistulae should be rinsed with antiseptic fluids and cover with adhesive paste 3 times a day. If there is no healing after 8 weeks, surgical debridement should be done⁴⁴.

- **Stage 2:** Exposed/ necrotic bone associated with evidence of infection, such as pain and erythema in the area of exposed bone, with or without pus drainage. Treatment is conservative surgical debridement after 2 weeks of antibiotics and antiphlogostic treatment⁴⁵.

- **Stage 3:** Exposed/ necrotic bone with pain, infection along with any one of the following – pathological fracture, extraoral fistula or osteolysis extending to the inferior border or sinus floor. Treatment is marginal or segmental osteotomies⁴⁶. Invasive surgery must be done only if it would improve the quality of patient's life. If the general condition of the patient is poor for invasive surgery or if patient rejects surgery, conservative approach to control symptoms and osteonecrosis progression must be done⁴⁵.

VI. Risk categorization of patients in BP

- **Low risk patients:** Patients on oral BP for less than 4 years with no other co- morbid conditions.

- **Moderate risk patients:** Patients on oral BP for more than 4 years⁴⁷, smokers⁴⁸, patients with very poor oral hygiene, anaemia and diabetes^{49,50,51}. Concomitant corticosteroids both oral and IV. Patients taking 7.5 mg of prednisolone daily for more than 3 months are at increased risk⁵². Patients on antiangiogenic drugs like Axitinib and Bevacizumab.

- **High risk patients:** Patients on treatment for cancer, regardless of the route of BP administrations should be considered as high risk⁵³. Those with previous history of BRONJ and those on second and third generation BP are at very high risk. Patients on single nucleotide polymorphism in the RBMS3 gene (genetic predisposition) are more prone for BRONJ⁵⁴. Age greater than 65 years and patients with Tori and other bony exostosis are also considered as high risk.

VII. Prevention protocol for BRONJ on patients on BP

- Establishment of good oral hygiene before dental procedures.
- Extraction of non-restorable teeth and teeth with poor prognosis before initiation of BP
- BP holiday: In high risk cases, a three months drug withdrawal prior to the procedure and cessation of the drugs until wound healing has been advocated.
- Pre-procedure antibiotics in moderate and high-risk cases.
- Cessation or reduction of corticosteroids
- Active treatment of oral infection if any.

VIII. Counselling for patients before taken for procedure

Dentist should inform the following to the patients on oral bisphosphonates before the procedure.

- There is a very low risk of developing BRONJ after the procedure. The approximate risk is estimated at 0.7 cases per 100000 persons – year exposure.
- There are ways to minimize the risk, but not to eliminate the already low risk.
- Good oral hygiene along with regular dental care is the best way to lower the risk.
- There are no diagnostic techniques to identify those at increased risk of developing BRONJ.
- The patient should be informed about the dental treatment needed, alternative treatments, how any treatment relates to the risk of BRONJ, other risks associated with various treatment options and the risk of foregoing treatment, even temporarily.
- The patient should be encouraged to consult with his or her treating physician about other health risks associated with the procedure.

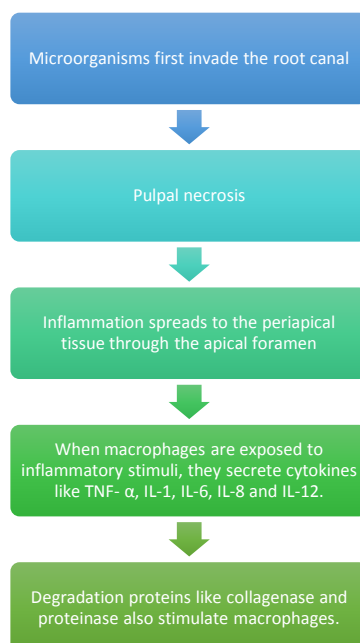
Patient should have all their doubt clarified to the maximum extent possible before the procedure. The dentist must document the discussion of risks, benefits and treatment options with patient and obtain written acknowledgement of the discussion and get written consent for the chosen course of treatment.

IX. BP and its implication in endodontics

In endodontic infection, microorganisms first invade the root canal and this leads to pulpal necrosis. Inflammation then spreads to the periapical tissue through the apical foramen. When macrophages are exposed to inflammatory stimuli, they secrete cytokines like TNF- α , IL-1, IL-6, IL-8 and IL-12. The degradation proteins like collagenase and proteinase also stimulate macrophages⁵⁵. Further, bacterial endotoxins activate the compliment system. The compliment components interact with variety of receptors on macrophages, leading to the modulation of cytokine production and inflammatory response. This provoke the differentiation of macrophages to osteoclasts. Osteoclasts increase bone resorption⁵⁶. BP is a specific inhibitor of functioning osteoclasts⁵⁷ and hence inhibit the resorption of bone by osteoclasts and inhibits bone remodelling. (FIGURE 1)

Also they interfere with healing of periapical lesions⁵⁸. BP delay healing of extraction sockets⁵⁹. This predisposes to infection and may lead to BRONJ. Hence dental extraction could be delayed or even avoided by performing root anal treatment. Root canal therapy eliminate infection and prevent from infiltration to periapical tissue⁶⁰. In a study⁶⁰, healing rate of periapical tissue taking BP and those without BP showed a healing rate of 73.5% and 81.6% respectively. In another study⁶¹, effect of IV Zolendronate on the clinical and radiographic success of nonsurgical root canal treatment was studied. The results showed that patient who are on BP for more than 1 year has less success rate. RCT can trigger the process of BRONJ through soft tissue damage, especially during application of rubber dam, apical extrusion of debris during cleaning and shaping of root canal⁶².

Patel and saberi⁶³ described a case series of external cervical resorption in patient taking BP, where no other possible cause of resorption was present. Their findings are that acute phase response to amino containing BP initiates external cervical resorption in teeth. Animal studies show that the superficial application of Zolendronate and Alendronate reduce replacement root resorption in intentionally replanted teeth⁶⁴. Low dose of alendronate inhibits the receptor activation of nuclear factor Kappa Beta ligands [RANKL] of generated osteoclasts without cytotoxic influences⁶⁵. In open apex teeth with pulpal necrosis, the new concept of treatment is 'revascularisation'⁶⁶. Here the root canal system is disinfected first. Then intracanal bleeding is induced through the apical foramen. This creates a suitable environment for endogenous mesenchymal stem cells to differentiate to several types of odontogenic cells and complete root canal maturity. Induction of intracanalicular bleeding trigger BRONJ. Hence the treatment of choice in this condition is apexification or apexogenesis.



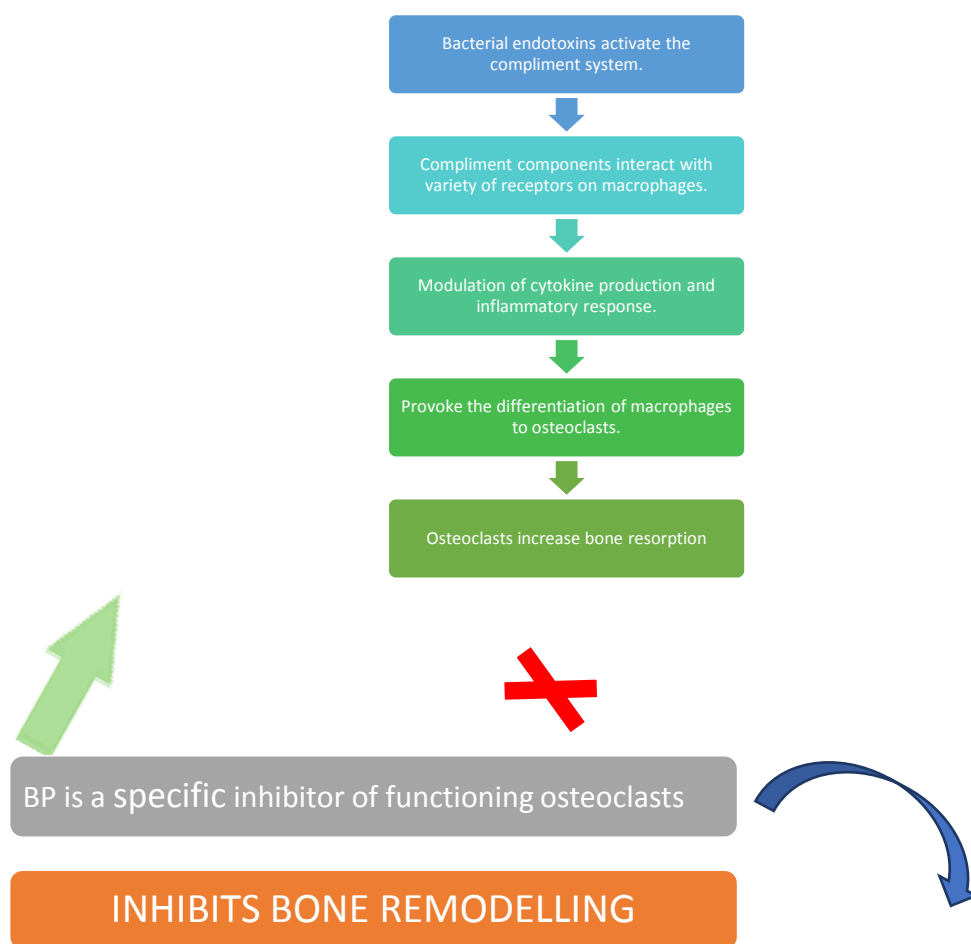


FIGURE 1: BP AND ITS IMPLICATION IN ENDODONTICS

X. Clinical recommendations in endodontic procedure

- Endodontic treatment is preferable to surgical treatment if a tooth is salvageable.
- Any procedure should be started with Chlorhexidine mouthrinse for one minute.
- This reduces the number of microorganisms in the oral cavity⁶⁷ and reduces the chances of bacteremia that may be present due to soft tissue trauma.
- BP has anti-angiogenic effects⁶⁸.
- Hence using anaesthetic agents with vasoconstriction effects has to be avoided as it increases the risk of inadequate vascularisation⁶⁹.
- Rubber band application must be done with almost care to prevent soft tissue trauma⁷⁰.
- Strict aseptic environments should be ensured during the procedure.
- The tooth and rubber dam must be disinfected with a suitable disinfecting solution for 2 minutes⁷¹.
- Manipulation beyond the apex should be avoided. Avoid patency of the apical foramen, which can increase the possibility of bacteremia from extruded debris. Hence it is recommended to use electronic apex locators during cleaning and shaping to maintain files at apical constriction and prevent it from apical extrusion⁷².
- Nickel Titanium rotary systems are preferred. Avoid reciprocating systems during shaping of root canal due to more risk of extrusion of debris⁷³.
- Obturation should be done with minimal risk of overfilling and overextension, to increase the efficiency of root canal treatment⁷⁴ and reduce the possibility of periapical irritation⁷⁵.
- The cold lateral compaction technique is preferred over warm root filling techniques⁷⁶.
- The use of prophylactic antibiotics in patients on BP before a nonsurgical root canal treatment has remained a controversy⁷⁷. Patients who are on IV BP with necrotic pulps, oral BP for more than 3 years and several teeth requiring root canal treatment are preferably put on systemic antibiotics^{71,78,79}.

XI. Tooth extraction in a patient on BP

In **low risk patients**, extraction can be carried out, after getting informed and written consent from the patient explaining the risks. A thorough mouth wash with 0.12 to 0.2% chlorhexidine should be done before tooth extraction. The removal of tooth must be done with least trauma to the soft tissue. If the treatment plan involves the medullary bone and or periosteum involving multiple sextants, then the dentist should treat one sextant or one tooth at a time if possible. The dentist should allow a two months disease free follow up, treating the patients with antimicrobials, before other sextants are treated with similar therapy. Primary closure of extraction wound should not be considered a must^{80,81}. Tooth extraction can be performed without the detachment of full thickness flaps, and the socket should be filled with absorbable gelatin sponge haemostatic including suture placement, so as to allow wound healing through secondary intention. If a sharp socket wall margin or interradicular bone are observed, they should be reduced selectively without lifting the periosteum from bone. Surgical antibiotic prophylaxis is needed only for selected patients. If antibiotic prophylaxis is needed, it is ideal to start on phenoxymethylpenicillin 500 mg 4 times per day. If patient is penicillin allergic, doxycycline 100mg once daily is suitable. Metrodinazole 200mg 3 times a day can also be used in high risk patients. Oral antibiotics should be given one hour prior to the procedure. After extraction of tooth weekly review is mandatory. If there is debris in the socket, it has to be irrigated with saline or chlorhexidine only. Follow up is needed for 3 to 4 weeks for symptoms of BRONJ. Pain, *fetor oris* and bad taste are few presenting symptoms of post-extraction BRONJ.

In patients with **medium risks**, i.e., patients with associated risk factors, the risk factors have to be reduced and later tooth extraction must be done after getting informed consent.

In patients with **high risks**, first the patients must be assessed whether tooth extraction can be avoided. If tooth extraction can be avoided, other treatment modalities like endodontic treatment has to be considered. If tooth extraction is absolutely necessary, tooth extraction must be done after getting written consent, explaining all the risks of BRONJ, along with adjunctive treatment. Cancer patients receiving IV BP must receive plasma rich growth factors during tooth extraction to shorten healing time⁸². After tooth extraction, patient should be reviewed weekly for 3- 4 weeks. If debris is present in the socket irrigate with saline or chlorhexidine only. If healing of the socket does not take place within 3-4 weeks, closely follow up for BRONJ. If the bone is exposed at 6-8 weeks, treatment for BRONJ has to started.

XII. Implant treatment for a patient on BP

Implant placement requires the preparation of osteotomy sites. Hence patients on BP requiring extensive implants and guided bone regeneration to augment the deficient alveolar ridge before implant placement are at increased risk of BRONJ. Hence dentist must first discuss with the patients about the risks, benefits and treatment alternatives available. Individuals who have been taking BP for less than four years and have no risk factors (**low risk**), there is no need for alteration of treatment plan⁸³. For patients taking oral BP for less than four years and is taking corticosteroids or antiangiogenic drugs concomitantly (**moderate risk**), discontinuation of BP for two months prior to the surgery must be done (drug holiday). Treatment can be started after two months, but BP should be started only after osseous healing has occurred. In **high risk patients** implants should be avoided.

A fully written informed consent must be obtained before the procedure. Patient should be stressed about the need of maintaining strict oral hygiene and any oral infection if present must be actively treated. Patients should be scheduled for a prophylaxis/Periodontal Maintenance Therapy (PMT) with the hygienist and oral rinse containing chlorhexidine to be started at least one week prior to surgery. Assuming no Penicillin allergy, the patient should start on Augmentin 500 mg (four times per day) starting 48 hours prior to scheduled surgery⁸⁴.

As per Expert panel recommendations American Dental Association Council on Scientific Affairs, maintenance of the implants must follow accepted mechanical and pharmaceutical methods to prevent peri-implantitis. Patients must be kept under weekly follow-up. If features of peri-implantitis appears, active antibiotic treatment must be started. If peri-implantitis does not resolve with routine antibiotic therapy, surgical revision of soft tissues around the implants may be needed. If needed modest bone recontouring may be considered. If signs of infection still persist, initiation of treatment of BRONJ must be started.

XIII. Restorative dentistry and prosthodontics procedures in patients on BP

All routine restorative procedures can be carried out. There is no evidence that malocclusion or masticatory forces increase the risk of developing BRONJ. All prosthodontic appliances in patients taking an oral bisphosphonate should be adjusted for fit as needed.

XIV. Maxio-facial surgery in patients on BP

If bone surgery are necessary, conservative surgical techniques with primary tissue closure must be considered. Chlorhexidine rinse should be started before the procedure and continued for two times per day for two months after surgery. Prophylactic antibiotics though not mandatory, clinicians can start it depending on the patients concomitant risk factors like prolonged BP, old age. use of steroids etc..

XV. BP and periodontal diseases

A patient on BP, with mild periodontal disease routine treatment can be carried out without modification, because BP is actually beneficial in modulating the host response for management of periodontal diseases^{85,86}. If the patient on BP is having destructive periodontal disease, they should receive appropriate non - surgical therapy along with prolonged phase of initial therapy. In spite of these measures, if the disease doesn't resolve, surgical treatment should be aimed primarily at obtaining access to root surface with modest bone recontouring. Guided bone regeneration or tissue regeneration must be considered, in view of fact that BP reduces vascularity of tissues⁸⁷.

XVI. Conclusion

A patient's chances of developing BRONJ resulting from dental procedures is due to the compromised healing status of the hard and soft tissues of the jaws, and is also determined by significant risk factors, such as oral hygiene status, periodontal disease and systemic conditions. A thorough pre-operative risk assessment and clinical examination should be done before the procedure. The need for antibiotic prophylaxis must also be considered before the procedure. A complete and detailed discussion regarding the complication must be done with the patient and the patient's physician. This will help the dental practitioner to judiciously plan and perform dental procedures on patients undergoing BP therapy.

Reference

- [1]. Reyes C, Hitz M, Prieto-Alhambra D, Abrahamsen B. Risks and benefits of bisphosphonate therapies. *J Cell Biochem* 2016;117: 20-28.
- [2]. Compston J, Cooper A, Cooper C, Gittoes N, Gregson C, Harvey N, Hope S, Kanis JA, McCloskey EV, Poole KE, Reid DM. UK clinical guideline for the prevention and treatment of osteoporosis. *Archives of osteoporosis*. 2017 Dec 1;12(1):43.
- [3]. McClung M, Harris ST, Miller PD, Bauer DC, Davison KS, Dian L, et al. Bisphosphonate therapy for osteoporosis: benefits, risks, and drug holiday. *Am J Med* 2013; 126: 13-20.
- [4]. Khan M, Cheung AM, Khan AA. Drug-related adverse events of osteoporosis therapy. *Endocrinol Metab Clin North Am* 2017; 46: 181-192.
- [5]. Popp A, Senn R, Curkovic I, Senn C, Buffat H, Popp P, et al. Factors associated with acute-phase response of bisphosphonate naïve or pretreated women with osteoporosis receiving an intravenous first dose of zoledronate or ibandronate. *Osteoporos Int* 2017; 6: 1995-2002.
- [6]. Sharma A, Chatterjee S, Arbab-Zadeh A, Goyal S, Lichstein E, Ghosh J, et al. Risk of serious atrial fibrillation and stroke with use of bisphosphonates: evidence from a meta-analysis. *Chest Journal* 2013; 144: 1311-1322.
- [7]. Herrera L, Leal I, Lapi F, Schuemie M, Arcoraci V, Cipriani F, Sessa E, Vaccheri A, Piccinini C, Staniscia T, Vestri A. Risk of atrial fibrillation among bisphosphonate users: a multicenter, population-based, Italian study. *Osteoporosis International*. 2015 May 1;26(5):1499-506.
- [8]. Wright E, Schofield PT, Molokhia M. Bisphosphonates and evidence for association with esophageal and gastric cancer: a systematic review and meta-analysis. *BMJ Open* 2015; 5:e007133.
- [9]. Patel DV, Bolland M, Nisa Z, Al-Abuwsi F, Singh M, Horne A, et al. Incidence of ocular side effects with intravenous zoledronate: secondary analysis of a randomized controlled trial. *Osteoporos Int* 2015; 26: 499-503.
- [10]. Rappoport D, Leiba H. Bisphosphonates and ocular inflammation. *Harefuah* 2017; 156: 71-73.
- [11]. Nogués X, Prieto-Alhambra D, Güerri-Fernández R, García-Giralto N, Rodríguez-Morera J, Cos L, et al. Fracture during oral bisphosphonate therapy is associated with deteriorated bone material strength index. *Bone* 2017; 103: 64-69.
- [12]. Landesberg R, Woo V, Cremers S, et al. Potential pathophysiological mechanisms in osteonecrosis of the jaw. *Annals of the New York Academy of Sciences* 2011a; 1218:62-79.
- [13]. Malden N, Beltes C and Lopes V. Dental extractions and bisphosphonates: The assessment, consent and management, a proposed algorithm. *British Dental Journal* 2009; 206(2):93-98.
- [14]. Marx RE, Cilio JE Jr and Ulloa JJ. Oral bisphosphonate induced osteonecrosis: Risk factors, prediction of risk using serum CTX testing, prevention, and treatment. *Journal of Oral and Maxillofacial Surgery* 2007; 65:2397- 2410.
- [15]. Su J, Feng M, Han W and Zhao H. The effects of bisphosphonate on the remodeling of different irregular bones in mice. *Journal of Oral Pathology and Medicine* 2015; 44:638-648.
- [16]. Giannobile WV. Host-response therapeutics for periodontal diseases. *Journal of Periodontology* 2008;79:1592-1600.
- [17]. De Ponte Fs, Catalfamo L, Micali G, et al. Effect of bisphosphonates on the mandibular bone and gingival epithelium of rats without tooth extraction. *Experimental and Therapeutic Medicine* 2016; 11:1678-1684.
- [18]. Marx RE, Cilio JE Jr and Ulloa JJ. Oral bisphosphonate induced osteonecrosis: Risk factors, prediction of risk using serum CTX testing, prevention, and treatment. *Journal of Oral and Maxillofacial Surgery* 2007; 65:2397-2410.
- [19]. Reid IR, Bolland MJ and Grey AB. Is bisphosphonate associated osteonecrosis of the jaw caused by soft tissue toxicity? *Bone* 2007; 41:318-320.
- [20]. Arco A, Favalaro A, Giuffrè M, Santoro G, Speciale F and Vermiglio G. Sarcoglycans in the normal and pathological breast tissue of humans: An immunohistochemical and molecular study. *Cells Tissues Organs* 2012; 195:550-562.
- [21]. Reid IR, Bolland MJ and Grey AB. Is bisphosphonate associated osteonecrosis of the jaw caused by soft tissue toxicity? *Bone* 2007; 41:318-320.

- [22]. Senoo M, Pinto F, Crum CP and McKeon F. p63 is essential for the proliferative potential of stem cells in stratified epithelia. *Cell* 2007; 129:523-536.
- [23]. Ravosa MJ, Ning J, Liu Y and Stack MS. Bisphosphonate effects on the behaviour of oral epithelial cells and oral . *Archives of Oral Biology* 2011;56:491-498.
- [24]. Allam E, Allen M, Chu TM and Windsor LJ. In vivo effects of zoledronic acid on oral mucosal epithelial cells. *Oral Diseases* 2011; 17:291-297.
- [25]. Allen MR. The effects of bisphosphonates on jaw bone remodeling, tissue properties, and extraction healing *Odontology* 2011; 99:8-17.
- [26]. Yamada J, Tsuno NH, Kitayama J, Tsuchiya T, Yoneyama S and Asakage M. Anti-angiogenic property of zoledronic acid by inhibition of endothelial progenitor cell differentiation. *Journal of Surgical Research* 2009; 151:115-120.
- [27]. Oteri G, Allegra A, Bellomo G, Alonci A, Nastro E and Penna G. Reduced serum levels of interleukin 17 in patients with osteonecrosis of the jaw and in multiple myeloma subjects after bisphosphonates administration. *Cytokine* 2008; 43:103-104.
- [28]. Ribatti D, Maruotti N, Nico B, Longo V, Mangieri D and Vacca A. Clodronate inhibits angiogenesis invitro and in vivo. *Oncology Reports* 2008; 19:1109-1112.
- [29]. Sedghizadeh PP, Kumar SK, Gorur A, Schaudinn C, Shuler CF and Costerton JW. Identification of microbial biofilms in osteonecrosis of the jaws secondary to bisphosphonate therapy. *Journal of Oral and Maxillofacial Surgery* 2008; 66:767-775.
- [30]. Aghaloo TL, Kang B, Sung EC, et al. Periodontal disease and bisphosphonates induce osteonecrosis of the jaws in the rat. *Journal of Bone and Mineral Research* 2011; 26:1871-1882.
- [31]. Mawardi H, Giro G, Kajiya M, Ohta K, Almazroo S and Alshwaimi E. A role of oral bacteria in bisphosphonate-induced osteonecrosis of the jaw. *Journal of Dental Research* 2011; 90:1339-1345.
- [32]. Migliorati CA, Saunders D, Conlon MS, Ingstad HK, Vaagen P and Palazzolo MJ. Assessing the association between bisphosphonate exposure and delayed mucosal healing after tooth extraction. *Journal of the American Dental Association* 2013; 144:406-414.
- [33]. Patschan D, Lodenkemper K and Buttgerit F. Molecular mechanisms of glucocorticoid-induced osteoporosis. *Bone* 2001; 29:498-505.
- [34]. López-Cedrún J, Sanromán J, García A, Peñarrocha M, Feijoo J, Limeres J, et al. Oral bisphosphonate-related osteonecrosis of the jaws in dental implant patients: a case series. *Br J Oral Maxillofac Surg* 2013; 51: 874-879.
- [35]. Soydan SS, Uckan S. Management of bisphosphonate-related osteonecrosis of the jaw with a platelet-rich fibrin membrane: technical report. *J Oral Maxillofac Surg* 2014; 72: 322-326.
- [36]. Williams DW, Lee C, Kim T, Yagita H, Wu H, Park S, et al. Impaired bone resorption and woven bone formation are associated with development of osteonecrosis of the jaw-like lesions by bisphosphonate and anti-receptor activator of NF- κ B ligand antibody in mice. *Am J Pathol* 2014; 184: 3084-3093.
- [37]. Sharma D, Ivanovski S, Slevin M, Hamlet S, Pop TS, Brinzaniuc K, et al. Bisphosphonate-related osteonecrosis of jaw (BRONJ): diagnostic criteria and possible pathogenic mechanisms of an unexpected anti-angiogenic side effect. *Vasc Cell* 2013; 5(1): 1
- [38]. Yoshiga D, Nakamichi I, Yamashita Y, Yamamoto N, Yamauchi K, Nogami S, et al. Prognosis factors in the treatment of bisphosphonate-related osteonecrosis of the jaw – prognostic factors in the treatment of BRONJ. *J Clin Exp Dent* 2014; 6: e22-e28.
- [39]. Grisar K, Schol M, Schoenaers J, Dormaar T, Coropciuc R, Vander Poorten V, et al. Osteoradionecrosis and medication-related osteonecrosis of the jaw: similarities and differences. *Int J Oral Maxillofac Surg* 2016; 45: 1592-1599
- [40]. Thumbigere-Math V, Michalowicz BS, Hodges JS, Tsai ML, SInson KK, Rock III L, et al. Periodontal disease as a risk factor for bisphosphonate-related osteonecrosis of the jaw. *J Periodontol* 2014; 85: 226-233.
- [41]. Hoff AO, Toth BB, Altundag K, Johnson MM, Warneke CL, Hu M, Nooka A, Sayegh G, Guameri V, Desrouleaux K, Cui J, Adamus A, Gagel RF, Hortogagyi GN 920080 Frequency and risk factors associated with osteonecrosis of the jaw in cancer patients treated with IV bisphosphonates. *J Bone Miner Res* 23: 826 – 836
- [42]. Ruggiero SL, Dodson TB, Fantasia J, Goodday R, Aghaloo T, Mehrotra B, et al. American Association of Oral and Maxillofacial Surgeons position paper on medication-related osteonecrosis of the jaw-2014 update. *J Oral Maxillofac Surg* 2014; 72: 1938-1956.
- [43]. Latifyan S, Genot M, Klasterky J. Bisphosphonate-related osteonecrosis of the jaw: a review of the potential efficacy of low-level laser therapy. *Supportive Care Cancer* 2016; 24:3687-369
- [44]. Ristow O, Otto S, Troeltzsch M, Hohlweg-Majert B, Pautke C. Treatment perspectives for medication-related osteonecrosis of the jaw (MRONJ). *J Craniomaxillofac Surg* 2015; 43: 290-293.
- [45]. Rugani P, Acham S, Kimbauer B, Truschnegg A, Obermayer- Pietsch B, Jakse N. Stage-related treatment concept of medication-related osteonecrosis of the jaw—a case series. *Clin Oral Investig* 2015; 19: 1329.
- [46]. Pompa G, Bignozzi I, Cristalli M, Quaranta A, Di Carlo S, Annibali S. Bisphosphonate and osteonecrosis of the jaw: The oral surgeon's perspective. London (UK): SAGE Publications Sage; 2012.
- [47]. Lo JC, O'Ryan FS, Gordon NP, et al. Prevalence of osteonecrosis of the jaw in patients with oral bisphosphonate exposure. *Journal of Oral and Maxillofacial Surgery* 2010; 68:243-253.
- [48]. Ruggiero SL, Dodson TB, Fantasia J, et al. American Association of Oral and Maxillofacial Surgeons. Medication-related osteonecrosis of the jaw – 2014 update. Position paper. *Journal of Oral and Maxillofacial Surgery* 2014; 72:1938-1956.
- [49]. Landesberg R, Woo V, Cremers S, et al. Potential pathophysiological mechanisms in osteonecrosis of the jaw. *Annals of the New York Academy of Sciences* 2011a; 1218:62-79.
- [50]. Saad F, Brown JE, Van Poznak C, et al. Incidence, risk factors, and outcomes of osteonecrosis of the jaw: Integrated analysis from three blinded active-controlled phase III trials in cancer patients with bone metastases. *Annals of Oncology* 2012; 23:1341-1347.
- [51]. Qi WX, Tang LN, He AN, Yao Y and Shen Z. Risk of osteonecrosis of the jaw in cancer patients receiving denosumab: A meta-analysis of seven randomized controlled trials. *International Journal of Clinical Oncology* 2014; 19:403-410.
- [52]. Landesberg R, Taxel P, Tannebaum S, Shafer D, Pendrys D and Almas K. The University of Connecticut OsteoNecrosis Numerical Scale (UCONNS): A proposed predictive index for ONJ risk assessment. Appendix. *Annals of the New York Academy of Sciences* 2011b; 1218:77-79.
- [53]. Khosla s, Burr D, Cauley J et al. Bisphosphonates associated osteonecrosis of the jaw: report of a task force of the American Society for Bone and Mineral Research. *J Bone Mineral Res* 2007; 22:1479 – 1491
- [54]. Nicoletti P, Carsos VM, Palaska PK, et al. Genome-wide pharmacogenetics of bisphosphonate- induced osteonecrosis of the jaw: The role of RBMS3. *Oncologist* 2012; 17:279-287.
- [55]. Martins VL, Caley M, O'Toole EA. Matrix metalloproteinases and epidermal wound repair. *Cell Tissue Res* 2013; 351:255-268.
- [56]. Ricucci D, Siqueira JF, Loghin S, Lin LM. Repair of extensive apical root resorption associated with apical periodontitis: radiographic and histologic observations after 25 years. *J Endod* 2014; 40: 1268-1274.
- [57]. H. Murakami, N. Takahashi, T. Sasaki et al.; A possible mechanism of specific action of bisphosphonates on osteoclasts: Tiludronate preferentially affects polarised osteoclasts having ruffled borders; *Bone*; Volume 17, Issue 2, August 1995, Pages 137-144

- [58]. Hsiao A, Glickman G, He J. A retrospective clinical andradiographic study on healing of periradicular lesions in patientstaking oral bisphosphonates. *J Endod* 2009; 35: 1525-1528.
- [59]. Hisatohikita, Ken Miyazawa, ShigemiGoto.:*Journal of Bone and Mineral Metabolism*, 27, 663 – 672, 2009
- [60]. Hsiao A, Glickman G, He J. A retrospective clinical andradiographic study on healing of periradicular lesions in patients taking oral bisphosphonates. *J Endod* 2009; 35: 1525-1528.
- [61]. Dereci Ö, Orhan EO, Irmak Ö, Ay S. The effect of the duration of intravenous zolendronate medication on the success of nonsurgical endodontic therapy: a retrospective study. *Bmc Oral Health* 2016; 16: 6-9.
- [62]. Gallego L, Junquera L, Pelaz A, Díaz-Bobes C. Rubber dam clamp trauma during endodontic treatment: a risk factorof bisphosphonate-related osteonecrosis of the jaw? *J OralMaxillofacSurg* 2011; 69: e93-e95.
- [63]. Patel S, Saberi N. External cervical resorption associated withthe use of bisphosphonates: a case series. *J Endod* 2015; 41: 742-748
- [64]. Najeeb S, Siddiqui F, Khurshid Z, Zohaib S, Zafar MS, Ansari SA. Effect of bisphosphonates on root resorption after tooth replantation. A systematic review. *Dent Traumatol* 2017; 33: 77-83.
- [65]. Martins CA, Leyhausen G, Volk J, Geurtsen W. Effects of alendronate on osteoclast formation and activity in vitro. *J Endod* 2015; 41: 45-49.
- [66]. Alrahabi MK, Ali MM. Root canal revascularization. *Saudi Med J* 2014; 35: 429-434.
- [67]. Choi SE, Kim HS. Sodium bicarbonate versus chlorhexidine mouthwash in oral care of acute leukemia patients undergoing induction chemotherapy: a randomised control trail. *Asian Nurs Res* 2012;6: 60-62
- [68]. Zhang X, Hamadeh IS, Song S,Katz J, Moreb JS, Langae TY, et al. Osteonecrosis og the Jaw in the United States Food and Drug Administration’s Adverse Event Reporting System (FAERS).*J Bone Miner Res* 2016; 31:336-340.
- [69]. Fedele S, Kumar N, Davies R, Fiske J, Greening S, Porter S.Dental management of patients at risk of osteochemonecrosisof the jaws: a critical review. *Oral Diseases* 2009; 15: 527-537.
- [70]. Gallego L, Junquera L, Pelaz A, Díaz-Bobes C. Rubber dam clamp trauma during endodontic treatment: a risk factorof bisphosphonate-related osteonecrosis of the jaw? *J Oral MaxillofacSurg* 2011; 69: e93-e95
- [71]. PARM M. Case selection and treatment planning. In: LHB KMH, editor. *Cohen’s Pathways of the Pulp*. 11th ed. Amsterdam: Elsevier Inc; 2016. p. 71-89.
- [72]. Connert T, Judenhofer MS, Hülber JM, Schell S, Mannheim JG, Pichler BJ, et al. Evaluation of the accuracy of nine electronic apex locators by using Micro-CT. *InternationalEndodontic Journal* 2018; 51: 223-232.
- [73]. Bürklein S, Schäfer E. Apically extruded debris with reciprocating single-file and full-sequence rotary instrumentation systems. *J Endod* 2012; 38: 850-852
- [74]. Vivekanandhan P, Subbiya A, Mitthra S, Karthick A.Comparison of apical debris extrusion of two rotary systems and one reciprocating system. *Journal of Conservative Dentistry* 2016; 19: 245.
- [75]. Scelza M, Linhares A, Da Silva L, Granjeiro J, Alves G. Amultiparametric assay to compare the cytotoxicity of endodontic sealers with primary human osteoblasts. *Int Endod J* 2012; 45:12-18
- [76]. Moeller L, Wenzel A, Wegge-Larsen A, Ding M, Kirkevang L. Quality of root fillings performed with two root fillingtechniques. An in vitro study using micro-CT. *Acta OdontolScand* 2013; 71: 689-696.
- [77]. Katz H. Endodontic implications of bisphosphonate-associated osteonecrosis of the jaws: a report of three cases. *J Endod* 2005; 31: 831-834
- [78]. Bermúdez-Bejarano EB, Serrera-Figallo MÁ, Gutiérrez-Corrales A, Romero-Ruiz MM, Castillo-de-Oyagüe R, Gutiérrez-PérezJL, et al. Prophylaxis and antibiotic therapy in management protocols of patients treated with oral and intravenous bisphosphonates. *J Clin Exp Dent* 2017; 9: e141.
- [79]. The American Association of Endodontists. AAE Position Statement AAE Guidance on the use of systemic antibiotics in endodontics. *J Endod* 2017; 43: 1409-14
- [80]. Malden N, Beltes C and Lopes V. Dental extractionsand bisphosphonates: The assessment, consent and management, a proposed algorithm. *British DentalJournal* 2009; 206:93-98
- [81]. Mozzati M, Arata V and Gallesio G. Tooth extraction in osteoporotic patients taking oral bisphosphonates. *Osteoporosis International* 2013; 24:1707-1712.
- [82]. Mozzati M, Arata V and Gallesio G. A dental extractionprotocol with plasma rich in growth factors (PRGF) in patients on intravenous bisphosphonate therapy: A case-control study. *Joint Bone Spine* 2011; 78:648-649.
- [83]. Ruggiero SL, Dodson TB, Fantasia J, Goodday R, AghalooT,Mehrotra B, et al. American Association of Oral and Maxillofacial Surgeons position paper on medication-related osteonecrosis of the jaw-2014 update. *J Oral Maxillofac Surg*. 2014;72:1938-56.
- [84]. How to Navigate the Complexities of Implant Treatment for Patients on Bisphosphates., by Diana Bronstein, DDS, MS, MS; Dmitriy Kravchenko, MPH; Cameron Lee, DMD, MD, PHD; MBA; Jon B. Suzuki, DDS,PhD, MBA . Oral health feature, December 2, 2016Rocha ML, Malacara JM, Sanchez-Marin FJ, Vazquez de la Torre CJ, Fajardo ME. Effects of alendronate on periodontal disease in postmenopausal women: a randomized placebo-controlled trial. *J Periodontol*2004;75:1579-85.
- [85]. Lane N, Armitage GC, Loomer P, et al. Bisphosphonate therapy improves the outcome of conventional periodontal treatment: results of a 12-month, randomized, placebo-controlled study. *J Periodontol*2005;76:1113-22.
- [86]. Fournier P, Boissier S, Filleur S, et al. Bisphosphonates inhibit angiogenesis in vitro and testosterone-stimulated vascular regrowth in the ventral prostate in castrated rats. *Cancer Res* 2002;62:6538-44.

A.GAUTHAM, et. al. “Management of A Dental Patient on Bisphosphonates: All That A Dentists Needs to Know.” *IOSR Journal of Dental and Medical Sciences (IOSR-JDMS)*, 19(8), 2020, pp. 21-29.