

## Gossypiboma Masquerading as Gastric Outlet Obstruction, A Diagnostic and Therapeutic Dilemma.

Dr. Husain Adenwala<sup>1</sup>, Dr. Ratna Chopra<sup>1</sup>, Dr. P. K. Govilla<sup>2</sup>, Dr. Satyaprakash<sup>3</sup>

<sup>1</sup>(DNB Resident, Dept. of Gen. Surgery, NDMC Medical College and Hindu Rao Hospital, Delhi, India)

<sup>1</sup>(HOD, Dept. of Gen. Surgery, NDMC Medical College and Hindu Rao Hospital, Delhi, India)

<sup>2</sup>(HOU2, Dept. of Gen. Surgery, NDMC Medical College and Hindu Rao Hospital, Delhi, India)

<sup>3</sup>(SR, Dept. of Gen. Surgery, NDMC Medical College and Hindu Rao Hospital, Delhi, India)

**Corresponding Author:** Dr. Husain Adenwala, DNB General Surgery (ORCID No. 0000-0002-2337-692X)

### Abstract -

Gossypiboma, also referred to as a "textiloma", or more broadly a Retained Foreign Object (RFO) is the technical term for surgical complications resulting from foreign materials, such as a surgical sponge, accidentally left inside a patient's body. [1] Clinical consequences may be dramatic, leading to a high rate of morbidity. The time of diagnosis is increased by poor knowledge of circumstances surrounding the occurrence of these incidents. We report a case of a gossypiboma which unfortunately lead to the death of the patient. Thus, although rare, gossypiboma should always be kept as a differential diagnosis in a patient who has undergone prior surgery who presents with vague pain or chronic lump in abdomen as this can avoid unnecessary morbidity and mortality if diagnosed early.

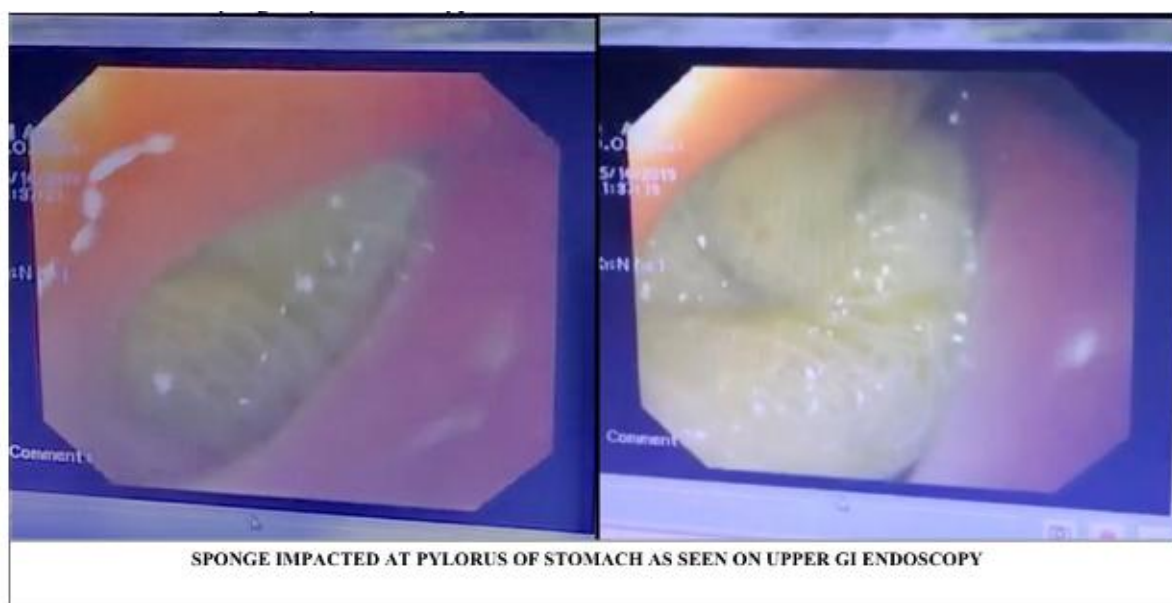
**Key words:** Gossypiboma, Textiloma, Gastric Outlet Obstruction, Giant Perforation.

Date of Submission: 18-07-2020

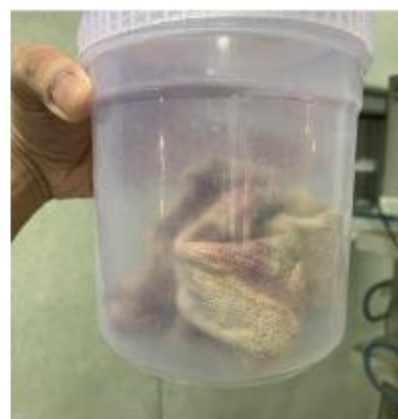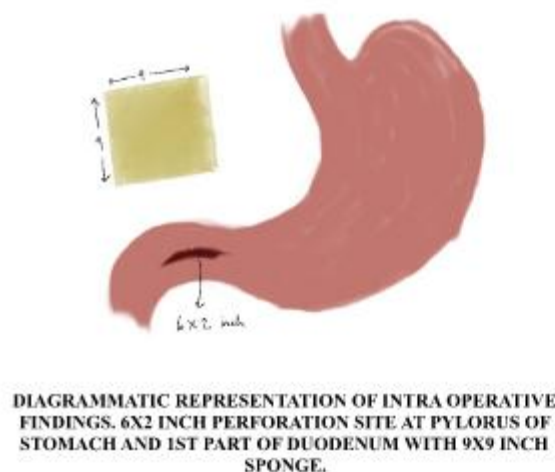
Date of Acceptance: 02-08-2020

### I. Introduction

Lady, aged 40 years, presented to our surgical emergency with the chief complaints of dull aching pain in the upper abdomen with lump in the epigastric region and multiple episodes of non-bilious vomiting for 1 month. She has a history of undergoing open cholecystectomy from another centre about 3 months prior. Patient was previously given analgesics and treatment for dyspepsia. Radiological evaluation including ultrasound and CT scan was done which was inconclusive. In view of gastric outlet obstruction, an upper GI endoscopy was done which revealed a sponge impacted at the pyloric end of stomach.



The patient was optimized and taken up for exploratory laparotomy. Intra operatively, it was discovered that a 9x9 inch surgical sponge was lying above the duodenum with two thirds of the sponge invaginated into the pyloric part of stomach and first part of duodenum with wall of fibrosis around the edge of the perforation site. Upon gentle removal of the sponge, a large perforation site of about 6x2 inch size was found which was longitudinal involving the pylorus and 1st part of duodenum. Low resection was attempted due to the close proximity of the sponge to other vital structures like the CBD and portal vein. The perforation site was repaired with omental patch grafting and repair and a drain was placed for external drainage. A feeding jejunostomy was also placed. However patient succumbed due to duodenal fistula and septicemia.



## II. Discussion

Gossypiboma (from Latin 'gossipium 'cotton and Kiswahili 'boma 'place of concealment) or retained surgical sponge is a ubiquitous medical error that is avoidable. [2] Literature search showed that the reported foreign bodies retained in the abdominal cavity include sponges, towels, artery forceps, pieces of broken instruments or irrigation sets, rubber tubes, etc. [3]

Gossypiboma is the most commonly retained foreign material in the body after surgical operation. [4][5]

The reported incidence of gossypiboma varies between 1/100 and 1/3000 for all surgical interventions and from 1/1000 to 1/1500 for intraabdominal operations. [6]

Gossypiboma is most commonly seen in cases of emergency surgery, unexpected change in the surgical procedure, disorganization (e.g., poor communication), change in surgical team or scrub nurses, hurried sponge counts, long operations, unstable patient, inexperienced staff, inadequate staff numbers, and obesity. [7]

The retained surgical sponge triggers two biological responses: aseptic fibrinous response due to foreign body granuloma or exudative reaction leading to abscess formation. [8] Gradually as the pressure increases, it may rupture toward its weaker wall, which is often the intestinal wall resulting in fistula formation, eventually pushing the surgical sponge partially into the lumen of intestine. Peristaltic waves may further withdraw the gauze completely into the lumen. [9]

Sponges may remain asymptomatic for a variable period depending on the size, site, and inflammatory response of body to it and may be detected incidentally. The longest interval of 40 years is reported in literature for clinical presentation. [10] It may also present with vague ill health, weight loss, fever with chills and rigors, altered bowel habits, anorexia, nausea, vomiting, tenesmus, diarrhea, discharging sinus, nonhealing wound, subacute or acute intestinal obstruction, malabsorption, and abdominal mass. [11]

Radiological evaluation plays an important role in the diagnosis. Plain X-ray abdomen may detect a retained surgical gauge with a radiopaque marker as a wavy or banded pattern. The radiopaque marker may be lost due to twisting, folding, or after prolonged, thus behaving like an ordinary sponge. Some centers recommend its use routinely after surgery, but this method is also not fool proof. [12] Ultrasound, computed tomography (CT) scan, and magnetic resonance imaging (MRI) are helpful in diagnosis.

As gossypiboma has been classified as "never event", prevention of such occurrences is of utmost importance. Prevention hinges on ensuring that a correct sponge count is made at the beginning and before the abdomen is closed. Sponge count is traditionally carried out manually. It is recommended that the count be made twice: at the beginning and also before closing the wound; the count should be done by at least two people. [23] Checklists in the operating theatre environment are now accepted as standard safety protocols since the 'Safe Surgery Saves Lives' Study Group at the WHO published their results. [24]

The best treatment for gossypiboma is surgical exploration. However, surgical intervention may not always be required. Spontaneous migration can occur, leading to expulsion of the foreign material through the anus during defecation,<sup>[14]</sup> through the cervix and vagina, as noticed in one of our patients or even through the urethra as we have reported above in this study. Percutaneous routes for removal of retained foreign bodies may be used where such bodies are readily accessible, but are not applicable to intra-abdominal foreign bodies. Laparoscopic methods have been used to remove left over gauze.<sup>[15][16]</sup>

Pertaining to this case, we would also like to highlight the troubles of managing a giant gastric perforation as well. Giant gastric ulcer (GGU) has been defined as an ulcer >3 cm in diameter or large enough to occupy at least one wall.<sup>[17][18]</sup> Giant gastric ulcer perforations present formidable challenges in management. The important issues that merit consideration while managing perforated GGU include exclusion of malignancy and reducing recurrence of ulcer. Partial gastrectomy is the only procedure that achieves both objectives. It demands more technical expertise and requires longer operating times and blood transfusions. The partial gastrectomy is reported to provide lower recurrence rates in the long term though the perioperative mortality was higher.<sup>[19]</sup> Omental plugging with placement of drains and feeding jejunostomy is a safe and reliable procedure.<sup>[20]</sup> It has the advantage of technical simplicity and can be performed expeditiously. Hence, omental plugging may be the preferred option in critically ill patients especially where technical expertise/facilities are limited. Despite the advances in critical care, anesthesia, and surgical techniques, the 30-day post procedure mortality of perforated peptic ulcer ranged between 16 and 26% at the best of the centers.<sup>[21][22]</sup>

Medicolegal importance -

A retained surgical sponge leads to allegations of medical negligence. This is often reported as "Res Ipsa Loquitur" meaning that "the thing speaks for itself," and that the issue at hand would not have happened if there was no negligence on the part of the surgeon. Thorough documentation is essential for the surgeon as it may absolve him partly of the responsibility. Exceptional circumstances where the surgeon could not carry out the search for the sponge without endangering the life of the patient can also be used as an argument by the operating surgeon. It must also be emphasized that despite nurse assistants being crucial members of the team, efforts to shift the blame onto them have not been accepted by the courts.<sup>[13]</sup>

### III. Conclusion

Such foreign bodies may produce a diagnostic as well therapeutic dilemma due to the operative challenges.

Hence, due to delayed diagnosis, the gossypiboma was complicated due to its invagination into the pylorus and causing further morbidity to the patient. Thus, early diagnosis and high suspicion of index can prevent severe morbidity and mortality in case of gossypiboma.

#### Abbreviations -

RFO - Retained Foreign Object  
GI - Gastrointestinal  
CT - Computed Tomography  
CBD - Common Bile Duct  
GGU - Giant Gastric Ulcer

#### Declarations -

##### Competing interests :

Authors report no conflicts of interest. None of the authors have any financial disclosures.

#### Funding :

Nil.

### References

- [1]. Kim HS, Chung TS, Suh SH, Kim SY (April 2007). "MR imaging findings of paravertebral gossypiboma". *AJNR Am J Neuroradiol.* 28 (4): 709–13.
- [2]. Kokubo T, Itai Y, Ohtomo K, Yoshikawa K, Iio M, Atomi Y. Retained surgical sponges: CT and US appearance. *Radiology.* 1987;165:415–418.
- [3]. Fair GL. Foreign bodies in abdomen causing obstruction. *Am J Surg.* 1953;86:472–475. doi: 10.1016/0002-9610(53)90465-6.
- [4]. Sun H, Chen S, Kuo C, Wang S, Kao Y. Gossypiboma: retained surgical sponge. *J Chin Med Assoc.* 2007;70(11):511–514.
- [5]. Gumus M Gumus. A serious medico-legal problem after surgery:gossypiboma. *American Journal of Forensic Medicine and Pathology.* 2012;33(1):54–57.
- [6]. Lv YX, Yu CC, Tung CF, Wu CC. Intractable duodenal ulcer caused by transmural migration of gossypiboma into the duodenum - A case report and literature review. *BMC Surg* 2014;14:36.

## Gossypiboma Masquerading as Gastric Outlet Obstruction, A Diagnostic and Therapeutic Dilemma.

- [7]. I. Lata, D. Kapoor, and G. Sahu, "Gossypiboma, a rare cause of acute abdomen: a case report and review of literature," *International Journal of Critical Illness and Injury Science*, vol. 1, no. 2, pp. 157–160, 2011.
- [8]. V. C. Gibbs, F. D. Coakley, and H. D. Reines, "Preventable errors in the operating room: retained foreign bodies after surgery—part I," *Current Problems in Surgery*, vol. 44, no. 5, pp. 281–337, 2007.
- [9]. Wattanasirichaigoon S. Transmural migration of a retained surgical sponge into the intestinal lumen: An experimental study. *J Med Assoc Thai* 1996;79:415-22.
- [10]. Kato K, Suzuki K, Sai S, Murase T, Haruta J. A case of paravesical foreign body granuloma due to surgical sponge retained for 40 years. *HinyokikaKiyō* 2000;46:491-4.
- [11]. Lata I, Kapoor D, Sahu S. Gossypiboma, a rare cause of acute abdomen: A case report and review of literature. *Int J Crit IllnInj Sci* 2011;1:157-60.
- [12]. Choi BI, Kim SH, Yu ES, Chung HS, Han MC, Kim CW. Retained surgical sponge: Diagnosis with CT and sonography. *AJR Am J Roentgenol* 1988;150:1047-50.
- [13]. Kotabagi RB. Medicolegal aspects-gossypiboma. *Med J Armed Forces India* 2011;67:397.
- [14]. Choi JW, Lee CH, Kim KA. Transmural migration of surgical sponge evacuated by defaecation : mimicking intraperitoneal gossypiboma . *Korean J Radiol.* 2006;7:212–214.
- [15]. Karahasanoglu T, Unal E, Memisoglu K, Sahinler I, Atkover G. Laparoscopic removal of a retained surgical instrument. *J LaparoendoscAdv Surg TechA.* 2004;14:241–243.
- [16]. Uramis S, Schauer C, Pfeifer J, Dagcioglu A. Laparoscopic removal of a large laparotomy pad forgotten in situ. *Surg LaparoscEndosc.* 1995;5:77–79.
- [17]. T. P. Barragry, J. W. Blatchford III, and M. O. Allen, "Giant gastric ulcers. A review of 49 cases," *Annals of Surgery*, vol. 203, no. 3, pp. 255–259, 1986.
- [18]. G. S. Raju, K. D. Bardhan, C. Royston, and J. Beresford, "Giant gastric ulcer: its natural history and outcome in the H2RA era," *American Journal of Gastroenterology*, vol. 94, no. 12, pp. 3478–3486, 1999.
- [19]. K. Tsugawa, N. Koyanagi, M. Hashizume et al., "The therapeutic strategies in performing emergency surgery for gastroduodenal ulcer perforation in 130 patients over 70 years of age," *Hepato-Gastroenterology*, vol. 48, no. 37, pp. 156–162, 2001.
- [20]. K. Jani, A. K. Saxena, and R. Vaghasia, "Omental plugging for large-sized duodenal peptic perforations: a prospective randomized study of 100 patients," *Southern Medical Journal*, vol. 99, no. 5, pp. 467–471, 2006.
- [21]. P. H. J. Hemmer, J. S. De Schipper, B. Van Etten et al., "Results of surgery for perforated gastroduodenal ulcers in a dutch population," *Digestive Surgery*, vol. 28, no. 5-6, pp. 360–366, 2012.
- [22]. D. L. Buck, M. Vester-Andersen, and M. H. Møller, "Surgical delay is a critical determinant of survival in perforated peptic ulcer," *British Journal of Surgery*, vol. 100, no. 8, pp. 1045–1049, 2013.
- [23]. Gumus M Gumus. A serious medico-legal problem after surgery:gossypiboma. *American Journal of Forensic Medicine and Pathology.* 2012;33(1):54–57.
- [24]. Haugen AS, Softeland E, Almeland SK et al. Effect of the World Health Organization checklist on patient outcomes. *Ann Surg.* 2015; 261: 821–8.

Dr. Husain Adenwala, et. al. "Gossypiboma Masquerading as Gastric Outlet Obstruction, A Diagnostic and Therapeutic Dilemma." *IOSR Journal of Dental and Medical Sciences (IOSR-JDMS)*, 19(8), 2020, pp. 38-41.