

Apocrine Carcinoma of Breast: A Case Report and Literature Review

Dr. D.P.Kavitha*, Dr. V. Soundarya¹

(*Assistant Professor, 1 Post Graduate Department of General Surgery, Coimbatore medical college hospital, Coimbatore, Tamil Nadu, India)

*Corresponding Author: Dr. V. Soundarya

Abstract:

Apocrine carcinoma is a very rare subtype of breast carcinoma, accounting to less than 1% of the affected population. It is characterized by Cells which have typical apocrine features, namely, abundant eosinophilic granular cytoplasm and prominent/multiple nucleoli. Apocrine carcinomas tend to show estrogen and progesterone receptor negativity and androgen receptor positivity (ER (-)/PR (-) /AR (+)); and expression of Gross cystic disease protein fluid-15 (GCDPF-15). We report a case of invasive apocrine carcinoma of breast as it is a very rare morphological entity.

Key word: Apocrine carcinoma, carcinoma breast, Androgen receptor, gross cystic disease protein fluid 15

Date of Submission: 01-08-2020

Date of Acceptance: 16-08-2020

I. Introduction

Breast cancer is the most common malignancy in women worldwide. Breast cancer can be classified into various subtypes based on their morphology, histological appearance and immunohistochemistry profile. Each histological subtype has a relevant prognostic implication. According to the World health organization classification, there are 21 histological subtypes. Invasive ductal carcinoma – no specific type (NST) is the most common subtype. Among the rare subtypes, there is a varied prognosis ranging from tubular carcinoma which has an indolent course to metaplastic carcinoma which has an unfavorable prognosis. A clear recommendation about the clinical management of rare subtypes is lacking. Apocrine proliferations most often are metaplasia as a component of fibrocystic change. However, the appearance of apocrine metaplasia within various breast lesions, such as papillomas, ductal adenomas, and sclerosing adenosis, may complicate their diagnosis. Distinguishing benign from malignant apocrine proliferations can be problematic owing to the nuclear characteristics of apocrine cells. This is a case report of a rare case of apocrine carcinoma of breast with literature review, presented for a better understanding of this rare entity.

II. Case Report

A 90 year old female patient presented with chief complaint of lump in her right breast that she had noted 3 months prior. It was a painless lump which gradually progressed to increase in size. There was associated history of nipple retraction. She had no family history of cancer. On physical examination, a hard and well defined lump was felt in the upper outer quadrant of right breast, with ulceration of the skin over the lump. Two hard and mobile nodes were palpable in the right axilla. Ultrasound of the breast showed a BIRADS - V hypo echoic lesion measuring 8 x 4 cm in the right breast from 2'o clock to 3'o clock position. Fine needle aspiration cytology was positive for malignant cells. Her metastatic work-up was clear. Owing to her age, significant co-morbidities and the fungating nature of the lump, she underwent a simple mastectomy and the specimen was sent for histopathological examination. Grossly the tumor was found to be multicentric, with the largest one measuring 7.5 x 3.8 cm and tumor involved the nipple areola complex and the overlying skin. Microscopically the tumor had typical apocrine features, namely, abundant eosinophilic granular cytoplasm and prominent nucleoli. The tumor was negative for estrogen receptor, progesterone receptor and Her 2-nu – triple negative. The tumor was positive for androgen receptor. Final diagnosis was given as Apocrine carcinoma of right breast – Grade II with all cut margins free from tumor.

DEPARTMENT OF PATHOLOGY
COIMBATORE MEDICAL COLLEGE HOSPITAL, COIMBATORE - 18

Lab Ref No. 180/20	NAME Vallyyannoor UNIT S5 SPECIMEN Right Simple mastectomy	AGE/SEX 70/F	Date of Report
22/11/2020 -		IP No./OP No. 787	
Cross:			
Procedure: Simple Mastectomy - Right side			
Specimen: Right breast tissue.			
Tumour site: Multicentric - central, upper and lower quadrant.			
Tumour size: 7.5x5x3.8cm (Main tumour) other tumour nodules measures 1.1x1x0.5cm, 0.2x0.4cm, 1.5x1x0.8cm			
Margins: Tumour has a cut margin clearance of 0.7cm superiorly, 0.5cm - inferiorly, 1.3cm - medially, 3.5cm - laterally. Tumour has a deep cut margin clearance of 1cm.			
Extent: Tumour involves the nipple areola complex and skin overlying tumour grossly.			
<u>Microscopy:</u>			
Histological type: Apocrine carcinoma			
Histological grade: Grade II			
Margins: Superior, Inferior, medial, lateral and deep cut margins are free from tumour.			
Extent: Tumour involves the nipple areola complex and skin overlying tumour.			
Lymphovascular invasion: not identified			
Perineural invasion: not identified			
Lymphnode status:			
Attached: pad of fat reveals 8 nodes.			
Total number of nodes involved - 8/8 (EIGHT)			
Extra capsular extension identified in 4 nodes			
IMPRESSION: APOCRINE CARCINOMA OF RIGHT BREAST- GRADE-II.			

Figure 1: Histopathology report

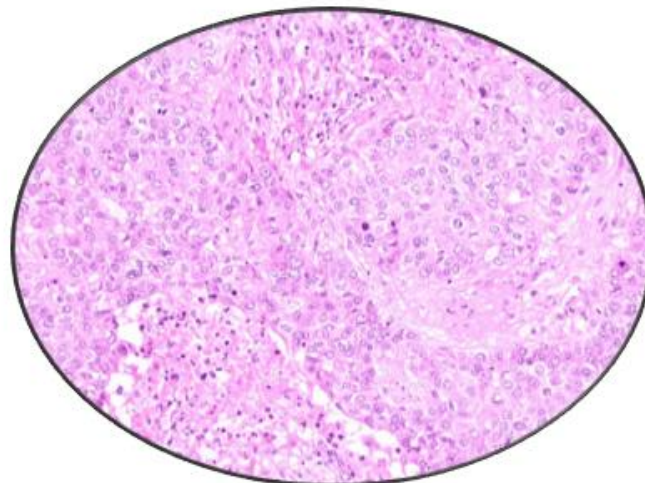


Figure 2: Histopathology slide of apocrine carcinoma breast

III. Discussion

Apocrine metaplasia often is seen in association with fibrocystic change. The incidence of infiltrating apocrine carcinoma is unclear, due to lack of clear consensus in pathological reporting and the consequent difficulty in diagnosis. Gayatri et al. included this entity under the group of “relatively rare carcinomas” [1]. Azzopardi reported an incidence of apocrine carcinoma between 0.3 and 0.4% of all breast carcinomas, Frable and Key reported 1%, Bonser et al. reported 14.5%, and Haagensen reported 62%. [2]

The origin of the apocrine cells is from the terminal duct–lobular unit [3] and not from axillary apocrine sweat glands, as Haagensen originally thought.[4] A variety of benign breast lesions may develop apocrine metaplasia, including sclerosing adenosis, ductal adenomas, nipple adenomas, intraductal papillomas, microglandular adenosis, and radial scars. Approximately 14% of fibroadenomas demonstrate apocrine metaplasia with the same appearance as apocrine metaplasia in fibrocystic change. [5]

Apocrine proliferation in breast can be classified as atypical apocrine hyperplasia, apocrine DCIS and infiltrating apocrine carcinoma. For the diagnosis of apocrine DCIS, guideline was given by Tavassoli and Norris. It required only a single duct or ductule lined by markedly atypical apocrine epithelium with necrotic debris. If there is no necrosis and the tumor has a solid or irregular cribriform or micropapillary pattern, the lesion must exceed the 2-mm quantitative criterion for DCIS. [6]

Apocrine carcinoma was first noted in 1916 by Krompecher.[7] Japaze et al., in 2005, proposed that criteria for diagnosis of apocrine carcinoma as follows:

- Apocrine features consisting of 75% of cells
- Large cells with eosinophilic granular cytoplasm
- Nucleus to cytoplasmic ratio of 1 : 2 or more
- Nucleus large, round, and vesicular may be pleomorphic
- Sharply defined borders.

Minor and nonmandatory criteria include prominent nucleoli in >50% of fields and apical cytoplasmic snouts into luminal spaces [1]. Most apocrine carcinomas are a modified Scarff-Bloom-Richardson grade 2 or 3. Whether this grade specifically correlates with behavior is not known. However, stage for stage, apocrine carcinomas have not been found to behave differently from usual ductal carcinomas. [8]

According to emerging evidence, apocrine carcinomas tend to show estrogen and progesterone receptor negativity and androgen receptor positivity.[1] Gross cystic disease fluid protein (GCDFFP)-15, is associated with apocrine carcinoma. GCDFFPs are a group of proteins ranging in size from 15,000 to 44,000kd. [9] GCDFFP-15 has been detected by immunohistochemical analysis in apocrine glands in other regions of the body, as well as in apocrine glands in the breast. Metaplastic apocrine cells and apocrine carcinoma cells have strong immunoreactivity for GCDFFP-15.[9] Tumors with immunoreactivity for GCDFFP-15 have not shown a different outcome, stage for stage, than tumors lacking immunoreactivity.[10]

Apocrine carcinoma may exhibit a unique response to androgen administration. An androgen, fluoxymesterone, was studied by Dilley et al. [11] Miller et al examined 120 breast cancers and found that the degree of apocrine differentiation correlated with the amount of GCDFFP-15 released by the tumors with high GCDFFP-15 levels in high-grade apocrine tumors. The presence of androgen receptors and also correlated with the amount of tumoral GCDFFP-15 released.[12]

IV. Conclusion

Most apocrine proliferations are benign and often are a component of fibrocystic change. As apocrine epithelium develops atypia, the differentiation between atypical apocrine hyperplasia and intraductal carcinoma is a concern. Although prognostically same as Intra duct, tal carcinoma – not otherwise specified, apocrine carcinoma should be diagnosed as separate entity, as there are growing bodies of evidence that apocrine carcinoma may have different hormonal profile and may show different clinical behavior with a unique response to androgens.

Reference

- [1]. G. Gayatri, B. Mondita, B. Asha, and A. Vishal, “Study on apocrine carcinoma of breast: histomorphologic features and immunohistochemical behavior,” *International Journal of Basic and Applied Medical Sciences*, vol. 2, no. 3, pp. 190–193, 2012. View at: [Google Scholar](#)
- [2]. J. R. Durham and R. E. Fechner, “The histologic spectrum of apocrine lesions of the breast,” *The American Journal of Clinical Pathology*, vol. 113, supplement 1, no. S3, p. S18, 2000. View at: [Google Scholar](#)
- [3]. Azzopardi JG. *Problems in Breast Pathology*. London, England:Saunders; 1979:64.
- [4]. Haagensen CD. *Diseases of the Breast*. 3rd ed. Philadelphia,PA: Saunders; 1986:82-101, 474-499.
- [5]. Fechner RE, Mills SE. *Breast Pathology, Benign Proliferations, Atypias and In Situ Carcinomas*. Chicago, IL: ASCP Press; 1990:30, 89-106.
- [6]. Tavassoli FA, Norris HJ. A comparison of the results of long-term follow-up for atypical intraductal hyperplasia and intraductal hyperplasia of the breast. *Cancer*. 1990;65:518-529.

- [7]. Krompecher E. Zur Histogenese und Morphologie der Cystenmamma (maladie Kystique recluse, cystadenoma Schimmelbuscin, mastitis chronica cystica König) des intrakanaligen Kystadenomas und Kystadenokarzinome der Brustdrüse (Hydro-Kystoma, Kystadenoma, Hydrokystadenocarcinoma mammae). *Beitr Pathol Anat.* 1916;62:403-409.
- [8]. Abati AD, Kimmel M, Rosen PP. Apocrine mammary carcinoma: a clinicopathologic study of 72 cases. *Am J Clin Pathol.* 1990;94:371-377.
- [9]. Mazoujian G, Bodian C, Haagensen DE Jr, et al. Expression of GCDFP-15 in breast carcinomas: relationship to pathologic and clinical factors. *Cancer.* 1989;63:2156-2161.
- [10]. Mazoujian G. Apocrine carcinoma of the breast [editorial]. *Am J Clin Pathol.* 1990;94:485-486.
- [11]. Dilley WG, Haagensen DE Jr, Leight GS, et al. Fluoxymesterone stimulation of tumor marker secretion in patients with breast carcinoma. *Breast Cancer Res Treat.* 1986;8:205-215.
- [12]. Miller WR, Shivas AA, Franchimont P, et al. Breast gross cystic disease protein-15 in human breast cancer in culture. *Eur J Cancer Clin Oncol.* 1988;24:223-228.

Dr. V. Soundarya, et al. "Apocrine Carcinoma of Breast: A Case Report and Literature Review." *IOSR Journal of Dental and Medical Sciences (IOSR-JDMS)*, 19(8), 2020, pp. 30-33.