

Etiology and Management of Relapse of Clubfoot after Ponseti Method of Treatment

Dr. Pancham Prasad, Dr. parvindersinghsandhu (HOD,dept.of orthopedic dept.)
Dr.Hardassinghorthopaedic hospital and super speciality research centre , circular road ,Amritsar,Punjab.

Abstract

• Idiopathic club foot is most common congenital anomalies occurring in 1 to 2 per 1000 live birth. Unilateral club foot are more common than bilateral club foot. Sex ratio of clubfoot is 2-3:1 in male and female. There are treated by serial manipulation and POP cast applied. The aim of retrospective study is to evaluate cause of relapse and treatment of relapse. After obtaining ethical clearance, retrospective study was conducted from Jan. 2006 to Dec. 2016. 136 patients with 190 feet form the basis of study. Classification or grading according to Pandey's and Pirani are used. All the cases are first serially manipulated and POP cast applied and tendo Achilles tenotomy, and the POP cast applied for 3 weeks and after removal of cast orthosis are applied. In relapse cases also manipulated and POP cast are applied and various surgical interventions are done. 12 patients with mild deformity and pliable foot had no recurrence. 12 patients with mild deformity with rigid in 3 feet. Moderate deformity and pliable foot 34 patients had 12 recurrence, Moderate deformity and rigid in 42 feet had 28 recurrence. Marked deformity and pliable in 27 had 18 recurrence and marked deformity and rigid in 63 had 57 recurrence. In relapse cases treatment POP cast has higher failure rate and JESS fixator has higher success rate. The result of clubfoot is good in normal foot and poor in equinovarus deformity.

Abbreviation –CTEV (congenital talipes equinus deformity)

FAO (foot ankle orthosis)

NTD-neural tube defect

AMC-arthrogryposis multiplex congenital.

Date of Submission: 10-09-2020

Date of Acceptance: 25-09-2020

I. Introduction

• Idiopathic club foot is most common congenital anomalies occurring in 1 to 2 per 1000 live birth. It is more common in male patient than female. Unilateral club foot are more common than bilateral club foot. Sex ratio of clubfoot is 2-3:1 in male and female.

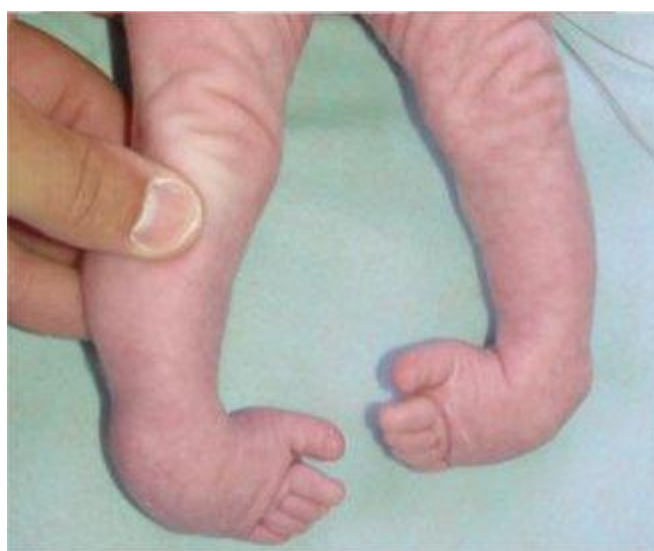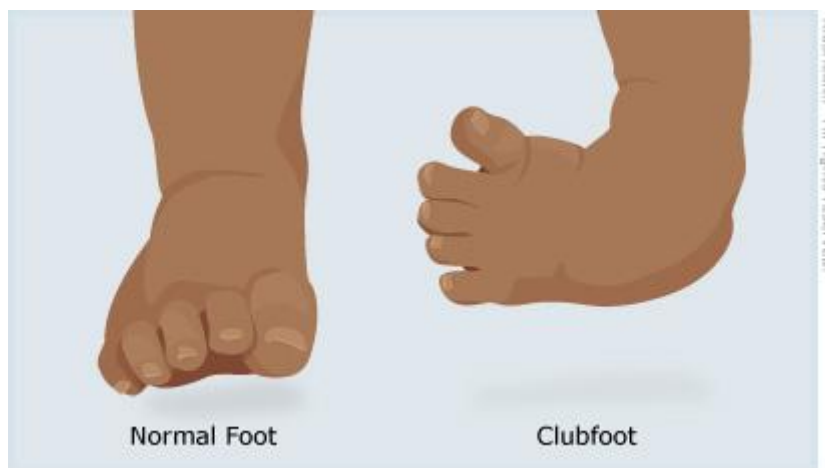
• Several theories have been put forward to explain causative factors, but none could be authentic to explain all, rather even majority of cases.

• **The equinovarus deformity is classified in congenital and acquired.** The congenital is further classified into idiopathic and non-idiopathic types. The idiopathic type is isolated skeletal anomalies, has higher response to conservative treatment, and tendency to late recurrence.

• The cause of non-idiopathic type includes **genetics, syndrome, teratogenic anomalies, neurological, disorder such as spina bifida.** The presence of other deformity associated with poor response to conservative or operative treatment.

• Acquired clubfoot has neurogenic causes such as **cerebral palsy, poliomyelitis, meningitis, sciatic nerve damage and vascular cause.**

Limitation: This is a retrospective study therefore only those features for CTEV have been available in the hospital records. It does not contain all features in fresh cases.



ETIOLOGY

- Numerous etiology has been proposed, discarded ,rediscovered by next generation and represented.
- Hippocrates postulated mechanical theory, clubfoot is due to elevated intrauterine pressure during pregnancy .This was seen in overcrowded uterus(e.g. twin pregnancy ,polyhydramnios).
- Neuromuscular etiology based on histochemical analysis of clubfoot .In this etiology there are increase in type I:II collagen fibre ratio from 1:2 to 7:1 and suggest a possible neural basis for etiology of clubfoot.
- Germ plasm defect ,defect in cartilage ,increase collagen synthesis and reaction fibrosis of distal muscle of calf leads to clubfoot deformity.
- Inheritance of clubfoot is polygenic multifactorial trait, which implies that genetic factor play role, but mode of inheritance not clear.

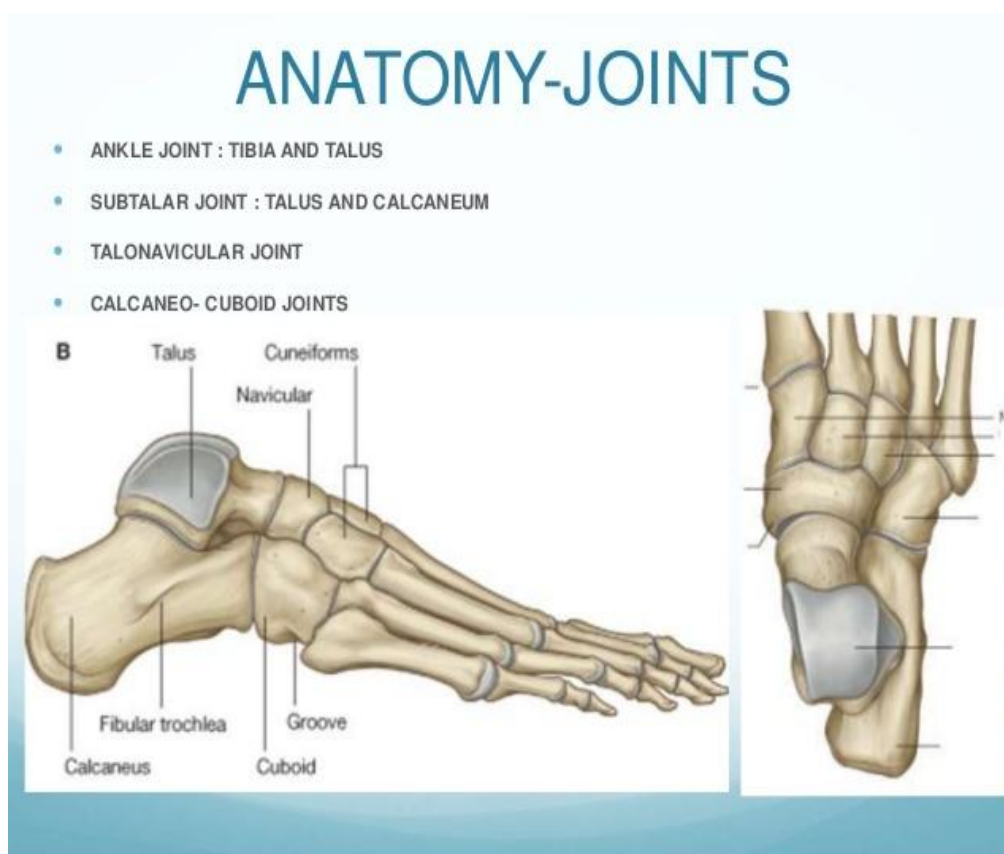
Different theory of clubfoot development

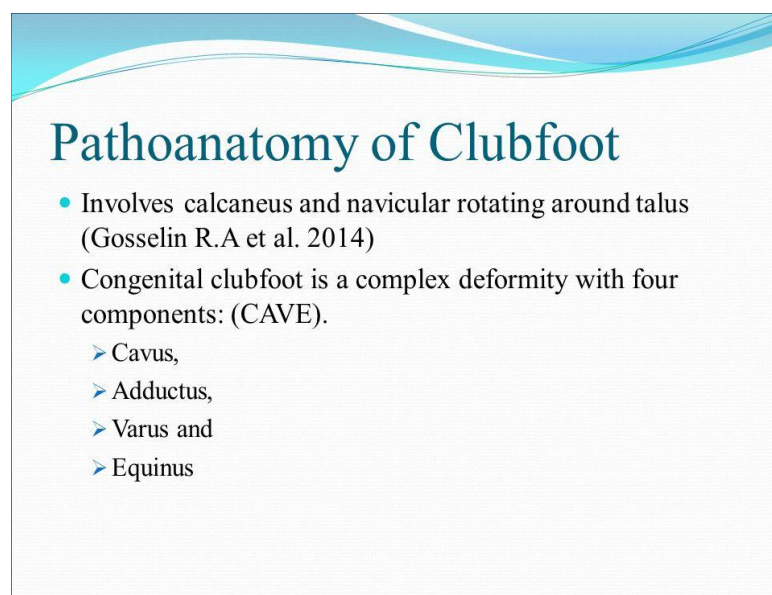
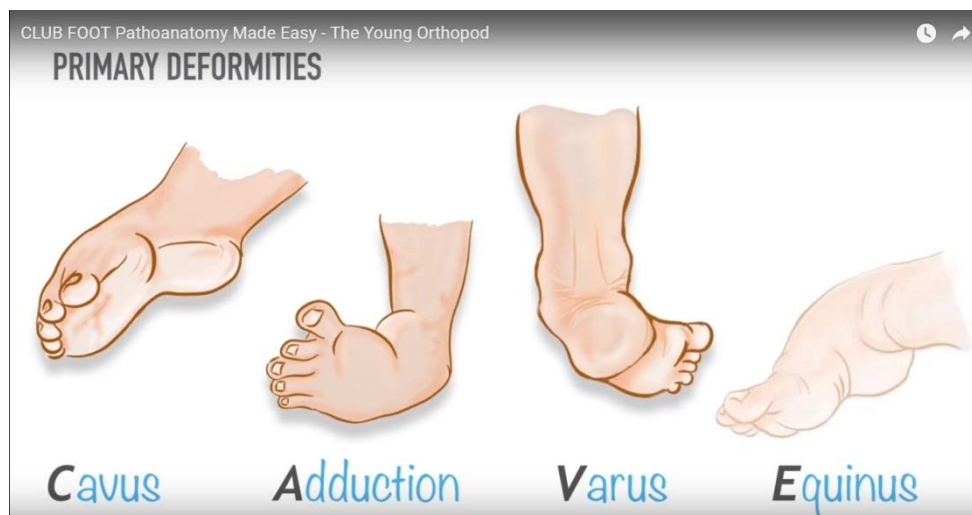
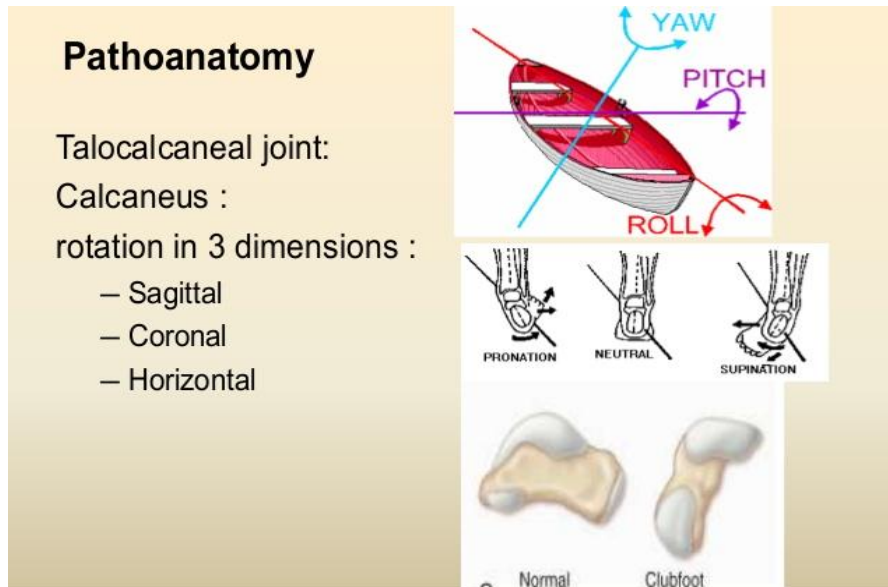
- **Otogenic theory(Bohm 1929)** –arrest in fetal development .Human foot assumes a shape of equinovarus deformity at 5 weeks stage. Temporary arrest in embryological development is most probable cause of clubfoot and it occurs at 7 to 8 weeks of gestation is likely to produce severe clubfoot deformity, where as 9 weeks can produce mild to moderate clubfoot deformity.
- **Fetal theory(Browne 1933)**- mechanical block to the development of fetal foot such as abnormal intrauterine posture and other mechanical factor. Extrinsic mechanical factor on developing embryological foot such as pressure by embryonic bands, tight uterine condition(oligohydromnios).
- **Embryonic theory (Iraw& Sherman 1963)**-these deformity occurs between conception and 12 weeks. Primary deformity is talar neck distortion which result from cartilaginous anlage defect.

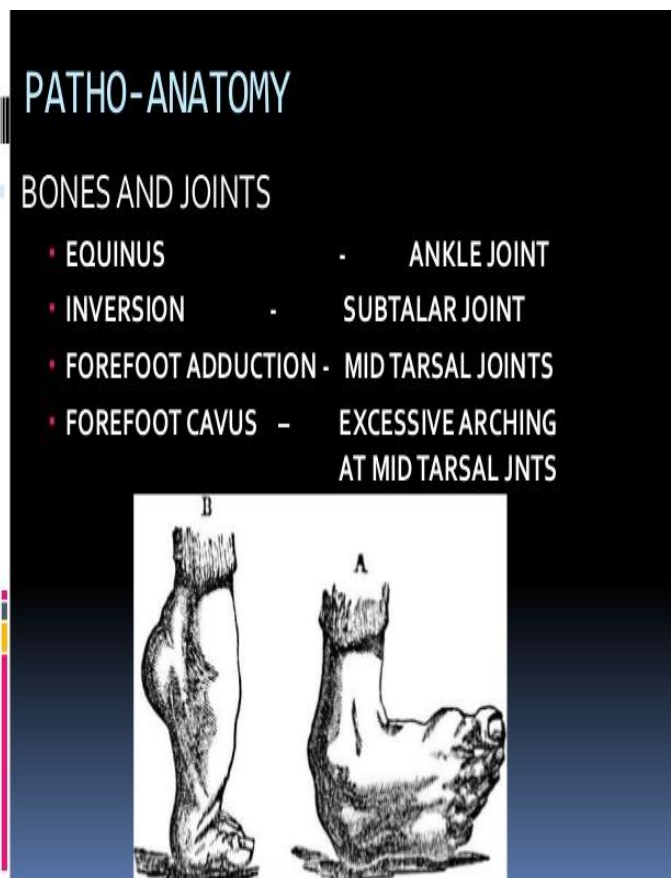- **Issac et al (1977)**- showed that abnormality in extrinsic muscle due to distorted neural control. In Arthrogyriposis multiplex congenital the associated clubfoot deformity resembles idiopathic clubfoot.
- **Chemical effect-Duraiswamy (1967)**- producing congenital malformation of foot by injecting insulin in chick embryo, sodium aminopterin, d tubocurarine, thalidomide may be possible cause of clubfoot.

PATHOANATOMY OF CLUBFOOT

- The anatomy was first described by **Scarpa in 1800** and has been subsequently verified by other authors such as Kite and Turco.
- The true clubfoot deformity is characterized by **cavus, adduction, varus, and equinus**
- The **equinus** deformity is present at the **ankle joint, TCN joint. In varus deformity** hind foot is rotated medially and this occurs primarily at TCN Joints.
- The whole of tarsus except talus is, rotated inward with respect to lower leg. **The medial border of forefoot face upward.**
- The adduction deformity takes place **at talo navicular and anterior sub talar joint.**
- The **cavus** components involves forefoot plantar flexion which contributes to composite equinus .
- The pathology of individual bone contributes to the clubfoot deformity .Multiple abnormalities of talus includes broadening of anterior part of trochlea, increase medial deviation of neck and flattening of talar head. Hypoplasia of inferior surface of talus.
- The calcaneum is involved in all of the components of deformity and is grossly normal except that three facets on dorsal surface are flattened and **sustentaculum tail is hypoplastic.**
- Navicular is displaced medially and its proximal concavity is flattened as a result never articulated with talus.
- The contracture are divided into four groups : posterior, medial plantar sub talar, plantar.
- Posterior contracture include **tendo –achilles, tibio –talercapsule, talo calcaneal capsule, posterior tibio-fibular ligament** and calcaneo-fibular ligament.
- Medial plantar contracture includes talo-navicular capsule, deltoid ligament, tibialis posterior tendon and spring ligament.
- The subtalar contracture include talocalcaneal interosseous ligament and bifurcated ligament.
- Plantar contracture are **adductor hallucis**, plantar fascia and intrinsic toe flexors.





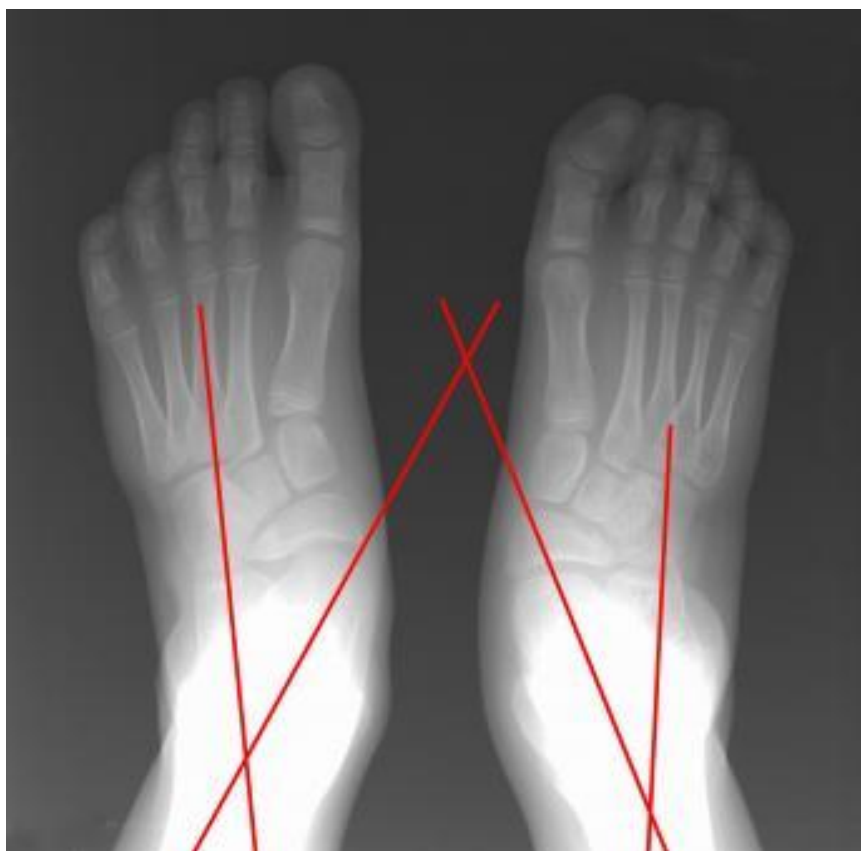
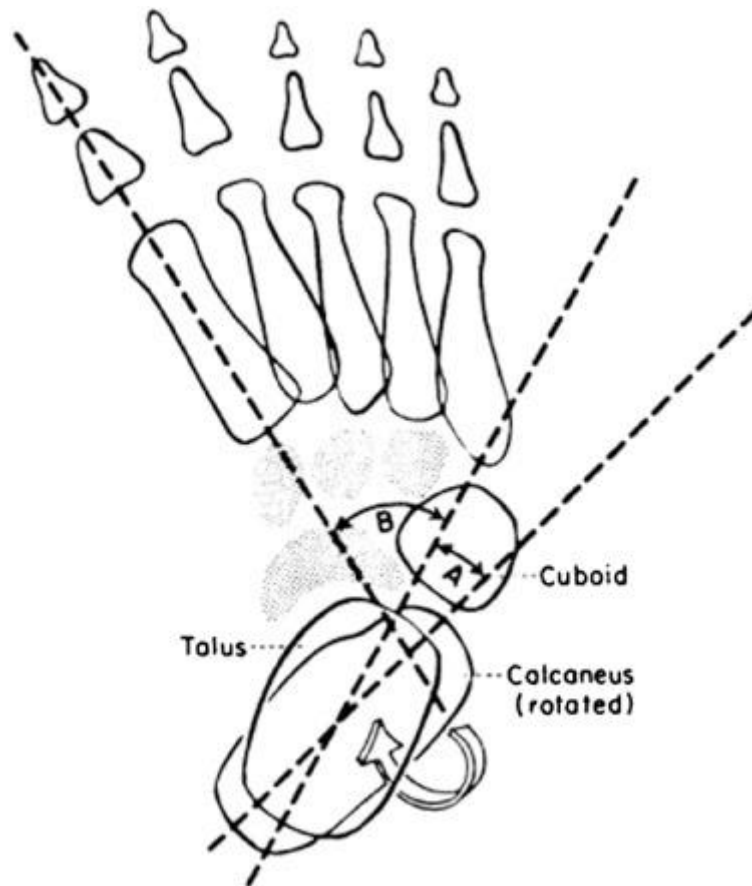


CLINICAL FEATURE OF CLUBFOOT

- Postural clubfoot can be differentiated from congenital clubfoot because it can be fully correctable to normal anatomical position at birth or shortly thereafter by manipulative strapping .Patient should be examined to exclude out multiple congenital malformation and paralytic clubfoot.
- Idiopathic clubfoot is characterized by bean shaped foot ,prominence of head of **talus** ,**medial plantar cleft** ,**deep posterior cleft**, **absence of normal crease** over insertion of tendo Achilles ,calcaneum tuberosity situated at higher level and atrophy of calf muscle.
- Three major components of deformity **equinus** ,**varus**, **adductus** on clinical examination .The attitude of knee is usually flexed but in case of neglected clubfoot attitude of knee is hyperextension.

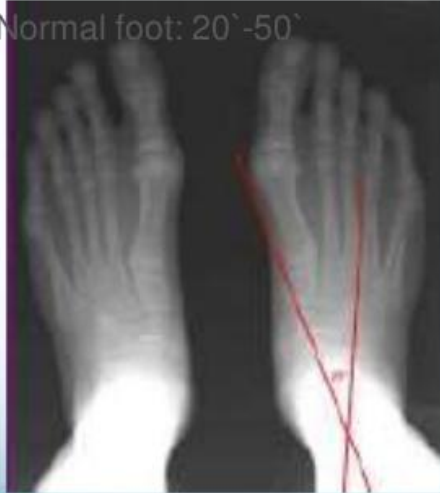RADIOLOGICAL ASSESSMENT

- Clubfoot can be diagnosed at birth by clinical examination .
At birth ossify nuclei of foot and ankle is distal tibia ,talus, calcaneum , cuboid .Rose et al(1985) observation radiograph are not helpful l,being flat image of three dimensional structure. In radiographic imaging talocalcaneum angle ,talar 1st,metatarsal angle ,calcaneal 5th metatarsal angle ,kite angle are measured .Lateral talocalcaneum angle more accurately and easily drawn and evaluation with accuracy.**Mc.caunely (1947)** stress for radiographic evaluation of the result of the treatment of clubfoot.
- **Yamato et al (1994) and Simons(1994)** observe that lateral tibio calcaneal angle is more valid angular measurement of equinus than lateral talo calcaneal angle.
- **Barriolhet (1994)** has described simple angular measurement i.e.first ray angle to evaluate to abduction and adduction of fore foot.

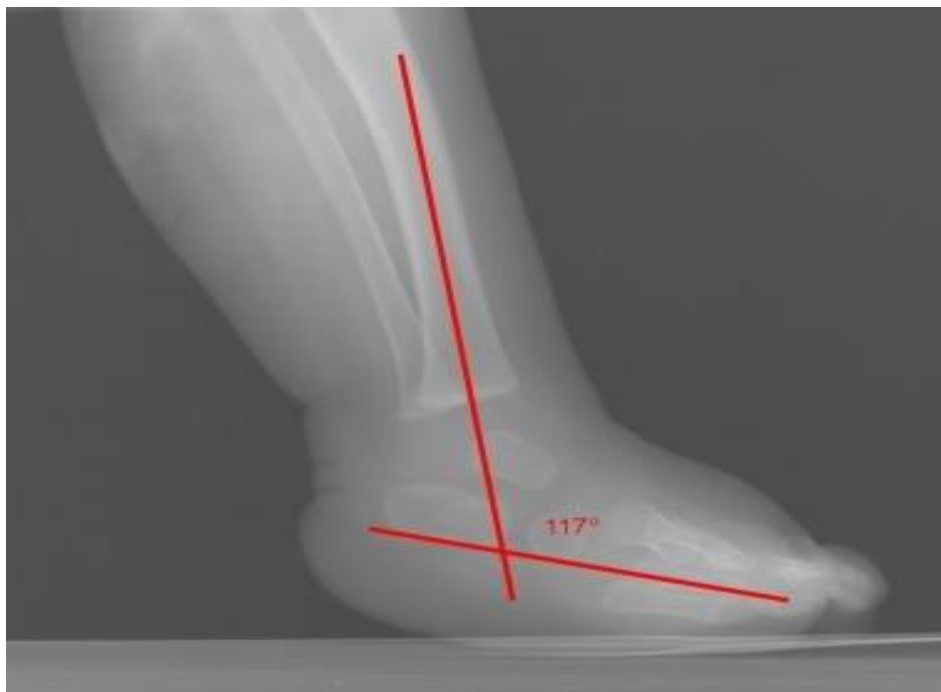
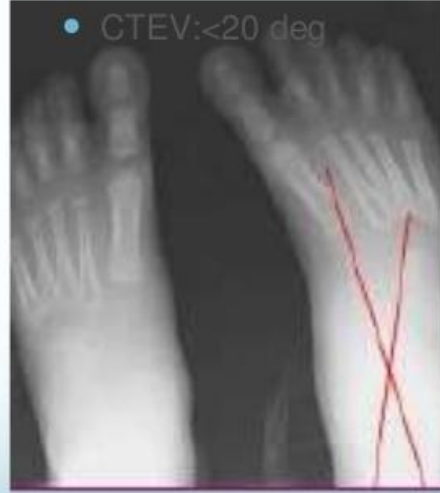

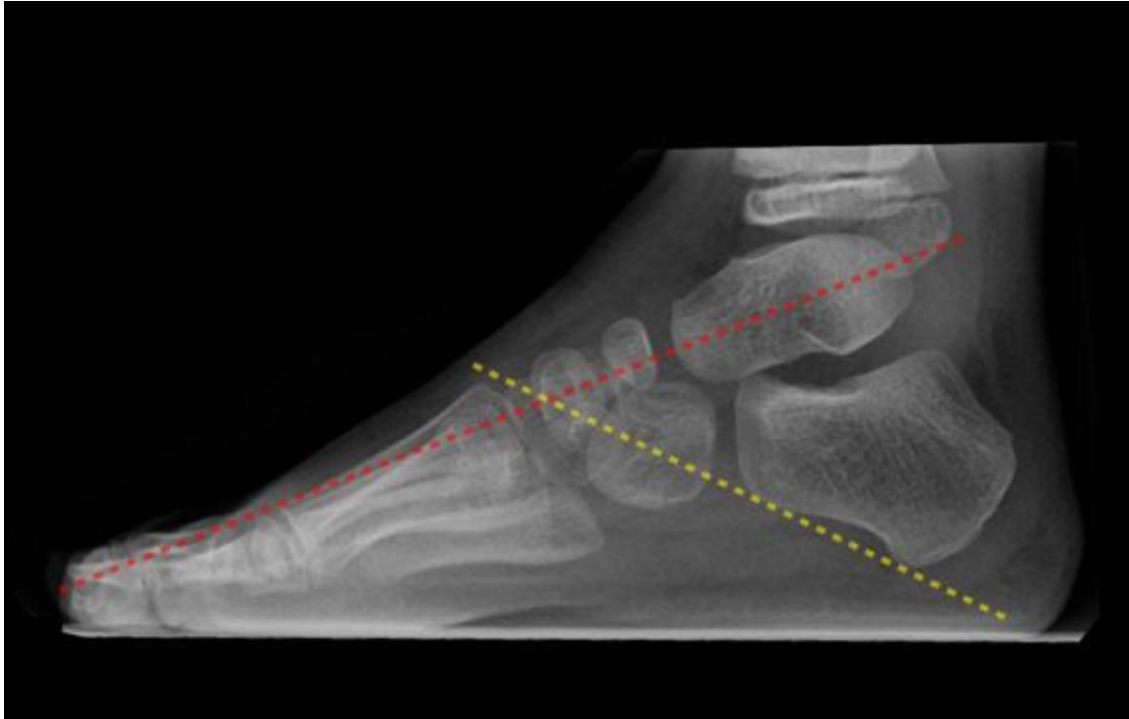AP radiograph: Talo-Calcaneal angle

- Normal foot: 20°-50°



- CTEV: <20 deg





- Antenatal diagnosis with the help of ultrasound ,clubfoot now can be diagnosed at 18-20 week of gestation .However this is 80% accurate ,if the antenatal diagnosis is done before 20 week ,some authors suggested amniocentesis due to high incidence of genetic anomalies such as trisomy 18 ,**Larsen’s syndrome** ,**NTD**, **congenital heart disease**. There are high false positive with USG and associated foetal loss with **amniocentesis**.

CLASSIFICATION OF CLUBFOOT

Previously clubfoot can be classified as mild, moderate, and severe,but this is considered to be subjective.Three classification system that are accepted world wide are **Dimeglio et al** ,**Pirani** and **international clubfoot study group(ICFSG)** classification.

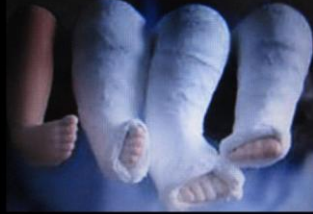TREATMENT OF CLUBFOOT

PONSETI METHOD

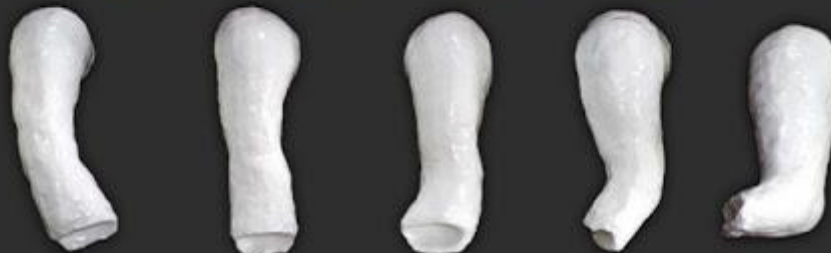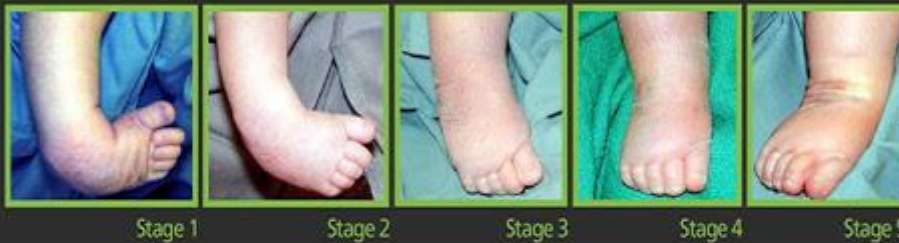- Major principle of **ponseti** technique is gentle manipulation of soft tissue include tendon, ligament ,joint capsule certain bone and above knee up to groin **POP** cast at weekly interval. **Ponseti technique** apply in first week of life and is initial method of club foot correction.In treatment phase of **Ponseti** gentle manipulation and **POP** cast apply at weekly interval .Each cast hold the foot in corrected position allowing it to be gradually re shape and 6 to 7 **POP CAST** are required to correct deformity.
- At the time of final cast majority of infants required percutaneous **tenotomy** to gain lengthening of **Achilles tendon** and then **POP cast** remain for three weeks.
- In maintenance phase brace is utilize to prevent recurrence by orthotic device. Orthotic device worn 23 hours in first three months and then during night time for 3 to 4 year.
- **Cavusis** corrected by lifting the metatarsal head, abduction the fore foot in supination till fore foot is maximally abducted.**Supination**corrected is indicated by neutral or slight valgus. **Manipulation** is done with thumb of one hand placed over talar head and other hand holding the first metatarsal head, index finger and thumb on the weekly basis. Manipulation carried out till adduction and inversion was fully corrected, usually equinus corrected by **TA tenotomy** and maintained the foot in **POP CAST** for 3 to 6 weeks and fitted **FAO** to be **continue** till further instruction with regular follow up.

The Ponseti Technique :

- * The Treatment Phase –
Deformity is corrected completely
- * The Maintenance Phase –
A brace is utilized to prevent recurrence
- # Minimize the possibility of incomplete correction
and recurrences.



Clubfoot treatment over 4 – 6 weeks



Series of Casts



KidsHealth® All rights reserved.

The Ponseti Method Treatment of Clubfoot

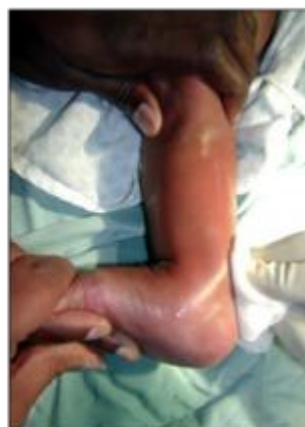
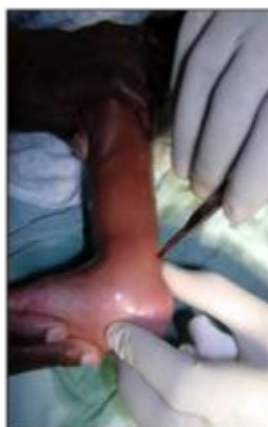
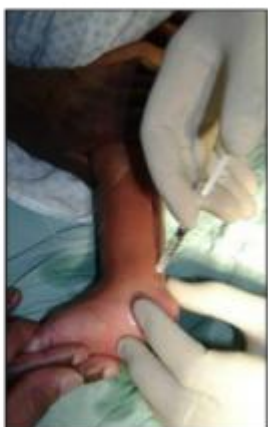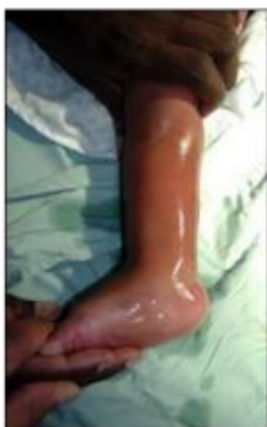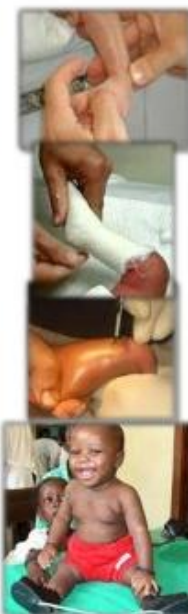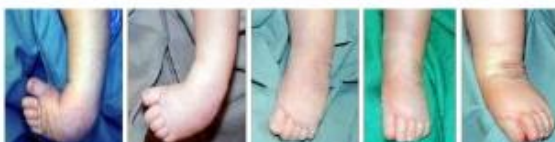Ignacio V. Ponseti
(1914-2009)

The PONSETI METHOD

- Gentle manipulation and stretching
- Series of precisely applied plaster casts
- Percutaneous tenotomy (most cases)
- Wear brace while sleeping to age four

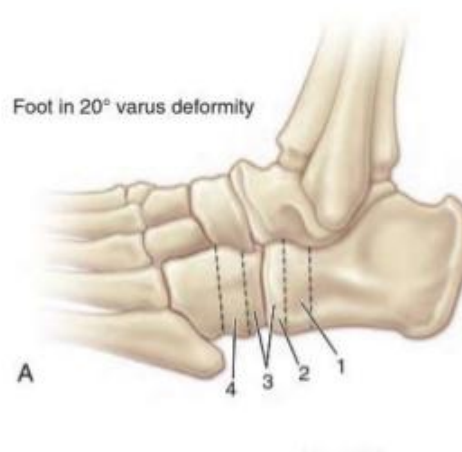
Endorsed and supported by



- Postero medial soft tissue release (PMSTR), tendon transfer, Lichtblau procedure, calcaneo-cuboid resection, percutaneous tenotomy surgical procedure done in relapse of clubfoot.

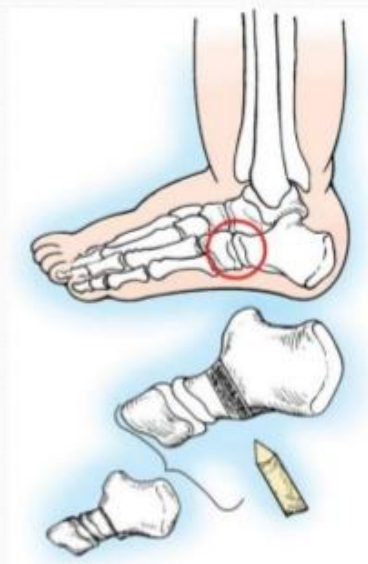
LATERAL COLUMN SHORTENING PROCEDURE

- **INDICATION**- RECURRENCE OF CLUBFOOT DEFORMITY AFTER SURGICAL RELEASE IS MOSTLY DUE TO DISPARITY BETWEEN MEDIAL AND LATERAL BORDER OF FOOT. ANY ATTEMPT TO CORRECT DEFORMITY IS RESISTED BY MEDIAL CONTRACTURE AND EXCESSIVE LENGTH OF LATERAL COLUMN.
- DIFFERENT PROCEDURE TO DO SHORTEN LATERAL COLUMN ARE-
 - DILLWYNN EVANS PROCEDURE
 - LICHTBLAU PROCEDURE
 - FOWLER PROCEDURE



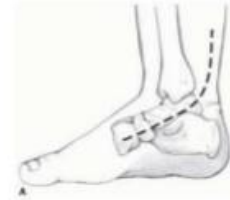Litchblau procedure

- Medial soft tissue release
- Lateral closing wedge osteotomy of calcaneus
- Prevents long term stiffness of hindfoot
- Shortens the lateral column



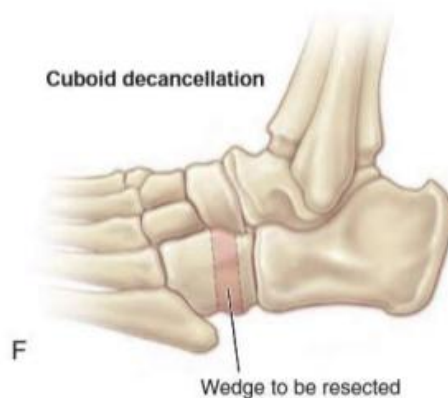TURCO OPERATION

- MEDIAL INCISION GIVEN
- EXPOSE TIBIALIS POSTERIOR, FDL, FHL, TENDOACHILLES AND POSTERIOR NEUROVASCULAR BUNDLE.
- DIVIDE MASTER KNOT OF HENRY.
- DIVIDE CALCANEONAVICULAR LIGAMENT AND ABDUCTOR HALLUCIS FROM TIBIALIS POSTERIOR TENDON, NAVICULAR TUBEROSITY AND 1ST METATARSAL.
- **POSTERIOR RELEASE-** BY DOING Z-PLASTY OF TENDO ACHILLES, INCISING POSTERIOR CAPSULE OF ANKLE JOIN, SUBTALAR JOINT AND DIVIDING TALOFIBULAR LIGAMENT AND CALCANEOFIBULAR LIGAMENT.
- **MEDIAL PLANTAR RELEASE-** DIVIDE TIBIALIS POSTERIOR, SUPERFICIAL DELTOID LIGAMENT, TALONAVICULAR CAPSULE AND SPRING LIGAMENT.
- **SUTALAR RELEASE-** DIVIDE MEDIAL PART OF TALOCALCANEAL INTERROSEOUS LIGAMENT AND BIFURCATION OF Y LIGAMENT.
- AFTER REDUCING NAVICULAR BONE TRANSFIX TALONAVICULAR JOINT BY K-WIRE AND SUBTALAR JOINT BY 2ND K-WIRE.



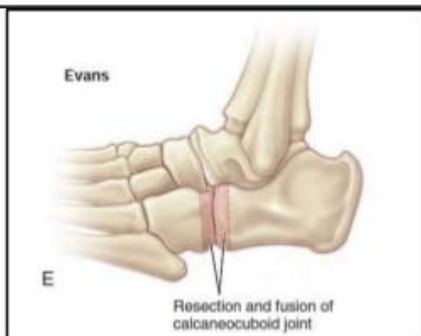
FOWLER PROCEDURE

- **INDICATION-** SUFFICIENT SCARRING THAT MEDIAL SOFT TISSUE AND SUBTALAR RELEASE WOULD BE IN EFFECTIVE.
- AGE- 6-8 YEARS
- **PROCEDURE-** LATERAL COLUMN SHORTENING COMBINING WITH MEDIAL COLUMN LENGTHING BY REMOVING WEDGE FROM CUBOID AND TRANSFERRING IT TO AN OPENING WEDGE.



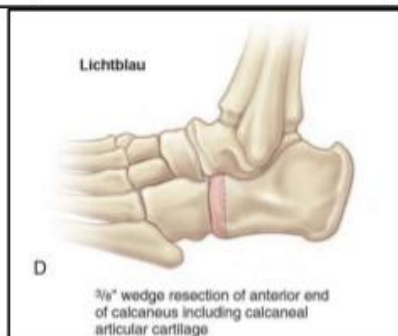
LATERAL COLUMN SHORTENING PROCEDURE

DILLWYN EVANS PROCEDURE



AGE- 4-8 YRS
INDICATION- MIDFOOT IN VARUS DUE TO TALONAVICULAR AND CALCANEOCUBOID SUBLUXATION

LICHTBLAU PROCEDURE




AGE- 3-4 YRS
INDICATION- HEEL VARUS & RESIDUAL INTERNAL DEFORMITY OF CALCANEUS WITH LONG LATERAL COLUMN

Extensile posteromedial and posterolateral release

- Modified McKay procedure
- Cincinnati incision

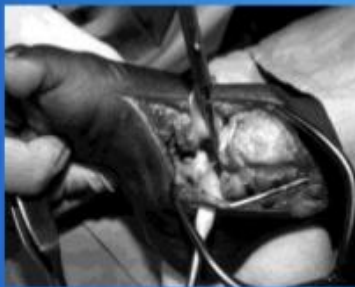Posterolateral release

- Z lengthening of the TA
- Posterior capsulotomy of Ankle joint & Subtalar joint

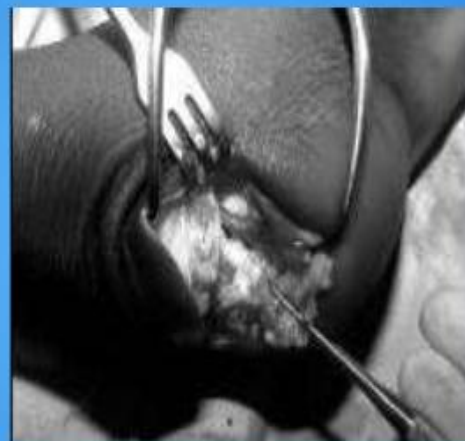


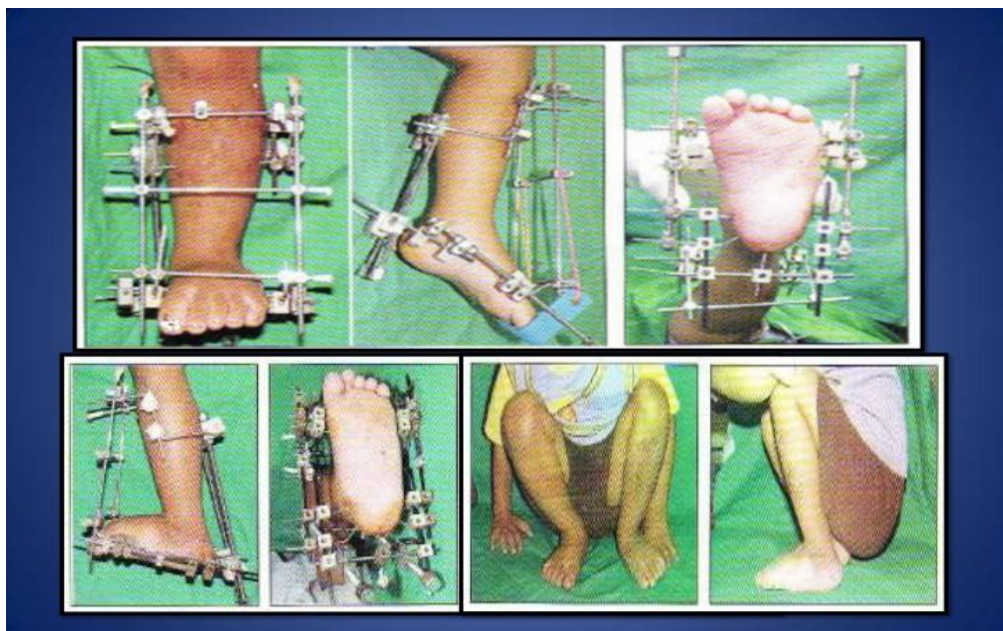
Caroll's two incision technique

Medial incision - straight oblique incision from first metatarsal, across medial malleolus to Achilles tendon



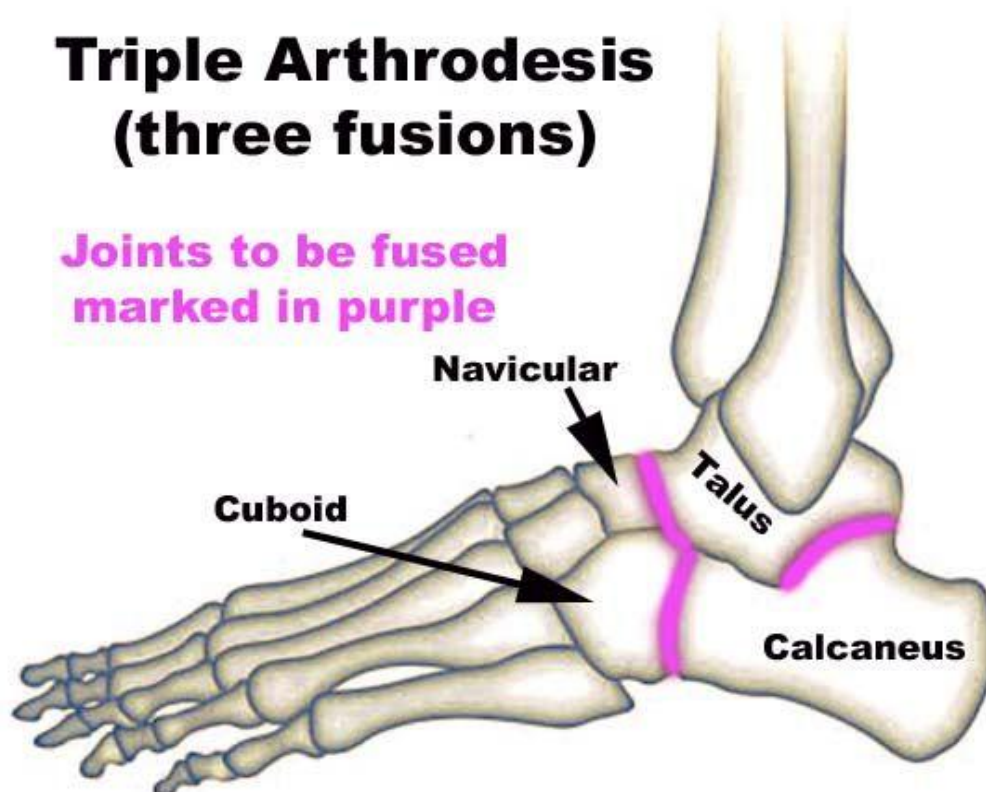
Straight lateral incision along the lateral subtalar joint antr to distal fibula





Triple Arthrodesis (three fusions)

Joints to be fused
marked in purple



II. REVIEW OF LITERATURE

1.Hippocrates (300 BC) was, perhaps, the first to actually describe the deformity in club foot and described intrauterine mechanical pressure as is causative factors. He had view that repeated manipulation could correct the deformity.

2.Bohms gives otogenic theory for arrest of foetal development in **1929**.

3.Irani and Sherman(germ plasm defect) 1963 believed that primary deformity is talarneck distortion which result from cartilaginous anlage defect.

4.Issacetal (1977) showed abnormality in extrinsic muscle to suggest to distorted neural control of muscle development. However no convincing evidence of muscular imbalance could be authenticated.

5.Issac et al (1977) and Swinyard and Bleck(1985) postulated that decrease movement of the extremities caused by intrauterine insult (e.g. viral infection)destroys motor neuron in the developing spinal cord which is cause of **Arthrogyposis multiplex congenita**.

6.Martin et al (1994) demonstrate reduced motor unit counts in distribution of common peroneal nerve as a constant finding in **congenital talipesquinovarus**.The possibleaxonal damage of common peroneal nerve in utero cannot be rule out.The relapsing /recurrent club foot is not the result of basic underlying skeletal deformity,rather it is result of continuing dynamic factor.

7.Sodre et al (1984) have suggested the anomalous muscles (accessory soleus muscle and flexor digitorum accessory longus muscle) in producing equinovarus deformity depending upon their insertion and dynamic action.

8.Fried (1959),suggested abnormal tibialis posterior tendon and contracted deltoid ligament as the possible cause of club foot.

9.Ippolito and Ponseti (1989) postulated a primary genetically **induced retractive Fibrosis** as cause of club foot deformity.Soft tissue abnormalities are cause or secondary adaptive change remains controversial.

10.Effect of chromosomal abnormalities have been review by **Cowell and wen (1980)** .It is being described that clubfoot may be a part of syndrome (**mendelian or non mendeian**) due to **chromosomal abnormality**.. However in spite of controversy ,clubfootetiology may be multifactorial.

11.Hootnick et al have proposed the possibility of diminution of **anterior tibial artery** and its derivative as the possible cause of **talipesquinovarus** .

12.Duraiswamy (1967) experiment that congenital deformity of limb was produce by **injecting insulin** in chick embryo and **sodium aminopterin**.

13.Gartland (1964) has rightly suggested about the clubfoot as:dealing with the condition ,the course of which is unknown ,pathoanatomy is unpredictable and treatment of which remains controversial.

14.One stage soft tissue release –postero medial by Turco(1971) and complete sub talar release (**McKay-1982,1983,Simmons-1985**) surgical release of clubfoot gained popularity but which is best remains controversial.

15.Seringe and Miladi (1994) suggest three reasons for not releasing the interosseous ligament.The intact interosseous ligament guide the abduction of calcaneo pedal block,release of ligament overcorrect the calcaneum resulting into valgus and result may leads to avascular necrosis of talus.

16.Seringe and Miladi (1994) also observed complication more frequently with sub talarrelease :recurrence of deformity ,overcorrection ,pain.

17.Gray and Katz(1981) quoted the work of Robl and Nyga ,who found that bone in neonate idiopathic clubfoot to be normal. This work may be turning point toward establishing the pathology of clubfoot in soft tissue.

18.Gray and Katz(1981) and Siera et al (1990) detected in their histochemical and electron microscopic examination of muscle biopsy from clubfoot, structural change and high collagen proportion of type 1 fibres.

19.Scarpa (1803), summarize the pathological anatomy as twisting as scaphoid ,oscalsis and cuboid around astragalus labelling it the congenital dislocation of astrogalo –calcaneo scaphoid complex.

20.Scarpa's view has been subsequently supported by several other as **Adaams(1866),Bissel(1888),Willey(1958),Schlicht,etc.**However,**Irani and Sherman(1963)** suggested that primary defect in club foot lies in neck of talus which remains short and in few case appears even non –existent and head of talus appears directly fused with body.

21.Turco (1971 and 1979) has assigned the club foot deformity to medial displacement of navicular and calcaneum around talus.He asserted that talus is forced into equinusby calcaneum and navicular while the head and neck of talus deviated medially.

22.Carrol et al (1978) dissected that congenital **clubfoot pathoanatomy is** due to subluxation of talo-navicular joint ,lateral malleolus is positioned and posteriorly,talarhead laterally.

23.Mckay(1983),observed that the major deformity in clubfoot is an inward rotation of the whole foot ,in which subtalar joint complex.

24.Goldner(1979) and Gould(1985) believed that primary deformity in clubfoot caused by rotation of talus combined with contracture of Achilles tendon and their tendon of posteromedial aspect of ankle.

25.Kitessuggested the association of **internal tibial torsion** ,whereas **Kleiger(1969)**suggested the association of external tibialtorsion.On the other hand according to **Wynne Davies** there is no tibial torsion.

26.Kuo(1994) also did not see any difference in functional result between tibialis posterior tendon release and **z lengthening of tendon**.

27.Malan (1994) prescribed the observation on long series of surgical correction of clubfoot in whom anterior tibial tendon have been lengthening as a part of extensive soft tissue procedure.He suggested that in a surgically corrected club foot the lateral **dorsiflexor** are weakened.

- 28. Harrold et al (1983) and Seringe (1900)** reported more or less similar classification based upon the measurement of the individual deformities especially varus and equinus.
- 29. Caterral (1900)** suggest to classify the clubfoot into three types on clinical assessment of the patterns of deformity ,mainly on tendon and joint contracture.
- 30. Goldner (1990)** USED numerical grading based on clinical ,radiographical,and intraoperative finding. Grade I with 10/60 points grade II with 11-20/60 points grade III with 21-40/60 points, grade IV 60/60 points as severe club foot.
- 31. Carrol (1990)** has claimed to a simple point system to evaluating the clubfoot assessed by allocating one point to each feature as follows; **cal fatrophy, posterior displacement of lateral malleolus** posterior crease or medial crease, curve lateral border, cavus and fixed equinus, navicular fixed to medial malleolus ,os calcis fixed to fibula, no mid tarsal mobility and fixed fore foot supination.
- 32. Molta and Morello (1994)** observe that if the club foot is fully corrected within first year, it is more likely to have almost normal motor and neuropsychiatric development.
- 33. Turco (1994)** suggested for early recognizing the atypical clubfoot, which though same as typical clubfoot at birth, but behave erratically after management ,especially after early surgery ,which may result in grotesque overcorrected severe flat foot.
- 34. Dimeglio (1994)** suggested a clinical classification of clubfoot into four basic category based upon reducibility of deformity components in horizontal and sagittal plane and over the assessment of 384 club feet in first few week of life.
- 35. Barwell** was first to describe the use of radiograph to evaluate the CTEV in 1896. X ray of new born show ossify nuclei of distal tibia ,talus, calcaneum, and cuboid.
- 36. Rose et al (1985)** observe that radiographs are not helpful ,being flat image of three dimensional situations.
- 37. McCaunley (1947)** stressed for the radiographic evaluation of the result of the treatment of clubfoot. Further he observe that except those clubfoot, which radially get corrected in early few months ,other tends to recur.
- 38. Yamamoto et al (1994) and Simmons (1994)** observed that lateral tibio calcaneal angle is more valid angular measurement of equinus than the lateral talocalcaneal angle which measure only the angular relationship between talus and calcaneum whereas the lateral tibio calcaneal angle measure the relationship between calcaneum and tibia.
- 39. Barriholet et al (1994)** has describe simple angular measurement the first ray angle the adduction and abduction of the fore foot.
- 40. KAMAGI ET AL (1977)** describe the metatarsal to malleolar (MTB) angle (angle of the line from the centre of second metatarsal **to talar head to bimalleolar line**) to measure the toeing deformity in CTEV.
- 41. Polo and Ruiz (1968)** first to suspect the abnormalities of anterior tibial vascular tree in club foot., which later on was reported by Hotnick, Packard and Levinshon in 1990 after anterior compartment necrosis had developed following operation on clubfoot.
- 42. Greider et al 1982, Hootnic et al 1982** observe anterior tibial artery hypoplasia arteriographically in 90 % clubfoot.
- 43. Early treatment method suggested by kite in 1939** focused on non operative management of club foot which remains as fundamental treatment of club foot more or less today of course with certain variable modification
- 44. Ponseti 1996** differ from Kite only on certain points such as initial focused pressure on talar head., supination forefoot and then abduction it etc and also stressed on non operative management of clubfoot .
- 45. IN 1976 Radovan** designed a silicone expander which was to inflated by remote subcutaneously placed injecting port, a course of now tissue expander with external injection ports have been described.
- 46. Crawford et al (1982)**, introduced the incision. It is just an incisional approach running transversally from posteromedial across the heel to posterolateral side of foot upto sinus tarsi.
- 47. Carrol (1978, 1988)** developed the surgical release technique in clubfoot by using the double incision and the release of lateral tether and the calcaneo cuboid joint.
- 48. Lorenz (1782) and Sartorius (1812)** advocated for subcutaneous tenotomy for getting early correction effect in clubfeet. Delpech (1832) suggest sub cutaneous tenotomy of tendo achilles for correcting the acquired talipes. Little (1839) popularised tendo achilles in England.
- 49. Ponseti (1996)** advocate for performing tendo Achilles tenotomy in almost all case after 5 to 8 sitting of plaster according to method.
- 50. Garceau (1940)** was first to performed tibialis anterior tendon transfer to third cuneiform to treat recurrent idiopathic clubfoot.
- 51. Many worker** contributes in the tendon transfer for club foot. Gracy (1960) + Ponseti (transposition of tibialis posterior tendon), **Gartland 1972** (transposition of tibialis posterior), **Grewal** (half tibialis anterior transposition).

52.HO Thomas of Liverpool(1886),used his wrench in 1886 to correct the neglected club foot,with bony change after preliminary subcutaneous Achilles tenotomy.

53.The pioneering work of **Stromeyer** of Hanover in 1830 became the hallmark in initiating the practicable elective surgery for the clubfoot when he initiated the minimallyinvasive surgery of subcutaneous **Achilles tenotomy**.

54.Recent trend in management of clubfoot is towards restoration of bony alignment under direct vision by extensive approach such as **complete subtalar release(Simmons 1971,1985)**.

55. One of the earliest basic soft tissue release was the posterior release operation of **Attenborough(1966)**,which is useful in hind foot varus and forefoot adduction corrected well and remaining deformity is hindfootequinus.

56.Porat 1990 presented a comparative evaluation of commonly used approach of surgical release of clubfoot.

57.Various bony procedure have been described to correct the residual bony deformity in club foot,e.g. osteotomy of neck of talus **or calcaneum(Phleps)**,wedge resection of calcaneo-cuboid joint (Evans 1961).wedge resection or insertion osteotomy of calcaneum(**Dwyer 1959,1963**),**LICHTBLAU (1973)** procedure of medial release with close wedge osteotomy of distal calcaneum,medial rotation osteotomy of tibia(**Lloyd Roberts 1990**) ,T –osteotomy of calcaneum(Pandey et al).

58.Morcuende et al reported that the number of cast required was not a long term prognostic factor for recurrence after treatment. Number of cast depends upon technique of casting, stretch period needed and discomfort on the child.

59.Newzealand Hast et al showed a high recurrence (41%) but could not attribute result to high proportional deformity in Polynesian children. The Polynesian patient has less disability and less likely to requires surgery than white patients.

60.Morcuende et al describe an atypical deformity which comprised of small, bean shaped stiff feet, with short big toe and volar crease. These foot are resistant to manipulates and kept having recurrence.

61.Dyer et al used catterall/pirani system to estimate the number of weekly cast required, they also used the hind foot score to predict the need of **tenotomy**. There are significant association between initial **pirani**score and the number of cast changes required to correct the deformity.

62.Bensahael et al review children with idiopathic, neurogenic, malformative clubfoot. Malformative were associated with other congenital deformities. One surgeon using the same method treated all case. They reported 88% success rate in idiopathic feet and 25% success rate in malformative feet.

63.Avilucea et al showed an increase in recurrence in native American living in rural than those in urban and other ethnicities. They suggested that rate could be attributed to problem in communication.

64.In 1872, **Lund** preferred talectomy, not as a corrective procedure for equinovarus deformity, but because it was prominent. This procedure resulted in plantigrade foot.

65.Barr (1958) believed that **tibialis anterior tendon** should not be transferred to a lateral insertion if peroneus longus is functioning, due to resulting muscle imbalance.

66.Brockman (1930) in addition to releasing the median ligament and plantar fascia, divided the abductor hallucis, tibialis posterior and subsequently carried out elongation of **Achilles tendon** to correct equinus.

AIMS AND OBJECTIVE

1.To study the incidence of relapse of clubfoot deformity after ponseti treatment.

2.**Relapse**of components or combination of deformity.

3.cause of relapse

4 Treatment of relapse deformity.

III. Material And Method

- **Place of study-** The study will be carried out in **Dr.Hardassinghorthopaedic hospital** and superspeciality research centre ,Amritsar.
- All the patient of CTEV treated with **PONSETI** technique will be followed up .Only those patient will be included who has-

1.IDIOPATHIC congenital talus equinovarus.

2. ONLY those treated within one month of day of birth.

3. Those whose record included-

(a)Degree of deformity

(b>About rigidity of foot

(c) Rigid , mild ,moderate

(d)Number of cast given and **FREQUENCY**.

(e) **TENDOACHILIS TENOTOMY.**

(f) **TREATMENT** for maintainance of correction by orthosis, splint **SHOES.**

(g) **AT LEAST 2** year of follow up

***** EXCLUDED FROM THIS STUDY WILL BE PATIENT-**

(a) CASE of **spinal DYSRAPAYSM.**

(b) **ARTHROGRYPOSIS**

(c) WHO had less than 2 year of follow up.

(d) who were treated older than 1 month at

the start of treat

(e) who had **INTERUPTED TREATMENT.**

***** Type of study- case control study**

***** AT FOLLOW UP** of examination patient will be examined and following will be noted

(a)Side of deformity.

(b)Size of the foot.

(c)comparision with opposite normal foot

(d)Recurrence of deformity –

(e) Which deformity –(i) **equinus**

(ii) **inversion**

(iii) **adduction**

(iv) **cavus**

(v) **combination of 2 or more**

Elements

(f)Cause of recurrence

(g)Management –(i) manipulation and pop cast

(ii) no. of cast with frequency

(iii) operative-type of procedure

(iv) result

ASSESSMENT OF RESULT

1. Normal foot.

Plantigrade foot capable of fitting commercially made shoe with normal shoe wear.

2. Any treatment planned for further care .

CORRELATION

1. **RECURRENCE** with degree of deformity

2. **RIGIDITY**

3. **TENDO ACHILLIS TENOTOMY**

4. **DURATION** of wearing of orthosis

5. Patient correlation

• This study was conducted in **Dr.Hardas Singh Orthopaedic hospital and super speciality**

researchcentre,Circular Road ,Amritsar Punjab.

• **Four hundred and fifty six patient (456)** with six hundred eighty four(**684**)feets of **congenital talipsequinovarus(CTEV)**deformity attended the hospital for treatment from **jan.2006 to Dec.2016.**

• Out of this **only 157 patient with 232 feets reported upto 3 weeks of age.**Twenty one Patient with **42 feets**were excluded from this study because **12 patients with 24 feets**had **spinal dysraphysm** and **9 patients with 18 feets** were of **Arthrogyposis multiplex congenital**,remaining 136 patients with 190 feets form the basis of study

- Out of 136 patient, 9 patient with 16 feet had positive family history, 6 patient belong to Muslim community with consanguineous marriage were first cousins. There are 3 patients with 4 feet with history of mother taking drugs during the 1st trimester of pregnancy, 2 patient had taken medication for morning sickness and 1 for viral infection.

In study patient----

	No.of patient	No.of foot	condition
	9	16	Family history +ve
	6		Muslim community
	3	4	H/o mother taking drug in 1 st trimester
	2		• Drugs for morning sickness
	1		• Viral infection

CLASSIFICATION

- As the feet of bilateral deformity in some patients behave differently on two sides, it has been decided to do analysis of the feet and not of the patients. So next observation are based on the number of feet.
- The deformity was assessed by Pirani score and Pandey's criteria.
- Pirani score 0.5 to 1.0 grade 1, 1.5 to 2.0 was grade 2, 2.5 to 3.0 was grade 3, 3.5 to 4 was grade 4, 4.5 to 5.0 was grade 5, 5.5 to 6 was grade 6.
- Pandey classified as mild, moderate, severe and very severe deformity. We have combined severe and very severe deformity to have proper number of patients for analysis.
- Further Pirani score 1 and 2 i.e. 0.5 to 2.0 score were considered to equivalent Pandey's mild deformity. Pirani score 2.5 to 4.0 i.e. grade 3 and 4 was equivalent to moderate, 4.5 to 6.0 i.e. grade 5 and 6 of Pirani score was considered severe deformity of Pandey's classification.
- Mild, moderate and severe deformity was further divided into pliable if they more than 50 % of deformity could be corrected and if correction was less than 50% it was considered rigid.
- Out of 190 feet included in this study 24 were graded as mild, 76 as moderate and 90 as severe. In mild category out of 24, 12 were pliable and 12 were rigid. In moderate category 34 feet were pliable and 42 were rigid. In severe deformity category 27 were pliable and 63 were rigid.

Deformity	pliable	rigid
Mild	12	12
Moderate	34	42
Severe	27	63

PIRANI SCORE

TABLE SHOWING PIRANI SCORE

GRADE	SCORE
Grade I	0.5-1.0
Grade II	1.5-2.0
Grade III	2.5 -3.0
Grade IV	3.5-4.0
Grade V	4.5-5.0
Grade VI	5.5-6.0 and above

Period of study (Jan 2006 to Dec 2016)

Category of patient	No.of patients (456)	No.of feet (684)
No .of patients below 3 weeks or below	157	232
Excluded spinal dysraphism	12	24
Arthrogryposis multiplex congenital	9	18
Patients included in study	136	190

Excluded 21 patient	No.patient	Feet
Spinal dysraphism	12	24
Arthrogryposis multiplex congenital	9	18

• **Age of feet(total 190)**

Age	No of feet	% age
3-7 days	45	23.68
8-14 days	84	44.21
15-21 days	61	32.11

• **Classification /grading of deformity in 190 feet**

Grade	Pirani score	Pandey's classification
Grade 1	0.5-1.0	mild
Grade 2	1.5-2.0	mild
Grade 3	2.5-3.0	moderate
Grade 4	3.5-4.0	moderate
Grade 5	4.5-5.0	severe
Grade 6	5.5-6.0and above	severe

TREATMENT

- All patient were treated with standard **Ponseti 's technique** without any modification.The manipulation of the foot and above knee at the right angle POP cast were carried out at an interval of **7-10 days** depending upon the convenience of the patients.
- First deformity to be corrected was **cavus** deformity by lifting the first ray on to the head of talus.,thereby reducing the downward subluxation of navicular over the head of talus.This slightly exaggeration of inversion of the foot.Second manipulation was abduction of the fore foot over the hind foot correction the adduction deformity and reducing the medial subluxation of navicular into the head of talus.
- One to four such manipulation was done to achieve correction of adduction deformity.Most of the inversion of the foot got corrected by this manuevere.Anypersistant inversion was now corrected by everting the heel and abducting the foot.
- When the correction of cavus ,adduction and inversion was achieved ,plantar flexion was corrected.In 126 feet ,closed **tenotomy of tendoachilles** was carried ,POP cast was continue for another 3-6 weeks.We continue to giving the above knee POP cast even **after tenotomy of tendoachilles** because in 7 patients,the patient was able to pull out the foot from the cast and cast was discarded.

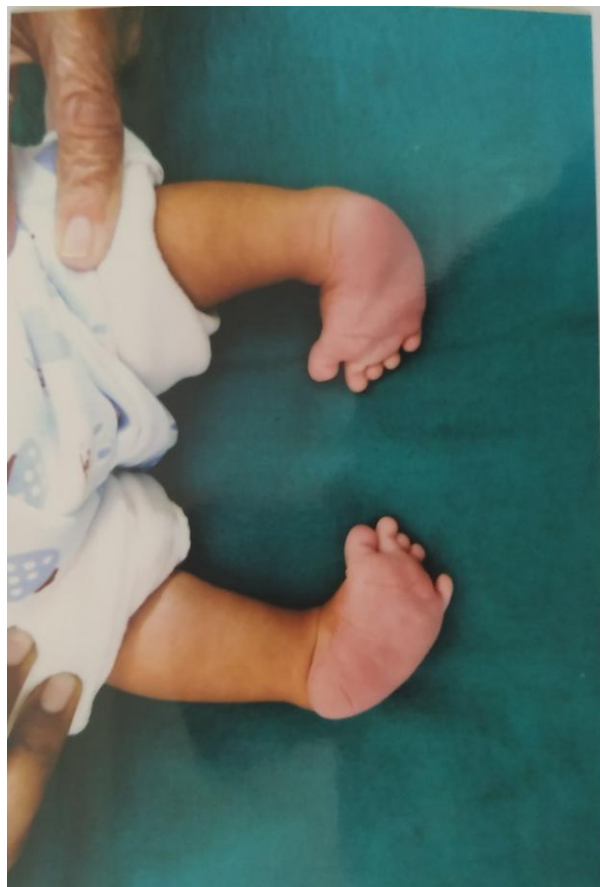

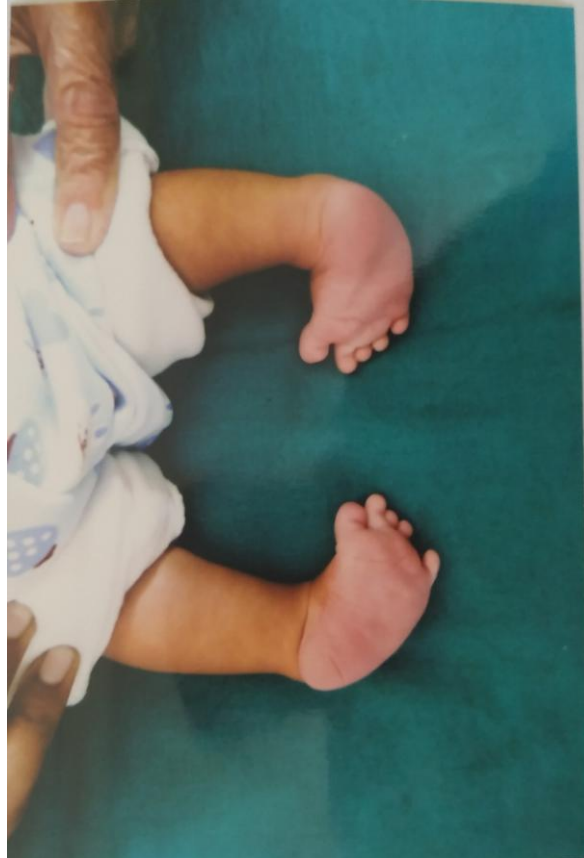Image of clubfoot before treatment



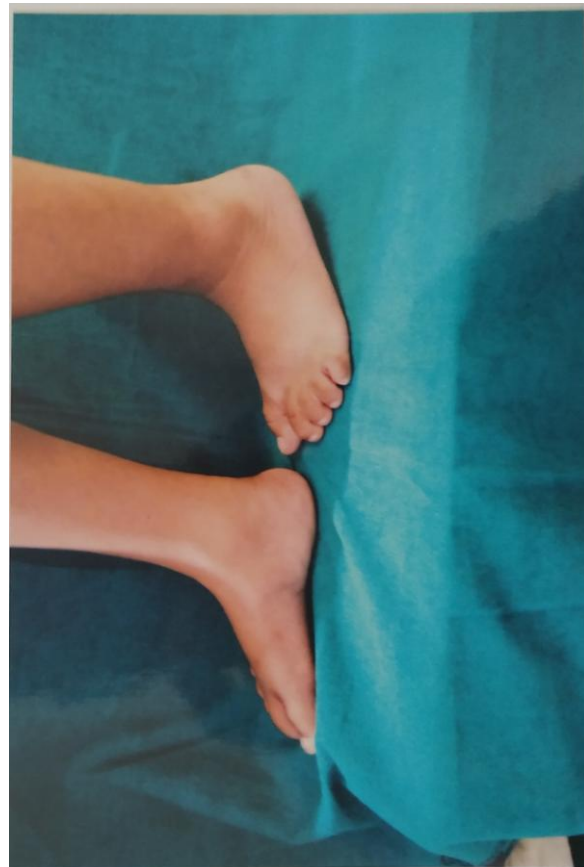Image of clubfoot at follow up



Image of clubfoot after treatment



Clubfoot before treatment



Treated clubfoot

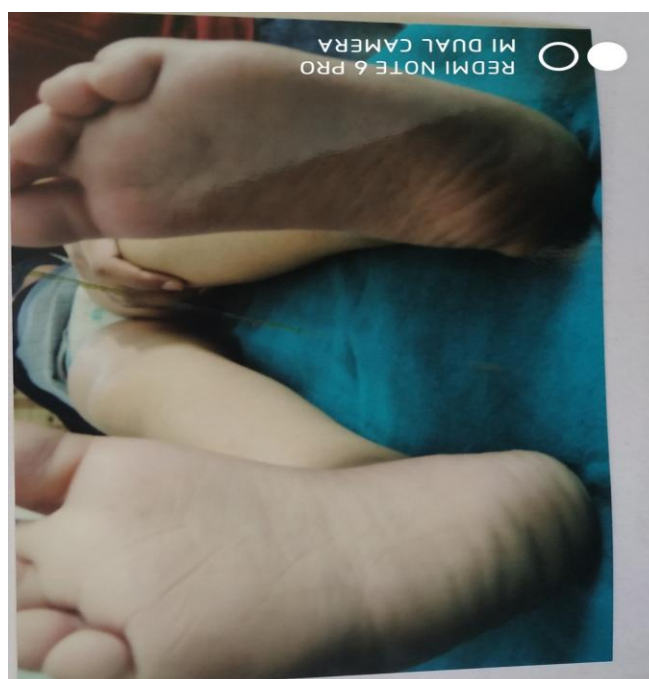
POST CORRECTION PROGRAMME

- The parents were advised to manipulate the foot **into abduction ,eversion ,and dorsiflexion** 5 times a day and 5 times each occasion.They were clearly informed that this deformity is lightly to recur in case the instruction were not followed particularly the application of splints and Foot ankle orthosis.
- The child was fitted **with soft talipes shoes** with **Dennis Brown Bar** to keep the foot at right angle and in abduction and eversion and was advised to wear the splint for at least 21 to 22 hours a day.
- At the age of 11-12 months ,when the child showed desire to stand up and walk ,the child was fitted with **talipes shoes without Dennis Brown Bar,but same was reapplied** when the child went to sleep.
- This was advised to be continue up to **theage of 2 years**,then during day,the child used to wear talipesshoes **at night**,he was given Foot ankle orthosis up to the age of 4-5 years.
- Follow up was carried out every months up to the age of two years and then every 2-3 months up to **the age of 5 years and after that every 3-6 months**.
- At the slightest indication of relapse of any deformity ,the foot was manipulated again,the deformity corrected and POP cast for 3-6 weeks was applied.

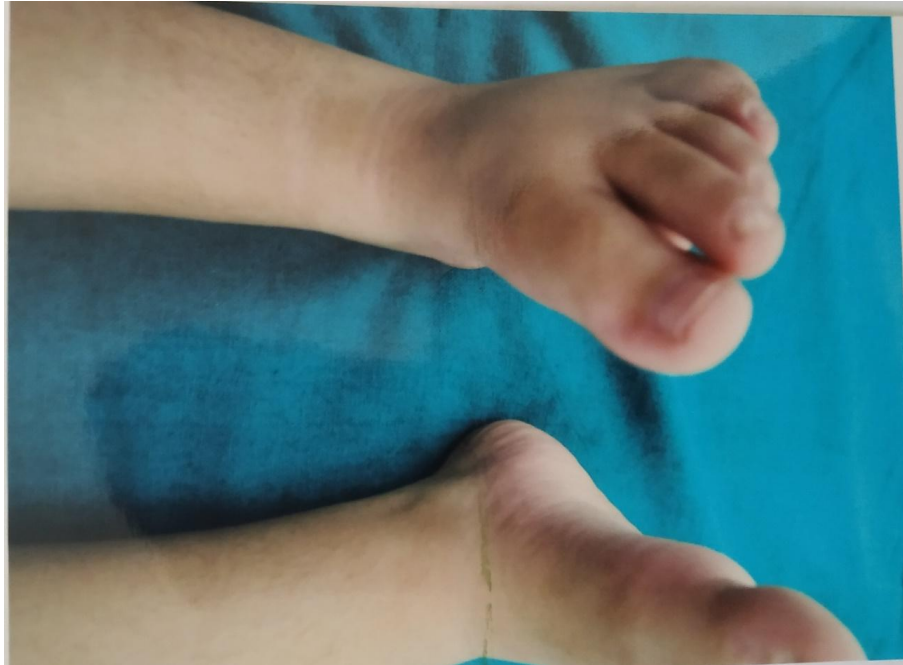
RELAPSE

Deformity	No.of feet	Relapse	% (percentage)
Mild deformity with pliable	12	0	0.00
Mild deformity with rigid	12	3	1.58
Moderate deformity with pliable	34	12	6.32
Moderate deformity with rigid	42	28	14.74
Moderate deformity with pliable	27	18	9.47
Marked deformity with rigid	63	57	30.00
Total	190	118	62.11

- 12 patient with mild deformity and pliable foot had no recurrence.12 patient with Mild deformity with rigid in 3 feet. **Moderate deformity** and pliable foot 34 patients had 12 recurrence, Moderate deformity and rigid **in 42 feet had 28 recurrence** . **Marked deformity and pliable** in 27 had 18 recurrence and marked deformity and rigid in 63 had 57 recurrence .
- If there was any relapse of deformity the foot was again manipulated and put into **POP cast for 3-6 weeks**.
- **Any second relapse** was treated surgically except in 3 cases which were in POP cast.



Relapse clubfoot



Relapse clubfoot

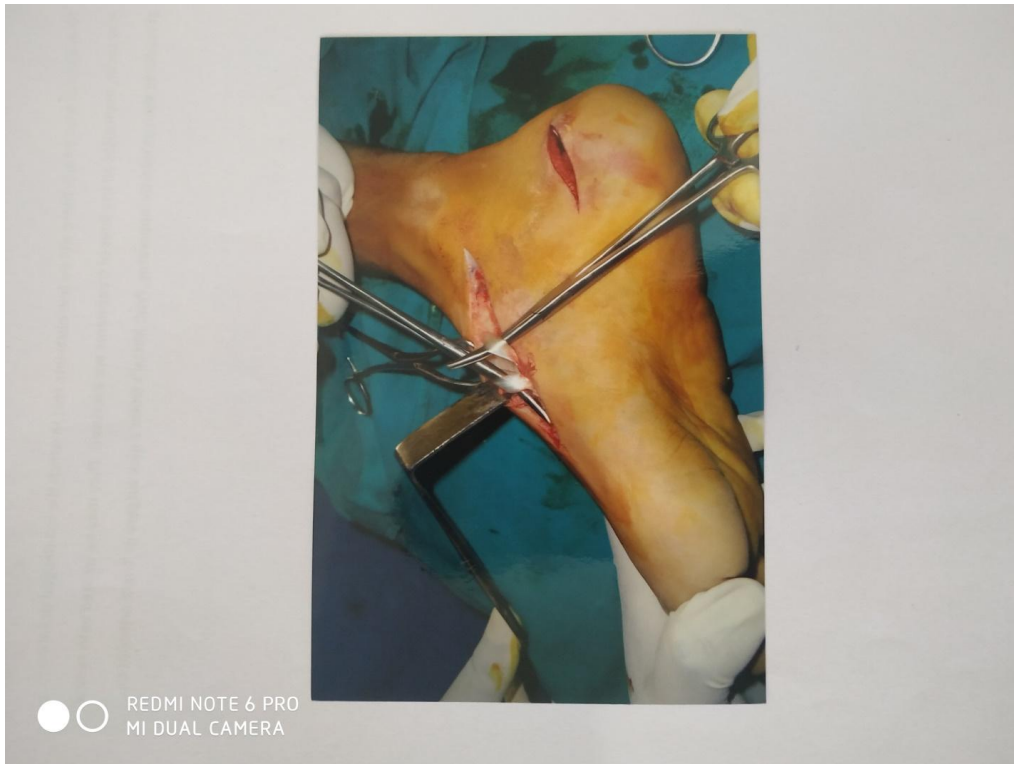MANAGEMENT OF RELAPSE

- Any relapse of deformity was treated with **manipulation and POP cast for 3-6 weeks** and **second relapse was treated with surgery except in 3 patients where POP cast was given for 3-6 weeks**.
- There was relapse of single deformity in 24 feet and combination of various **deformity in 92 feet**.
- Causing factor in the feet was **tight tendo-achilles**, tight plantar **aponeurosis and plantar structure**. Tight tibialis anterior, tight tibialis posterior and Henry's **knot, metatarsal adductus, weakness of peronei muscle**.

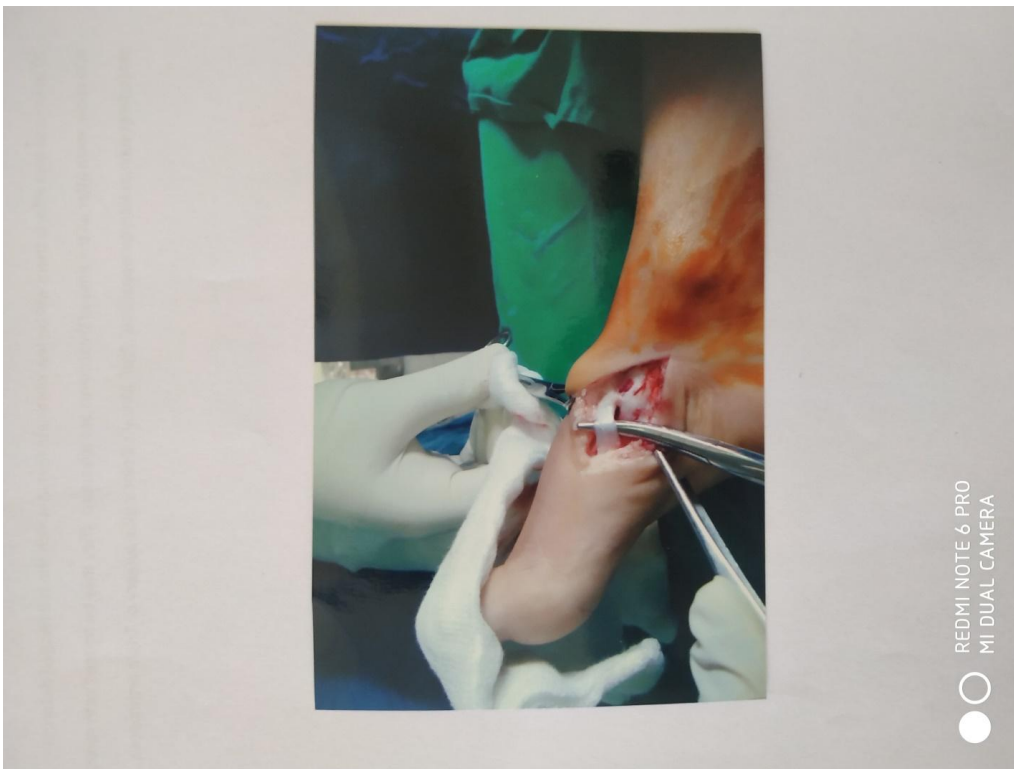OPERATIVE PROCEDURE

- 1. Tendo Achilles tenotomy or lengthening.**
- 2. Plantar release**
- 3. Full fledged posteromedial release.**
- 4. Sanctioning of posterior capsule of ankle and subtalar ligament.**
- 5 Sanctioning of interosseous tibio fibular and anterior tibio fibular ligaments.**
- 6 Calcaneal osteotomy.**
- 7 Tibialis anterior lengthening.**
- 8 Additional lateral release and release of sub talar ligaments.**
- 9 JESS fixator.**
- 10 Split Tibialis anterior transfer**
- 11 Peroneal shortening**
- 12 Osteotomy of the metatarsal**

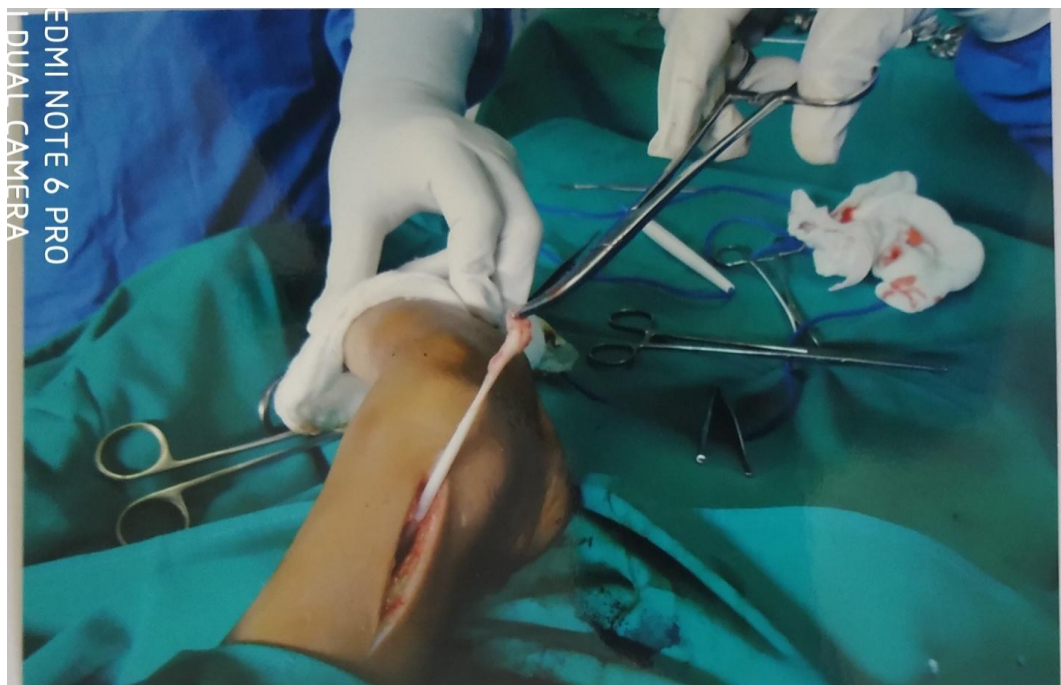
- **115 relapse** were treated by one or two POP cast of 3 weeks duration
- **Recurrence** was treated surgically except in 3 cases who are refuse operation.



Tibialis anterior splits into two parts near insertion and two parts shown



Tibialis anterior splits into two parts near insertion and two part shown



Tibialis anterior pulling through tunnel into plantar surface

TREATMENT OF RELAPSE RESULT

TREATMENT	No.of patients	No.ofsuccessful	No.of failure
POP cast	115	15	100
TA lengthening	21	12	9
Plantar release	36	25	11
Lengthening of Tibialis anterior	7	7	0
Postero medial release	52	42	10
Postero medial release andpostero lateral release	14	7	7
Tibio fibular interosseous ligament	57	0	0
Calcaneal Osteotomy	7	7	0
JESS fixation	5	5	0
Split Tibialis anterior transfer	7	7	0
Peroneal shortening	3	2	1
Osteotomy of the metatarsal	6	6	0

- Some of these procedure were carried out in second or third relapse.

FINAL RESULT

Normal feet	64(33.68)	Excellent
Occult equinus	75(39.47)	Good
Slight metatarsal adductus	25(13.15)	Fair
Slight inversion	19(8.42)	Fair
Equinovarus deformity	7(3.68)	Poor

- The treatment planned or under consideration in these 7 cases is either **ilizarov** technique or **Prof .Mital'sDolors Plus** technique or Triple arthrodesis.
- Further treatment planned in 7 feet with poor result and which is under consideration with either application of **ilizarov apparatus** or **Prof .Mital'sDolors Plus technique** or **triple arthrodesis** at appropriate time.

IV. Observation And Conclusion

1.Genetic factor as some role in etiology of **congenital talipesquinovarus** as there were **9 patients with 16 feet** who had positive family history and 2 patients were first cousins.Six patients were **muslim**family with consanguineous marriages.

2.It is easier to stretch the soft tissues at younger age than later because the soft tissues are pliable and it is also easy to maintain the corrected position amongst during application of the **POP cast**, because with the age the tissue loose their elasticity and required more force to stretch them .The child become more powerful and struggles a lot during the application of **POP CAST** and additional assistant is often required to keep the limb immobilized.

3.Regular follow up at monthly interval in the beginning and 2-3 months later on is absolutely essential in detecting the relapse at early stage and treat it It is of definite of advantage to educate the parents how to care the child be regular and rigid in the timing for which the splints and orthosis are applied .It is also of advantage to prevent the relapse by frequently manipulating the foot into abduction, eversion and dorsiflexion on five occasion and each time manipulating 5 times holding the foot in corrected position for few second each time.

4.The treatment for any relapse must be started immediately , the conservative in the beginning may produce lasting effect but if surgical is required ,it should also be done in time.

5.Above knee **POP cast** with knee at right angle is the ideal ,even after **tendinous tenotomy** or any other procedure.

6.Second and third relapse are not uncommon and must be tackled as required even if repeat surgery is required .

7.Muscular imbalance like weakness of peronei has to be treated by suitable tendon transfer , in this study split tibialis anterior as advocated by **Grewal and Girgla in 1964**.

8.Often the cause of multiple relapse is discrepancy **between the growth of soft tissue and bone** which may be growing at rapid rate than soft tissue .

9.Proper cooperation **and commitement** of parents as well as treating surgeon are required in achieving the good results.

10.In spite of best efforts there will be few obstinate feet in which the full fledge deformity may recur ,even after all the lines of treatments are executed .They may be treated by radical procedure such as **Illizarov apparatus ,Prof.Mittal’sDolor”z plus surgery or triple arthrodesis**.

V. Summary

- Out of this only **157 patient with 232 feet reported up to 3 weeks of age twenty one patient with 42 feet were excluded from this study** because 12 patient with 24 feet had spinal dysraphism and 9 patient were Arthrogryposis multiplex congenital ,remaining 136 patient with **190 feet** form the basis of study.`
- Out of **136 patient ,9 patient with 16 feet** had positive family history,6 patient belong to **muslimcommunity with consanguineous marriage** were first cousins. There are 3 patients with 4 feet with history of mother taking drugs during the **1st trimester of pregnancy** ,2 patient had taken medication for morning sickness and 1 for viral infection.
- Out of **190 feet include in the study 24** were graded as mild,76 as moderate and 90 as severe deformity.
- All patient were treated with **standard Ponseti technique** without any modification .The manipulation of the foot and above knee at the right angle POP cast were carried out an interval of **7-10 days** depending upon the convenience of the patients.
- The parents were advised to manipulate the foot in **abduction , eversion,and,dorsiflexion,5 times a day and 5 times each occasion**.
- The maintenance of correction by orthotic device e.g. **Dennis Brown splint ,softtalipes shoe**.
- The percentage of relapse is less in mild deformity with **pliable or rigid foot** and more in marked deformity with rigid foot.
- Any relapse of deformity was treated with manipulation and **POP cast for 3-6 weeks and** second relapse was treated with surgery.
- Causing factor in the feet was **tight tendo-achilles ,lengthening** or **tenotomy** posteromedial soft tissue release ,calcaneal osteotomy, tendon transfer etc.
- Highest failure rate of relapse in cases **treated by POP cast and lower failure rate of relapse in surgically treated cases**.
- Prognosis of relapse is **worst in equinovarus** deformity and excellent in normal foot.
- **Earlier the treatment** stared as better result in relapse treatment.
- **Prognosis of recurrence** is more worse in multiple deformity than single deformity.

- **Limitation**-this is a retrospective study therefore only those features for CTEV have been available in the hospital records. It does not contain all the features in fresh cases.

References

- [1]. Treatment of complex idiopathic clubfoot **Ignacio V Ponseti, Miroslav Zhivkov, Naomi Davis, Marc Sinclair, Matthew B Dobbs, Jose A** clinical orthopaedics and related research @451,171-176,2006.
- [2]. observation on pathogenesis and treatment of **congenital clubfoot Ignacio V Ponseti, Jeronimo Campos** clinical orthopaedics and related research @84,50-60,1972.
- [3]. **congenital clubfoot result of treatment Ignacio V Ponseti Eugene N Smoley** JBJS 45(2),261-344,1963.
- [4]. **Pirani S Outerbridge HK Sawatzky B et al(1999)** reliable method of clinically evaluating virgin clubfoot evaluation .In proceeding of the 21st SICOT world congress , Sydney,Australia.
- [5]. **Ponseti IV, Smoley EN (1963)** congenital clubfoot : the result of treatment.J BONE J surgery Am 45-A :261-275.
- [6]. **Morcuende JA Dolan LA , Dietz FR et al (2004)** radical reduction in the rate of extensive corrective surgery for clubfoot using the Ponseti method. Pediatrics 113:376-380.
- [7]. **Ponseti IV (1992)** current concept review :treatment of congenital clubfoot.J BONE J surg Am 74(3):448-454.
- [8]. **Laaveg SJ, Ponseti IV (1980)** long term result of congenital clubfoot.J Bone J surg Am 62-A :23-31.
- [9]. **Pirani S Outerbridge H, Moran M ,Sawatzky BJ.** A method of evaluating the virgin clubfoot with substantial interobserver reliability,Miami, Florida: POSNA; 1995;71:99.
- [10]. **Pirani S Hodges D , Sekeramiy F.** A reliable and valid method of assessing the amount of deformity in the congenital clubfoot deformity(The Canadian orthopaedic research society and Canadian orthopaedic association conference proceeding). J BONE Joint surg Br 2008 ; 90-B Suppl:I:53.
- [11]. **Pirani S Zeznik L Hodges D.MAGNETIC resonance imaging** study of congenital clubfoot related with Ponseti method .J pediatric orthop 2001;21:719-726.
- [12]. **Pirani S Maddumba E ,Mathias R,Konde –Lule J penny N, Beyeza T,Mbonye B ,Amoni J,Franceschi F(2009)** towards effective ponseti clubfoot care:the Uganda sustainable clubfoot care project.rch.clinicalorthopaedics and related research 467: 1154-1163.
- [13]. **Morcuende J (2006)** congenital idiopathic clubfoot: prevention of late deformity and disability by conservative treatment with the Ponseti technique .Pediatrics Annals 35(2):128-136.
- [14]. **Ponseti IV Campos J (1972)** observation on pathogenesis and treatment of congenital of congenital clubfoot .clinical orthopaedics and related research 84:50-60.
- [15]. **Kite J (1963)** some suggestion on treatment of clubfoot by cast . Journal of bone and joint surgery 45:406-412.
- [16]. **Morcuende J , Dolan L, Dietz F and Ponseti (2004)** radical reduction in the rate of extensive corrective surgery for club foot using Ponseti method .Pediatrics 113:376-380.
- [17]. **Pandey S Pandey AK.**clinical classification of clubfoot. Foot and ankle 1991;11(5):329.
- [18]. **Morcuende JA, Abbasi D, Dolan LA, Ponseti IV .**Result of an accelerated ponseti protocol for clubfoot. J Pediatric orthop.2005;25:623-626.
- [19]. **Laaveg SJ, Ponseti IV .** long term result of treatment of congenital clubfoot. J Bone joint surgery Am.1980;62(1):23-31.
- [20]. **Ponseti IV** common error in the treatment of congenital clubfoot.INT Orthop.1997;21(2):137-141
- [21]. **Shaheen S Jaibala H,Pirani S .**Interobserver reliability in pirani clubfoot severity scoring a pediatric orthopedic surgeon and physiotherapy assistant .J Pediatric orthop.2012; 21(4):366-368.
- [22]. **MCKAY sd ,Dolan LA , Morcuende JA ,**treatment of late relapsing idiopathic clubfoot previously treated by Ponseti method .J pediatric orthop.2012;32(4):406-411.
- [23]. **Ponseti IV.**The treatment of congenital club foot .J orthop sportsphysiotherapy.1994;20(1):1.
- [24]. **Ponseti IV** correction of talar neck angle in congenital clubfoot with sequential manipulation and casting .Iowa orthop J.1998.18:74-75.
- [25]. **Ponseti IV clubfoot management.**J pediatric orthop.2000,20(6), 699-700.
- [26]. **IV Ponseti and E.N. Smoley,**the classical congenital clubfoot: the result of treatment,.clinicalorthopaedics and related research ,vol 467,no.5,pp.1133-1145,2009.
- [27]. **Joshi BB ,Laud NS, Warriar S, Kanaji BG,Joshi AP, Dabake H.**treatment of CTEV by Joshi external stabilization system (JESS).In kulkarni GS ,editor .Textbook of orthopaedic and trauma .1st edition vol.4, new delhi: Jaypee Brother medical publishers ,1999.
- [28]. **Gupta PI ,Bither N.Illizarov in relapse clubfoot : A necessary evil?** J pediatric orthop B 2013; 22:589-594.
- [29]. **Lichtblau S .A** medial and lateral release operation for clubfoot.A preliminary report.. J Bone joint surgery Am 1973;55:1377-84.
- [30]. **Turco VJ.**surgical correction of the resistant clubfoot. One stage posteromedial release with internal fixation.A preliminary report.. J Bone joint surgery Am 1971;53A:477-497.
- [31]. **Kite JH.**Non operative treatment of congenital clubfoot: A review of 100 cases. South Med J 1930;23:337.
- [32]. **Kite JH** principle involved in the congenital clubfoot.J Bone joint surgery Am 1939;21:595-606.
- [33]. **Kite JH.**some suggestion on treatment of clubfoot by cast.. J Bone joint surgery Am 1963:45-A :406-412.
- [34]. **MCKay DW.** New concept of and approach to clubfoot treatment section II-correction of clubfoot. J pediatric orthop 1983; 3:10-21.
- [35]. **MCKay DW.** New concept of and approach to clubfoot treatment section III-evaluation and results.J pediatric orthop 1983; 3:141-8.
- [36]. **Brockman E .**Relapse clubfoot by Dilwyn Evans.J Bone joint surgery Am 1963:143:538;42.
- [37]. **Bohm M .**pathological anatomy of clubfoot. .J Bone joint surgery Am 1963:45:45-52.
- [38]. **Evan D R.**relapse clubfoot. J Bone joint surgery Am 1961: 43B :722-33.
- [39]. **Simons GW .COMPLETE SUBTALAR RELEASE** in clubfoot. part II- comparison with less extensive procedures.J Bone joint surgery Am 1985;67:1056-65.
- [40]. **Phleps AM .**The present status of open incision method for talipes equinovarus.Med res.1890;38:22.
- [41]. **Crawford AH .Marxen JL,Osterfeld DL.**The Cincinnati incision: A Comprehensive approach for surgical procedure of the foot and ankle in childhood .J Bone joint surgery Am 1982;64:1355-8.
- [42]. **Cooper DM, Dietz FR.** Treatment of idiopathic clubfoot: a thirty year follow up note. J Bone joint surgery Am 1995;77-A: 1477-89.
- [43]. **Dobbs MB, Gordon JE ,Walton T.Schoenecker PL.** Bleeding complication following percutaneous tendo Achilles tenotomy in the treatment of clubfoot.pediatrorthop 2004;24:353-7.
- [44]. **Mittal RL .**The surgical management of relapse clubfoot by rotation skin flap and extensive soft tissue release .International orthopaedics SICOT.1987;11:189-192.

- [45]. **Carroll N:** Preoperative clinical assessment of clubfoot .Simmons GW (ed):The clubfoot .1993,97-8.
- [46]. **Dwer FC.** Osteotomy of the calcaneum for pes cavus .J Bone joint surgery Am,1959;41-80.
- [47]. Conservative management of idiopathic clubfoot ;Kite versus **Ponseti method** .journal of orthopaedic surgery 2009;17(1):67;71.
- [48]. **Caterrall A.** A method of assessment of the clubfoot deformity.Clinorthop related res 1991(264):48-53.
- [49]. **DyerPJ,Davis N.T** has role of Pirani scoring system in the management of clubfoot using the ponsetimethod..J Bone joint surgery Br 2006;88(8):1082-1084.
- [50]. **Herzenberg JE Radler C, BorN.Ponseti** versus traditional method of casting for idiopathic clubfoot.J pediatric orthop 2002;22(4);517-521.S

Dr. Pancham Prasad, et. al. "Etiology and Management of Relapse of Clubfoot after Ponseti Method of Treatment." *IOSR Journal of Dental and Medical Sciences (IOSR-JDMS)*, 19(9), 2020, pp. 22-50.