

## A Study on Secondary Neck Nodes from Squamous Cell Carcinoma of the Head and Neck Region

PROF DR. K. KESAVALINGAM M.S., DR. C. VIJAYALAKSHMI

Department of General Surgery, GMKMCH, Salem, Tamil Nadu

### ABSTRACT

**AIM:** To find out the incidence of cervical node metastases on clinical examination in squamous cell carcinoma of the head and neck region. To find the incidence of cervical nodal metastases commonly involved according to the primary tumour at the time of presentation. To describe the distribution of cervical node metastases by the site of the primary tumour. To correlate individually the size of the tumour and cervical nodal metastases. To correlate individually the degree of histopathological differentiation of tumour and cervical nodal metastases.

**METHODS:** The materials used in the study consisted of 60 cases of histologically proven squamous cell carcinoma in the head and neck region which were admitted in all surgical wards of Government Mohan Kumaramangalam Medical College and Hospital, Salem during June 2018 – June 2020.

**RESULTS:** Males are predominantly affected by squamous cell carcinoma of head and neck region. 75% of patients had nodal metastasis at the time of admission. Posteriorly situated tumours displayed greater propensity of nodal metastases than anteriorly situated tumours. Carcinoma arising in the buccal mucosa, alveolus, floor of mouth, hard palate and maxillary antrum predominantly metastasized to the submandibular nodes, whereas those arising in the tongue (both anterior 2/3rd and posterior 1/3rd), tonsils and soft palate predominantly metastasized to the upper deep cervical group. A progressive increase in the incidence of node metastases was observed with increasing tumour size. A progressive increase in the incidence of node metastasis was observed with increasing histological undifferentiation of the tumour.

**CONCLUSION:** Males are predominantly affected by squamous cell carcinoma of head and neck region. 75% of patients had nodal metastasis at the time of admission Site of the primary appeared to influence the incidence of regional nodal metastases. Posteriorly situated tumours arising in the oropharynx (base of tongue, tonsils, soft palate) displayed a greater propensity for regional metastases(66% to 100%) as compared to anteriorly situated tumours arising in the oral cavity(33% to 83%). Amongst the posteriorly situated tumours, carcinoma of the tonsils showed the highest incidence of nodal metastases(100 percent). Amongst the anteriorly situated tumours, carcinoma of buccal mucosa showed the highest incidence of node metastases (83.33%). The large primaries (more than 4cm) and those with higher histologic grade (moderate to poorly differentiated) have a greater propensity for developing regional nodal metastasis.

Date of Submission: 26-12-2020

Date of Acceptance: 07-01-2021

### I. Introduction

Squamous cell carcinoma of the head and neck especially those arising in the oral cavity and oropharynx account for more than 50 % of all cancers in India. More than 30 % of these patients have clinical evidence of cervical node metastases when first seen. The presence of an enlarged node proven histological positive for metastases is an ominous sign and as a general rule decreases the 5 year survival rate by at least 50 percent.

In the present study an attempt has been made to determine the tumour factors increase the propensity for regional metastases in squamous cell carcinoma of the head and neck, so as to help, identify the cluster of high risk patients who are likely to harbour occult nodal disease in the absence of clinically negative nodes and for whom elective neck treatment may prove beneficial.

9 areas of the head and neck including 5 primary sites in the oral cavity, 3 in the oropharynx and the maxillary antrum have been considered under the preview of this study, as these were the sites involved in the patients presenting with squamous cell carcinoma of the head and neck in the surgical department of our hospital.

### II. Aims And Objective

To find out the incidence of cervical node metastases on clinical examination in squamous cell carcinoma of the head and neck region. To find the incidence of cervical nodal metastases commonly involved according to the primary tumour at the time of presentation. To describe the distribution of cervical node

metastases by the site of the primary tumour. To correlate individually the size of the tumour and cervical nodal metastases. To correlate individually the degree of histopathological differentiation of tumour and cervical nodal metastases.

### III. Materials And Method

#### STUDY AREA

Government Mohan Kumaramangalam Medical College and Hospital, Salem

#### STUDY POPULATION

Patients who were histologically proven squamous cell carcinoma in the head and neck region admitted in all surgical wards of Government Mohan Kumaramangalam Medical College and Hospital, Salem during June 2018 – June 2020.

#### INCLUSION CRITERIA

All patients who were histologically proven for squamous cell carcinoma

#### EXCLUSION CRITERIA

Patients with cervical node metastasis other than squamous cell carcinoma

#### STUDY PERIOD

June 2018 – June 2020

#### SAMPLE SIZE:

60 cases

All patients eligible by inclusion and exclusion criteria are to be included in the study.

#### STUDY DESIGN

A Prospective study is to be conducted on patients admitted in surgical wards of Government Mohan Kumaramangalam Medical College and Hospital , Salem with diagnosis of squamous cell carcinoma in head and neck region.

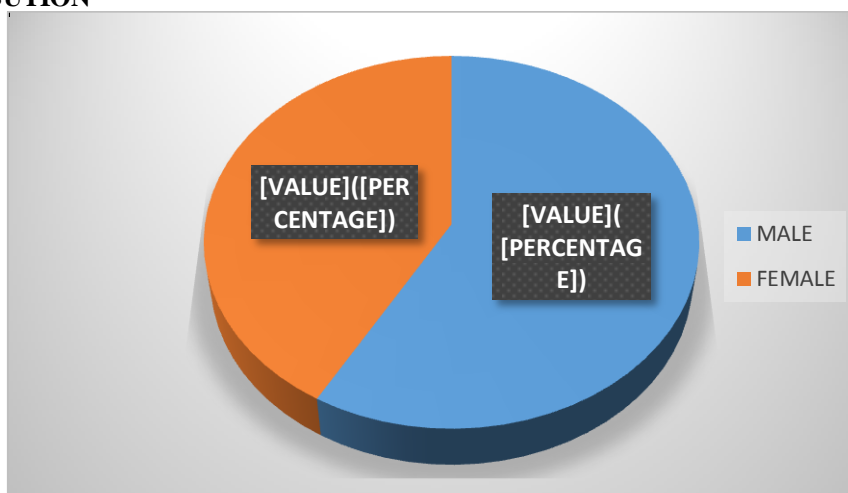
Informed consent will be taken from each respondent.

### METHODS

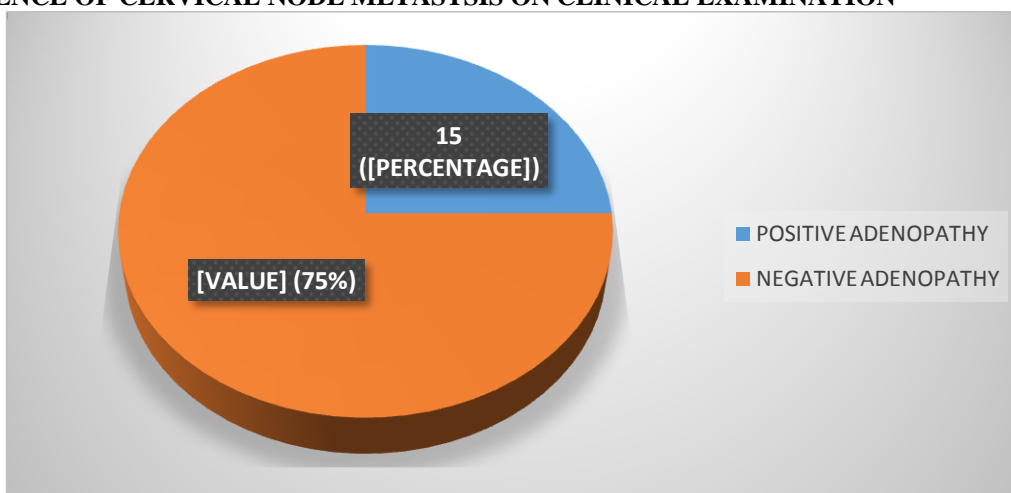
A detailed history was obtained regarding the nature and duration of presenting complaints as well as of all other associated complaints particular attention being paid to factors increasing the likelihood of malignancy. Complete physical examination including an indirect laryngoscopy in selected cases was done to note characteristics of the primary in terms of site, extent, size(in cm.), macroscopic appearance , degree of local infiltration, presence of other synchronous lesions and T stage of tumour. The criterion for “a clinically positive node” as defined by Lindberg was used to differentiate metastatic from non metastatic nodes throughout the study. Biopsy from the primary site was obtained in all the cases included in the study to obtain histological proof regarding its nature as well as to note its degree of differentiation.

### IV. Results

#### SEX DISTRIBUTION



**INCIDENCE OF CERVICAL NODE METASTASIS ON CLINICAL EXAMINATION**



**INCIDENCE OF CERVICAL NODE METASTASIS BY SITE OF PRIMARY**

PRIMARY	NO. OF CASES	PERCENTAGE	NON PALPABLE NODES	PALPABLE NODES	PERCENTAGE
Buccal Mucosa	18	30%	3	15	83.33%
Alvelous	7	11.6%	3	4	57.14%
Hard Palate	3	5%	2	1	33%
Floor of mouth	4	6.6%	1	3	75%
Soft Palate	3	5%	1	2	66%
Anterior 2/3 toungue	11	18.3%	2	9	81%
Posterior 1/3 toungue	7	11.6%	1	6	85.7%
Tonsil	4	6.6%	0	4	100%
Maxillary antrum	3	5%	2	1	33%

**DISTRIBUTION OF CERVICAL NODE METASTASIS BY SITE OF PRIMARY**

PRIMARY	NO METASTASIS	I A	I B	II	III	IV
Buccal Mucosa	3	-	13	2	-	-
Alvelous	3	1	3	-	-	-
Hard Palate	2	-	1	-	-	-
Floor of mouth	1	1	2	-	-	-
Soft Palate	1	-	2	-	-	-
Anterior 2/3 toungue	2	-	2	6	1	-
Posterior 1/3 toungue	1	-	1	5	-	-
Tonsil	-	-	-	2	1	1
Maxillary antrum	2	-	1	-	-	-

**CORRELATION BETWEEN TUMOUR SIZE AND CERVICAL NODE METASTASES**

TUMOUR SIZE(cm)	NO. OF CASES	NON PALPABLE NODES	PALPABLE NODES
0 - 2	18	10	8
2.1 - 4	34	10	24
>4	8	-	8

**CORRELATION BETWEEN TUMOUR DIFFERENTIATION AND CERVICAL NODE METASTASES**

DEGREE OF DIFFERENTIATION	NO. OF CASES	NON PALPABLE NODES	PALPABLE NODES
Well differentiated	30	10	20
Moderately differentiated	15	3	12
Poorly differentiated	15	1	14

## **V. Discussion**

Out of 60 patients with histologically proven squamous cell carcinoma arising from various primary sites in the head and neck who were ultimately included in the study. 35(58%) were males and 25(42%) were females. Palpable neck nodes were detected on admission in 45 patients (75%) and out of them 30 males (67%) and 15 females (33%).

The most frequent site of the primary in the present study was the buccal mucosa (18 patients) which accounted for 30% of the head and neck cancers. Next in frequency was the anterior 2/3 rd of the tongue 11 patients (18.3%) and alveolus 7 patients (11.6%). Posteriorly situated cancers arising in the oropharynx showed a comparatively lower frequency with the base of tongue having the highest 7 patients (11.6%). Overall the least frequent site was maxillary antrum 3 patients (5%).

Tonsils accounted for higher incidence of node metastasis accounting for 100% involvement in our study followed by Posterior 1/3<sup>rd</sup> of tongue(85.71%), Buccal mucosa (83.3%), Anterior 2/3<sup>rd</sup> of tongue, Floor of mouth (75%), soft palate (66%) and Alveolus (57%). Least incidence were from hard palate and maxillary antrum (33%).

Carcinoma of the buccal mucosa predominantly metastasized to the submandibular nodes. Only when very advanced (T4 with retro molar extension), they involve the upper deep cervical nodes. Sub mental node involvement was totally absent.

Carcinoma of the alveolus predominantly metastasized to sub mandibular nodes. Sub mental node involvement was infrequent.

Carcinoma of hard palate infrequently metastasized. The only one patient, in whom this happened, had involvement of the ipsilateral submandibular node. The lower incidence of cervical metastases in patients with cancer of the hard palate has been ascribed in the literature to a less extensive lymphatic network in the immobile palate mucosa. Although the number of patients with hard palate cancer was small in the present series, our findings appeared to confirm with this explanation.

Carcinoma of the anterior two third of the tongue most commonly involved the upper deep cervical group followed by the submandibular group of nodes. In only one instance, the middle deep cervical nodes involved. Involvement of nodal groups at a lower level in the neck was not seen. As none of the primaries involved the tip of the tongue, predictably sub mental node involvement was absent. Bilateral nodal involvement was present in one instance with involvement of the contra lateral submandibular nodes.

Carcinoma of the posterior one third of tongue most commonly involved upper deep cervical nodes and less frequently to submandibular nodes.

Carcinoma of the Tonsils most commonly metastasized to upper cervical nodes and remaining to middle and lower cervical nodes.

Carcinoma of the floor of the mouth predominantly metastasized to the ipsilateral submandibular nodes, inspite of the anterior location of the tumours and their proximity to the midline, sub mental node involvement was infrequent and contra lateral nodes were uninvolved at all.

Carcinoma of the soft palate commonly metastasized to upper deep cervical nodes. Although it is a midline structure, the incidence of the bilateral nodal involvement was nil.

Carcinoma of maxillary antrum metastasize rarely and in our metastasized to submandibular nodes.

Tumours of size larger than 4 cm had clinically palpable nodes at time of admission.

The degree of differentiation was found to influence the incidence of regional nodal metastases. Overall tumour differentiation showed an inverse relationship with the incidence of nodal metastases. Decreasing tumor differentiation was associated with increasing nodal spread.

## **VI. Conclusion**

1. 75% the patients had palpable nodes in the neck on admission.
2. Site of the primary appeared to influence the incidence of regional nodal metastases. Posteriorly situated tumours arising in the oropharynx (base of tongue, tonsils, soft palate) displayed a greater propensity for regional metastases as compared to anteriorly situated tumours arising in the oral cavity.
3. Amongst the posteriorly situated tumours, carcinoma of the tonsils showed the highest incidence of nodal metastases(100 %)
4. Amongst the anteriorly situated tumours, carcinoma of buccal mucosa showed the highest incidence of node metastases (83.33%)
5. With regard to topographical distribution for any given primary, certain nodal groups in the neck were involved more frequently than others. Carcinoma arising in the buccal mucosa, alveolus, floor of mouth, hard palate and maxillary antrum predominantly metastasized to the submandibular nodes, whereas those arising in the tongue (both anterior 2/3rd and posterior 1/3rd), tonsils and soft palate predominantly metastasized to the upper deep cervical group.

6. Tumour size appeared to have bearing on the incidence of cervical node metastases. A progressive increase in the incidence of node metastases was observed with increasing tumour size.
7. Tumour grade also appeared to influence the incidence of node metastasis. A progressive increase in the incidence of node metastasis was observed with increasing histological undifferentiation of the tumour.

### **Bibliography**

- [1]. Park and Park Textbook of Preventive and social medicine – cancer 19th edition
- [2]. The American cancer society's clinical oncology – Raymond E. Lenbard, Jr., M.D., Robert T. Osteen, M.D., Ted Gansler M.D.,
- [3]. Devita, Hellman, and Rosenberg's Cancer Principles & Practice of Oncology, 8th edition
- [4]. The M.D. Anderson Surgical Oncology Handbook IV edition, Barry W. Feig, David H. Berger, George M. Fuhrman.
- [5]. Bailey & love Short Practice of Surgery 25th edition 2008
- [6]. Shah JP, Candela FC, Poddar AK. The pattern of cervical nodemetastases from squamous carcinoma of the oral cavity. Cancer 1990;66:109-113
- [7]. Parkin DM, Pisani P, Ferlay J. estimates of the worldwide incidence of 25 major cancers in 1990. Int J Cancer 1999;80: 827-841
- [8]. Lindberg RD: Distribution of the cervical lymph nodes metastases from squamous cell carcinoma of upper aero digestive tracts. 29: 1446: 1972
- [9]. Lederman M: Cancer of pharynx; J laryngo oncology. 1967; 81:151
- [10]. Arthur K, Farrhow; Prognostic significance of histologic grade in epidermoid carcinoma of mouth and pharynx. Am J Surg. 1972; 124:149
- [11]. Sankaranarayanan R. Oral cancer in India: an epidemiologic and clinical review. Oral Surg Oral Med Oral Pathol Oral Radiol Endod 1990; 69:325-330
- [12]. Khafif RA, Gelbfish GA, Asase DK, Teppar P, Attie JN. Modified radical neck dissection in cancer of mouth, pharynx and larynx. Head and neck 1990;
- [13]. Last RJ, Anatomy Regional and applied: Edinburg Churchill 1994;
- [14]. Fisher B, Fisher ER: Studies concerning regional nodes in cancer. 1972
- [15]. Mackenzie JJ; The mouth, In Pm Stell: Scott and Brown's Otolaryngology Vol-5, Butterworth and Co Ltd: 1987

PROF DR. K. KESAVALINGAM M.S, et. al. "A Study on Secondary Neck Nodes from Squamous Cell Carcinoma of the Head and Neck Region." *IOSR Journal of Dental and Medical Sciences (IOSR-JDMS)*, 20(01), 2021, pp. 33-37.