

## Radiological and histopathological correlation of salivary gland pathologies.

Dr Shilpa Chudasama<sup>1</sup>, Dr Divyesh Sarvaiya<sup>2</sup>, Dr Daxa Khunt<sup>3</sup>,  
Dr Manukumar B<sup>4</sup>

<sup>1</sup>Associate Professor

<sup>2</sup>Second year resident

<sup>3</sup>Third year resident

<sup>4</sup>Second year resident

Department of Radiodiagnosis, Shri M.P. Shah Government Medical College and Shri Gurugobind Singh Government Hospital, Jamnagar.

Corresponding author: Dr Divyesh Sarvaiya

Resident, Department of Radiodiagnosis, Shri M.P. Shah Government Medical College and Shri Gurugobind Singh Government Hospital, P.N.Marg, Jamnagar, Gujarat, India – 361008

---

### Abstract

The present study aimed at studying the role MRI in salivary gland pathology with emphasis on diagnosis of salivary gland pathology and differential diagnoses of various salivary gland pathologies and to differentiate between malignant and benign lesions and its histopathological correlation

**Materials and methods:** - The present prospective study was carried out at department of radiology, Guru Gobind Singh Hospital and M P Shah Medical College, Jamnagar. Total 50 patients with salivary gland pathology were examined with MRI and MRI findings were correlated with histopathological diagnosis.

**Results:** - In our study of 50 patients, 60 % were male and 40% were female. Majority of the patients were adults which belongs to age group of 30 – 40 years. Among our patients 76% patients diagnosed as benign lesions on MRI and 26% were diagnosed as malignant lesion, most common benign lesion was pleomorphic adenoma (42%), the next common lesions were malignant mass lesions which consisted 26 % of the cases, among the malignant lesion most common was mucoepidermoid carcinoma. Third common lesion was sialoadenitis which consisted 14 % of the cases. Majority of lesions are found in parotid gland (78%), next common involvement is of submandibular gland (24%) and least involvement was of sublingual gland (2%). Majority of benign lesion was found in 30 -40 yrs of age and majority of malignant cases found in more than 40 yrs of age group.

**Conclusions:** MRI is very helpful in identification and characterisation of various pathologies involving salivary glands and able to detect malignant lesions involving salivary glands with very high sensitivity and specificity above 95% as correlation done with histopathology.

**Key Words:** Salivary glands, MRI, Histopathology

---

Date of Submission: 26-12-2020

Date of Acceptance: 07-01-2021

---

### I. Introduction

MRI plays a very significant and crucial role in diagnosis and management of the salivary gland lesions. In the recent years gradient-echo T2-weighted MR imaging have expanded the options for diagnosing patients with salivary gland disease. Imaging is useful in acute infections, sialolithiasis, primary (isolated) and secondary (associated with connective tissue diseases) Sjogren's syndrome, fungal infections, TB, sarcoidosis, Wegener's disease, granulomatous disease and various tumors. MRI also helps differentiate between malignant and benign lesions.

### II. Materials And Methods

The present study of 50 patients between time periods of March 2020 to November 2020 was carried out at department of radiology, Guru Gobind Singh Hospital and M P Shah Medical College, Jamnagar.

#### Study Population:

Patients of various age groups presenting to the ENT and surgical OPD with complaints swelling and or tenderness in salivary gland region are included in the study.

---

**Inclusion criteria:**

1. All the symptomatic Patients referred to radiology department for MRI scan of salivary gland pathology.
2. Only those patients fulfilling above mentioned inclusion criteria and willing to participate in study.

**Exclusion criteria:**

1. Patients presenting to radiology department having neck swellings not confined to salivary gland regions.
2. Patients with pace makers, metal implants in their bodies, foreign bodies in their eyes and those having claustrophobia.

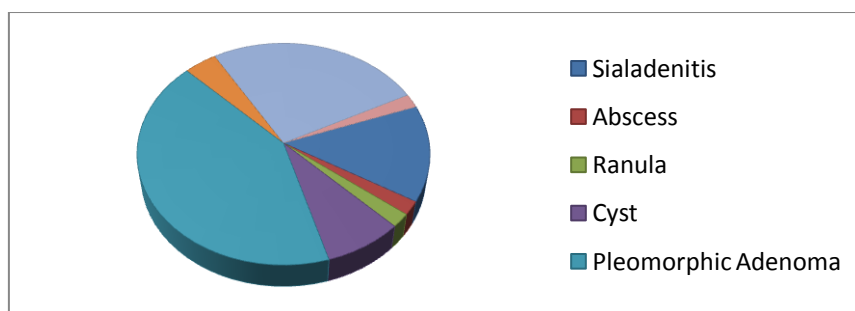
**Imaging technique:**

- For the routine MR examination, sagittal T1-weighted, spin-echo localizer images are obtained. Axial T1-weighted and fast spin-echo, T2-weighted images are then obtained through the field of interest. A coronal and axial STIR sequence also provides an additional orthogonal view.
- Sections 4 or 5 mm thick, with a 1-mm interstice gap, are mandatory to prevent volume averaging.

**III. Observations And Results**

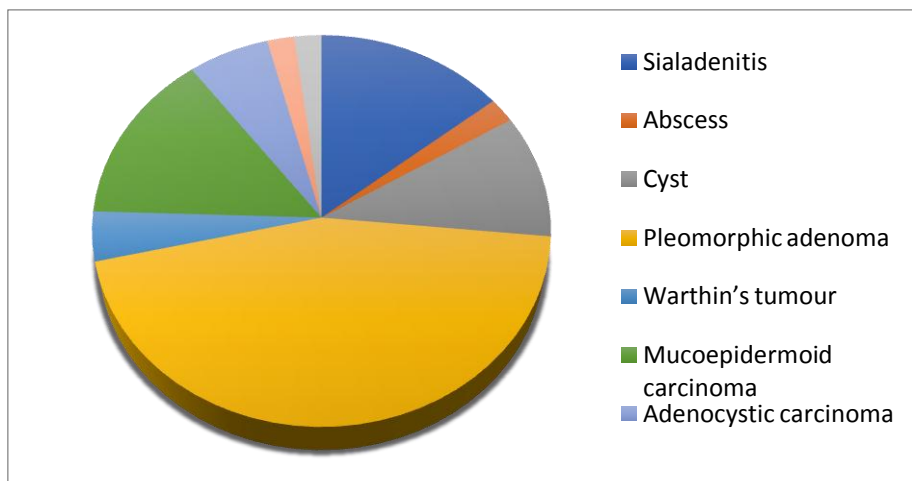
**TABLE-1  
FREQUENCY OF SALIVARY GLAND LESIONS BY MRI**

SR NO	MRI diagnosis	No. of cases	Percentage (%)
1	Sialoadenitis	7	14
2	Abscess	1	2
3	Ranula	1	2
4	Cyst	4	8
5	Pleomorphic adenoma	21	42
6	Warthin's tumour	2	4
7	Malignant mass	13	26
8	Venous malformation	1	2
	<b>Total</b>	<b>50</b>	<b>100</b>



**TABLE-2  
FREQUENCY OF SALIVARY GLAND LESIONS BY PATHOLOGICAL EXAMINATION**


NO	Pathological diagnosis	No. of cases	Percentage (%)
1	Sialoadenitis	7	14
2	Abscess	1	2
3	Cyst	5	10
4	Pleomorphic adenoma	21	42
5	Warthin's tumour	2	4
6	Mucoepidermoid carcinoma	8	14
7	Adenocystic carcinoma	3	6
8	Squamous cell carcinoma	1	2
9	Carcinoma ex pleomorphic adenoma	1	2
10	Venous malformation	1	2
	<b>Total</b>	<b>50</b>	<b>100</b>



**TABLE-3**  
**NUMBER OF BENIGN AND MALIGNANT LESIONS IN SALIVARY GLANDS ACCORDING TO MRI FINDINGS**

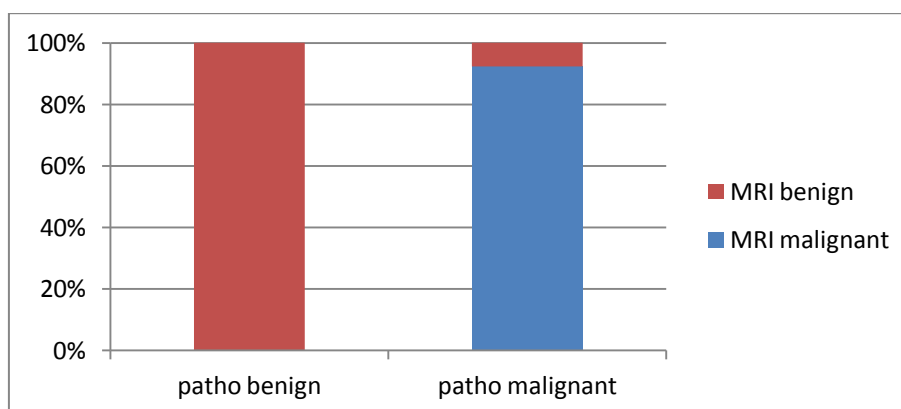
Lesion	No. of cases	Percentage (%)
Benign lesions	37	74
Malignant lesions	13	26
<b>Total</b>	<b>50</b>	<b>100</b>

In our study, majority of lesions were benign 74% of all cases .



**TABLE-4**  
**COMPARISON OF MRI FINDINGS VERSUS PATHOLOGICAL FINDINGS**

	Pathologically malignant	Pathologically benign	Total
<b>MRI malignant</b>	13	0	13
<b>MRI benign</b>	0	37	37
<b>Total</b>	<b>13</b>	<b>37</b>	<b>50</b>



Test	Disease				Total
	Present	n	Absent	n	
<b>Positive</b>	<b>True positive</b>	<b>a=13</b>	<b>False Positive</b>	<b>b=0</b>	<b>a+b = 13</b>
<b>Negative</b>	<b>False positive</b>	<b>c=0</b>	<b>True Negative</b>	<b>d=37</b>	<b>c+d = 37</b>
	<b>a+c = 13</b>		<b>b+d = 37</b>		

**INTERPRETATION**

On statistical analysis,

- The sensitivity of the study was found to be 100 % with 95% confidence interval.
- The specificity of the study was found to be 100% with 95% confidence interval.
- The positive predictive value of the test was found to be 100% with 95% confidence interval.
- The negative predictive value was found to be 100% with 95 % confidence interval.

**IV. Discussion**

**IMAGING IN SALIVARY GLAND PATHOLOGY**

**Acute sialoadenitis**

Infections are more common in the parotid gland than the submandibular glands;

**Chronic sialadenitis**

It can be due to infectious or non-infectious causes.

**Infections include-** mycobacteria, syphilis, actinomyces, and toxoplasmosis.

**Non infectious** - prior irradiation and autoimmune diseases like Sjogren’s syndrome.

On MR imaging, the parotid gland is variably enlarged, and the usual interstitial and ductal components are poorly seen compared to those of a normal gland. The gland can have either higher or lower than normal signal intensity on T2-weighted scans, depending on whether edema or cellular infiltration predominates.

**Sjogren’s syndrome**

It is a systemic autoimmune disease of exocrine glands, primarily affecting the salivary and lacrimal glands

On MR imaging, globular changes are present within the parotid glands, these collections can be seen on T1-weighted scans as discrete collections of low signal intensity, reflecting the watery saliva contained within them.

**HIV associated sialoadenitis:**

- Chronic parotitis in children is pathognomic of HIV infection.
- Multiple parotid cysts with gross parotid enlargement and facial distortion is noted.
- CT scan and MRI demonstrate characteristic Swiss cheese pattern.

**BENIGN TUMORS:**

**Pleomorphic adenoma or mixed tumor:**

- It is the most common salivary gland tumor accounting for 60-70% of all salivary gland tumors.
- It is 10 times more common in the parotid than the submandibular gland.
- 90% of parotid pleomorphic adenomas occur in superficial lobe.
- 25% are associated with satellite nodules away from the main tumor.
- Malignant transformation and calcification occur in long standing cases. If left untreated, 25% will undergo malignant degeneration.
- Women are more commonly affected and the age at diagnosis is usually greater than 40 years.
- Recurrence rates vary between 1-50%
- Presentation – as a slowly growing painless mass with average interval between onset of symptoms and initial workup of 1-6 years.

*Histology:* It contains both epithelial and mesenchymal tissues.

Proposed origin of these tumors is Intercalated duct- Myoepithelial cell unit.

**MR imaging-** these tumors, when small, have a fairly homogeneous low T1-weighted and a **high T2-weighted signal intensity**. However, when large, these tumors usually have a nonhomogeneous, low to intermediate T1-weighted and an intermediate to high T2-weighted signal intensity. Areas of hemorrhage appear as regions of high signal intensity on both T1-weighted and T2-weighted images. Regions of necrosis usually have low T1-weighted and high T2-weighted signal intensity.

**WARTHIN'S TUMOR:**

Synonyms- Papillary cystadenoma lymphomatosum.

-It is the second most frequent benign parotid tumor.

- Commonly located at the apex of superficial lobe of parotid gland, it is rare in submandibular gland.
- It is multicentric in 30-65% and bilateral in 30%
- It is more common in elderly men than in women.
- ORIGIN- during encapsulation of parotid gland several lymph nodes are entrapped in its substance and act as origin of this tumor. It is associated with cigarette smoking and radiation exposure.
- **On MR imaging**, when solid, these tumors appear similar to pleomorphic adenomas in that they have low T1 weighted, intermediate proton density, and high T2-weighted signal intensities. However, if the Warthin's tumor is cystic, the cyst fluid usually has a sufficiently different signal intensity from the solid tumor component that the cyst can be identified on some or all of the imaging sequences.

**Monomorphic adenoma:**

- Constitutes 2% of parotid tumor
- It is usually a solitary lesion composed of uniformly differentiated cells of one type.
- Basal cell adenoma is the most common type.

**Oncocytomas:**

Constitute 1.6% of salivary gland tumors and 1% of parotid tumors.

**Malignant Tumors:**

**Mucoepidermoid carcinoma:**

Most common malignant salivary gland tumor

Most common pediatric parotid malignancy

Origin- arises from excretory duct cells and contains epidermoid i.e. squamous cells and mucous cells.

**On MR imaging**, these low-grade tumors also have signal intensities that are indistinguishable from those of pleomorphic adenomas. By comparison, the high-grade lesions have indistinct infiltrating margins and may destroy salivary ducts. On CT they usually have few cystic areas, and they tend to be more homogeneous in appearance than the low-grade tumors. On MR imaging, these cellular tumors tend to have low to intermediate signal intensities on both T1-weighted and T2-weighted images.

**Adenoid cystic carcinoma:**

Constitutes 2-6% of all parotid gland tumors and submandibular gland tumors.

Commonest malignant submandibular tumor

Commonly affects women over 40 years of age, perineural extension is common. Most common parotid tumor associated with facial nerve weakness.

**Appearance on MRI-**

T1: hypo- to isointense

T2: slightly hyperintense, with higher grades being markedly hyperintense

T1 C+: homogeneous enhancement

**Acinic cell carcinoma:**

Second most common bilateral parotid tumor and the second most common paediatric salivary tumor. On ultrasound- similar to pleomorphic adenoma.

**Squamous Cell Carcinoma:**

- Unusual primary tumor.
- Exclusion of metastasis from skin of face or upper aerodigestive tract.
- On imaging, these are infiltrating, often partially necrotic tumors. Like other high-grade tumors, they tend to have low T2 and intermediate to high T1 weighted signal intensity on MR imaging.

**Other pathologies:**

**HAEMANGIOMA:**

Most common salivary gland neoplasm in children.

On MR imaging, the lesion can have sites of high signal intensity on both T1- weighted and T2-weighted images.

**LYMPHANGIOMA:**

On MR imaging, the dominant water content of the cysts is revealed in their signal intensities, which are low on T1-weighted images and high on T2-weighted images. The multiple, intercommunicating nature of the cysts and any fluid-fluid levels are best seen on MR imaging, especially on T2-weighted scans.

**LIPOMA:**

On MR imaging, lipomas are well-defined, capsulated lesions and have a high T1-weighted and an intermediate T2-weighted signal intensity, which may be minimally heterogeneous and which show fat suppression on fat suppression sequences.

**NEUROGENIC TUMOR:**

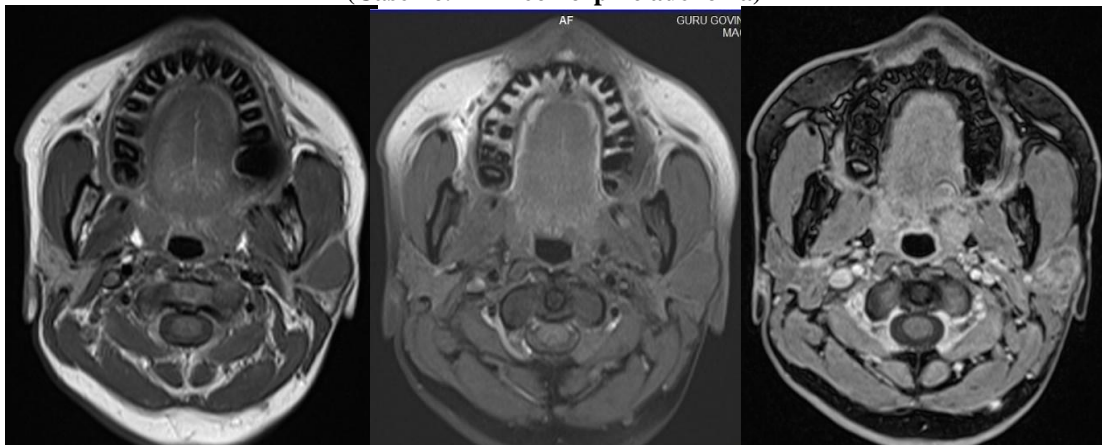
Rarely schwannoma, neurofibroma or ectopic meningioma can be seen in parotid gland. On MR imaging, these tumors in general have a low to intermediate T1-weighted and a high T2-weighted signal intensity.

**RANULA:**

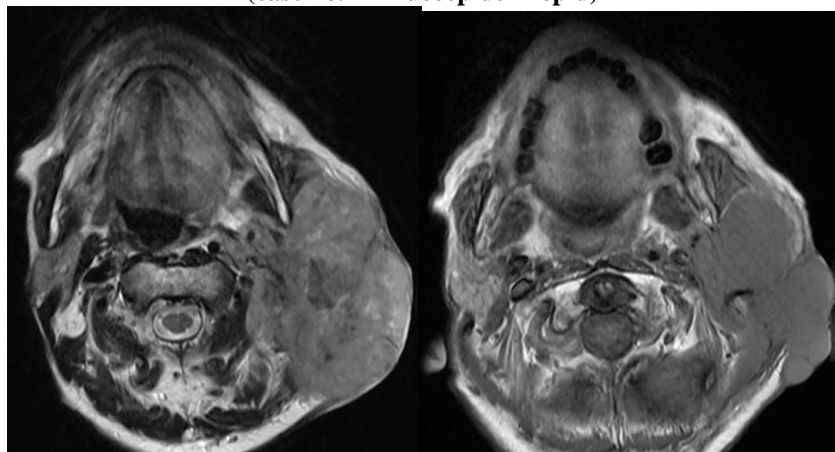
Mucous retention cyst that occurs primarily in sublingual salivary gland.

- Structural distribution of lesion demonstrates majority of lesion in parotid gland are benign accounting 28 lesions out of 39 lesions and 11 lesions are malignant. Similarly majority of submandibular lesions are benign accounting 10 lesions out of 13 lesions and 3 lesions are malignant. However, the percentage of malignancy is higher in submandibular gland as compared to parotid gland suggestive of smaller the gland higher the chances of lesion being malignant.
- Most benign and malignant salivary gland lesions can be discriminated by their appearance on MR imaging using a standard neck protocol.
- Most of the benign lesion found is pleomorphic adenoma and majority of them shows classic T2 bright signals. Similarly the other benign lesions like warthin tumor, cysts and venous malformation also shows T2 bright signals.

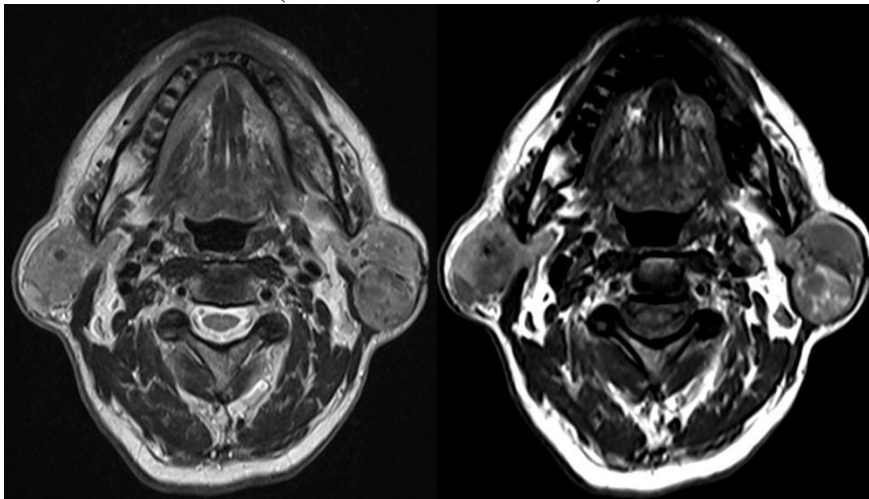
**Figures**  
**(Case no. 1 – Pleomorphic adenoma)**



**(case no. 2- Mucoepidermoid)**



(case no. 3 – Warthin tumor)



## V. Conclusion

Salivary glands pathologies are very common in clinical practice and constitute of major portion of patients with neck swelling and tenderness.

It is very important to differentiate it between malignant and benign pathologies involving salivary glands.

MRI offers a non-invasive and non-radiation hazardous method to identify various salivary gland pathologies.

In our study shows that MRI has very high sensitivity and specificity in identifying malignant lesions and we recommend using MRI in management of salivary gland pathologies.

## References

- [1]. Batsakis JG. Tumors of the Head and Neck. 2nd ed. Baltimore: Williams and Wilkins; 1979:2–75
- [2]. Freling NJ, Molenaar WM, Vermey A, et al. Malignant parotid tumors: clinical use of MR imaging and histologic correlation. *Radiology* 1992;185:691–96
- [3]. Joe VQ, Westesson P. Tumors of the parotid gland: MR imaging characteristics of various histologic types. *AJR Am J Roentgenology* 1994;163:433–38
- [4]. Swartz JD, Rothman MI, Marlowe FI, et al. MR imaging of parotid mass lesions: attempts at histopathologic differentiation. *J Comput Assist Tomogr* 1989;13:789–96
- [5]. Rosai J Ackerman S. *Surgical Pathology*. 8th ed. St. Louis: Mosby; 1986:815–55
- [6]. Tsushima Y, Matsumoto M, Endo K, et al. Characteristic bright signal of parotid pleomorphic adenomas on T2-weighted MR images with pathological correlation. *Clin Radiol* 1994;49:485–89
- [7]. Ikeda K, Katoh T, Ha-Kawa SK, et al. The usefulness of MR in establishing the diagnosis of parotid pleomorphic adenoma. *AJNR Am J Neuroradiol* 1996;17:555–59
- [8]. Mortelet B, Lemmerling M, Seynaeve P, et al. Hemangiopericytoma of the parotid gland: CT and MR features. *Eur Radiol* 2001;11:1073–75
- [9]. Motoori K, Yamamoto S, Ueda T, et al. Inter- and intratumoral variability in magnetic resonance imaging of pleomorphic adenoma: an attempt to interpret the variable magnetic resonance findings. *J Comput Assist Tomogr* 2004;28:233–46
- [10]. Som PM, Curtin HD. *Head and Neck Imaging*. 3rd ed. St. Louis: Mosby; 1996:877–912
- [11]. Lowe LH, Stokes LS, Johnson JE, et al. Swelling at the angle of the mandible: imaging of the pediatric parotid gland and periparotid region. *Radiographics* 2001;21:1211–27
- [12]. Vogl TJ, Dtesel SH, Spath M, et al. Parotid gland: plain and gadolinium-enhanced MR imaging. *Radiology* 1990;177:667–74
- [13]. Harnsberger HR. *Handbook of Head and Neck Imaging*. 2nd ed. St. Louis: Mosby; 1990:60–73
- [14]. Sigal R, Monnet O, Baere T, et al. Adenoid cystic carcinoma of the head and neck: evaluation with MR imaging and clinical-pathologic correlation in 27 patients. *Radiology* 1992;184:95–101
- [15]. Teresi LM, Lufkin RB, Wortham DG, et al. Parotid masses: MR imaging. *Radiology* 1987;163:405–09
- [16]. Schlakman BN, Yousem DM. MR of intraparotid masses. *AJNR Am J Neuroradiol* 1993;14:1173–80
- [17]. Mandelblatt SM, Braun IF, Davis PC, et al. Parotid masses: MR imaging. *Radiology* 1987;163:411–14
- [18]. Minami M, Taniao H, Oyama K, et al. Warthin's tumor of the parotid gland: MR-pathologic correlation. *AJNR Am J Neuroradiol* 1993;14:209–14
- [19]. Takashima S, Wang J, Takayama F, et al. Parotid masses: prediction of malignancy using magnetization transfer and MR imaging findings. *AJR Am J Roentgenol* 2001;176:1577–84
- [20]. Thoeny HC. Imaging of salivary gland tumors. *Cancer Imaging* 2007;7:52–62
- [21]. Okahara M, Kiyosue H, Hori Y, et al. Parotid tumors: MR imaging with pathological correlation. *Eur Radiol* 2003(13 suppl 4):L25–33

**AUTHOR PROFILE:**



*Dr. Shilpa Chudasama – Associate professor in Radiology, G.G. Hospital, M.P. Shah medical college, Jamnagar-361008*

*Dr. Divyesh Sarvaiya – 2<sup>nd</sup> year Resident Doctor in Radiology, G.G. Hospital, M.P. Shah medical college, Jamnagar-361008*

Dr Divyesh Sarvaiya, et. al. "Radiological and histopathological correlation of salivary gland pathologies." *IOSR Journal of Dental and Medical Sciences (IOSR-JDMS)*, 20(01), 2021, pp. 49-56.