

A Rare Case of Urinary Fistula: Successful conservative management by Yoga Prana Vidya (YPV) Healing

Rajkumari Khatri¹, Nanduri VS^{2*}

¹ Senior ENT & Head Neck Oncologist, YPV Trainer & Healer
Indore (M.P), India.-452007. Email:raj.sachdeva@rediffmail.com

² Consultant –Research & Publications,
Yoga Prana Vidya Ashram, Thally-635118, Tamilnadu, India

*Corresponding Author: vsnanduri@yahoo.com

Abstract

Introduction: Rectourethral fistula (RUF) is a rare and debilitating condition. Spontaneous closure is rarely effective, and appropriate management regarding the timing of repair and surgical approach remains debateable. This paper presents a case of a 14 year old mentally challenged male patient suffering over 6 months from RUF and advised surgery, but reluctant to undergo.

Material & Methods: This is case study method. Considering the patient's morbid condition, as an alternative the author who is a senior YPV healer started healing treatment using advanced YPV protocols to improve and cure his RUF condition.

Results: Within 7 days of healing, the severity of the incontinence reduced as observed by the soiling of the bed. Healing continued for 1 month, and the child recovered fully with no urinary incontinence and no recurrence noticed during subsequent yearlong follow up.

Conclusion: Yoga Prana Vidya is an effective alternative modality of conservative management of urinary fistula where other conservative measures failed and where the surgery had to be avoided due to the comorbid condition and reluctance of the child.

Key words: Urinary Fistula, Rectourethrorectal fistula, Pneumaturia, Faecaluria, Pelvic collection, Urinary infection

Date of Submission: 01-01-2021

Date of Acceptance: 13-01-2021

I. Introduction

Recto urethral fistula (RUF) is a connection between the lower urinary tract and the distal part of the rectum. RUFs are rare conditions and can be classified as congenital or acquired [1]. Congenital RUFs, usually related to imperforate anus, represent a small subset of this pathology and are managed by paediatric surgeons. Acquired RUFs resulting from surgery, radiation, trauma, or inflammation often occurs in adults and account for the majority of the condition [2]

From the pathophysiology point of view, the RUF is a communication between the lower part of the rectum and the urethra. In this context, the higher pressure in the rectum kept by the normal sphincteric muscles contraction leads to the passage of air and later faeces from the rectum to the bladder causing Pneumaturia, Faecaluria, pelvic collection, urinary infection, fever, and potentially sepsis. [3]

Urethrorectal fistula is a rare yet potentially debilitating condition, which can affect both males and females in all age groups. RUF is an uncommon complication that is mostly iatrogenic in origin (60%) [1], but can also be caused by a neoplasm, infection, inflammation, or trauma. Iatrogenic RUF is often the result of surgery or irradiation for prostate cancer, and less commonly is the result of rectal cancer.

Due to the rarity of cases and the heterogeneity of causes, Treatment of RUF is still challenging to the surgeons and devastating circumstances to patients. Surgical repair can be challenging. More than 40 different surgical approaches were described in the literature. However, no standardized management exists due to the rarity and complexity of the problem. Spontaneous closure of fistula is rare and most cases need reconstructive procedures. In some small RUF, spontaneous closure can be expected with faecal and urinary diversion. Urethrorectal fistulas may be suspected when classical symptoms, such as Faecaluria, Pneumaturia, abnormal urethral discharge, or leakage of urine from the rectum during micturition, are present [1]. The symptoms vary by type and severity of the fistula. They may include any of the following: abdominal pain, Dysuria (painful urination), foul-smelling urine (urine smells like sulphur), incontinence, sore or infected genital area, pain during intercourse, Pyelonephritis (urinary tract infection where both kidneys become infected), recurrent sepsis, urinary obstruction (inability to completely void urine), unusual

vaginal discharge, recurrent and frequent problematic urinary tract infections (recurrent cystitis), urine that looks like stool/urinary discharge during defecation, and the gas that escapes through the urethra when urinating/faecal discharge during urination.

The diagnosis is essentially clinical [4]. Typical symptoms are Faecaluria (43–65%), Pneumaturia (67–85%), and urine leakage from the rectum during voiding (40%). Faecaluria is a pathognomonic sign and is not usually present until late in the course of the disease when the fistula has become quite large. Other symptoms may be recurrent nonspecific urinary tract infection (UTI) 73%, abdominal pain (22%), and dysuria (14.6%)

For enterovesical fistula, causes include the following:

- Diverticulitis – accounts for 50 to 70 percent of cases
- Crohn’s disease – accounts for 10 percent of cases
- Other inflammatory conditions
- Cancer
- Trauma
- Foreign body
- Prolonged childbirth
- Post-surgical complication

Fistulas can cause a lot of discomforts, and if left untreated, may cause serious complications. Some fistulas can cause a bacterial infection, which may result in sepsis, dangerous condition that can lead to low blood pressure, organ damage, or even death. Fistula tracts must be treated because they will not heal on their own. There is a risk of developing cancer in the fistula tract if left untreated for a long period. Most fistulas are simple to treat. Fistulas are most often caused by injury to the organs in question, either during surgery or through trauma, such as in an automobile accident

It is very important to establish the cause of the fistula. In the present case study, the cause appears to be accidental injury or inflammation as the predominant symptom was only urinary discharge through the Rectum & the subject become symptom-free within a month without any recurrence or any other complication. Surgery is the only treatment option for fistulas, except in the rare case of a small fistula detected very early. In those cases, catheter drainage may successfully treat the fistula, but not always. The applicability and durability of conservative management of URF remain unclear. [5]

YPV Healing

Yoga Prana Vidya is an ancient integrated and holistic scientific approach. It has been observed that Yoga Prana Vidya which is a non-touch, non-drug, bio-energy healing method has been used successfully as complementary and alternative medicine to treat and heal patients having several medical conditions such as, diabetes and difficult multiple medical conditions [6, 8]; Heart block case [9] without need of surgery; treating hypothyroidism [10], Post-herpetic neuralgia [11] high Cholesterol [12]; treating Exostosis [13] without surgery; vision improvements [14]. It was also found that after a month of intensive YPV in-house residential programme the participants gained significant improvements in physical, emotional and mental well-being. [15]

Yoga Prana Vidya is not intended to replace the systems like Ayurveda, Homoeopathy, and Allopathy, etc. It works complementary to these systems to enhance the natural healing power within our bodies to heal at a faster rate with remarkable effect. YPV primarily involves the healing of the Energy Body which interpenetrates and extends beyond the Physical Body by several inches. The Energy Body is referred to as the Pranamaya Kosha in Sanskrit, Etheric Double in Theosophy, and Bio-Plasmic Body by Modern Science.

The human energy body consists of an inner aura surrounding the physical body. The inner aura is like a mould around the physical body. Surrounding the inner aura is the outer aura. Health rays connect the inner and outer auras as shown in Figure 1.



Fig1: photographic Representation of the Aura

The aura can also be captured using a GDV (Gas discharge Visualization) camera. The energy body acts as a shield protecting the physical body.

The system of YPV consists of cleansing and energizing the energy body which in turn ensures that the physical body is healthy. When disease strikes, it first strikes the energy body and, if that is weak, the disease passes on to the physical body. The Healing involves Generalized sweeping to clean the aura surrounding the Physical body & localized sweeping to clean the local organs & their corresponding chakras.

There are eleven Major Chakras (wheels) or Energy Centres in the body which keep rotating and distributing energy to various parts of the body through meridians or channels (Nadis). Each Chakram is assigned a specific function to keep certain organs & the entire system healthy by supplying energy to them, removing diseased & dirty used up energy by expelling them out.

The science of YPV Healing is based on the principle that the body has a self –Healing power, YPV healing accelerates this process by removing diseased & dirty energy and replacing it with healthy Prana. Based on the principle that the energy follows thought, the Healer heals the subject from the distance (distant healing) or direct face to face healing (Direct healing). YPV Healing can be applied to heal a wide range of physical and psychological ailments of the subject through the energy healing process.

YPV healing in Urinary tract and lower gastrointestinal tract- The lower gastrointestinal (GIT) system - involves the rectum, anal canal and colon which is controlled by navel chakra and perineum minor chakra. While the urinary tract involved was the bladder and urethra which are controlled by sex chakra. The basic chakra or Root chakra (Muladhara) is the basic chakra controlling the whole physical body. The abnormal fistulous tract between the lower GIT and urinary tract is dissected and ligated with the imagination to seal both ends.as shown in the fig 2.

II. Materials and methods

Case Presentation

A 14 year old severely mentally challenged male child with epilepsy and deafmutism in a Government boarding school of mentally challenged children at Indore, was suffering from urinary incontinence, foul-smelling urine from anal aperture for 6 months. He had been shown to the surgery department of the Government Hospital, he had been advised surgery for urinary fistula (see Figures 2 and 3).

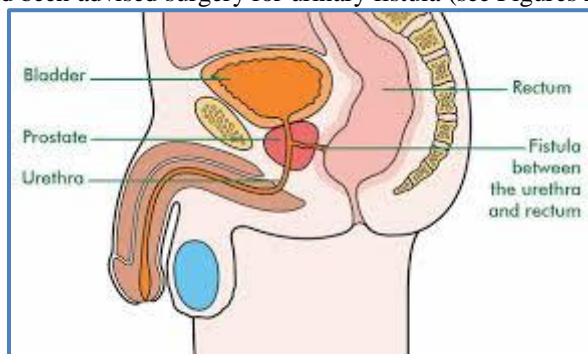


Fig 2: Diagrammatic representation of Rectourethral Fistula

(Source: www.google.com/www.macmillan.org.uk)

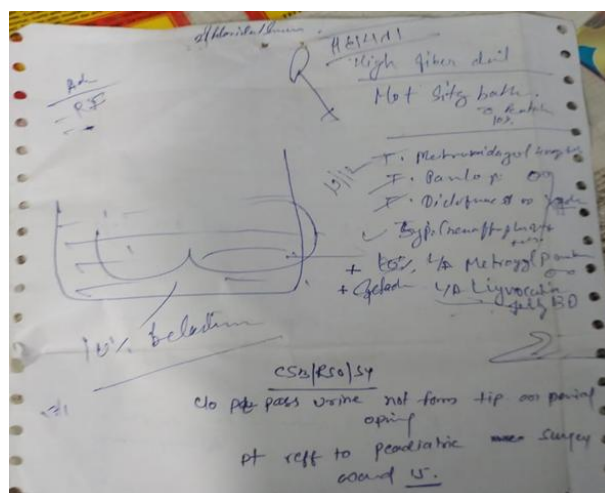


Fig 3: Hospital Investigation and Prescription for surgical reference

As he was a severely mentally challenged child with epilepsy, having no parents, the school authority was not willing to subject him to surgery, as post-op care for a prolonged period is required and will be difficult to provide as he may become violent sometimes because of lack of awareness. The School authorities consulted the author, a YPV senior healer, and it was mutually agreed that YPV healing as complementary and alternative therapy as non-invasive and safe modality shall be tried to help this patient.

YPV Protocols applied

Local cleaning of the perineum with Sitz bath, anti-inflammatory and systemic antibiotics continued for 2 weeks as the child was sleeping in that contaminated bed sometimes as he was not able to speak, has no toilet training. He had no fever though, was not allowing anyone to touch him, and becoming panicky sometimes. He might be having pain but could not be assessed by looking at his face.

The senior YPV healer provided advanced YPV healing protocol to the patient, which included Generalized Sweeping of the aura to remove the disease and dirty energy from the aura and to seal cracks and holes if any. The YPV healer carried out localized healing of the concerned chakras, i.e., sex chakra, navel chakra, perineum minor chakra, basic chakra, and organs like the rectum, anal canal, perineum, bladder and urethra. The Imaginary fistulous tract between lower GIT & urinary tract was cleansed thoroughly & then ligated & cut and the cut ends of the tract were sealed with bluish violet energy with the imagination that the fistulous tract is completely shrunken.

III. Results

Outcome for patient

The YPV healing protocol was carried out and within 7 days positive response was observed as reduced and less severe incontinence. Healing continued for 1 month and the child recovered fully with no urinary incontinence. The child was followed up for 1 year and he was asymptomatic and no recurrence of symptoms was observed. Thus in this case study, YPV healing cured the child of the urinary fistula, the morbidity of the child is reduced, surgical intervention is completely avoided even without knowing the site of the lesion. A testimonial from the school written in Hindi and its English translation are at Annexure.

IV. Discussion

A RUF condition is a rare, but distressing complication for both the patients and the surgeons. Since a RUF is challenging to treat and may seriously impact the quality of life of the patients, optimal treatment plans should be made to minimize morbidities. Most studies advocate faecal and urinary diversion as the initial treatment in the management of a RUF because diversion may provide better conditions to safely dissect the plane between the rectum and the urethra by controlling the local inflammation and contamination around the fistula. However, the spontaneous closure rate for RUF after diversion only has been reported to be 14% to 46.5%. [4].

In the present case study, the author has achieved control of inflammation & fistulous tract closure by conservative energy healing technique along with conservative antibiotic & anti-inflammatory therapy to prevent secondary infection.

Even when diverted, patients may suffer from urinary tract infections, resistant to medical therapy. Thus, most of these patients will eventually require surgical treatment. [7] However in our present case study, the subject was followed up for 1 year, but there was neither recurrence nor recurrent UTI. One limitation of our case study is, there was no assessment of the site and size of the fistula due to lack of investigations.

Fiaschetti employed a conservative treatment by positioning a Foley catheter of monthly duration, to allow the urethra to rest, in a case of Urethrorectal fistula post- HIFU for the treatment of prostate cancer. HIFU is a technique that permits one to destroy the tumor located in the prostate by “bombarding” it with ultrasound at high intensity; this is aimed at precise points of the prostate. This treatment is also advisable for treating patients who cannot be operated on due to the presence of cardiac comorbidity. During a follow-up 70 days later, the direct cystography with contrast media showed the closure of the fistulous tract. [16]

Hechenbleikner EM, et al. have shown that patients affected by RUF undergo up to 4 categories of surgical repair with an 87.5% rate of fistula closure and with more than 10% rate of permanent faecal and/or urinary diversion in post radiated cases .Permanent faecal and/or urinary diversion should be a last resort in patients with devastated, non-functional faecal and urinary systems. [2] Regardless of the cause, position, or dimension of the fistula, all RUF should undergo conservative treatment. In case of recurrence, a double diversion has to be performed as the first step, followed by the surgical repair of the fistula. [3]

V. Conclusion

Urethrorectal fistula is a rare, debilitating and distressing condition. In this case study YPV healing cured the child of the urinary fistula, the morbidity of the child is reduced, and surgical

intervention is completely avoided even without knowing the site of the lesion. Yoga Prana Vidya system of Healing, known to be effective non-drug and non-touch process in healing of various ailments, has been found to be very helpful in treatment of this condition effectively by a trained and experienced YPV healer.

Acknowledgements

Grateful acknowledgements to Yoga Prana Vidya Ashram, Sri Ramana Trust, Tamilnadu, India for permission given to use their copyright terms Yoga Prana Vidya System[®] and YPV[®].

Funding

None

Conflicts of Interest

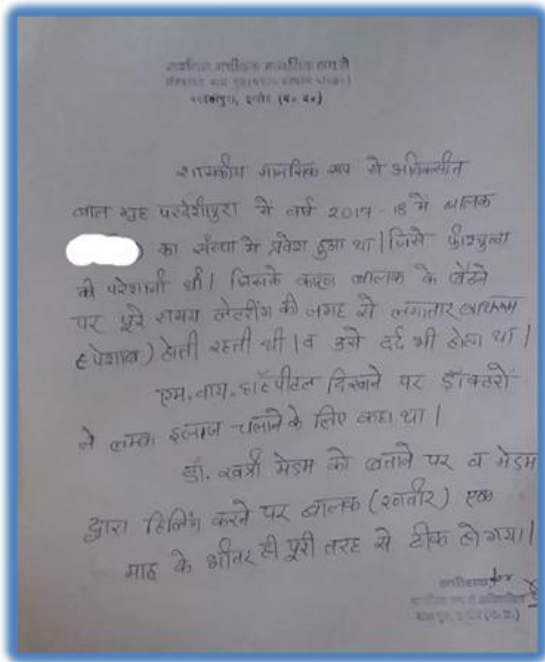
None

References:

- [1]. Constantinos Nastos, Ira Sotirova, Athanasios Papatsoris, Andreas Skolarikos, Ioannis Papaconstantinou, and Athanasios Dellis, Unusual Case of Urethrorectal Fistula in Adolescence in a Patient with a History of Congenital Anorectal Malformation. *Journal of Endourology, Case Reports*. 2016; 2(1): 24–26.
- [2]. Hechenbleikner EM, Buckley JC, Wick EC. Acquired Rectourethral fistulas in adults: a systematic review of surgical repair techniques and outcomes. *Dis Colon Rectum*. 2013 Mar; 56(3):374-83. doi: 10.1097/DCR.0b013e318274dc87. PMID: 23392154.
- [3]. Inama M, Moretto G (2017) Treatment of Recto – Urethral Fistula: State of the Art in Brief. *Urol Nephrol Open Access* .2017; 5(2): 00165. DOI: 10.15406/unoaj.2017.05.00165.
- [4]. Ji Hye Choi, Byeong Geon Jeon, Sang-Gi Choi, Eon Chul Han, Heon-Kyun Ha, Heung-Kwon Oh, Eun Kyung Choe, Sang Hui Moon, Seung-Bum Ryoo, Kyu Joo Park. Rectourethral Fistula: Systemic Review of and Experiences with Various Surgical Treatment Methods. *Ann Coloproctol* 2014; 30(1):35-41.
- [5]. Krishnan Venkatesan Evangelos Zacharakis Daniela E .AndrichAnthony R.Mundy Conservative Management of Urorectal Fistulae. <https://doi.org/10.1016/j.urology.2012.10.040>.
- [6]. Neravetla JR, Nanduri VS. A study into the successful treatment of some difficult Medical cases using Yoga Prana Vidya (YPV) Healing System as alternative medicine. *Int J Sci EngH Res*. 2019 ;(7):882–7.
- [7]. Oded Zmora, Fabio M. Potenti, Steven D. Wexner, Alon J. Pikarsky, Jonathan E. Efron, Juan J. Noguerras, Victor E. Pricolo, and Eric G. Weiss. Gracilis Muscle Transposition for Iatrogenic Rectourethral Fistula. *Annals of Surgery*; 237(4):483–487.
- [8]. Rajagopal AH, Ashwin R, Nanduri VS. Diabetes Management and Control Using Yoga Prana Vidya (YPV) Healing System. *J Biol Life Sci*. 2019; 10(2):106.
- [9]. Ramya A, Nanduri VS. Cardiac Case Study: Successful Healing Treatment of A 48-Year-Old Male with Block in Heart, using Yoga Prana Vidya (YPV) Healing System. *Saudi J Nurs Health Care*. 2019; 2:353–6.
- [10]. R Revathi, N Janani, Venkata S Nanduri. Successful healing treatment of Hypothyroidism using Integrated Yoga Prana Vidya (YPV) healing approach as complementary medicine: A case report. *Journal of Preventive Medicine and Holistic Health*. h 2020;6(1):42–48.
- [11]. Sachdeva R, Nanduri VS. Management of Post-Herpetic Neuralgia PHN) by Yoga Prana Vidya (YPV) Healing: A Case Study. *Am J Biomed Life Sci*. 2019; 7(6):174–8.
- [12]. Nanduri, V.S., Vasavada, A. 2019. Successful healing treatment of high blood cholesterol levels and asthma using Yoga Prana Vidya (YPV) system: A case study of self-healing. *Panacea Journal of Medical Sciences*, September - December, 2019; 9(3): 131 – 137
- [13]. Gupta, K & Nanduri, V.S. (2019). A case report of the Exostosis of ear of an elderly female: Successful healing with Integrated Yoga Prana Vidya (YPV) healing approach as alternative to surgical intervention. *Ann Geriatrics Educ Med Sci* 2019 6(2): 42-47.
- [14]. Nanduri, V.S., & Chaitra, N. (2019). How the participants of a Yoga Prana Vidya (YPV) Eye Camp experienced vision improvements: A Case study. *The Journal of Community Health Management*. 2019, 6(4):
- [15]. Neravetla, J & Nanduri, V.S. (2020). A study of the effects of Yoga Prana Vidya one month intensive residential programme for participants on their physical health, psychological well-being and improved immunity. *International Journal of Research and Analytical Reviews (IJRAR)*, 2020, 7(2), 18-27.
- [16]. Fiaschetti V, Manenti G, Di Poce I, et al. A Rectourethral Fistula due to Transrectal High-Intensity Focused Ultrasound Treatment: Diagnosis and Management. *Case Rep Radiol*. 2012; 2012:962090. doi:10.1155/2012/962090

Annexure

Testimonial from School



English Translation

In our Government school of mentally challenged children, a boy named [redacted] was admitted in year 2016-17. He was suffering from fistula, in which his urine used to come from anal aperture. He was also suffering from pain.

When shown to doctors at M.Y.H., they have advised that his treatment will remain continued for long time.

When we show the child to Dr khatri, healing done by Dr khatri made the child completely healthy within 1 month.

Nanduri VS, et. al. "A Rare Case of Urinary Fistula: Successful conservative management by Yoga Prana Vidya (YPV) Healing." *IOSR Journal of Dental and Medical Sciences (IOSR-JDMS)*, 20(01), 2021, pp. 13-18.