

## **A Retrospective Clinico-pathological Study of Salivary Gland Tumors**

Dr.Rutul Panchal, Dr.Meeta Bathla, Dr.Hiren Doshi, Dr.Rinkal Diwan,  
Dr.Pinky Shah

---

Date of Submission: 02-01-2021

Date of Acceptance: 15-01-2021

---

### **I. Introduction**

Salivary gland tumors represent an uncommon heterogeneous group of neoplasms with complex clinico-pathological behaviour. These are diverse group of neoplasms, and this constitutes about 0.5 % of all cancers and 5% of head-and-neck malignancy[1]. Around 64%–80% are located in the parotid gland, 7%–11% in the submandibular glands, and the remainder being distributed between the sublingual (1%) and the minor salivary glands (9%–23%) throughout the oral cavity [2,3].

A neoplasm in the parotid gland is statistically more likely to be benign than one arising in a minor salivary gland. Pleomorphic adenoma is the most common benign salivary gland tumor, and mucoepidermoid carcinoma (MEC) is the most common malignant salivary gland tumor; the diagnosis of the salivary gland tumor includes clinical examination, supported by complementary techniques such as magnetic resonance imaging, computed tomography (CT) alone or combined with sialography, and fine-needle aspiration biopsy. The combination of some of these techniques is able to offer a tentative diagnosis that must be confirmed by histopathological study. Efficacy of treatment of malignant salivary gland tumors is dependent upon stage, location, presence of peri-neural invasion, treatment modality, histological type, and presence of regional invasion[1].

Although the aetiology of salivary gland tumors is unknown, literature reports certain risk factors implicated in causation of these tumors. Among the viruses, Epstein-Barr virus, polyoma virus, cytomegalovirus, human immune deficiency virus and human papilloma virus types 16,18 are likely to cause salivary gland neoplasms [4].

Considering the diverse anatomical sites and histological subtypes, it is easy to understand why otolaryngologists, head and neck surgeons, oncologists and pathologists accumulate only restricted exposure to specific types of SGTs[5].

**Keywords:** (PA) Pleomorphic adenoma, (SGT) Salivary gland tumor, Warthin's tumor.

### **AIMS & OBJECTIVES**

The aim of this study was to carry out a survey of different tumors of major and minor salivary glands, at the department of Otorhinolaryngology, AMC MET MEDICAL COLLEGE & L.G.Hospital , Maninagar, Ahmedabad, during the period of January 2018–November 2020.

The Objectives of this study were:

- (1) To correlate gender and age in different tumor types.
- (2) To correlate the anatomical location of different salivary gland tumors.

### **II. Materials & Methods**

This is a 3-year retrospective study of salivary gland tumors operated at the Department of torhinolaryngology, AMC MET MEDICAL COLLEGE & L.G.Hospital , Maninagar, Ahmedabad, during the period of January 2018–November 2020.

Data was collected from the archives maintained in the Department of Otorhinolaryngology & Department of Histopathology, and details of the patient include age, sex, site of the tumor and type of the tumor were obtained and confirmed. Only salivary gland tumors both benign and malignant were included in the study. Data was collected pertaining to the tumor type, location, age, and gender of the patients and statistical analysis was done. The tumors were classified according to the WHO's histological typing of SGTs. All patients with histopathologically proven lesion treated with surgery (with or without adjuvant therapy) were included. Details regarding patient demography, clinical details, surgeries performed, and 30-day morbidity were retrieved

from prospectively maintained database of Head & Neck oncology register.. The collected data was analysed statistically and results obtained compared with existing studies in the literature.

Out of 29 patients presented to our OPD, 13 were males and 16 were females. All patients were presented with chief complain of a lump or swelling on or near jaw or in neck or mouth. Other associated symptoms were local site numbness of face, muscle weakness on one side of face, persistent pain, difficulty swallowing, and difficulty in mouth opening. All patients were subjected to FNAC( Except patients with intraoral lesions) & Direct Laryngoscopic Examination besides routine blood investigations. All patients had preoperative imaging including USG Neck/local part followed by CECT Neck/ CT PNS

### **Parotid Gland Surgery**

Types of parotid surgery include [6].

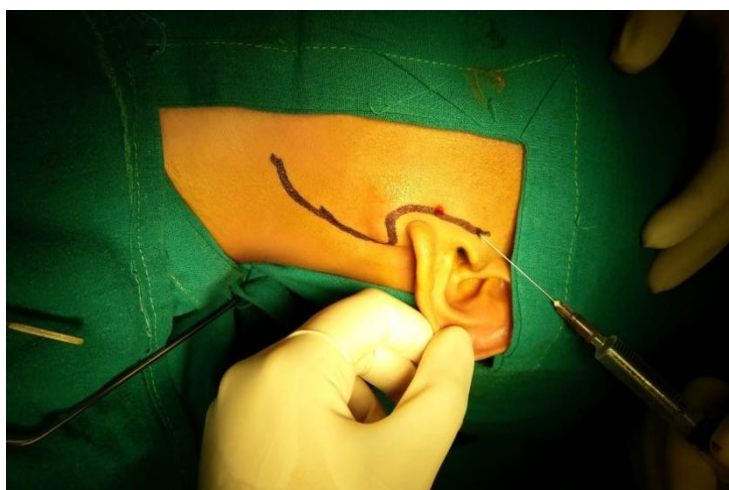
- **Extra-capsular dissection:** the tumor is resected with the help of a facial nerve monitor used for benign lesions that are not pleomorphic adenoma.
- **Partial/superficial parotidectomy:** the tumor is resected with a cuff of parotid tissue, used for benign lesions and lymph node metastasis into the superficial lobe.
- **Total parotidectomy:** the entire gland is removed, used for aggressive malignant tumors, deep lobe tumors, sentinel lymph node excision when located in the deep lobe, vascular malformations, or in large tumors where the distinction between superficial and deep lobes is unclear.
- **Radical parotidectomy:** the entire gland and the facial nerve is removed, mostly used when preoperative facial paralysis is well established, or circumferential involvement of the nerve by malignant tumor is encountered. Simultaneous nerve grafting or other facial reanimation procedures can be employed in this situation.

### **Partial/Superficial Parotidectomy Surgical Steps[7]**

#### **Anaesthesia**

- General anaesthesia given
- Short-acting muscle relaxation used for intubation only, so that facial nerve may be stimulated and/or monitored
- 2% lox with 1:100000 adrenaline infiltrated along the skin incision, to reduce thermal injury to skin from electrocautery to skin vessels

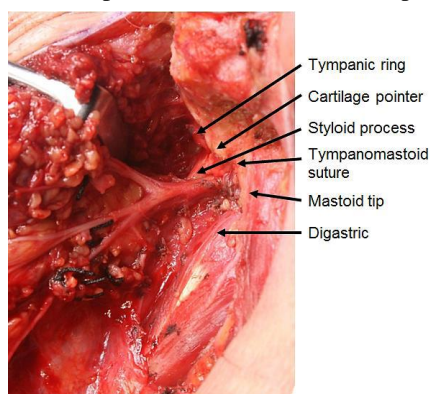
- **Lazy-S incision:** This was placed in pre-auricular and cervical skin creases.



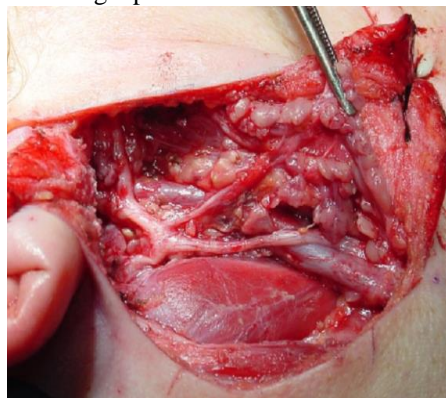
*Fig .1 “Lazy-S” incision (Modified Blair’s incision)*

- Superficial cervicofacial flap was raised to the anterior border of parotid mass or of the parotid gland in the plane between the SMAS and the parotid fascia.
- The anterior border of sternocleidomastoid muscle skeletonised.
- External jugular vein divided.
- The greater auricular nerve divided as it crosses sternocleidomastoid muscle, posterior to the external jugular vein. The posterior branch of the nerve was preserved to retain sensation of the skin of the auricle.

- The posterior belly of the digastric muscle identified & skeletonised.
- The cartilage of the external auditory canal was skeletonised up to the tragal pointer quickly with electrocautery dissection as the facial nerve exits the stylomastoid foramen 1cm deep to the tragal pointer
- The mastoid tip was skeletonised to the depth of the tragal pointer



*Fig.2 Intraoperative surgical land-marks for the facial nerve trunk[7].*



*Fig.3 Facial nerve running superficial to retro mandibular vein[7].*

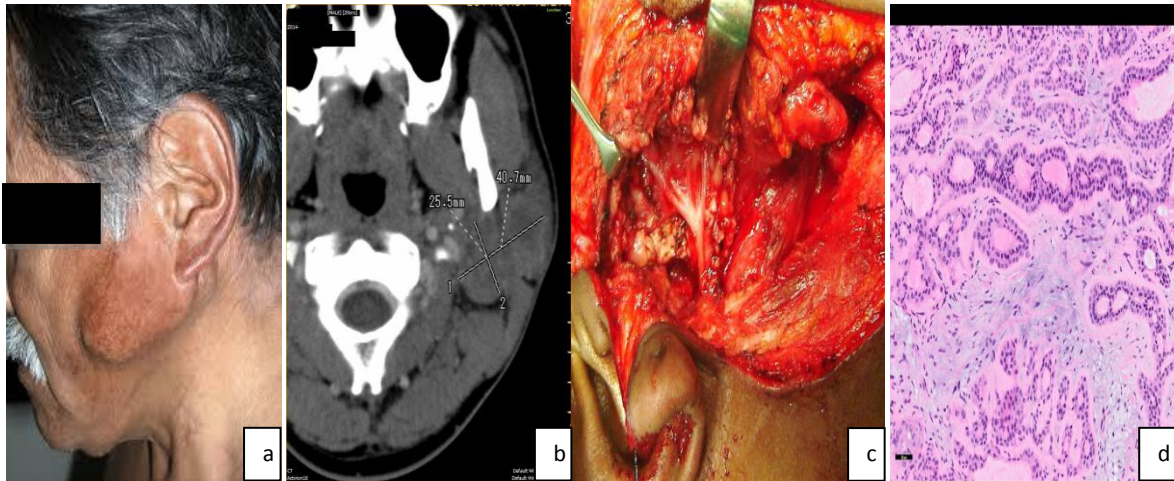
All the following landmarks for the facial nerve identified

- Tragal pointer (nerve 1 cm deep and inferior)
- Tympanic ring
- Anterior aspect of mastoid bone
- Tympanomastoid suture line (leads directly to stylomastoid foramen)
- Posterior belly of digastric muscle (Facial nerve at same depth, just above muscle)
- Palpate the styloid process (facial nerve in angle between styloid and digastric, and crosses styloid more anteriorly)

- The facial nerve trunk was located by blunt dissection with a fine haemostat
- The remainder of the nerve dissection was done, the parotid tissue overlying the facial nerve and its branches were divided.
- Hemostasis was achieved with bipolar diathermy and fine silk ties.
- Dissection was done along the trunk to the pes anserinus then back towards the stylomastoid foramen to exclude early branching from the trunk.
- The parotid fascia and parotid tissue was divided superiorly and inferiorly to release the parotid posteriorly and to permit anterior mobilisation of the gland/ tumour.
- The superficial lobe was stripped off the branches of facial nerve.
- The retromandibular vein identified as it was crossing the medial to the facial nerve.
- For dissecting to the anterior border of the gland, the parotid duct identified & transacted
- The tumour with a cuff of the superficial parotid lobe was removed & sent for HPE.

#### **Wound closure**

- A valsalva manoeuvre was done to identify venous bleeding
- Sealed suction drain: Until drainage <50ml/24 hrs
- Skin closure: Subcutaneous and subcuticular absorbable sutures



**Fig.4 LEFT SIDE PAROTID SWELLING**

a] Pre-Op Image,

b] CECT neck axial cut: Well defined lobulated peripherally enhancing lesion in superficial lobe of Lt parotid gland s/o: pleomorphic adenoma,

c] Intra-op Image,

d] Histology: Biphasic population of epithelial & mesenchymal cells, ducts with luminal & myoepithelial cells s/o pleomorphic adenoma

#### **Submandibular Gland Excision Surgical Steps[8]**

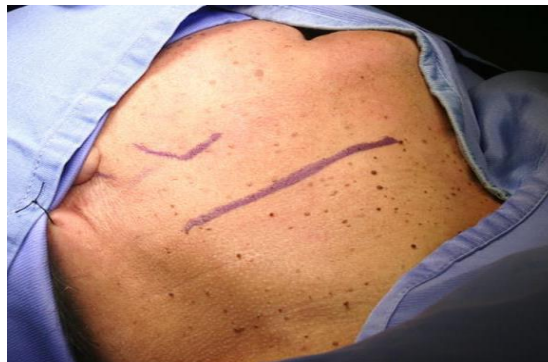##### **Anaesthesia**

- General anaesthesia given.
- Muscle paralysis was avoided as it was useful to monitor movement of the lower lip, if the marginal mandibular nerve was surgically irritated

##### **Positioning and draping**

- The patient was placed in a supine position with neck extended and the head rotated to the opposite side. The skin of the anterior neck and lower face was sterilised. Draping was done in such a way that the lower lip, lower margin of the mandible, and upper neck were exposed.

- Incision of skin and platysma



**Fig.5** A horizontal incision is placed in a skin crease at least 3cms below the mandible or at the level of the hyoid bone, extending 10 cm anteriorly from the anterior border of the sternocleidomastoid muscle

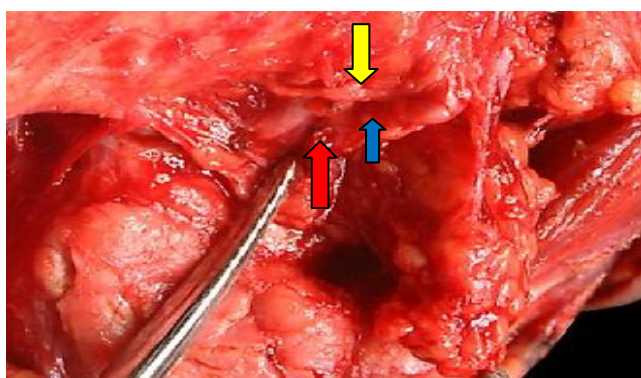
- A horizontal incision was placed in a skin crease at least 3cms below the mandible or at the level of the hyoid bone, extending anteriorly from the anterior border of the sternocleidomastoid muscle

- Skin, subcutaneous tissue and platysma cut to expose the capsule of the SMG, the facial vein and posteriorly, the external jugular vein

- The facial vein was ligated and divided where it crosses the SMG.

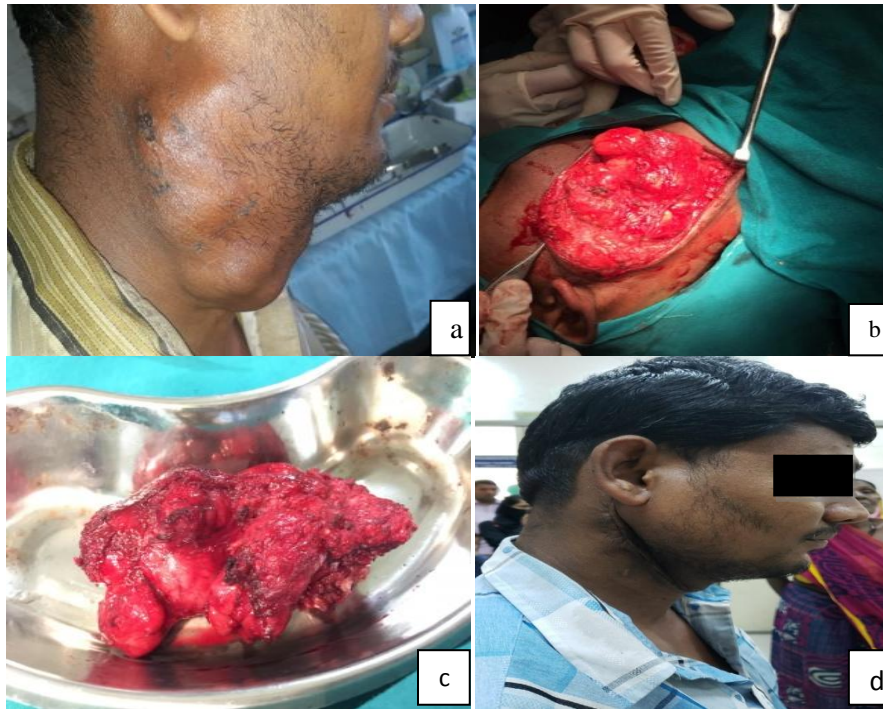

- The fascial capsule of the SMG was incised with cautery or a knife parallel to and just above the hyoid bone to expose the SMG.
- Once the superior margin of the SMG reached, then dissection was done bluntly with a haemostat in the fatty tissue above the gland to identify the facial artery and vein keeping immediately above the SMG to avoid injury to the marginal mandibular nerve.
- The facial artery and vein divided & ligated close to SMG to avoid injury to marginal mandibular nerve.



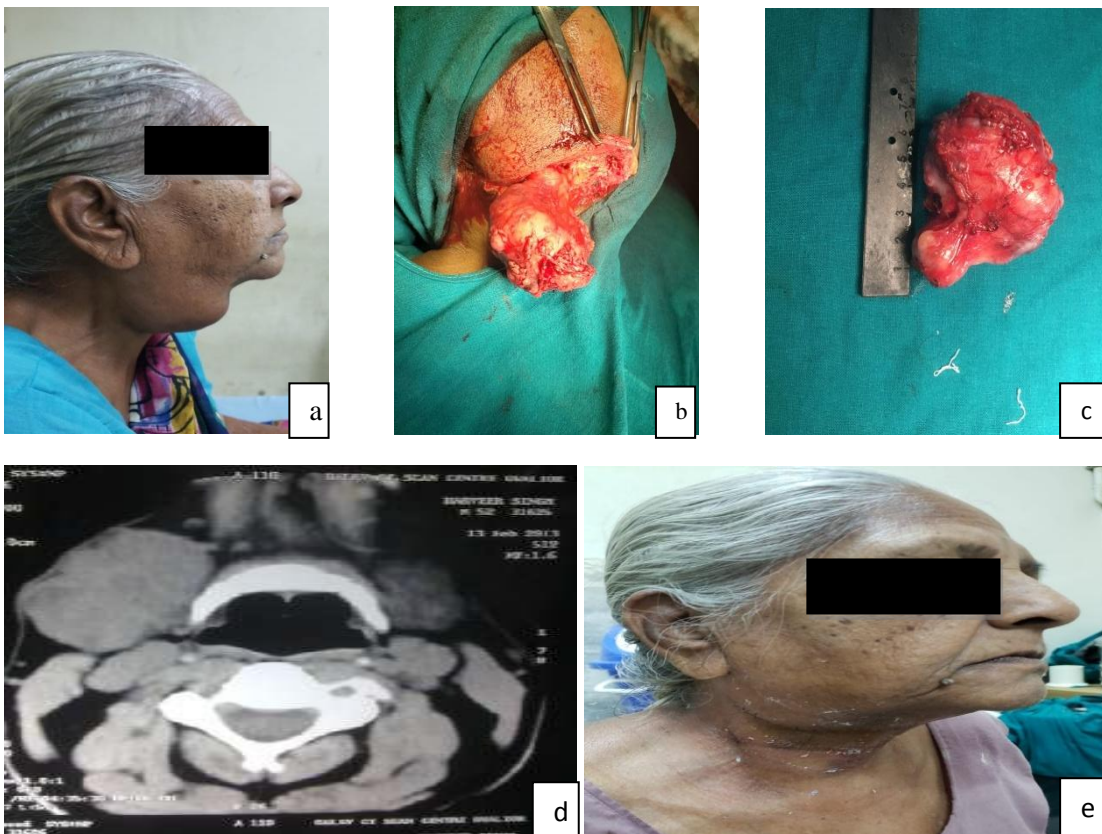**Fig.6** The marginal mandibular nerve (yellow arrow) is seen crossing the facial artery (red arrow) and the ligated vein (blue arrow)[8]

- The anterior margin of the SMG was freed from the anterior belly of digastric & proceeded in a posterior direction, elevating the SMG from the lateral surface of the mylohyoid muscle. The mylohyoid nerve and vessels divided to gain free access to the posterior part of the mylohyoid muscle.
- The posterior free margin of the mylohyoid skeletonised with diathermy with the knowledge that the XIIIn, ranine veins and lingual nerve were all immediately deep to the muscle and were exposed and vulnerable to injury immediately posterior to the muscle.
- By retracting the mylohyoid anteriorly and by using careful finger dissection, the lingual nerve, submandibular ganglion, and submandibular duct came into view
- An index finger was passed in the well-defined interfascial plane that exists between the SMG and submandibular ganglion laterally, and the fascia covering the XIIIn and ranine veins medially.
- The XIIth nerve identified, the submandibular duct and the branch of the lingual nerve to the submandibular ganglion were safely clamped, divided and ligated.
- The SMG reflected inferiorly, and the facial artery was identified, ligated and divided where it exits from behind the posterior belly of digastrics
- The SMG was then finally freed from the tendon and posterior belly of the digastric and removed.
- The wound was irrigated and closed in layers with vicryl to platysma and subcuticular suture to skin. A suction drain was placed.



**Fig 7: RIGHT SUBMANDIBULAR MULTINODULAR SWELLING**

- A] Pre-op Image
- B] Intra-op Image
- C] Biopsy specimen
- D] Post-op Image



**Fig.8 RIGHT SUBMANDIBULAR SWELLING**

- a] Pre-op Image
- b] Intra-op Image

c] Post-op Specimen

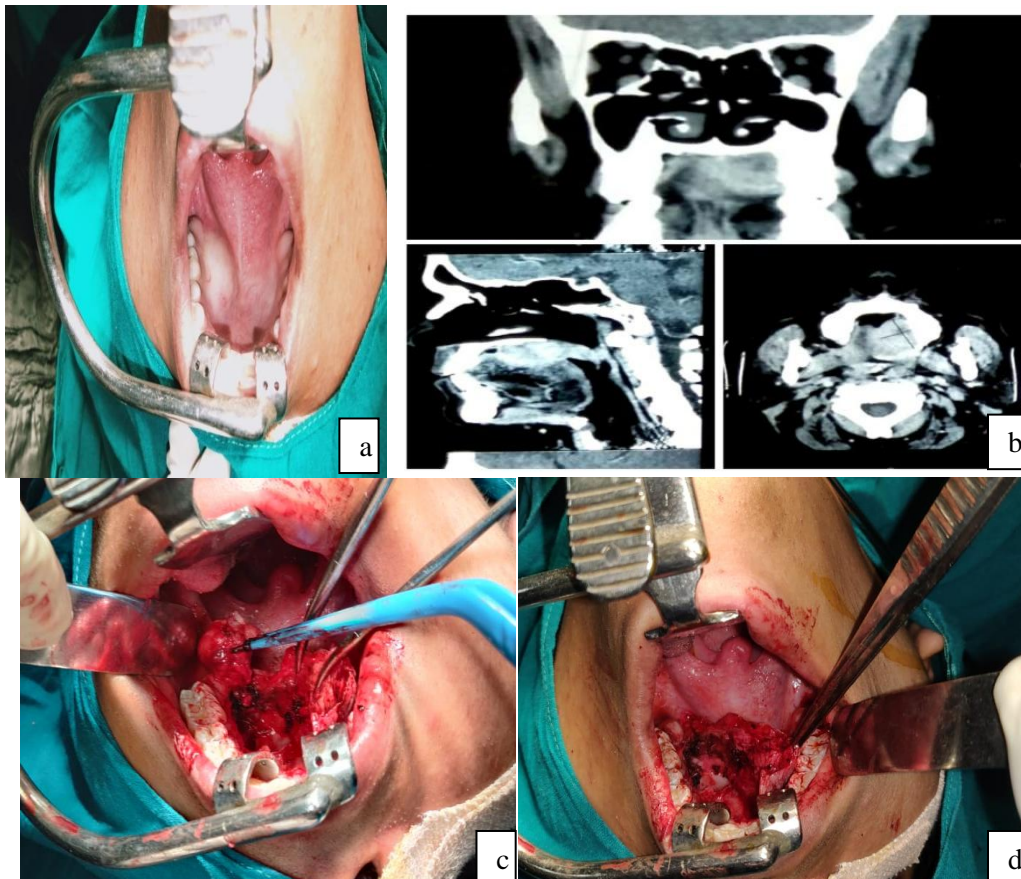
d] CECT neck axial cut showing Well defined homogenously enhancing soft tissue density lesion in right submandibular gland p/o submandibular gland adenoma

e] Post-op Image

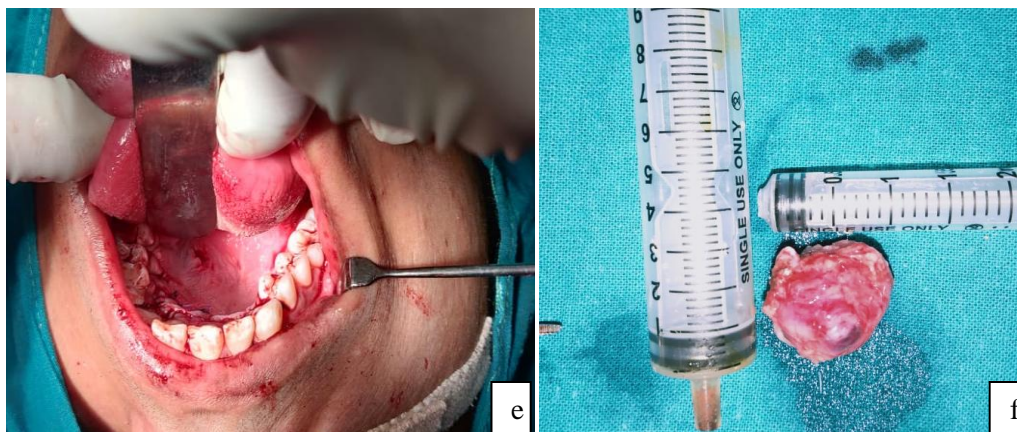
### Minor Salivary Gland Tumor Excision Surgical Steps

#### Hard Palate Lesion Excision

- General anesthesia given, Painting & drapping done
- Boyle davis mouth gag with tongue depressor applied
- Left sided hard palate mass lesion identified
- 2% lox with 1:100000 adrenaline infiltrated over mass lesion
- Crevicular incision placed from right upper lateral incisor till left upper 2<sup>nd</sup> molar
- Periodontal flap elevated, mass lesion was dissected from the overlying flap & from the periosteum of bone with cuff of surrounding normal tissue.
- Saline with Betadine wash given
- Periodontal flap repositioned & sutured with vicryl 3.0
- Button hole is created for drainage of serous fluid or blood
- Boyle davis mouth gag with tongue depressor released







**Fig.9 LEFT SIDED HARD PALATE MASS LESION**

- a] Pre-op Image
- b] CT PNS showing 17x18x11 mm well defined moderately Heterogenously enhancing soft tissue density lesion noted in hard palate of maxilla on left side with scalloping of inner sublingual alveolar margin on left side p/o adenoma of minor salivary gland.
- c ,d] Intra op removal of tumor from its base by crevicular incision
- e] Creation of button hole for drainage.
- f] Post-op Specimen

#### Upper lip Lesion

- General anesthesia given, painting & drapping done
- 2% lox with 1:100000 adrenaline infiltrated
- Eliptical incision placed
- Blunt dissection done, hemostasis achieved with monopolar cautery
- Mass lesion removed in toto with adequate surgical margins.
- Base was cauterised
- Upper lip defect was sutured with vicryl 4.0

### III. Results

During the period of January 2018–November 2020, a total number of 29 specimens were of Salivary gland tumors. The age range of patients was 10-80 years, with youngest patient presented at the age of 12 years and oldest patient presented at the age of 80 years.

Out of 29 patients presented to our OPD, 13 patients (44.82%) were males & 16 (55.17%) were females with male: female ratio was about 0.8:1. The peak incidence for the salivary gland tumors were in the 3rd decade of life. In our study, 27 cases were benign & 2 cases were malignant salivary gland tumors. (TABLE 3 &4)

Parotid gland was the most common major salivary gland involved (n =20, 68.96%) including 2 cases of malignant salivary gland (parotid) tumors, followed by submandibular gland (n=6, 23.07.%) all of them were benign tumors . There were no sublingual gland tumors in this series. There were three cases of minor salivary gland tumors, two over hard palate & one case over upper lip. (TABLE 1)

In our study, we had 22 cases of Pleomorphic Adenoma constituting (75.86 %) of benign salivary gland tumors, 3 cases (10.34%) of warthin's tumor , 2 cases(6.89%) of monomorphic basal cell adenoma , 1 case of mucoepidermoid carcinoma &1 case of acinic cell carcinoma. (TABLE 1)

The most common presenting complaint was a localised swelling. Only a small percentage (n=5, 17.24 %) of patients also presented with pain along with swelling. History of tobacco chewing (n=9, 31.03%), smoking (n=7, 24.13%) and alcohol consumption (n=4, 13.79%) was noted.

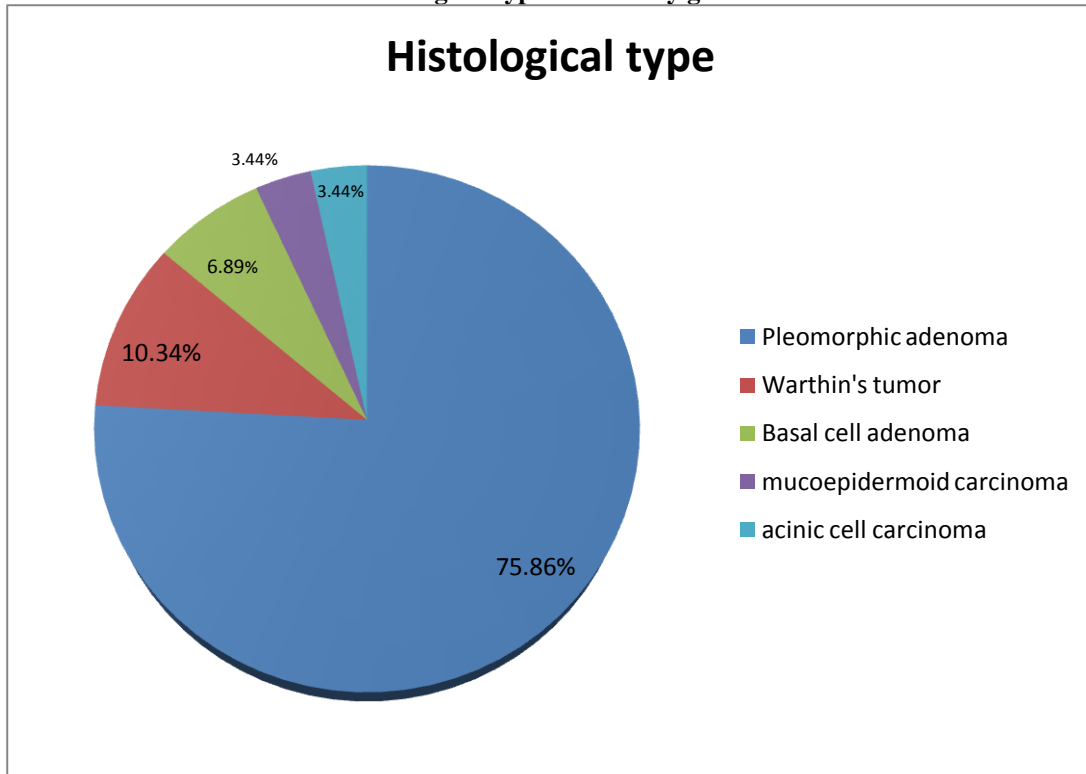
Out of 29 patients, Fine needle aspiration cytology (FNAC) was done in 26 patients (93.10%), of which definitive diagnosis of benign tumor possible in 19 patients(74.07) & malignant tumor in 2 patients(7.40%). The remaining 5 patients(18.51%) had non-specific changes on FNAC. Three patients did not have any FNAC done on them.

All the patients in the series underwent surgery. The most common surgery performed was superficial parotidectomy (n =18, 65.51%) followed by submandibular gland excision (n=6, 20.68%), total parotidectomy with facial nerve preservation in 2 cases, 2 cases of hard palate mass lesion excision & upper lip mass excision in one case. (TABLE 2)



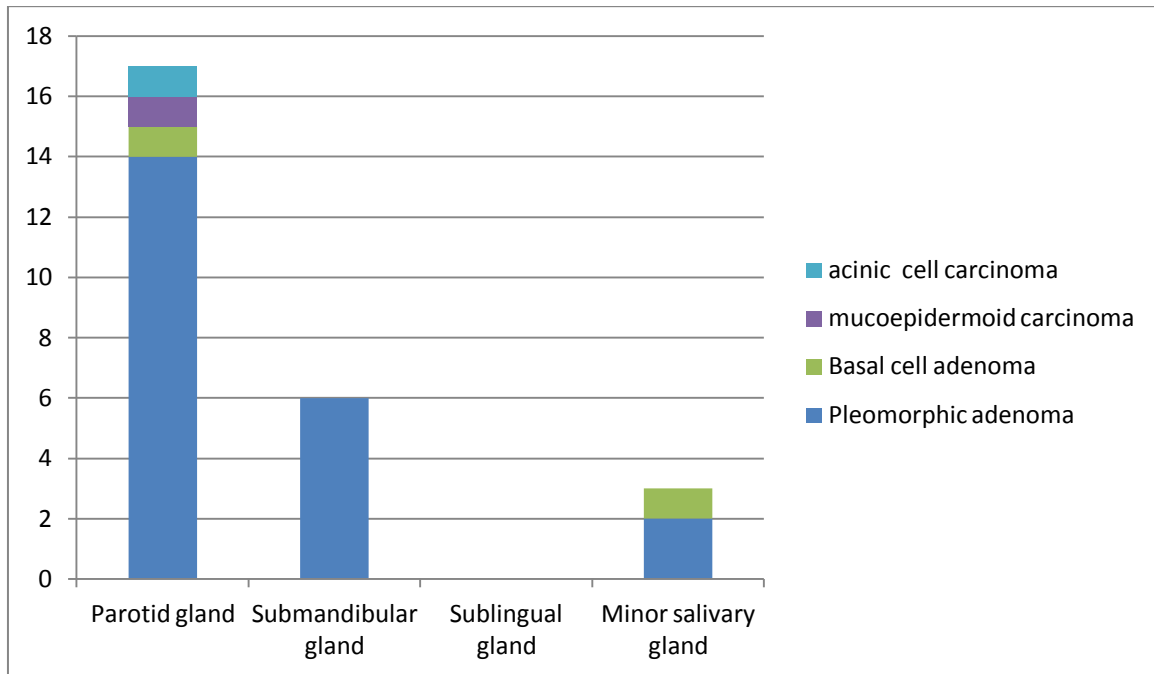
Following surgery, the most common morbidity noted was facial nerve dysfunction (n =11, 37.93%) at first post operative day which includes 8 cases in superficial parotidectomy, 2 cases in total parotidectomy & one case in submandibular gland excision , which were reduced to(n=3, 10.34%) at 1 month after surgery, which included two cases of malignant parotid tumors, which may be related to stretch injury or as a result of surgical interference with the vasa nervorum. The most common dysfunction was paresis in a single nerve branch,in particular, the marginal mandibular branch. Surgical-site infection (n=2) , hematoma (n=2) , skin flap necrosis (n=3) , salivary fistula (n=2) were the other common post-operative complications seen. (TABLE 5)

**Distribution of histological types of salivary gland tumors**



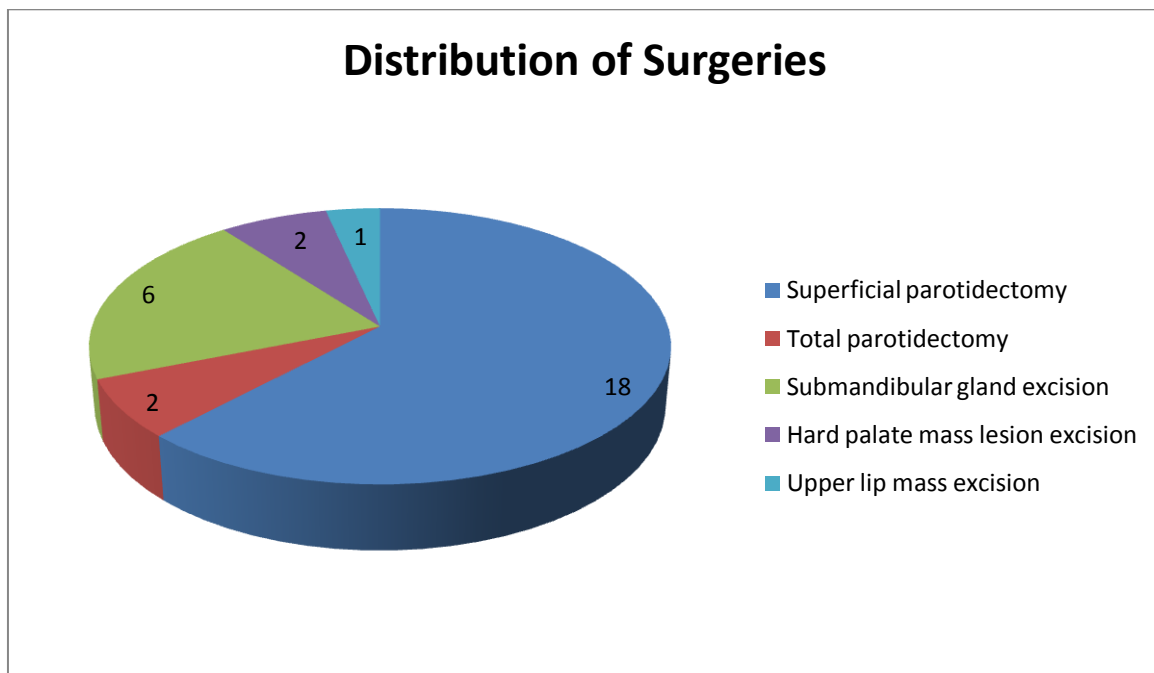
**Table 1 : Distribution of different histological types of salivary gland tumors according to anatomical location**

Histology Type	Anatomical Location				Total
	Parotid gland	Submandibular gland	Sublingual gland	Minor salivary glands	
Pleomorphic adenoma	14	6	0	2	22
Warthin's tumor	3	0	0	0	3
Monomorphic basal cell adenoma	1	0	0	1	2
Mucoepidermoid carcinoma	1	0	0	0	1
Acinic cell carcinoma	1	0	0	0	1
Total	20	6	0	3	29



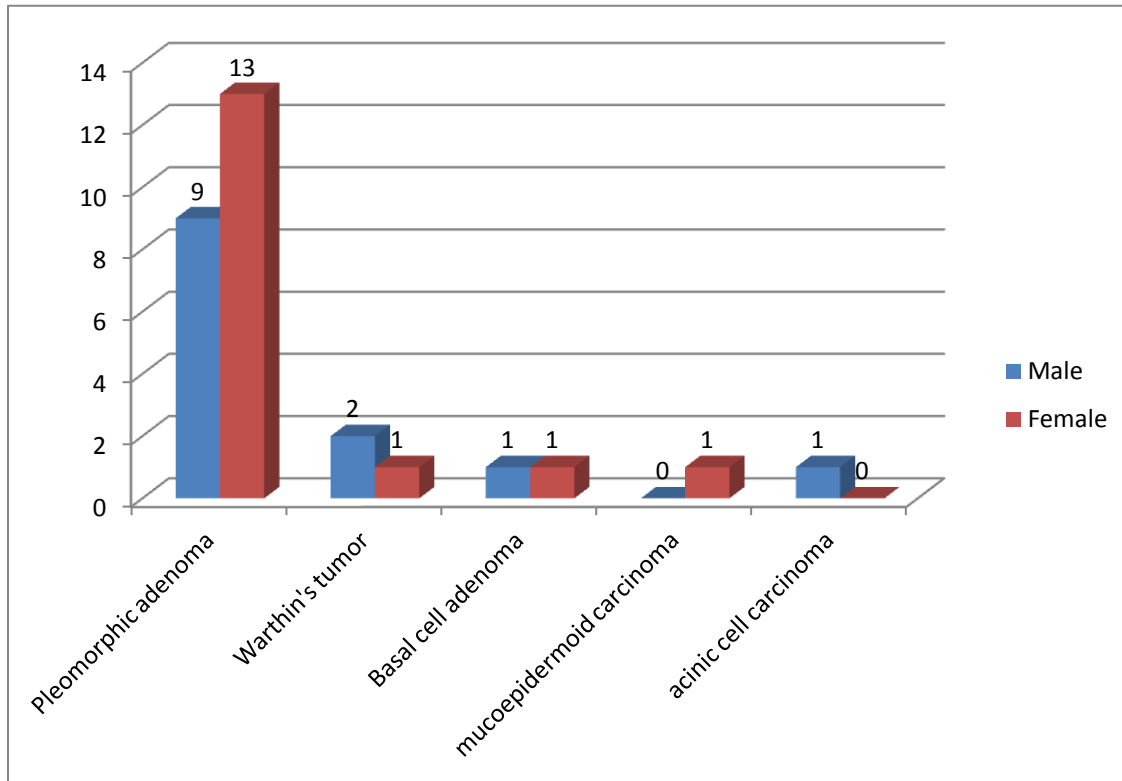
**Table 2 : Distribution of different salivary gland tumor surgeries**

Type of Surgery	Number of Surgery
Superficial parotidectomy	18
Total parotidectomy	2
Submandibular gland excision	6
Hard palate mass lesion excision	2
Upper lip mass excision	1
<b>TOTAL</b>	<b>29</b>



**Table 3: Number, percentage & sex distribution of different histological types of salivary gland tumors.**

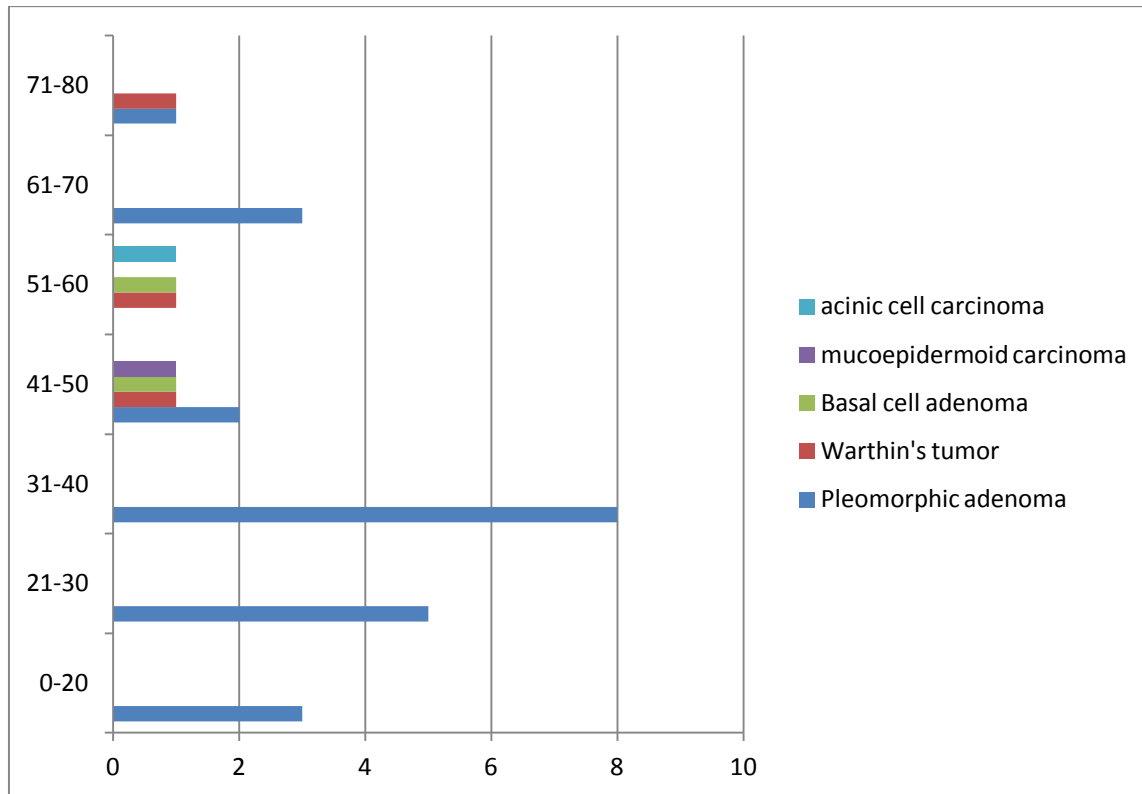
Histology Type	Male	Female	Patient	Percentage
Pleomorphic adenoma	9	13	22	75.86
Warthin's tumor	2	1	3	10.34
Monomorphic basal cell adenoma	1	1	2	6.89
Mucoepidermoid carcinoma	0	1	1	3.44
Acinic cell carcinoma	1	0	1	3.44
Total	13	16	29	100



**TABLE 4: Age distribution of different histological types of salivary gland tumors**

Histology Type	Age Groups							Total
	10-20	21-30	31-40	41-50	51-60	61-70	71-80	
Pleomorphic adenoma	3	5	8	2	0	3	1	22
Warthin's tumor	0	0	0	1	1	0	1	3
Monomorphic basal cell adenoma	0	0	0	1	1	0	0	2
Mucoepidermoid carcinoma	0	0	0	1	0	0	0	1
Acinic cell carcinoma	0	0	0	0	1	0	0	1
Total	3	5	8	5	3	3	2	29





**TABLE 5: Distribution complications following parotid gland tumor excision/surgery.**

Surgery	Post operative complications							
	Facial nerve paresis	Haemorrhage or Hematoma	Infection	Skin flap necrosis	Parotid fistula	Hypertrophic scar or keloid	Seroma	Frey's syndrome
Superficial parotidectomy	8	1	2	2	1	0	0	0
Total parotidectomy	2	0	0	1	1	0	0	0
Submandibular gland excision	1 (Marginal mandibular branch)	1	0	0	-	0	0	-
Hard palate mass lesion excision	-	0	0	0	-	-	-	-
Upper lip mass excision	-	0	0	-	-	-	-	-

#### IV. Discussion

The annual incidence of salivary gland tumors (SGT) is less than 1/100000 population and they represent less than 5 % of head and neck tumors [9,10]. In our study of 29 salivary gland tumors were included.

In our study there were 13 males and 16 females with male: female =0.8:1 which goes well with other studies like Zacharie sando et al(2016) & Vuhahula et al(2004), which showed male:female ratio 0.7:1 & 1:1.3 respectively [10,11].

Pleomorphic adenoma (PA) a benign tumour with variable cyto-morphological and architectural manifestations, is the most common SGT. We had 22 cases of PA constituting 75.86 % of benign salivary gland tumors. This is in accordance with the studies conducted by Zacharie sando et al(2016) & Vuhahula et al(2004) where PA constituted 60.36% & 74.8% of all SGTs respectively[10,11].

Warthin's tumour is the second most common SGT, accounting for approximately 5-15% of all tumors according to Subhashraj et al(2008) [12], similar findings were seen in our study in which warthin's tumor constituted 10.34 % of all cases.

Among the malignanat salivary gland tumors, there was one case of mucoepidermoid carcinoma & one case of acinic cell carcinoma seen in our study, while in study conducted by Zacharie sando et al(2016) adenoid cystic carcinoma(31%), mucoepidermpoid carcinoma (19%) and adenocarcinoma were the most common malignanat tumors{10} also according to Vuhahula et al(2004) adenoid cystic carcinoma was the most

encountered malignant tumor (29%) followed by mucoepidermoid carcinoma (20.3%) & acinic cell carcinoma (13.1%) [11]. No significant conclusion can be made in our study because of small sample size & different geographic distribution of cases in our study.

In our study, Parotid gland was predominantly affected gland involving 20 cases (68.96%) followed by Submandibular gland- 6 cases (20.68%), Minor salivary gland- 3 cases (10.34%), & Sublingual gland- 0 cases (0.0%). While in study by Vuhahula et al (2004) PG, SMG & MSG tumors were seen in 34%, 33.2% & 32.8% respectively [11] & in study by Subhashraj et al (2008), where PG, SMG & MSG tumors were seen in 61%, 17% & 22% respectively [12]. The incidence of Parotid gland & submandibular gland involvement were seen in agreement with Subhashraj study, but there are discrepancies observed in involvement of minor salivary glands with other studies. The reason might be small sample size.

The common complications encountered in the postoperative period following surgery for the major salivary glands are facial nerve palsy, hypoesthesia of greater auricular nerve, haemorrhage/hematoma, infection, skin flap necrosis, parotid fistula, chyle leak, and seroma. In literature, incidence of temporary facial nerve paresis ranges between 30% and 65% and that of permanent facial nerve paresis from 3%–6%. Temporary facial nerve palsy usually recovers within 6–18 months [13]. The incidence of facial nerve paresis in our series was (n=11, 37.93%) at first post-op day which includes 8 cases in superficial parotidectomy, 2 cases in total parotidectomy & one case in submandibular gland excision, which were reduced to (n=3, 10.34%) at 1 month after surgery, out of which 2 cases in superficial parotidectomy & 1 case in total parotidectomy were observed. So, in our study there was 72% reduction in facial paresis within 1 month, comparable to study by Marchese Ragona et al (2005) in which there was 90% reduction [14]. Marginal mandibular branch of facial nerve was at highest risk.

In our study, there were 2 cases of hematoma noted, 1 after superficial parotidectomy & 1 after submandibular gland excision. Two cases of surgical site infection & three cases of skin flap necrosis were seen after parotid surgery. Surgical site infections were treated with appropriate antibiotics.

There were two cases of salivary fistula (6.89%), one after superficial parotidectomy & one after total parotidectomy, which were treated conservatively. Salivary fistula rate following parotidectomy described in study by Marchese Ragona et al (2005), was between 4% and 14% [14].

## V. Conclusion

Our study was a single institutional experience where analysis of 29 SGTs was carried out. The findings of age, sex, site, type distribution, and pathologic features encountered in the study were mostly in agreement with other reviewed studies & literature. Although few discrepancies were observed because of small sample size in our study, the observations helped in better understanding of the disease & its management. The postoperative morbidities and outcomes for major salivary gland neoplasms in our series were acceptable and comparable to the results available in the literature. More prospective multi-centric studies need to be carried out to understand the influencing factors for salivary gland tumors.

## References

- [1]. Speight PM, Barrett A. Salivary gland tumours. *Oral Dis.* 2002 Sep;8(5):229-40.
- [2]. Kumaran JV, Daniel MJ, Krishnan M, Selvam S. Salivary gland tumors: An institutional experience. *SRM J Res Dent Sci* 2019;10:12-6.
- [3]. Lewis JE, McKinney BC, Weiland LH, Ferreiro JA, Olsen KD. Salivary duct carcinoma. Clinicopathologic and immunohistochemical review of 26 cases. *Cancer* 1996;77:223-30.
- [4]. Saldanha C., Yaranal P., Upadhyaya K. A clinicopathological study of salivary gland tumors. *Trop J Path Micro* 2018;4(7):532-538.
- [5]. Jude UO, Olu-Eddo AN. Salivary gland tumors, a twenty-year retrospective study. *Afr J Med Health Sci* 2014;13:24-9.
- [6]. El Sayed Ahmad Y, Winters R. Parotidectomy. [Updated 2020 Nov 30]. In: StatPearls [Internet]. Treasure Island (FL): StatPearls Publishing; 2020 Jan-. Available from: <https://www.ncbi.nlm.nih.gov/books/NBK557651/>
- [7]. Parotidectomy :The Open Access Atlas of Otolaryngology, Head & Neck Operative Surgery by Johan Fagan/ [www.entdev.uct.ac.za](http://www.entdev.uct.ac.za)
- [8]. Submandibular Salivary Gland Excision :The Open Access Atlas of Otolaryngology, Head & Neck Operative Surgery by Johan Fagan/ [www.entdev.uct.ac.za](http://www.entdev.uct.ac.za)
- [9]. Johns M, Goldsmith M. Incidence, diagnosis and classification of salivary gland tumours-Part. *Oncology (Huntingt)*. 1989;3(2):47-56.
- [10]. Sando Z, Fokouo JV, Mebada AO, Djomou F, NDjolo A, Oyono JLE. Epidemiological and histopathological patterns of salivary gland tumors in Cameroon. *Pan African Medical Journal.* 2016; 23:66 .
- [11]. Vuhahula E. Salivary gland tumors in Uganda: clinical pathological study. *African health sciences.* 2004 Apr;4(1):15-23.
- [12]. Subhashraj K. Salivary gland tumors: a single institution experience in India. *Br J Oral and Maxillofac Surg* 2008; 46, 635-8
- [13]. Thiagarajan S, Fathehi K, Nair D, Deshmukh A, Pantvaidya G, Chaukar DA, et al. Surgical morbidities and outcomes of major salivary gland neoplasms treated at a tertiary cancer center. *Indian J Cancer* 2018;55:33-6.
- [14]. Marchese-Ragona R, De Filippis C, Marioni G, Staffieri A. Treatment of complications of parotid gland surgery. *Acta Otorhinolaryngol Ital.* 2005 Jun;25(3):174-8.