

Role of Mri Brain In Early Diagnosis Of Rare Entity Of Postpartum Osmotic Extrapontine Myelinolysis Due To Hypernatremic Encephalopathy And Assessment Of Its Reversibility

Dr. Barakath Nisha Abdul Ajis¹

¹(Department of Radiodiagnosis, Tirumelveli Govt. Medical College Affiliated to The Tamil Nadu Dr.M.G.R. Medical University, Chennai)

Abstract:

Background: Postpartum hypernatremic osmotic demyelination is one of the recently proposed condition which is being frequently diagnosed nowadays. It is a rare and potentially lethal, but treatable and reversible clinico-neuro-radiological entity. Morbidity and mortality are recorded high in this condition that warrants prompt and early diagnosis and timely management. The aim of our study is to evaluate the diagnostic utility of MRI in postpartum hypernatremic osmotic extrapontine myelinolysis and to assess whether it is reversible or not.

Materials and Methods: 87 patients of postnatal encephalopathy were studied over a period of 2 years from 2018 to 2020. MRI brain was taken for all patients using standardized institutional sequences. The images were read independently by two senior neuro-radiologists and the diagnosis was arrived by consensus.

Results: Out of 87 patients, 11 patients were diagnosed as hypernatremic osmotic demyelination syndrome. All these patients showed bilateral symmetrical diffusion restriction involving corona radiata, basal ganglia, thalamus, posterior limb of internal capsule, middle cerebellar peduncle, crus cerebri, hippocampal isthmus, fornix, cerebellar white matter and corpus callosum in various combinations with 8 of them showing T2/FLAIR hyperintensities in corresponding areas. 5 of them showed wine glass sign, i.e. bilateral symmetrical T2/FLAIR hyperintensity and restricted diffusion in the path of corticospinal tract, typical for this entity. 7 out of these 11 patients were referred as PRES / CVT/ CVA and MRI helped them to diagnose hypernatremic demyelination syndrome. They were started with treatment accordingly and optimal correction of hypernatremia was started early. 9 patients [including those 7 diagnosed radiologically], had completely recovered from the disease and follow up MRI were normal. 2 patients who were diagnosed and treated late had residual focal neurological deficit. They had rhabdomyolysis with elevated serum creatine phosphokinase level, 1 of them had azotemia too. Follow up MRI showed residual T2 hyperintensity.

Conclusion: We suggest MRI brain at the earliest for all patients of postnatal encephalopathy, as the prime modality of investigation, for the precise diagnosis. Diffusion weighted imaging is very much sensitive in early diagnosis aiding for the timely and effective management. And also early management and optimal correction of hypernatremia helps in complete reversal of this condition.

Key Word: Postpartum hypernatremic encephalopathy syndrome; Hypernatremia; Extrapontine myelinolysis; Postnatal osmotic extrapontine myelinolysis; Rhabdomyolysis; Hypernatremic encephalopathy; Wine glass sign.

Date of Submission: 12-10-2021

Date of Acceptance: 27-10-2021

I. Introduction

Postpartum is a period that demands greater focus and utmost attention since there occurs a multitude and diverse complications. Some of them are unique to the pregnancy/postpartum period and some of them are aggravated directly or indirectly by pregnancy/peurperium while some others are unrelated to them. Postpartal neurological complications are fairly common and most of them are attributed to migraine, cerebral venous sinus thrombosis, intracerebral hemorrhage, eclampsia and posterior reversible encephalopathy syndrome¹. Few of the these neurological symptoms are because of electrolyte disturbances which occurs due to postpartum hemorrhage, reduced water intake, infection, endocrine disturbances like thyroiditis². Hyponatremia is the most common and well known electrolyte disturbance and its rapid correction leads to osmotic demyelination syndrome which can be central pontine or extrapontine³. However, hypernatremia also contributes its part in causing neurological insult and osmotic demyelination^{4,5}, but with a little different imaging picture that mainly

involves extrapontine structures^{6,7,8}. Hypernatremic encephalopathy in postpartum period is not uncommon and is increasingly diagnosed for the past two decades^{2,9,10,11,12}.

In the current study, we explore the diagnostic utility of MRI brain in the early detection of postpartum hypernatremic myelinolysis, which would refine the treatment process and propose the reversibility of this condition after early treatment.

II. Material And Methods

This study was conducted in our institute from 2018 to 2020. Approval was obtained from the ethical committee. Postpartum patients with mild to severe neurological symptoms who were referred to MRI brain were enrolled for our study. We included 87 patients over the period of two years. Exclusion criteria included non-pregnant women, postnatal mothers more than 3 months of delivery, pregnant women before delivery and male patients. Informed consent was obtained from caregivers of all patients.

MRI Brain was done using Seimens Magnetom Amira 1.5Tesla Machine [Germany] with Standardized institutional protocol including T1W Sagittal, T2W Axial, FLAIR axial and coronal, Diffusion weighted image with ADC mapping, susceptibility weighted imaging, MRA /MRV and post contrast study [if needed].

Study Design: Prospective observational study

Study Location: The study was done in Department of Radiodiagnosis, Tirunelveli Govt. Medical College, Tirunelveli, Tamil Nadu.

Study Duration: July 2018 to July 2020.

Sample size: 87 patients.

Inclusion criteria:

1. Postpartum patients with mild to severe neurological symptoms who were referred to MRI brain were enrolled for our study.

Exclusion criteria:

1. Non-pregnant women,
2. Postnatal mothers more than 3 months of delivery
3. Pregnant women before delivery.
4. Male patients.
5. Pregnant women with history of previous neurological disorders.

III. Analysis

The images were reviewed independently by two senior neuroradiologists with careful scrutinisation and detailed comprehensive history. The signs and symptoms of the patients included altered level of consciousness ranging from irritability and drowsiness to deep coma, seizures, severe headache, fever, tachycardia, quadriparesis with brisk deep tendon reflexes.

T2 axial, FLAIR axial and coronal images were analysed for hyperintensities and their sites, areas, laterality and symmetry were studied. Analysis was also done if there was any cortical atrophy, cortical swelling, white matter edema, corpus callosal swelling and intensity changes, hydrocephalus, loss of flow void in venous sinuses and SOL. Optic nerve thickening and signs of papilloedema were also studied. T1 sagittal images were analysed for altered signal intensity, hemorrhage and other changes. Anterior pituitary gland and bright spot of posterior pituitary were studied in mid sagittal plane for their size and intensity changes to rule out Sheehan's syndrome and other pituitary disorders. Hyperintensity of sinuses were also looked to rule out thrombosis. Special attention was given to diffusion weighted imaging and corresponding ADC map, MRA and MRV. Interpretation of restricted diffusion with corresponding low ADC values were done and their site, size, symmetry and correlation with corresponding areas in T1, T2 and FLAIR were noted down. MRA was looked for any focal or diffuse loss of signal, cut off of arteries, thinning, dilatation and aneurysm. MRV was evaluated for loss of signal and presence of collaterals. The two neuroradiologists discussed the findings and final diagnosis was arrived by consensus.

IV. Results

Based on presentation and imaging findings of 87 postnatal mothers, final diagnoses were arrived as follows. 32 patients showed cerebral venous sinus thrombosis in various sites, most commonly in superior sagittal sinus, then in transverse sinus and sigmoid sinus. 17 patients showed T2/ FLAIR hyperintensities in the parieto occipital regions with or without diffusion restriction and were diagnosed as posterior reversible encephalopathy syndrome. 1 patient showed T2/ FLAIR hyperintensity in the parieto occipital and frontal regions and was diagnosed as atypical posterior reversible encephalopathy syndrome. MRA of 7 patients showed multifocal narrowing in anterior and posterior circulation with or without infarcts and were diagnosed as reversible cerebral vasoconstriction syndrome. 2 patients showed bilateral symmetrical T2 / FLAIR gyal

hyperintensities in temporal lobes and hippocampus with corresponding diffusion restriction and they were diagnosed as herpes encephalitis. 17 patients showed no significant abnormality in the brain and were diagnosed with other causes like migraine, chronic epilepsy and eclampsia based on history and other investigations.

11 patients showed bilateral symmetrical diffusion restriction involving corona radiata, basal ganglia, thalamus, posterior limb of internal capsule, middle cerebellar peduncle, crus cerebri, hippocampal isthmus, fornix, cerebellar white matter and corpus callosum in various combinations with 8 of them showing T2/FLAIR hyperintensities in corresponding areas (Fig 1 to fig 5). They were diagnosed as hypernatremic extrapontine osmotic demyelination syndrome. 9 out of 11 patients had swelling and T2/ FLAIR hyperintensity with diffusion restriction in corpus callosum also, particularly splenium. 5 patients showed wine glass sign, i.e. bilateral symmetrical T2/ FLAIR hyperintensity and restricted diffusion in the path of corticospinal tract (Fig 6 & 7), which is typical for this entity.

Only 4 out of these 11 patients were referred as hypernatremic demyelination syndrome, other 7 patients were referred with different diagnosis of postpartum encephalopathy - 3 patients were referred as PRES, 2 patients as CVT and 2 patients as CVA. MRI helped them to diagnose hypernatremic osmotic demyelination syndrome and then samples were taken for serum electrolytes which showed elevated sodium levels ranging between 165 to 210 mEq/l. They were started with treatment accordingly and optimal correction of hypernatremia was started early.

All patients were followed up clinically and by imaging, some patients after 1 week, some after 10-14 days and some after 1 month. 9 among 11 patients [including those 7 diagnosed radiologically], had completely recovered from the disease and follow up MRI were normal. 2 patients who were diagnosed and treated late, had residual focal neurological deficit and follow up MRI showed residual T2 hyperintensity. Both of them entered the stage of rhabdomyolysis, with elevated serum creatine phosphokinase level [3567 & 5112 U] and 1 of them suffered from azotemia. These 2 patients were again followed up after 2 months which also showed residual lesions (Fig 8).

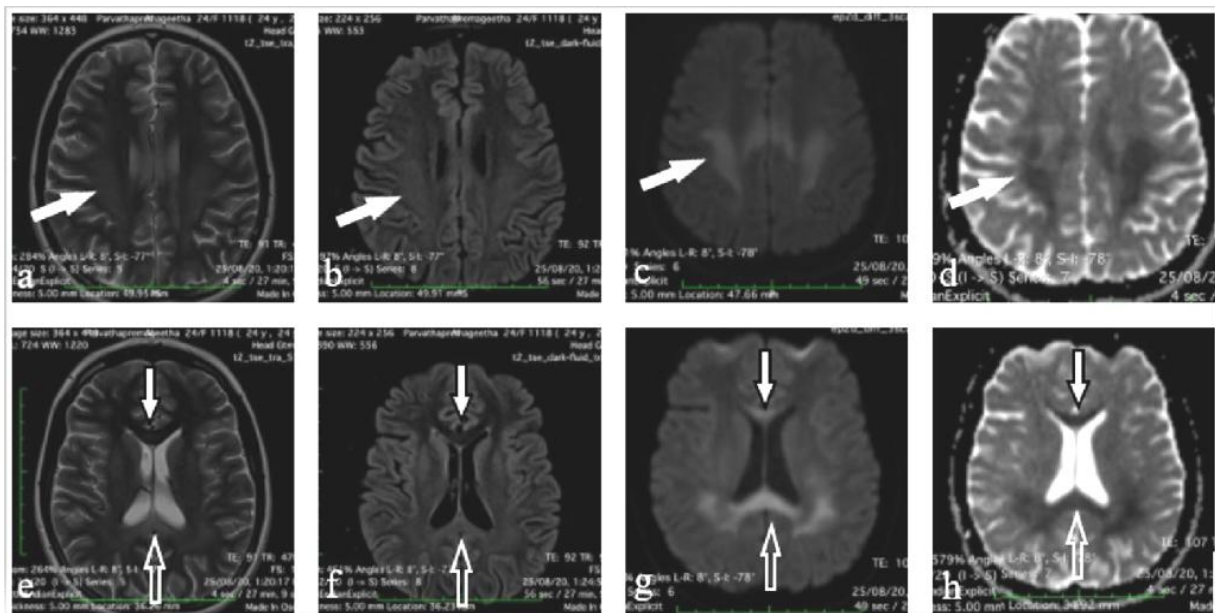


Figure 1: MRI axial sections of a patient showing axial T2W image (a, e), FLAIR (b, f), DWI (c, g) and corresponding ADC mapping (d, h) reveals T2 /FLAIR hyperintensity in bilateral para-sagittal parietal regions (solid arrows) and corpus callosum - genu (small arrows) and splenium (open arrows) which showed diffusion restriction appearing hyperintense on diffusion images and hypointense on ADC.

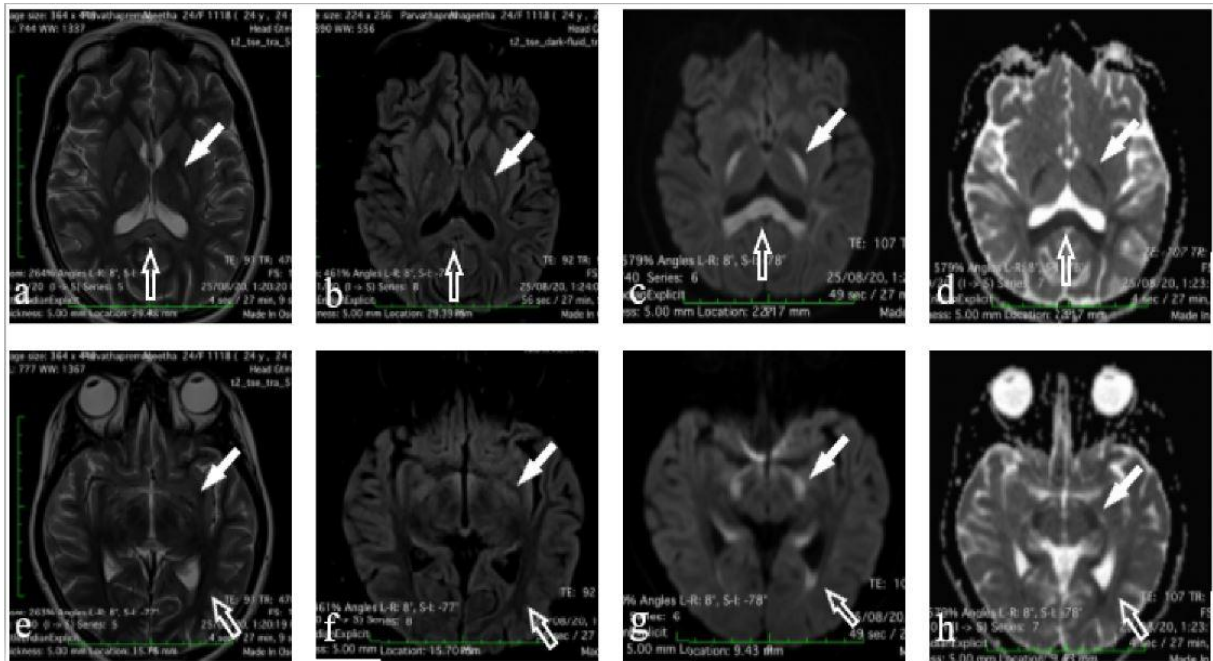


Figure 2: MRI axial sections of the same patient showing T2W image (a, e), FLAIR (b, f), DWI (c, g) and corresponding ADC mapping (d, h) reveals symmetrical T2 /FLAIR hyperintensity in bilateral posterior limb of internal capsule (solid arrows in a-d), hippocampus (solid arrows in e-h), periventricular white matter of occipital horns (open arrows in e-h) and hyperintensity in splenium of corpus callosum (open arrows in a-d) which showed diffusion restriction.

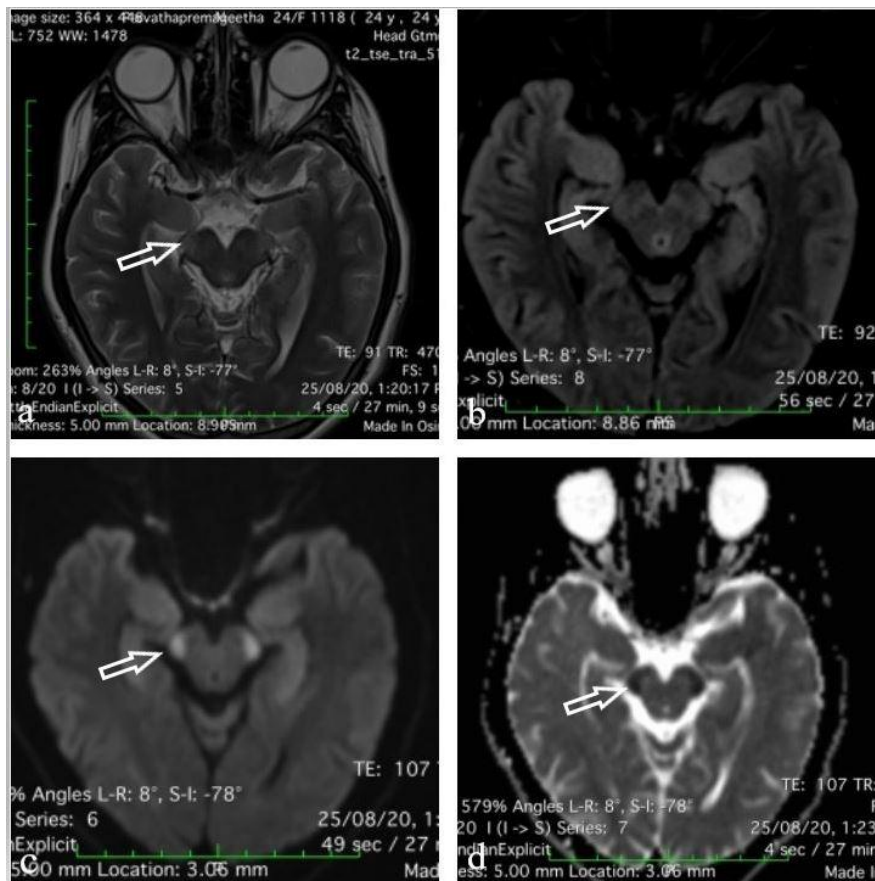


Figure 3: MRI axial sections of the same patient showing T2W image (a), FLAIR (b), DWI (c) and corresponding ADC mapping (d) reveals symmetrical T2 /FLAIR hyperintensity with diffusion restriction (open arrows) in bilateral cerebral peduncle of midbrain.

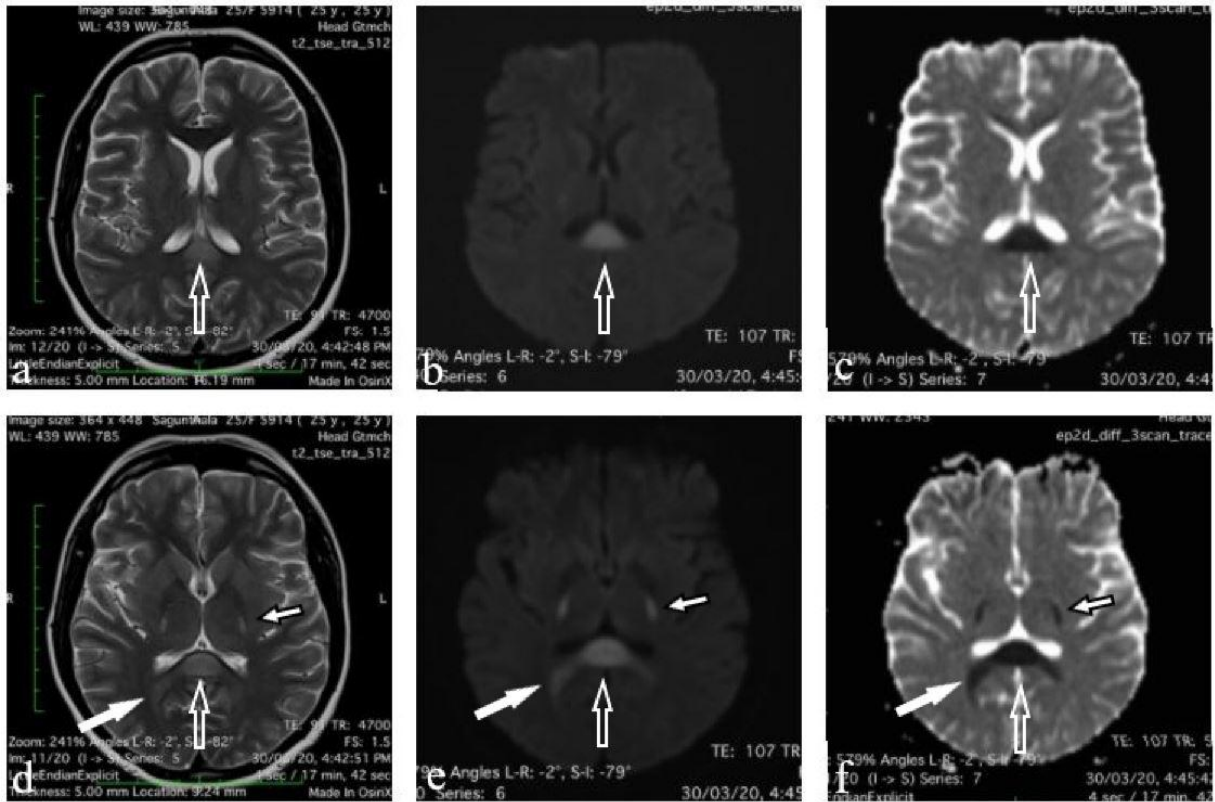


Figure 4: Magnetic resonance imaging of another patient showing axial sections of T2-weighted (a, d), DWI (b, e) and corresponding ADC mapping (c, f) which reveals T2 hyperintensity in splenium of corpus callosum (open arrow) extending into forceps major (solid arrow) and bilateral posterior limb of internal capsule (small solid arrow) and showed restricted diffusion appearing bright on diffusion images and hypointense on ADC.

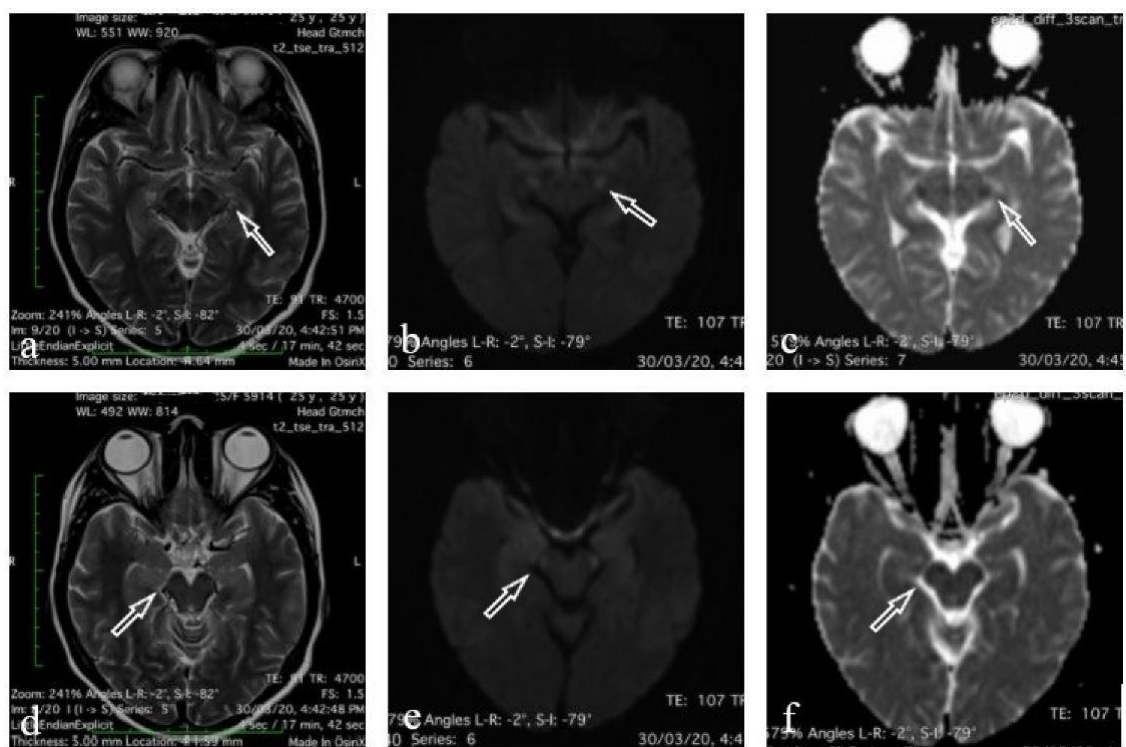


Figure 5: MRI axial sections of the same patient showing T2W image (a,d), DWI (b, e) and corresponding ADC mapping (c,f) reveals T2 hyperintensity with diffusion restriction (arrows) in bilateral cerebral peduncle of midbrain.

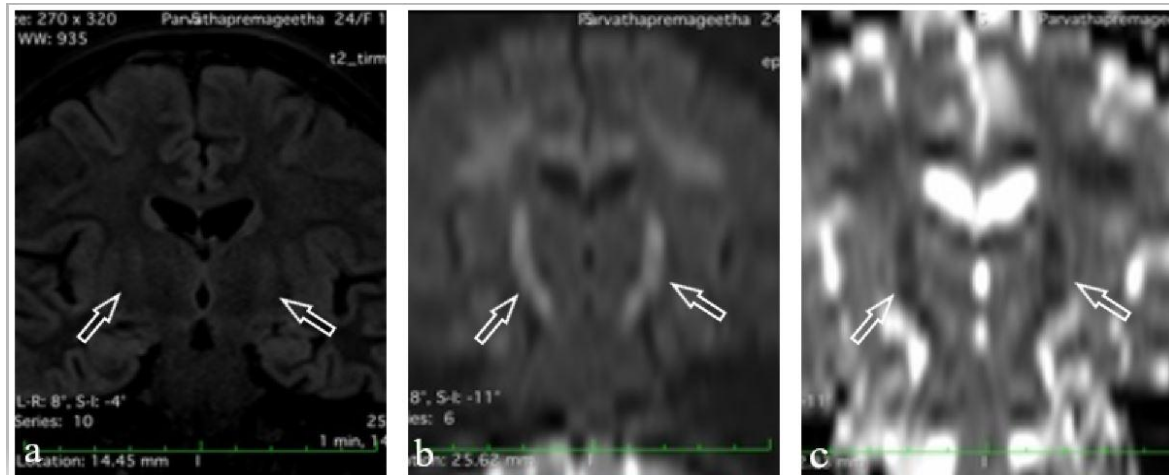


Figure 6: MRI coronal image of FLAIR (a), coronal reformatted images of DWI (b) and corresponding ADC mapping (c) reveals bilateral symmetrical hyperintensity with diffusion restriction (open arrows) in corticospinal tract extending from posterior limb of internal capsule, crus cerebri of midbrain and basilar part of pons. Hyperintensity with restricted diffusion is seen in bilateral corona radiata and splenium of corpus callosum also.

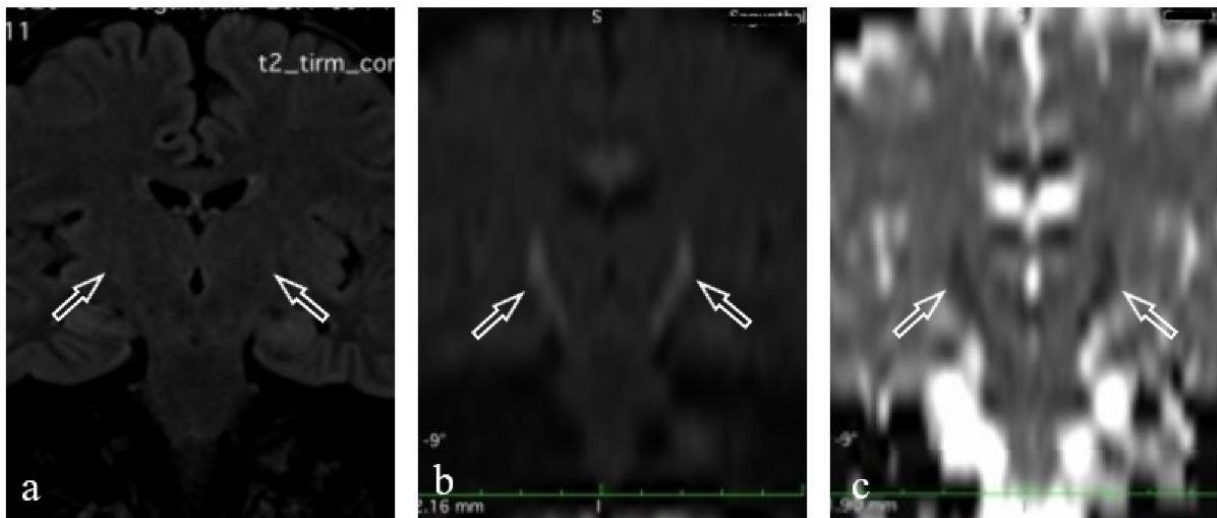


Figure 7: MRI of another patient showing coronal image of FLAIR (a), coronal reformatted images of DWI (b) and corresponding ADC mapping (c) reveals bilateral symmetrical hyperintensity with diffusion restriction (open arrows) in the corticospinal tract.

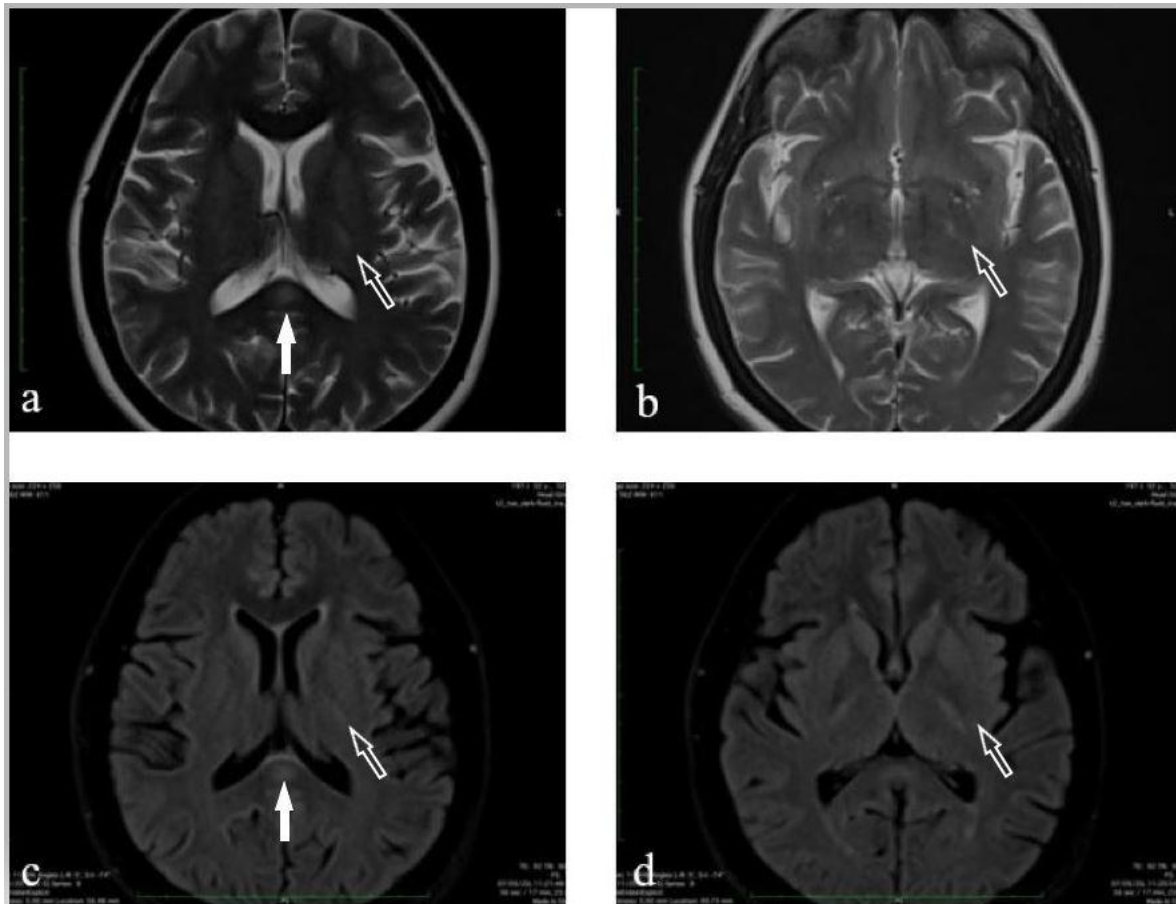


Figure 8: Repeat Magnetic resonance imaging of a patient showing axial sections of T2-weighted (a, c) and fluid attenuated inversion recovery (b, d) images reveals residual T2/FLAIR hyperintensity in splenium of corpus callosum (solid arrow) and bilateral posterior limb of internal capsule (open arrow).

V. Discussion

The increase in the average age of pregnancy in recent decades, parallely increased the pregnancy associated complications¹³. The range of neurological complications affecting the pregnancy and perurperium is very broad^{14, 15}. They may be either unique to pregnancy and perurperium or directly / indirectly related to or aggravated by pregnancy with some others being unrelated to pregnancy¹⁶. Some of them turn out to be emergency in certain situations and may have grave prognosis if not diagnosed and treated promptly¹⁶. Thus it is crucial to have a flawless and safe diagnostic approach towards these emergencies.

In the midst of the common causes of postpartum encephalopathy like eclampsia, cerebral venous thrombosis, posterior reversible encephalopathy syndrome, migraine, etc, uncommon etiologies also play critical role, dyselectrolemias being one of them². The most common dyselectrolemia, as we all know is hyponatremia, the rapid correction of which leads to osmotic demyelination syndrome (ODS)³, one of the most devastating conditions. However it is not surprising to know that hypernatremia which is actually an inverse condition of hyponatremia, also leads to ODS^{4, 5}. Hence, we need to understand that some common pathogenesis takes place during the correction of sodium, whether it is in high end or low end.

The total body water and the concentration of solutes called osmolality are maintained within a cramped limit and are regulated by multiple homeostatic mechanisms, the interruption of which leads to hypo-osmolality or hyper-osmolality¹⁷. The major solute being sodium, hypo-osmolality and hyper-osmolality most often accounts to hyponatremia and hypernatremia respectively.

Dehydration occurring in hypernatremia leads to rapid intracellular fluid loss in brain, which is prevented by a protective mechanism of generation of new intracellular idiogenic osmoles thereby increasing the intracellular osmolality and minimizing cerebral dehydration¹⁷. It is thought that, as a consequence of this, during correction of hypernatremia and replacement of extracellular fluid, an increase in intracellular shift of water associated with idiogenic osmoles leads to cerebral edema^{17, 18, 19}. These idiogenic osmoles are identified as myo-inositol, N-acetylaspartate, choline and taurine^{17, 18}.

These alterations of extracellular and intracellular components affects the oligodendrocytes leading to their injury and myelin degradation^{2, 17}. Grey matter rich areas are more vulnerable for these myelinotoxic

substances released due to the osmotic injury²⁰ and hence the characteristic involvement of the regions in hypernatremic osmotic myelinolysis.

The etiology for postpartum hypernatremia might have been contributed by several factors like fever, restricted water intake due to ritualistic feeding practices, lack of sensation of thirst due to postpartum hypothalamic dysfunction and unmasking of partial ADH secretion^{9,11,12} because of the enhanced peripheral breakdown by vasopressinase.

“Damn if we do, damn if we don’t” is the statement aptly fitting to the correction of sodium level. Hence we need to be vigilant in the correction of hypo/hypernatremia. We should do optimal correction at the optimal time, failure of which may jeopardize the patient.

MRI brain is the imaging modality of choice for accurate diagnosis of hypernatremic osmotic demyelination. The picture is different from osmotic demyelination induced by hyponatremia, which involves central pontine as well as extrapontine structures. Here it involves only extrapontine structures ie. internal capsule most commonly posterior limb, external capsule, corona radiata, crus cerebri, middle cerebellar peduncles, hippocampal isthmus, fornix, basal ganglia, thalamus and cerebellar white matter in different combinations in different patients. These areas show symmetrical T2/FLAIR hyperintensities along with restricted diffusion^{2, 9, 10, 11, 12, 17-19, 21}. Corpus callosum is involved in majority of cases, particularly splenium, showing swelling, signal intensity changes and diffusion restriction^{2, 9, 10, 11, 12, 17-19, 21}. More typically involved is the cortico-spinal tract which on coronal MRI shows signal intensity changes with diffusion restriction, that gives the appearance of ‘wine glass’^{2, 9, 10, 11, 12, 17-19, 21}, earlier described in amyotrophic lateral sclerosis. It depicts the involvement of corona radiata, posterior limb of internal capsule, crus cerebri of midbrain, basilar part of pons and medullary pyramid showing continuous symmetrical T2/FLAIR hyperintensity and diffusion restriction in coronal MRI^{10, 11}.

When severe, patients enter into the state of rhabdomyolysis causing breakdown of muscle fibres and release of creatine phosphokinase and myoglobin in blood. The serum creatine phosphokinase level would be higher in these patients^{2, 9, 10, 11, 12, 17-19, 21}. Some patients would suffer from azotemia too.

Naik and Saroja et al in their article in 2010 published that 11 perurperal patients with encephalopathy showed hypernatremia, azotemia and rhabdomyolysis and 10 of them showed symmetrical hyperintensities in internal capsule, corona radiata and cerebellar peduncles and also in corpus callosum⁹. In our study also, distribution of hyperintensities were symmetrical and involved internal capsule, corona radiata, cerebellar peduncles and basal ganglia and thalamus. Corpus callosum was involved in 9 patients. In his study 4 patients died while others recovered. No patients died in our study, but 2 patients had residual focal neurological deficit and follow up MRI showed residual T2 hyperintensity while others recovered.

Saroja AO et al in 2013 in her case report of recurrent postpartum hypernatremic osmotic demyelination published that wine glass sign was seen during recurrent episode of hypernatremic demyelination¹¹. However, in our study, wine glass sign was demonstrated in the first episode itself in 5 patients.

Phajir Vishwanath SR et al in 2015 in his case report documented 2 postnatal patients of hypernatremic osmotic myelinolysis and he reported that one of the case showed typical features of symmetrical hyperintensities in posterior limb of internal capsule, external capsule, crus cerebri, corticopontine tracts, middle cerebellar peduncle, hippocampus, fornix, and cerebellar white matter with classical appearance of wine glass and another case with atypical imaging features with small focal hyperintensity in splenium of corpus callosum². All the patients in our study showed typical findings in MRI and corpus callosum involvement was seen in 9 patients.

Archana B Netto et al in his case report in 2016 published a case of hypernatremic extrapontine myelinolysis showing T2/FLAIR hyperintensities in bilateral putamen, isthmus of hippocampus, middle cerebellar peduncles, posterior internal capsule and subcortical white matter. Also he wrote that the condition has mortality rate of > 60% and should be treated at the earliest²¹. Our study suggests that mortality could be nil if the condition is diagnosed at its earliest and prompt treatment is started at the optimal time.

Suri V et al in his case report in 2017 mentioned the presence of wine glass sign in a postpartum hypernatremic osmotic demyelination¹². In our study, wine glass sign was demonstrated in 5 patients.

Our study shows that all postnatal encephalopathy mothers should be suspected for this devastating condition and serum sodium levels should be ordered. Meanwhile the patients should be shifted for MRI brain at the earliest to look for the imaging features of hypernatremic extrapontine demyelination. Once the diagnosis is done, the ideal slow correction of sodium should be started soon. The patient’s condition will start to improve when correction is done at the ideal speed. The patient’s improvement is monitored clinically, biochemically as well as radiologically. MRI brain should be repeated after a week or earlier to look for the residual lesion. Our study showed that patients who were imaged and diagnosed at the earliest were started treatment soon, and so the recovery was complete. The patients who were brought late for imaging and diagnosis, treatment was also

started late, these patients had residual neurological defects. The follow up MRI also showed residual lesion leading to morbidity.

Thus MRI plays an important role in the early diagnosis and follow up of these patients. In our study, all patients in acute stage had diffusion restriction of involved regions. 3 of them showed no abnormality in T2/FLAIR sequences. Hence, diffusion weighted imaging is superior over other sequences in diagnosing the condition earlier aiding for the timely effective management.

VI. Conclusion

Hypernatremic osmotic demyelination is like a double edged sword, both correcting as well as uncorrecting the sodium levels will jeopardize the patient. Thus there needs to be a flawless and safe diagnostic approach towards these emergencies. MRI brain is the modality of choice and diffusion weighted imaging is much more sensitive in early diagnosis than any other sequences. The main key in diagnosing this condition relies on the recognition of the characteristic imaging features in MRI by the radiologist and the prognosis of the patient depends on the commencement of early and optimal correction of hypernatremia, for which earlier suspicion of disease and earlier imaging are required that eventually can prevent morbidity as well as mortality. The earlier the diagnosis is made, the earlier the treatment will be started. The earlier the treatment is started, better will be the prognosis of the patient and lesser will be the residual lesion. More appropriate therapy at appropriate time will cure the disease completely without residual neurological defect. As time is brain for stroke, time is brain for this condition too.

References

- [1]. Hosley CM, McCullough LD. Acute neurological issues in pregnancy and the peripartum. *Neurohospitalist* 2011;1[2]:104-16.
- [2]. Phajir Vishwanath SR, Sekhar M, Bele K, Chandrashekar RK. Postpartum hypernatremic cerebral encephalopathy with osmotic myelinolysis: Report of two cases and review with emphasis on magnetic resonance imaging findings. *Int J Adv Med Health Res* 2015;2:112-5.
- [3]. Martin RJ. Central pontine and extrapontine myelinolysis: The osmotic demyelination syndromes. *J Neurol Neurosurg Psychiatry* 2004;75 Suppl 3:iii22-8.
- [4]. Clark WR. Diffuse demyelinating lesions of the brain after the rapid development of hypernatremia. *West J Med* 1992;157:571-3.
- [5]. Riggs JE. Neurologic manifestations of electrolyte disturbances. *Neurol Clin* 2002;20:227-39 vii.
- [6]. Kallakatta RN, Radhakrishnan A, Fayaz RK, Unnikrishnan JP, Kesavadas C, Sarma SP. Clinical and functional outcome and factors predicting prognosis in osmotic demyelination syndrome [central pontine and/or extrapontine myelinolysis] in 25 patients. *J Neurol Neurosurg Psychiatry* 2011;82:326–31.
- [7]. Brown WD, Caruso JM. Extrapontine myelinolysis with involvement of the hippocampus in three children with severe hypernatremia. *J Child Neurol*. 1999;14:428–33.
- [8]. Maeda M, Tsukahara H, Terada H, Nakaji S, Nakamura H, Oba H, et al. Reversible splenic lesion with restricted diffusion in a wide spectrum of diseases and conditions. *J Neuroradiol* 2006;33:229–36.
- [9]. Naik KR, Saroja AO. Seasonal postpartum hypernatremic encephalopathy with osmotic extrapontine myelinolysis and rhabdomyolysis. *J Neurol Sci* 2010;291:5–11.
- [10]. Sonia Bhatia, Abhay Kumar Kapoor, Anurag Sharma, Rajiv Gupta, Sushila Kataria. Cerebral encephalopathy with extrapontine myelinolysis in a case of postpartum hypernatremia. *Indian J Radiol Imaging* 2014 Jan-Mar; 24[1]: 57–60.
- [11]. Saroja AO, Naik KR, Mali RV, Kunam SR. Wine Glass' sign in recurrent postpartum hypernatremic osmotic cerebral demyelination. *Ann Indian Acad Neurol* 2013;16:106–10.
- [12]. Suri V, Jasuja S, Suri N, Saini R, Naga MK, Suri K. Postpartum hypernatremic encephalopathy with "Wine Glass Sign" on magnetic resonance imaging. *Apollo Med* 2017;14:188-9.
- [13]. Luke B, Brown MB. Elevated risks of pregnancy complications and adverse outcomes with increasing maternal age. *Hum Reprod* 2007;22[5]:1264–72.
- [14]. Goldstein PJ. Neurological disorders of pregnancy. New York: Future Publishing, 1986.
- [15]. Donaldson JO. Neurology of pregnancy. 2nd ed. London: Saunders, 1989
- [16]. Koushik Pan I, Shyamal Kumar. Neurological Emergencies in Pregnancy. *J Ass Phys India* Volume : 66
- [17]. Jung Hee Lee, Edgardo Arcinue, Brian D. Ross. Organic Osmolytes in the Brain of an Infant with Hypernatremia . *N Engl J Med* 1994; 331:439-42.
- [18]. Kashinkunti M, Hemamalini G, Halakatti BV, et al. Postpartum hypernatremic encephalopathy with osmotic extrapontine myelinolysis and rhabdomyolysis: a case report. *Sch J Med Case Rep* 2014; 2: 420–42.
- [19]. A Chhabra, R Kaushik, RM Kaushik, D Goel. Extra-pontine myelinolysis secondary to hypernatremia induced by postpartum water restriction. *Neuroradiol J* 2017 Feb; 30[1]: 84–7.
- [20]. Jain N, Phadke RV, Chauhan G, Ambesh S P. Osmotic demyelination syndrome in the setting of hypernatremia. *Neurol India* 2018;66:559-60.
- [21]. Archana B Netto, N. Deepak, Chaithra S.P, T. Thahira, N. Karthik, Agadi Jagadish B. Osmotic Demyelination Syndrome and Rhabdomyolysis Secondary to Postpartum Hypernatremia. *International Journal of Neurology and Neurosurgery* Volume 8, Issue 1, January - June 2016, Pages 9-12.

Dr. Barakath Nisha Abdul Ajis. "Role of Mri Brain In Early Diagnosis Of Rare Entity Of Postpartum Osmotic Extrapontine Myelinolysis Due To Hypernatremic Encephalopathy And Assessment Of Its Reversibility." *IOSR Journal of Dental and Medical Sciences (IOSR-JDMS)*, 20(10), 2021, pp. 48-56.