

Malignant Melanoma of the Nasal Cavity and Paranasal Sinuses: A Case Report

Saroj Kafle¹, Niva Sharma², Nivash Sharma³, Santosh Kafle⁴

¹Department of Otorhinolaryngology–Head and Neck Surgery, Karnali Academy of Health Sciences, Jumla, Nepal

²Department of Gynecology/ Obstetrics, Karnali Academy of Health Sciences, Jumla, Nepal

³Department of Orthopedics, Lumbini Provincial Hospital, Butwal, Nepal

⁴Department of Physiotherapy, Universal College of Medical Sciences, Bhairahawa, Nepal

Corresponding author: Dr. Saroj Kafle

Abstract

Malignant melanoma of nasal cavity and paranasal sinuses is a rare tumor encountered by ENT surgeons. This is case of 50 yrs old female with complaint of recurrent episodes of nasal bleed with nasal obstruction. The patient's history revealed recurrent episodes of nasal bleeding for past 4 months. She also complained of progressively increasing nasal obstruction from left nose for 3 months. Nasal endoscopy was done which revealed a smooth pinkish mass in the left nasal cavity, filling the whole middle meatus, and extending till, just anterior to the choana. The nasal endoscopy on the right side was normal. The histopathological examination gave a conclusive diagnosis of Malignant Melanoma. CT scan of PNS confirmed the finding of a localized mass in left nasal cavity. Surgical excision was done and patient was referred to higher center for radiotherapy.

Key words: Epistaxis; Malignant Melanoma; Paranasal Sinus ; Radiotherapy

Date of Submission: 09-03-2021

Date of Acceptance: 23-03-2021

I. Introduction

Tumors arising from melanocytes which are neuroectodermally derived cells located in the basal layers of skin, skin adnexa and some of the mucosal membrane are called melanoma. Common sites for melanomas are head, neck and the lower extremities, which is one of the predisposing factors. Less common sites of involvement are oral and genital mucosa, nail beds, conjunctiva, orbit, esophagus, nasal mucosa or nasopharynx, vagina and leptomeninges. Primary melanoma of head neck accounts for 25% to 30% of all melanomas¹. However the incidence of melanomas arising from mucosal surface of aero digestive tract varies from 0.4 to 4%². Tumors arising in the nasal cavity or Para nasal sinuses less in number^{3,4}. The peak age incidence is between fifth and eighth decade⁵. It is more commonly seen in males than females, although age and sex do not affect the prognosis^{6,7}. Resection with a clear margin is emphasized as the most important factor for good local control and better prognosis. However, radical surgery is not possible in certain cases as many important organs may be located near the tumor.

II. Case Report

A 50 yrs old female presented to our ENT OPD with the complaint of recurrent episodes of nasal bleeding and nasal obstruction. The patient's history revealed recurrent episodes of nasal bleeding for past 4 months. She also complained of progressively increasing nasal obstruction from left nose since 3 months. A few days after when the patient settled down, diagnostic nasal endoscopy was performed which revealed a pink, smooth mass in the left nasal cavity, filling the whole middle meatus, and extending till choana. The nasal endoscopy on the right side was within normal limits. The biopsy was taken in the same sitting and sent for histopathological examination, which gave a conclusive diagnosis of Malignant Melanoma (Fig.1). CT scan of PNS confirmed the finding of a localized mass in left nasal cavity involving the left anterior and posterior ethmoid sinuses (Fig.2) also blocking the infundibulum of maxillary antrum. There was a mass effect on the left orbit pushing the medial wall. However there was no evidence of direct orbital involvement. Superiorly the mass was extending up to the cribriform plate with possibility of its erosion at some places, however the patient did not have any altered smell or any signs of meningeal irritation. There was no involvement of sphenoid sinuses, regional lymphnodes or any distant organ. The disease was not found eroding nasal septum and was limited to left side only. The Patient was under gone for surgical excision. After surgery she was referred to department of Radiation Oncology for radiotherapy at higher center.

III. Figures

Figure 1: Showing histopathology of Tumor tumor

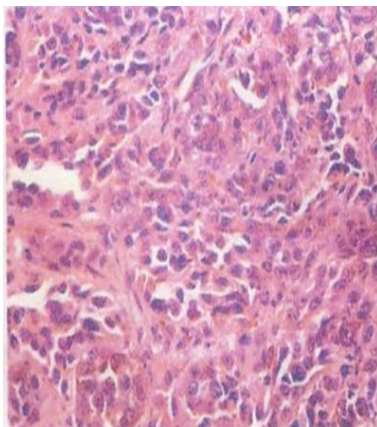
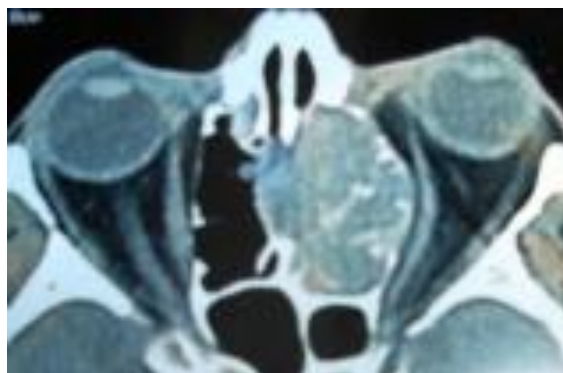


Figure2: CT scan axial cut, showing the extent of the tumor



IV. Discussion

Malignant melanoma is comparatively rare in comparison to squamous cell carcinomas among the cancers that arise in nasal cavity and Para nasal sinuses. The natural course of malignant melanomas is marked by early local recurrences, extensions and frequent metastasis to lymph nodes and viscera, making it one of the most dangerous forms of nasal and paranasal sinus tumors. The incidence of regional lymph node metastasis on admission is approximately 5% to 15%⁸. The submandibular lymphnodes are most commonly involved. High index of suspicion is required to make an early diagnosis. Generally ENT surgeons do not have any problem in diagnosing and staging this disease but owing to its rarity there remains some disparity in deciding the proper plan of treatment.

In general, the management of mucosal melanomas has not been uniform. The only definitive prognostic factor is the presence of distant metastasis at the time of diagnosis. As a rule, the patients with localized disease should undergo surgery followed by postoperative radiotherapy for better local control of the disease.

Historically, mucosal melanoma was characterized as radio-resistant disease, but recent observations have suggested that radiotherapy has a significant role in their treatment⁹. Literature shows overall response rate of 50% to 75%, if radiotherapy alone is used for treating localized mucosal melanomas. These are more radiosensitive than their cutaneous counterparts. Surgery along with adjuvant radiotherapy should be used for patients with either regional metastases or large bulky primary disease.

Melanoma is relatively chemo resistant tumor; thus, the main role of chemotherapy remains palliative treatment in the setting of disseminated disease. Recent studies showed that immunotherapy might have role in the treatment of malignant melanomas.

V. Conclusion

Most of malignant melanomas arise in the nasal cavity. Those that arise in the paranasal sinuses tend to be relatively advanced at diagnosis. It was typically presents with nasal obstructive symptoms and epistaxis. Treatment of malignant melanoma is the same, stage for stage (i.e. surgery and post op radiotherapy). Mucosal melanomas tend to be more aggressive and have a poorer prognosis than cutaneous counterparts, having 10% to 15% 5-year survival rates. The poor prognosis may be attributed to local recurrence, distant metastasis and/or second primary. Hence the importance of life time surveillance, patient's education and monthly self examination of skin and regional lymph nodes for A (Asymmetry), B (Border), C (Color), D (Diameter) of melanoma surveillance should not be overlooked.

Several new biologic and immunomodulatory treatments are currently being investigated for use in patients with mucosal melanoma: the results of such treatment approaches are eagerly awaited.

References

- [1]. Goldsmith HS. Melanoma: An overview. *CA Cancer J Clin* 1979; 29:194-215.
- [2]. Berthelsen A, Andersen AP, Jensen S, Hansen HS. Melanomas of the mucosa in the oral cavity and the upper respiratory passages. *Cancer* 1984; 54:907-912
- [3]. McKinnon JG, Kokal WA, Neifeld JP, et al. Natural history and treatment of mucosal melanoma. *J Surg Oncol* 1989; 41:222-225.
- [4]. Stern SJ, Guillaumondegui OM. Mucosal melanoma of the head and neck. *Head Neck Surg* 1991; 13:22-27.
- [5]. Batsakis JG, Suarez P, Naggar AK. Pathology consultation, mucosal melanomas of the head and neck. *Ann Otol. Rhinol Laryngol* 1998; 107:626-630
- [6]. Batsakis JG, Regezi JA, Soloman AR, Rice DH. The pathology of head and neck tumors; mucosal melanomas, Part B. In: *Head and Neck Surgery* 1982; 4:404-418
- [7]. Snow GB, van der Waal I. Mucosal melanomas of the head and neck. *Otolaryngol Clin North Am* 1988; 19:549-564
- [8]. Batsakis JG. Pathology of tumors of the nasal cavity and. paranasal sinuses and neck cancer. Philadelphia: WB Saunders Company; 1999; 522-539
- [9]. Conley JJ (1989) Melanomas of the mucous membrane of the head and neck. *Laryngoscope* 1999; 1248-1254.