

## Leiomyosarcoma of Mesentery: A Case Report

Dr. Manisha Narayana<sup>1</sup>, Dr. Divya R I<sup>2</sup>

<sup>1</sup>General Surgery, Bowring And Lady Curzon Hospital, India

<sup>2</sup>General Surgery, Bangalore Medical College and Research Institute, India

---

**Abstract:** *Leiomyosarcoma are aggressive soft tissue sarcomas, derived from smooth muscle cells, typically of uterine, gastrointestinal, blood vessels, or other soft tissue origin. Leiomyosarcomas of the mesentery are rare tumors. We report a case of a patient who presented with a mass per abdomen associated with pain, diagnosed with leiomyosarcoma of mesentery after immunohistochemistry.*

**Key Words:** *Leiomyosarcoma, Mesentery*

---

Date of Submission: 29-03-2021

Date of Acceptance: 12-04-2021

---

### I. Introduction

Primary tumors arising from the mesentery are rare, lymphomas being the most common<sup>1</sup>. However, leiomyosarcomas of mesenteric origin are rare tumor<sup>2</sup> with an incidence of 1:350000<sup>3</sup>. Leiomyosarcomas are malignant tumors that arise from smooth muscle cells. The clinical, radiological and histopathological features, and prognosis of leiomyosarcomas are unique for each site of origin<sup>4</sup>. A mesenteric tumor may present with palpable abdominal mass, distention, or discomfort, but it rarely causes symptoms, because of its mobility in the peritoneal space or fixation in the retroperitoneum<sup>5</sup>. Therefore, a mesenteric tumor tends to be large when it is found.

### II. Case Report

A 80 year old gentleman presented with complaints of mass per abdomen since 3 months and pain in the left upper abdomen and umbilical region since 20 days. No associated altered bowel/ bladder habits. No history of nausea, vomiting, bleed PR or malena, or weight loss. No history of fever. No history of trauma. No history of swellings elsewhere in the body. No significant family history. No previous surgical interventions. No comorbidities. He was diagnosed with pulmonary tuberculosis 2 years ago, for which he has taken anti-tubercular treatment under RNTCP for 2 years. On examination the patient was conscious, cooperative, well oriented to time, place and person, well built and nourished. Patient was afebrile. No pallor, icterus, cyanosis, clubbing, generalized lymphadenopathy, or oedema. Patient had stable vitals: PR= 82 bpm, BP= 120/80 mmHg, RR= 20 cpm, SPO2= 99% at room air.

On inspection the abdomen was normal in shape. Umbilicus was central and inverted. Corresponding quadrants moved equally with respiration. No visible dilated veins, scars, sinuses. On palpation there was no local rise of temperature. A 4x5cm mass was palpated in left hypochondrium and epigastrium, with nodular surface, hard in consistency. Tenderness elicited in left hypochondrium, epigastrium and umbilical regions. No hepatomegaly, no splenomegaly. Other systems examination were within normal limits.

On routine workup, all blood parameters were within normal limits. Patient was worked up with USG A+P, and CECT A+P . USG A+P showed a large well defined heterogenous mass lesion measuring 4.3x5.6cm arising from small bowel.

CECT A+P showed a well defined mild homogenously enhancing soft tissue density mass lesion measuring 6x5cm with center luminal contrast representing involvement of small bowel loops more likely jejunal loops however there is no prestenotic dilatation seen, rest of the bowel loops were unremarkable.

Patient underwent exploratory laparotomy. A 6x5cm highly vascular mass seen arising from the mesentery near the ileojejunal junction, with mesenteric lymph nodes (Fig. 1). The mass was excised in toto with mesentery and small bowel loops and anastomosis was done. Resected specimen was sent for histopathology which showed leiomyosarcoma, moderately to poorly differentiated, restricted to the mesentery, with uninvolved margins, with lymphovascular invasion. Diagnosis was confirmed by immunohistochemistry, which was strongly positive for desmin and smooth muscle actin.

### III. Discussion

Mesenteric masses, primary or metastasis, pose a diagnostic and therapeutic challenge<sup>1,3</sup>. The mesentery is a common site for the metastasis of gastrointestinal malignancies. Primary tumors arising from the

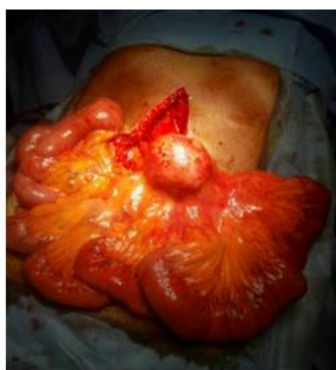mesentery are relatively rare, lymphomas being the most common followed by mesenchymal malignancies<sup>1</sup>. Malignancies include Gastrointestinal Stromal tumors (GIST), leiomyosarcoma, liposarcoma, fibrosarcoma, pleomorphic undifferentiated sarcomas and hemangiopericytomas. Differentiating leiomyosarcomas from GISTs histologically is difficult and is done by IHC. Leiomyosarcomas are derived from smooth muscle cells, they stain positively for smooth muscle markers and negatively for intestinal markers<sup>6</sup>. Leiomyosarcomas of bowel mesentery are associated with poor prognosis and 5 year survival rate is only between 20-30%. Complete primary surgical resection with negative margins is critical for achieving the best outcome. In this case, complete surgical resection of the tumor with negative margins was achieved, post-operative period was uneventful and patient is presently on follow-up.

#### IV. Conclusion

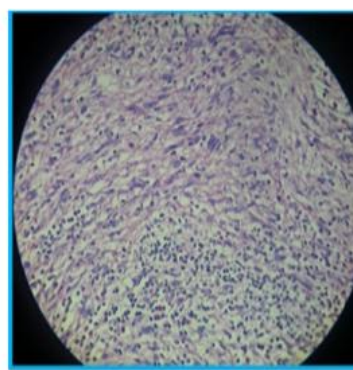
Mesenteric masses often pose a diagnostic and therapeutic challenge. Definitive guidelines are still unclear because of the small number of cases reported<sup>7</sup>. Patients should be kept on long-term follow-up.

#### References

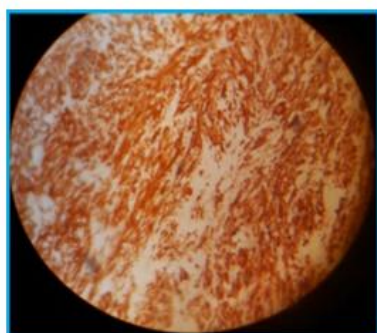
- [1]. Sharma R, Mahajan N, Vij A, Chaudhary UK, Sharma A. Mesenteric Leiomyosarcoma Mistaken as Subserosal Fibroid. A Rare Case Report. 2015;2:8–10.
- [2]. Kato T, Noda H, Abe I, Alonso S, Yokoyama N, Rikiyama T. Curative resection for leiomyosarcoma of the descending mesocolon with metachronous liver metastasis: A case report and literature review. *Mol Clin Oncol.* 2016;5:53–56.
- [3]. Dalal V, Kaur M, Menia R, Siraj F, Bhatnagar A, Agrawal U. Primary Leiomyosarcoma of the Mesentery: A Case Report. *Iran J Med Sci.* 2017;42(5):505-508.
- [4]. Bathan AJ, Constantinidou A, Pollack SM, Jones RL. Diagnosis, prognosis, and management of leiomyosarcoma: recognition of anatomic variants. *Curr Opin Oncol.* 2013;25:384–9.
- [5]. Nagarsheth NP, Nicastrì DG, Kashani M, Fried K. Complete surgical resection of a 40- cm leiomyosarcoma of the large bowel mesentery. *J Surg Educ.* 2007;64:162–4.
- [6]. Affas S, Ayas MF, Mendes JM, Hadid T. Primary Leiomyosarcoma of the Mesentery: A Case Report With Review of Literature. *Cureus.* 2020;12(10):e10777.
- [7]. Koyama R, Maeda Y, Minagawa N, Shinohara T. A case of laparoscopic resection of leiomyosarcoma arising in the mesentery of descending colon: a case report and review of the literature. *Clin Case Rep.* 2020;8(12):3344-3348.



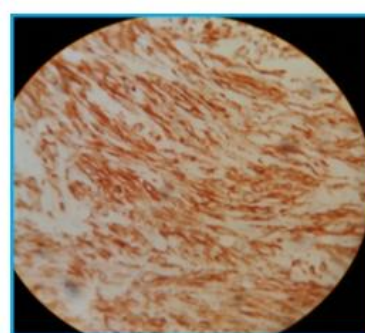
(Fig. 1) Mass arising from the mesentery



(Fig. 2) Elongated fusiform cells with eosinophilic cytoplasm



(Fig. 3) Smooth Muscle Actin



(Fig. 4) Desmin

Dr. Manisha Narayana, et. al. "Leiomyosarcoma of Mesentery: A Case Report." *IOSR Journal of Dental and Medical Sciences (IOSR-JDMS)*, 20(04), 2021, pp. 14-15.