

## Surgically Induced Corneal Astigmatism Following Cataract Surgery

Dr. Jitendra Kumar<sup>1</sup>, Dr. Shailendra Batham<sup>2</sup>

1. Associate Professor & Head, Dept. of ophthalmology, MLB Medical College Jhansi, India.

2. Junior Resident, Dept. of ophthalmology, MLB Medical College Jhansi, India.

Corresponding author: Dr. Jitendra Kumar

---

### Abstract

**Aim:** To study the surgically induced astigmatism (SIA) caused by two different type main incisions in phaco-emulsification.

**Methods:** In this prospective randomised controlled study, Sixty-eight eyes of 65 patients who underwent phaco-emulsification were randomly divided into two groups according to main incision type: 2.8 mm superior limbal incision (in Group 1) and 2.8 mm upper clear corneal incision (in Group 2). Surgical techniques did not differ between the groups except for the main incisions. All patients received detailed ophthalmological examination in addition to keratometry at the pre- and post-operatively. The preoperative and postoperative astigmatisms were calculated by the vector analysis method and the SIA was compared between the groups.

**Results:** The mean SIA values were  $1.3 \pm 0.67$  D,  $0.89 \pm 0.47$  D,  $0.77 \pm 0.37$  D in Group 1 and  $1.42 \pm 0.62$  D,  $1.15 \pm 0.54$  D,  $0.94 \pm 0.47$  D in Group 2 on the first day, first week and first month postoperatively, respectively. According to the vector analysis, SIA was less in Group 1 than Group 2; although the difference was not statistically significant ( $p > 0.05$ ).

**Conclusion:** Although less astigmatism was detected in the superior limbal incision group, this difference was not statistically significant.

**Keyword:** Phaco-emulsification, Surgically Induced Astigmatism.

---

Date of Submission: 30-05-2021

Date of Acceptance: 13-06-2021

---

### I. Introduction

Cataract is the leading treatable cause of blindness in the world and it is treated by surgery only. Due to fast visual improvement and lower complication rate, cataract extraction by phaco-emulsification and the insertion of a foldable intraocular lens (IOL) through a small incision is the preferred surgical method<sup>[1]</sup>. Currently, cataract surgery is considered as a type of refractive surgery and reduction of refractive defects to the lowest level is possible, leading to increased expectations of patients. Astigmatism due to surgery may affect vision quality and varies related to the type and size of the incision and suture utilization<sup>[2]</sup>. In this study, surgically induced astigmatism (SIA) following phaco-emulsification by 2.8 mm superior limbal incision and superior clear corneal incision were compared.

### II. Materials and Methods

This prospective comparative study was carried out on patients of Department of Ophthalmology at Maharani Laxmi Bai Medical College, Jhansi, Uttar Pradesh from November 2020 to January 2021. A total 65 adult subjects (both male and females) of aged  $\geq 50$ , years were enrolled in this study, subjected to phaco-emulsification and IOL implantation were enrolled in this study. Ethical approval was obtained from the Maharani Laxmi Bai Medical College ethics committees and informed consent was obtained from all patients. The study adhered to the tenets of the Declaration of Helsinki.

**Study Design:** Prospective open label observational study

**Study Location:** This was a tertiary care teaching hospital based study done in Department of Ophthalmology at Maharani Laxmi Bai Medical College, Jhansi, Uttar Pradesh

**Study Duration:** November 2020 to January 2021.

**Sample size:** 65 patients.

**Inclusion criteria:**

- Patients with cataract
- Patients with >50years of age.
- Either sex

**Exclusion criteria:**

- Patients with previous ocular surgery, diabetes, systemic connective tissue disorder, severe dry eye, pterygium, corneal scar, degeneration and ectasia, pseudo-exfoliation, uveitis, glaucoma, high myopia and retinal diseases.
- Patients with complications such as non-completed capsulorhexis during the operation.
- Patients with zonular dialysis, posterior capsule opening.
- Patients with sutured incisions.
- Patients without regular post-op follow up were excluded.

Ophthalmologic evaluation included best corrected visual acuity (BCVA) by Snellen chart, refraction, keratometry, biomicroscopy, detailed fundus examination, and intraocular pressure (IOP) measurement and corneal topography (Orbscan 2z, B & L, USA). IOL diopter was calculated by Reichert B&L keratometer and Carl- Zeiss biometry instrument according to SRK-T formula. Pre- and post-operative astigmatism was calculated by vector analysis and the effect of the incision site on astigmatism due to surgery was compared. All operations were performed by single surgeon under topical anesthesia by proparacaine HCl 0.5%

(Alcaine; Alcon, Puurs, Belgium). Patients were assigned randomly into two groups. Main incision was made with two sided 2.8-mm blade. One-step superior limbal incision was done in Group 1 and superior clear corneal incision in Group 2. There was no difference between the groups, except location of incision, in any aspects of surgery. Nucleus was broken by “horizontal chop” method and was emulsified using a ZEISS Visalis 100 phaco-emulsification instrument. Hydrophobic acrylic IOL (Acryva UD 613.VSY, Istanbul, Turkey) was placed by injector-cartridge system. In this study, surgical SIA Calculator Version 2.1 vector analysis program developed by Sawhney and Aggarwal, was used. SPSS (Statistical Package for Social Sciences) 17.0 program was used for statistical analysis. Mann Whitney U, Friedman and t tests were used for data comparison. Any p value less than 0.05 ( $p < 0.05$ ) was accepted as significant. Power analysis recommended a minimum of 33 eyes per group in order to obtain an efficacy size of 0.8, alpha value 0.05 and statistical power of 0.8.

**III. Results**

Sixty-eight eyes of 65 patients (31 females, 34 males) were included. Superior limbal incision was used in 35

patients (13 female, 22 male) (Group 1) and superior clear corneal incision in 33 patients (18 female, 15 male)

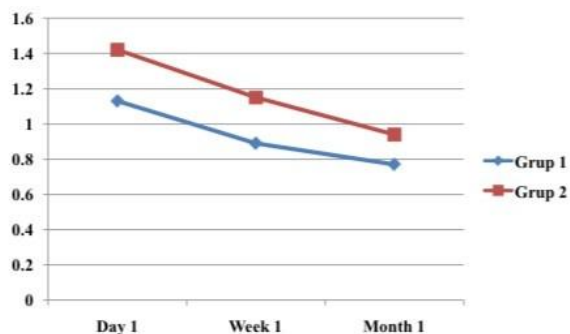
(Group 2). Mean age was  $64.00 \pm 8.83$  and  $64.12 \pm 10.30$  years in Group 1 and 2, respectively. No statistical differences were present between the two groups in terms of mean age ( $p = 0.959$ ) and gender distribution ( $p =$

$0.150$ ). Mean BCVAs in Group 1 were  $0.19 \pm 0.11$ ,  $0.36 \pm 0.23$ ,  $0.70 \pm 0.23$  and  $0.92 \pm 0.08$  pre-operatively, and postoperatively first day, first week and first month, respectively; same parameters were  $0.17 \pm 0.11$ ,  $0.38 \pm 0.24$ ,  $0.72 \pm 0.20$  and  $0.94 \pm 0.08$  in Group 2. No statistical difference was found between the groups in terms of these values ( $p = 0.512$ ,  $p = 0.808$ ,  $p = 0.686$  and  $p = 0.150$ ). Mean IOP measured by non-contact tonometry in Group 1 were  $12.71 \pm 3.81$  mmHg,  $15.06 \pm 3.39$  mmHg,  $12.85 \pm 3.54$  mmHg, and  $12.66 \pm 3.71$  mmHg pre-operatively, postoperatively first day, first week and first month, respectively; same parameters were  $13.09 \pm 2.98$  mmHg,  $15.27 \pm 4.93$  mmHg,  $13.00 \pm 3.93$  mmHg,  $12.97 \pm 2.70$  mmHg in Group 2. No statistical difference was found between the two groups in terms of these values ( $p = 0.643$ ,  $p = 0.567$ ,  $p = 0.875$  and  $p = 0.715$ ). Mean SIA calculated by vector analysis method was smaller in Group 1 than those in Group 2 however; the difference was not statistically significant between the groups (**Table 1** and **Figure 1**). In-group comparison, significant decrease was seen in astigmatism during postoperative wound healing period when analyzed by

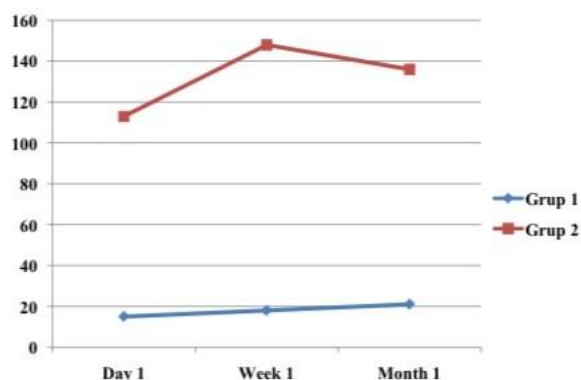
Friedman test ( $p$  values for Group 1 and 2 respectively, 0.045 and  $<0.001$ ).

Mean SIA centroid values calculated by vector analysis method in Group 1 and 2 were seen in **Table 2** and **Figure 2**. Mean SIA centroid axial values revealed that patients in Group 1 had irregular astigmatism whereas oblique astigmatism were seen in Group 2 postoperatively.

Correlation between mean SIA calculated by vector analysis and mean IOP was evaluated and no significant correlation was detected by assessing the effect of mean IOP on SIA ( $r < 0.50$ ) (**Table 3**).



**Figure 1.** Mean SIA in both groups (diopter) calculated by vector analysis method in both groups on postoperative 1st day, 1st week and 1st month.



**Figure 2.** Mean SIA centroid axial values (degree) in both groups calculated by vector analysis method in both groups at postoperative 1st day, 1st week and 1st month.

**Table 1.** Surgery-related astigmatism ± SD (dioptr) calculated by vector analysis method in both groups on postoperative 1st day, 1st week and 1st month.

Postoperative	Group 1	Group 2	t/u value	p value
1st day	1.13 ± 0.67	1.42 ± 0.62	-1.721 (t)	0.090
1st week	0.89 ± 0.47	1.15 ± 0.54	392 (u)	0.054
1st month	0.77 ± 0.37	0.94 ± 0.47	519 (u)	0.473

**Table 2.** Mean surgery-related astigmatism centroid (c) in both groups calculated by vector analysis method in both groups on postoperative 1st day, 1st week and 1st month.

Postoperative	Group 1		Group 2	
	Centroid	Axis	Centroid	Axis
1st day	0.81	15	0.31	113
1st week	0.60	18	0.26	148
1st month	0.43	21	0.46	136

**Table 3.** Correlation between mean surgery-related astigmatism calculated by vector analysis and mean IOP postoperative 1st day, 1st week, 1st month in both groups.

Postoperative	Group 1		Group 2	
	r value	p value	r value	p value
1st day	-0.21	0.219	-0.08	0.634
1st week	-0.27	0.116	-0.02	0.878
1st month	-0.14	0.421	0.18	0.300

### III. Discussion

Phaco-emulsification and IOL implantation technique is currently the most widely used ocular surgery. Corneal interventions affect corneal curve and refraction power. Post-surgical high astigmatism is one of the reasons behind unsatisfying visual outcomes of cataract procedure. Phaco-emulsification provides faster visual improvement, smaller surgical incision and less irregular astigmatism than other techniques. Foldable IOL usage leads to small incision site and minimal SIA. Post operative astigmatism after cataract surgery is related to two factors: preoperative astigmatism of patient and SIA [3] [4].

Surgically induced astigmatism is a frequent complication of cataract surgery and plays an important role in Post-operative visual acuity. Astigmatic variation is mostly due to corneal contour changes in SIA. Surgically induced astigmatism varies related to type, length and site of the incision, suture utilization, distance of incision to the optic centre of cornea. Even lower astigmatism is important, since this would affect distance sight of patients<sup>[3] [5]</sup>. Incision site is an important factor affecting SIA. While superior corneal or limbal incision leads to irregular astigmatism, temporal corneal incision leads to regular astigmatism. One or two sided temporal incisions lead to minimal astigmatism; however three sided and deep groove incisions lead to increased astigmatism<sup>[6]</sup>. Kohnen *et al.*<sup>[7]</sup> showed more SIA in nasal incisions in their study. They suggested that this could be due to more stress and corneal stretch in the wound site related to more perpendicular entrance to cornea in nasal incision and also to the closer location of nasal incision to corneal centre.

Wirbelauer *et al.*<sup>[8]</sup> compared superior, temporal and oblique vertical axial scleral tunnel incisions of 7.0 mm and detected flattening of vertical axis and steepening in horizontal axis. In addition, increased degrees of astigmatism were seen in superior incisions than all other incisions. Şimşek *et al.*<sup>[9]</sup> compared temporal clear corneal incision and superior clear corneal incision; they showed statistically significantly more and irregular astigmatism in superior corneal incisions.

In another study, Pakravan *et al.*<sup>[10]</sup> compared biplanar temporal and nasal clear corneal incisions of 3.2 mm and they determined statistically significantly less astigmatism for temporal incision (0.26 D) compared to nasal incision (0.92 D) at 6th month. Özkurt *et al.*<sup>[11]</sup> compared the effects of superior-nasal and superior-temporal clear corneal incisions on total astigmatism and they showed statistically significantly less total and SIA in temporal incision at 6th week. Long *et al.*<sup>[12]</sup> compared corneal tunnel incisions from vertical axis of 3.0 - 3.2 and 3.5 mm. Incisions on vertical meridian were reported to lead to more astigmatic change than ones at horizontal meridian. Kılıc *et al.*<sup>[13]</sup> compared superior temporal and superior nasal clear corneal incisions of 3.2 mm in their study. Surgically induced astigmatism was statistically significantly more frequent with nasal incision. Yayıcioglu *et al.*<sup>[14]</sup> compared nasal, temporal, superior temporal or superior clear corneal incisions to vertical .

#### IV. Conclusion

In conclusion, no differences were present in our study in terms of incision site and size between groups. Mean SIA was lower in limbal incision group than clear corneal incision group on postoperative first day, first week and first month. However, no statistically significant difference was present.

#### References

- [1]. Jackson, T.L. (2008) Moorfields Manual of Ophthalmology. Mosby Elsevier, Philadelphia, 6.
- [2]. Henderson, B., Pineda, R., Ament, C., Chen, S. and Kim, J. (2007) Essentials of Cataract Surgery. Slack Incorporated, Online Library, Chapter 2.
- [3]. Albert, D.M., Miller, J.W., Azar, D.T. and Blodi, B.A. (2008) Principles and Practice of Ophthalmology. 3rd Edition, Saunders Company, Philadelphia, Chapter 120.
- [4]. Henderson, B., Pineda, R., Ament, C., Chen, S. and Kim, J. (2007) Essentials of Cataract Surgery. Slack Incorporated, Online Library, Chapter 7.
- [5]. Kohnen, T. (1997) Corneal Shape Changes and Astigmatic Aspects of Scleral and Corneal Tunnel Incisions. Journal of Cataract Refractive Surgery, **23**, 301-302. [http://dx.doi.org/10.1016/S0886-3350\(97\)80168-X](http://dx.doi.org/10.1016/S0886-3350(97)80168-X)
- [6]. Henderson, B., Pineda, R., Ament, C., Chen, S. and Kim, J. (2007) Essentials of cataract surgery. Slack Incorporated, R2 Online Library, Chapter 6.
- [7]. Kohnen, S., Neuber, R. and Kohnen, T. (2002) Effect of Temporal and Nasal Unsutured Limbal Tunnel Incisions on Induced Astigmatism after Phacoemulsification. Journal of Cataract Refractive Surgery, **28**, 821-825. [http://dx.doi.org/10.1016/S0886-3350\(01\)01215-9](http://dx.doi.org/10.1016/S0886-3350(01)01215-9)
- [8]. Wirbelauer, C., Anders, N., Pham, D.T. and Wollensak, J. (1997) Effect of Incision Location on Preoperative Oblique Astigmatism after Scleral Tunnel Incision. Journal of Cataract Refractive Surgery, **23**, 365-371. [http://dx.doi.org/10.1016/S0886-3350\(97\)80181-2](http://dx.doi.org/10.1016/S0886-3350(97)80181-2)
- [9]. Simsek, S., Yasar, T., Demirok, A., Cinal, A. and Yılmaz, O.F. (1998) Effect of Superior and Temporal Clear Corneal Incisions on Astigmatism after Sutureless Phacoemulsification. Journal of Cataract Refractive Surgery, **24**, 515-518. [http://dx.doi.org/10.1016/S0886-3350\(98\)80294-0](http://dx.doi.org/10.1016/S0886-3350(98)80294-0)
- [10]. Pakravan, M., Nikkhab, H., Yazdani, S., Shahabi, C. and Rahimabadi, M.S.M. (2009) Astigmatic Outcomes of Temporal versus Nasal Clear Corneal Phacoemulsification. Journal of Ophthalmic Vision Research, **4**, 79-83.
- [11]. Özkurt, Y., Erdogan, G., Guveli, A.K., et al. (2008) Astigmatism after Superonasal and Superotemporal Clear Corneal Incisions in Phacoemulsification. International Ophthalmology, **28**, 329-332. <http://dx.doi.org/10.1007/s10792-007-9141-y>
- [12]. Long, D.A. and Monica, M.L. (1996) A Prospective Evaluation of Corneal Curvature Changes with 3.0 to 3.5 mm
- [13]. Corneal Tunnel Phacoemulsification. Ophthalmology, **103**, 226-232. [http://dx.doi.org/10.1016/S01616420\(96\)30712-4](http://dx.doi.org/10.1016/S01616420(96)30712-4) D. B. Kağnici et al
- [14]. Kılıc, A., Gul, A., Yener, H.I., Cinal, A. and Demirok, A. (2010) Surgically Induced Astigmatism after Superotemporal or Superonasal Clear Corneal Incision in Phacoemulsification Surgery. Van Medical Journal, **17**, 84-88.
- [15]. Yayıcioglu, A., Akova, Y.A., Akca, S., Gur, S. and Oktem, C. (2007) Effect on Astigmatism of the Location of Clear Corneal Incision in Phacoemulsification of Cataract. Journal of Refractive Surgery, **23**, 515-518.