

Comparative evaluation of Platelet Rich Plasma and Platelet Rich Fibrin as a scaffold for Regenerative Endodontic Procedure: A Clinical study.

Dr Haridas Das Adhikari, Dr. Sujith R , Dr. Aparna Gupta,
Dr Swati Markandey

(Department of Conservative Dentistry and Endodontics, Dr. R Ahmed Dental College and hospital,
Kolkata, West Bengal, India)

Abstract:

Background: Clinicians are in search of suitable scaffold for Regenerative Endodontic Procedure (REP). Most commonly used scaffold in REP includes Blood Clot and Autologous Platelet Concentrates (APC) but the question of superiority of one over another is still inconclusive.

Aim: Comparative evaluation of outcome of REP using Platelet Rich Plasma (PRP) and Platelet Rich Fibrin (PRF) separately as scaffold in immature non vital teeth including quantitative assessment of root development among two groups through Radiographic Root Area (RRA).

Method: 20 anterior teeth in 15 patients were selected. 1.5% sodium hypochlorite and 17% ethylenediamine tetra acetic acid as irrigant and Calcium hydroxide as intracanal medicament were used. PRP & PRF were prepared from patients own blood. Equal number of teeth were chosen for these two scaffolds. Canals were then sealed by Biodentine & composite. Clinical and radiological follow up was done for 12-28 months to assess the outcome.

Statistical analysis: Data assessed by two evaluators was excellent ($\alpha=0.94$) and was subjected to chi square (χ^2) and Fisher exact test. Software -Epi Info(TM)7.2.2.2 was used.

Results: All the patients were asymptomatic. There was no significant difference in bony healing, percentage increase of lateral dentin thickening (calculated by RRA), root lengthening and apical closure of teeth of two groups. Three teeth in PRP group responded positive to pulp sensibility test by cold. Interestingly calcific bridge formation was seen in more number of cases in this group.

Conclusion: Both PRP & PRF have created effective scaffold for REP with greater chances of IntraCanal calcification in PRP group.

Key words: PRP, PRF, REP, Radiographic Root Area, Scaffold, Calcific bridge.

Date of Submission: 30-05-2021

Date of Acceptance: 13-06-2021

I. Introduction

Drawbacks of Calcium hydroxide ($\text{Ca}[\text{OH}]_2$) apexification and artificial apical barrier with Mineral Trioxide Aggregate / Biodentine; failing to complete root maturation and thus susceptibility for root fracture have led to emergence of Regenerative Endodontic Procedure (REP) as a promising alternative.

Thickening of root dentin, closure of apex, lengthening of remaining root and importantly filling the root canal system with a biologic tissue - all are achievable through REP and may allow retention of tooth for longer duration.^[1]

There are three pillars for the success of REP – stem cells, scaffold & growth factors. With suitable scaffold & growth factors^[2] the targeted stem cells are allowed to migrate, proliferate and differentiate to generate various tissues of periodontium and pulp-dentin complex.

Patient's intracanal blood clot as a source of scaffold and growth factor is suggested. Ease of operation, minimum armamentarium and no extra cost prompted its use^[3] but induction of bleeding upto cemento-enamel junction (CEJ) through over instrumentation was often seen to be difficult^[4] and also had possibility of damage to Hertwigs Epithelial Root Sheath hampering the process of root maturation.^[5]

Advent of platelet concentrate from patients own blood e.g. Platelet Rich Plasma (PRP), Platelet Rich Fibrin (PRF) opened a new horizon. Most active component of the patient blood sample contains high concentration of platelet granules which are rich with many substances fundamental to promote healing process including adhesive proteins, pro coagulant factors, cytokines, chemokines, antimicrobial proteins and a number of mitogenic growth factors such as Platelet derived Growth factor, Transforming Growth Factor-Beta,

Epidermal Growth Factor, Vascular Endothelial Growth Factor, important for angiogenesis and improve tissue vascularisation.^[6,7,8]

This attracted the clinicians to use PRP^[9] and PRF^[10] alone as scaffold in REP. Fibrin mesh of PRP is non elastic in nature with condensed tetramolecular bilateral junction, whereas it is elastic and dense with connected trimolecular equilateral junction in PRF.^[11] Because of the quality of the fibrin mesh the nature of release of the said bioactive molecules is different in both. Those are released faster – five to seven days with 80% in first day in PRP which shorten the wound healing period, whereas in PRF this release is sustained upto 14 days which is the time for tissue regeneration.^[12]

Attempts have been made to evaluate traditional REP (using Blood clot) in conjunction with PRP^[13] & PRF^[14] but issue remains unresolved. However there are studies which support that PRF is superior to PRP^[12] and vice versa.^[15] Thus judgement of superiority remains inconclusive.

Therefore the present clinical study is aimed to comparatively evaluate the outcome of REP in terms of healing of periapical lesion, percentage increase of lateral dentin thickening, root lengthening, apical closure and pulp sensibility using PRP and PRF separately as scaffold in ten cases each.

II. Materials And Methods

A total of 20 teeth in 15 healthy individuals (nine female and six male) aged between 8 to 28 years were selected from outpatient department of hospital. Ten teeth in eight patients were allocated for PRF scaffold and rest for PRP in different period of time. This research work was done for dissertation of post graduate of the institute under the guidance of same postgraduate teacher of the department. The study protocol was approved from Institutional Ethics Committee through letter approval no RADCH/IEC/28-11-2017 and RADCH/IEC/29-11-2018. Details of REP were explained to the patients & parents and informed consent was taken. After taking thorough history; all findings of clinical examination, radiograph and pulp sensibility test were recorded.

Selection criteria of their teeth were i) Pulp necrosis, in immature teeth with or without periapical lesion ii) Possibility of restoration (not requiring post & core) iii) No signs of - root fracture, active resorption, pathologic mobility or probing depth > 3mm.

History of trauma was common. Patients presented with tenderness, swelling, mobility and discharging sinus were noted.

Under Inj. 2% xylocaine with 1:100,000 adrenaline and rubber dam, access opening was done. Working length was determined radiographically. Gentle & limited amount of filing was done in order to dislodge & remove the biofilm by roughening the wall without widening the canal. Copious & gentle irrigation with 20ml of 1.5% sodium hypochlorite (Prime Dental Products, Mumbai, India) was done over a course of five minutes using side vented needle placing 1-2mm short of apex. This was followed by irrigation with 20mL of saline for a period of five minutes. The canal was dried with paper points. Ca(OH)₂ paste (Ultracal, Ultradent Products, Inc., South Jordan, USA) was introduced into the canal as intracanal medicament, which maintains the high alkaline pH for about 30days.^[16] The canal was sealed with three to four mm of Cavit (3M ESPE, St. Paul, Germany). The patient was dismissed for one to four weeks and asked to report whenever any symptom arises. In case of persistent infection, additional treatment time was given with same medicament.

On Second appointment teeth were re-accessed; Ca(OH)₂ was washed away through copious & gentle irrigation with 20ml of 17% ethylenediaminetetraacetic acid (EDTA) (Desmear, Ahmedabad, India) for five minutes. Then the canal was dried with paper points. Ten millimeter of whole venous blood was drawn from the patient's anticubital vein.

PRP was prepared as per following procedure.^[17] The drawn blood was transferred to a glass test tube containing anticoagulant 3.8% sodium citrate (Universal chemicals, Kolkata, India), centrifuged (Remi R8C, Remi Instruments, Mumbai, India) at 300 x g (1831 rpm) for five minutes. The separated plasma with buffy coat was transferred to other glass test tube discarding the layer of Red Blood Cells (RBCs) and subjected to second centrifugation at 700 x g (2797 rpm) for 17 minutes. The second spin separated PRP at the bottom (lower 1/3rd) and clear straw colored serum (Platelet Poor Plasma-, PPP) at the top (upper 2/3rd). Leaving aside the layers of PPP, the separated PRP was mixed well with 10% calcium chloride (Universal chemicals, Kolkata, India) for nullifying the effect of anticoagulant and activating the platelets. This was then collected in insulin syringe and injected into the root canal and allowed to clot in 10minutes.

As per the protocol suggested by Dohan et al^[11], PRF was prepared. Collected blood was transferred to a test tube, centrifuged (Remi R8C, Remi Instruments, Mumbai, India) at 400 x g (2114 rpm) for ten min. The middle layer of PRF was taken out using sterile tweezer leaving the top and bottom layers of plasma and RBC respectively and squeezed between gauge pieces and autologous fibrin membrane thus obtained was then pushed within the canal with help of hand plugger.

Three millimeter of Biodentine (Septodont Ltd., Saint Maur des Faussés, France) was placed over the scaffold followed by coronal restoration with composite.

The patients were recalled every three month. The teeth were assessed for clinical and radiographic

parameters set by American Association of Endodontics (AAE)^[18] to evaluate success of REP. Vitality test with cold (Endofrost, Coltene Whaledent, Langenau, Germany) and electric pulp test (EPT) (Confident Dental, Bangalore, India) was done. Periapical (PA) healing, apical closure/narrowing, root lengthening, dentinal wall thickening were noted. Dentinal thickening was calculated through Radiographic Root Area (RRA) as per Flakes method. It is the difference between total root area (bordered occlusally by mesial & distal CEJ and peripherally by Periodontal Ligament space) and the pulpal area (bordered by Root Canal space) in pre and last post op radiographs. By using Image J software (version 1.52a, National Institute of Health, USA) standardization of radiographs were done by TurboReg Pluggin tool followed by measurement of the areas by Polygon tool. Post op RRA – Pre op RRA/Pre op RRA $\times 100$ is percentage increase of RRA.^[19]

III. Statistical analysis

The entire procedure of assessment was done twice by two evaluators separately. Intra & interrater reliability evaluated by Cronbach alpha (α) test was found to be excellent ($\alpha=0.94$). Data thus obtained were evaluated statistically through chi square (χ^2) test and Fisher exact test (where χ^2 not applicable) using Software -Epi Info (TM) 7.2.2.2. $P<0.05$ was taken to be statistically significant.

IV. Results

All preoperative signs and symptoms were eliminated after intra canal medication.

Assessment of Root development-

Percentage increase of Lateral dentinal thickening calculated through RRA (Table 1, outline for RRA measurement shown only in tooth S.No 7 in both the groups- Fig 1 & 2) in PRP (mean – 8.86 ± 4.23) and in PRF (mean – 8.11 ± 3.18) was more or less equal and have no significant difference. ($P=0.66$) (Table 2)

Root lengthening (Table 1) was seen 70% in PRP (Fig 1: S.No 1,2,3,4, 6&7) and 50% in PRF (Fig 2: S.No 1,5 & 6) cases but this difference was not statistically significant. ($P=0.36$) (Table 2)

Apical closure was seen in same number of teeth (40%) in each group (Table 1 & 2, Fig 1: S.No 1,2,4&5 and Fig 2: S.No 1,5,6&7). In rest teeth the process of apical closure was seen to be in progress as the apical pulp space was observed to be gradually tapered. Also no statistical significant difference was seen in apical closure (Table 2) ($P=0.99$) among two groups.

Assessment of Periapical healing-

Patient to patient, size of Periapical lesion was different (Table 1) mean of which in cases with PRP (7.87 ± 2.75) was higher than in PRF (7.80 ± 1.93) but difference did not carry any statistical significance ($P=0.47$) (Table 2). Complete bony healing was seen in 87.5% of PRP and 70% of PRF cases and in the rest it is yet to complete with evidences of progressive healing. (Fig 1 & 2) The phenomenon of bony healing was seen to be more or less equally distributed in the two groups. (Table 1 & 2) ($P=0.37$)

Intra Canal Calcification (ICC)

ICC (Table 1) was seen in 60% cases in PRP (Fig 1: S.No 1,2,4,5,6&7) and 10% in PRF group (Fig 2: S.No 3). This difference was **statistically significant**. ($P=0.019$) (Table 2)

Response to Pulp Sensibility tests

Cold test of pulp sensibility was positive in three PRP (30%) cases (Table 1, Fig 1: S.No 2,4&5) and none in PRF. The result of Fisher Exact test showed no significant difference. However none of the case responded positively to EPT in both the groups.

Above findings were observed at minimum & maximum follow up period of 12 & 28 months respectively (Table 1). Though there was some difference in mean follow up period in two groups -- PRP (18.60 ± 2.83) & PRF (18.61 ± 5.08), but was statistically comparable. ($P=0.99$) (Table 2)

The difference of mean age between patients with PRP (13.83 ± 3.43) and PRF (16.71 ± 7.65) did not have any statistical significance ($P=0.17$). Also there was no significant difference ($P=0.83$) in gender distribution in between two groups (Table 2).

TABLE 1: OUTCOME OF REP IN BOTH THE GROUPS OF PRP & PRF

PRP Cases									
S. NO.	TOOTH NO.	AGE/SEX	PA LESION (mm x mm)	FOLLOW UP PERIOD (mon.)	BONY HEALING	APICAL CLOSURE	%↑ RRA	RL	PULP SENSIBILITY TEST (COLD)
1	22	17/M	13x10	18	*	*	14.46 ‡	YES	---
2	21	11/M	8x9	18	*	*	15.53 ‡	YES	YES
3	11	14/M	5x6	12	†	†	5.29	YES	---
4	11	12/F	4x5	20	*	*	5.43 ‡	YES	YES
5	21		6x10	20	*	*	8.31 ‡	---	YES
6	11	17/F	5x7	22	*	†	6.80 ‡	YES	---
7	21		3x4	22	*	†	14.36 ‡	YES	---
8	21	15/F	9x5	18	*	†	5.34	---	---
9	11	8/F	NO	18	---	†	5.34	---	---
10	21		NO	18	---	†	7.77	YES	---
PRF cases									
1	11	9/M	6x8	26	*	*	14.16	YES	---
2	21	15/F	7X4	18	*	†	12.04	---	---
3	22			18	*	†	10.14 ‡	---	---
4	21	28/F	10x12	12	†	†	4.01	---	---
5	22		6x7	12	*	*	5.79	YES	---
6	21	25/F	8x9	18	*	*	9.01	YES	---
7	21	10/M	5x7	18	*	*	6.64	--	---
8	11	11/M	8x9	18	*	†	5.34	YES	---
9	11	20/F	4x3	18	†	†	7.03	YES	---
10	21	14/F	7x8	28	†	†	7.01	---	---

* - COMPLETE, † - YET TO COMPLETE, RRA – RADIOGRAPHIC ROOT AREA, ‡ – INTRA CANAL CALCIFICATION, PA LESION- PERIAPICAL LESION, RL- ROOT LENGTHENING

TABLE 2: COMPARISON OF OUTCOME OF REP IN BOTH THE GROUPS OF PRP & PRF

S. NO	PARAMETERS		PRP (n=10)		PRF (n=10)		Statistical Significance§(P<0.05)
			Mean ± SD	Range	Mean ± SD	Range	
1	Age (yrs)		13.83±3.43	8- 17	16.71±7.65	9-28	$\chi^2=3.44; P=0.17$
2	sex	Male	3		3		$\chi^2=0.10; P=0.83$
		Female	4		5		
3	PA lesion size		7.87±2.75	4-13	7.80±1.93	4-12	$t_{16}=0.06; P=0.47$
4	Follow up period		18.60±2.83	12-22	18.61±5.08	12-28	$t_{18}=0.01; P=0.99$
5	Bony healing	Complete (*)	87.5%(7/8)		70%(7/10)		$\chi^2=0.78; P=0.37$
		Yet to complete(†)	12.5%(1/8)		30%(3/10)		
6	Apical closure	Complete (*)	40%(4/10)		40%(4/10)		$\chi^2=0.01; P=0.99$
		Yet to complete(†)	60%(6/10)		60%(6/10)		
7	%↑ RRA (Lateral Dentin Thickening)		8.86±4.23	5.29 - 15.53	8.11±3.18	4.01 - 14.16	$t_{18}=0.44; P=0.66$
8	Root lengthening (RL)		70%(7/10)		50%(5/10)		$\chi^2 =0.83; P=0.36$
9	Pulp sensibility test (cold)		30%(3/10)		---		Fisher exact test - NS
10	Intra canal calcifications (‡)		60%(6/10)		10%(1/10)		$\chi^2 =5.49; P=0.019$

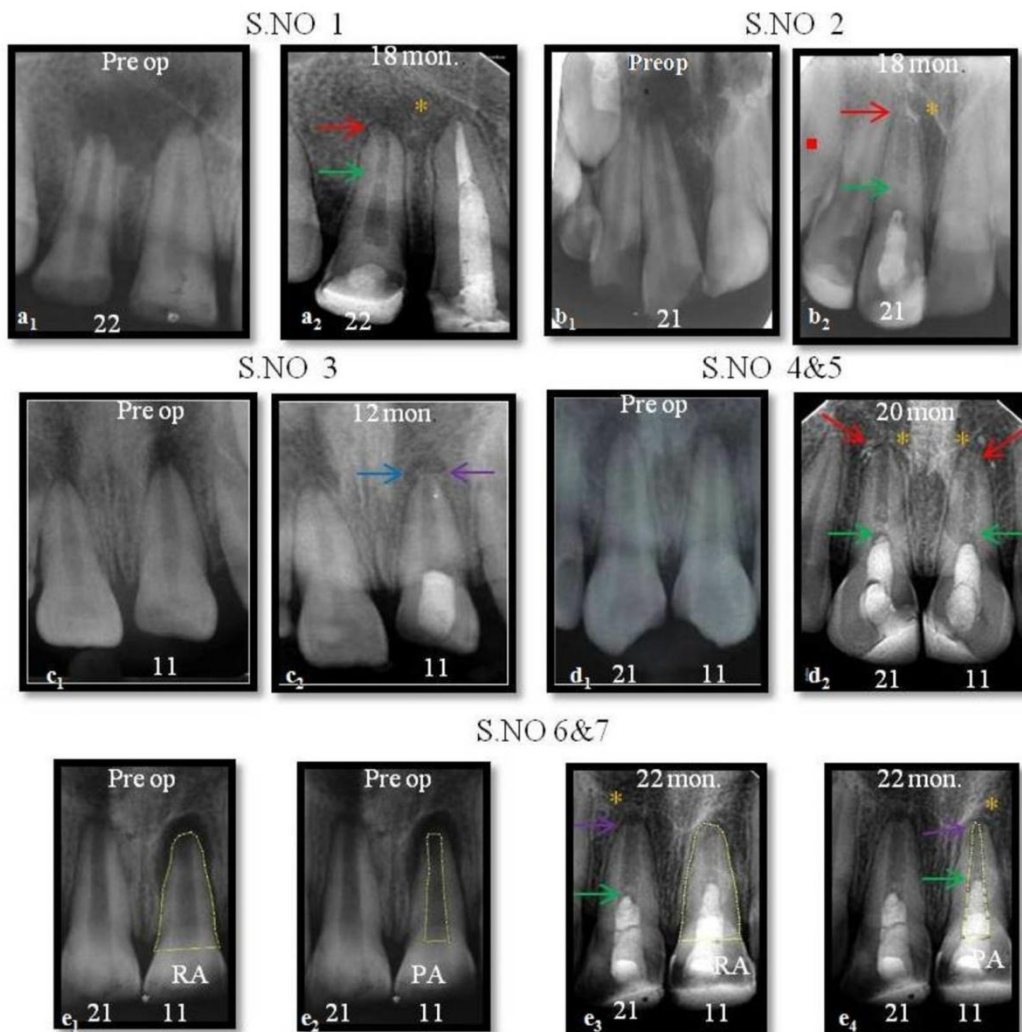


Fig 1: PRP CASES (S. NO. 1-7) Bony healing: complete (yellow asterisk), yet to complete (blue arrow).apical closure: complete (red arrow), yet to complete (purple arrow), intracanalcalcification (green arrow). RRA measurement -s.no.7. RA (Root Area) - e₁&e₃, PA (Pulpal Area) - e₂&e₄

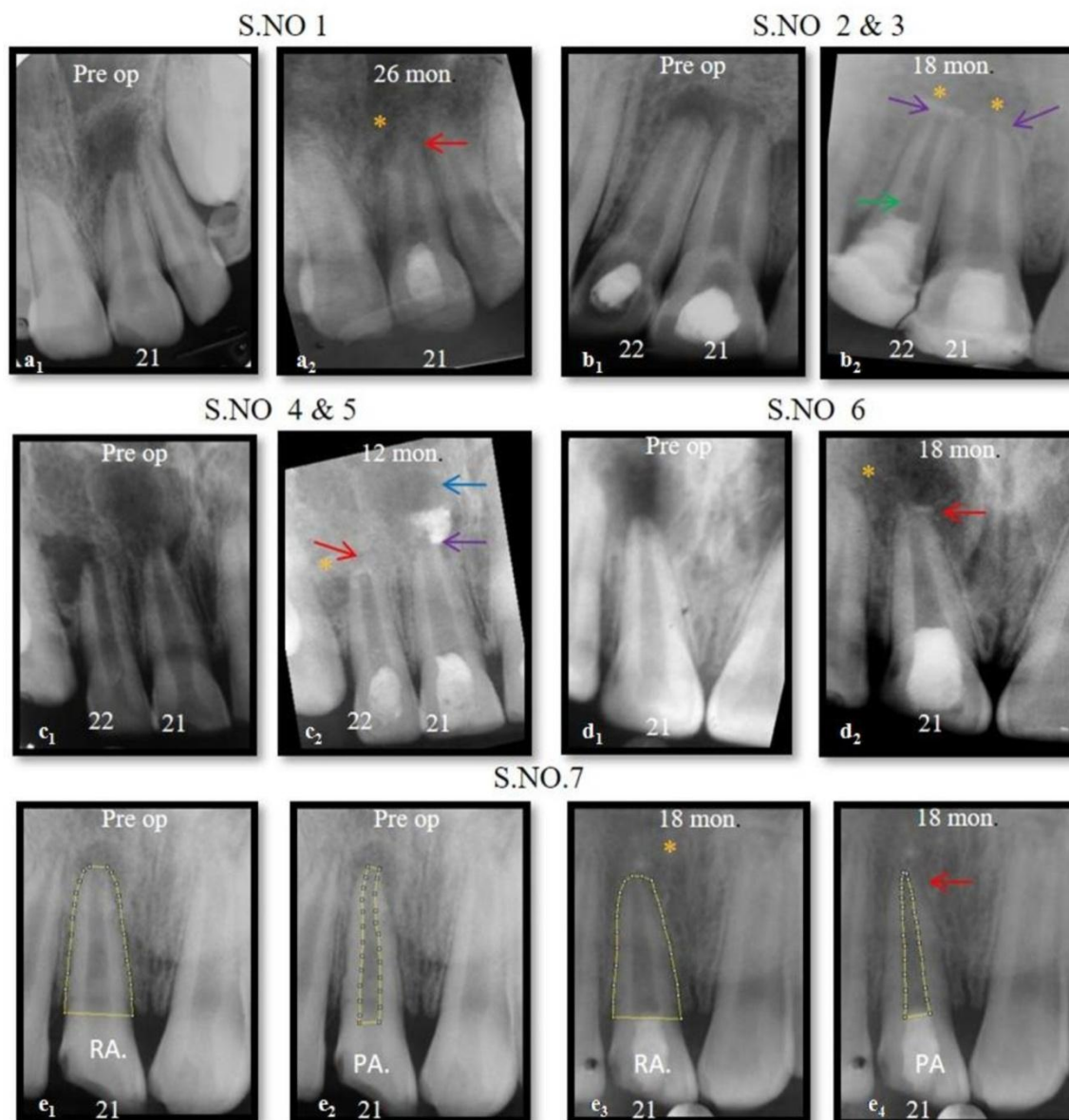


Fig 2: PRF CASES (S. NO. 1-7) Bony healing: complete (yellow asterisk), yet to complete (blue arrow). apical closure: complete (red arrow), yet to complete (purple arrow), intracanal calcification (green arrow). RRA measurement -s.no.7. RA (Root Area) - e₁&e₃, PA (Pulpal Area) - e₂&e₄

V. Discussion

Various scaffolds^[3,9,10] have been used in REP but superiority of one over other is still a matter of debate. Blood Clot being most commonly used but as it is difficult to evoke bleeding in some cases and due to lesser amount of growth factors in induced blood, alternative to it is platelet concentrate. PRP and PRF being most commonly used platelet concentrates, were chosen for the present study. Some previous studies have compared outcome of REP using PRP and PRF^[12, 15, 20, 21, 22] but except 1 study^[22] most of them utilized either scoring criteria for assessment or linear parameters.

In the present study RRA was used to measure the planar area of roots rather than linear dimensions of the roots. Previous study by Ulusoy et al^[22] also showed that RRA measurements offer a higher level of sensitivity to detect minor dimensional changes, which were not detected by conventional linear measurements.

The mean percent increase of RRA in PRP cases is almost close to that in study of Bezgin et al 2015¹ (9.86%, in comparable period of follow-up) and Ulusoy et al 2019^[22] (9.53±2.17), while the later study reported 6.93±1.44 mean percent increase of RRA in PRF group in contrast to the present study. Outcome analysis in regard to bony healing, root lengthening showed some differences between the two groups but without any statistical significance. Status of apical closure in said mean follow up period was observed to be same. Thus two platelet concentrates were comparable in bony healing and continued root development.

Intra canal calcification is a major concern seen in many cases of REP which will adversely affect future treatment if required. Selection of scaffold might affect occurrence of ICC after REP. None of the previous study compared occurrence of ICC among these two platelet concentrates. In the present study, at above specified followup period, occurrence of more number of ICC was associated with PRP group. In some cases it was seen in the form of calcific bridge close to bioceramic. ICC is regarded as healing outcome, not a diseased state. Trauma causing pulpal necrosis and use of Ca(OH)₂ may be contributing factors. Its various types including complete canal obliteration have been reported^[23], but later is not desirable. Effect and extent of the calcification can only be discernible in present case series at later date.

There are studies^[9,10] showing positive response to vitality testing. Pulp sensibility test which was positive in 3 teeth (30%) in PRP group on application of cold and non responsive to EPT when compared with total number of cases, it appeared to be statistically insignificant. The presence or absence of response depends on the coronal extent of the tissue. Also, thick layers of restorative materials, given to prevent coronal leakage, may also hamper the response to any stimuli.

Irrigation protocol suggested by AAE^[18] was followed. Ca(OH)₂ was used as intracanal medicament since it has no detrimental effect on SCAP (Stem Cells from Apical Papilla) at any concentration. The safe recommended concentration of Triple Antibiotic Paste (TAP) - 0.001 to 0.01^[24] / 1-5 mg/ml^[18] cannot be achievable clinically. Moreover, previous study^[25] have reported that 80% of TAP remain tightly bound to dentin to depths >350 mm. Conversely, up to 98% of Ca(OH)₂ can be removed and remaining Ca(OH)₂ was found within 50 mm of dentin.^[25]

Relative centrifugal force (RCF) is preferred parameter over speed (revolutions per minute- rpm) to determine protocol for preparation of PRP and PRF as different centrifuge machine will generate different RCF depending on radius of the rotor of the machine while working on same speed. During centrifugation, separation of different phases occur due to application of force i.e. RCF and it is expressed as multiples of the earth's gravitational field (g). It is dependent on the radius of the rotor (from centre of rotor to sample) and the speed of the centrifuge (rpm)^[26]

Procedure for PRP preparation was according to Amable et al.^[17] This protocol included first spin at 300 x g for five min and second spin at 700 x g for 17 min. This lead to 5.4-fold to 7.3-fold increase in platelet concentration (1.4×10⁶ to 1.9×10⁶ platelets/μl) and normal platelet counts in blood range between 1.5 x10⁵ platelets/μl - 3.5 x10⁵ platelets/μl and average about 2 x10⁵ platelets/μl. Also this protocol was in accordance to Marx et al^[27] which proposed platelet count of 1×10⁶ platelets/μl in 5 mL of PRP, as a working definition of PRP based on the scientific proof of bone and soft tissue healing. For preparation of PRF, most commonly used protocol of Dohan et al^[11] (400xg force for 10 min) was followed in the present study.

Age of the patients was statistically comparable though three patients in PRF were above adolescence. Role of viable Mesenchymal Stem Cells (MSC's) like Periodontal ligament Stem Cells (PDLSCs) and Bone Marrow Stem Cells (BMSCs) for successful REP in adults were kept in mind during the study.^[28]

VI. Limitations of the present study

1. Short follow up period: Maximum followup could be done for 22 months in PRP study group and for 28 months in the study of PRF group. Patient follow up of at least four to five years is necessary to come to a definite conclusion with regard to the criteria given by AAE & ESE (European Society of Endodontology).
2. Angulation differences in radiographs: Though standardization of radiographs was done using suitable software, exact duplication of images of a tooth may not have been possible due to chances of change of angulation in subsequent radiograph.
3. Use of 2D imaging modality to assess the outcome: Accurate assessment can only be done through use of three dimensional imaging eg Cone Beam Computed Tomography (CBCT) which was not done in the present study.

VII. Conclusion

Within the limitation of this clinical study, it can be concluded that treatment outcome did not differ significantly with PRP and PRF. Both has created effective scaffold for REP but PRP has significantly higher chances of ICC than PRF. Further research is required to find out the cause, nature and patterns of these calcification. Also long term follow up is required to assess variation in calcification among two groups to reach to a definite conclusion.

References

- [1]. Bezgin T, Yilmaz AD, Celik BN, Kolsuz ME, Sonmez H. Efficacy of platelet rich plasma as a scaffold in Regenerative Endodontic Treatment. J Endod 2015;41:36-44
- [2]. Hargreaves KM, Diogenes A, Teixeira FB. Treatment options: Biological basis of regenerative endodontic procedures. J Endod 2013;39 (Suppl 3):S30-43
- [3]. Banchs F, Trope M. Revascularization of immature permanent teeth with apical periodontitis: new treatment protocol? J Endod 2004;30:196-200

- [4]. Nosrat A, Homayounfar N, Oloomi K. Drawbacks and unfavorable outcomes of regenerative endodontic treatments of necrotic immature teeth. A literature review and report of a case. *J Endod* 2012;38:1428-34.
- [5]. Xu L, Tang L, Jin F, Liu X, Yu J, Wu J, et al. The apical region of developing tooth root constitutes a complex and maintains the ability to generate root and periodontium-like tissues. *Journal of Periodontal Research* 2009; 44: 275-282.
- [6]. Alessandra Lolato, Cristina Bucchi, Silvio Taschieri, Ahmed El Kabbaney & Massimo Del Fabbro. Platelet concentrates for revitalization of immature necrotic teeth. A systematic review of the clinical studies. *Platelets* 2016; 27(5): 383-392.
- [7]. Marx RE, Carlson ER, Eichstaedt RM, Schimmele SR, Strauss JE, Georgeff KR. Platelet-rich plasma: growth factor enhancement for bone grafts. *Oral Surg Oral Med Oral Pathol Oral Radiol Endod* 1998; 85: 638-46.
- [8]. Lucarelli E, Beretta R, Dozza B, Tazzari PL, O'Connell SM, Ricci F, et al. A recently developed bifacial platelet rich fibrin matrix. *Eur Cell Mater* 2010; 20:13-23.
- [9]. Torabinejad M, Turman M. Revitalization of Tooth with Necrotic Pulp and Open Apex by Using Platelet-rich Plasma: A Case Report. *J Endod* 2011; 37:265-8.
- [10]. Keswani & Pandey. Revascularization of an immature tooth with a necrotic pulp using platelet rich fibrin: A case report. *Int Endod J* 2013;46:1096-1104.
- [11]. Dohan D, Choukroun J, Diss A, Dohan SL, Dohan AJ, Mouhy J, et al. Platelet-rich fibrin (PRF): A second-generation platelet concentrate. Part I: Technological concepts and evolution. *Oral Surg Oral Med Oral Radiol* 2006; 101:37-44.
- [12]. Narang I, Mittal N, Mishra N. A comparative evaluation of the blood clot, platelet-rich plasma and a platelet-rich fibrin in regeneration of necrotic immature permanent teeth: A clinical study. *Contemp Clin Dent* 2015;6:63-68
- [13]. Jadhav GR, Shah N, Logani A. Comparative outcome of revascularization in bilateral, non-vital, immature maxillary anterior teeth supplemented with or without platelet rich plasma: A case series. *J Conserv Dent* 2013;16:568-72
- [14]. Bakhtiar H, Esmaeili S, Fakhr Tabatabayi S, Ellini MR, Nekoofar MH, Dummer PM. Second-generation Platelet Concentrate (Platelet-rich Fibrin) as a Scaffold in Regenerative Endodontics: A Case Series. *J Endod* 2017; 43: 401 – 408
- [15]. Shivashankar VY, Antony Johns D, Maroli R K, Sekar M, Chandrasekaran R, Karthikeyan S, et al. Comparison of the Effect of PRP, PRF and Induced Bleeding in the Revascularization of Teeth with Necrotic Pulp and Open Apex: A Triple Blind Randomized Clinical Trial. *Journal of Clinical and Diagnostic Research* 2017; 11: ZC34-ZC39
- [16]. Zmener O, Pameijer CH, Banegas G. An invitro study of three calcium hydroxide dressing materials. *Dent. Traumatol* 2007; 23: 21-25
- [17]. Amable PR, Carias RB, Teixeira MV, da Cruz Pacheco I, Corrêa do Amaral RJ, Granjeiro JM, et al. Platelet-rich plasma preparation for regenerative medicine: Optimization and quantification of cytokines and growth factors. *Stem Cell Res Ther* 2013;4:67.
- [18]. American Association of Endodontics. Clinical considerations for a regenerative procedure. Available at: www.aae.org. Accessed 4/1/2018.
- [19]. Flake NM, Gibbs JL, Diogenes A, Hargreaves KM, Khan AA. A standardized novel method to measure radiographic root changes after endodontic therapy in immature teeth. *J Endod* 2014;40:46-50
- [20]. Murray PE. Platelet-Rich Plasma and Platelet-Rich Fibrin Can Induce Apical Closure More Frequently Than Blood-Clot Revascularization for the Regeneration of Immature Permanent Teeth: A Meta-Analysis of Clinical Efficacy. *Front Bioeng Biotechnol*. 2018; 6:139.
- [21]. Rizk H.M, Salah Al-Deen MSM, Emam AA. Comparative evaluation of Platelet Rich Plasma (PRP) versus Platelet Rich Fibrin (PRF) scaffolds in regenerative endodontic treatment of immature necrotic permanent maxillary central incisors: A double blinded randomized controlled trial. *Saudi Dental Journal* 2019; 32(5):224-31
- [22]. Ulusoy AT, Turedi I, Cimen M, Cehreli ZC. Evaluation of Blood Clot, Platelet-rich Plasma, Platelet-rich Fibrin, and Platelet Pellet as Scaffolds in Regenerative Endodontic Treatment: A Prospective Randomized Trial. *J Endod* 2019; 45: 560 – 56
- [23]. Song M, Cao Y, Shin SJ, Shon WJ, Chugal N, Kim RH et al. Revascularization-associated Intracanal Calcification: Assessment of Prevalence and Contributing Factors. *J Endod* 2017; 43: 2025 – 2033
- [24]. Diogenes A, Ruparel N., Teixeira F., Hargreaves K. Translational Science in Disinfection for Regenerative Endodontics. *J Endod* 2014; 40(Suppl 4): 52-57
- [25]. Berkhoff J, Chen PB, Teixeira FB, Diogenes A. Effective removal of triantibiotic paste during regenerative endodontic treatment: an evaluation of different irrigation procedures. *J Endod* 2013;39:e15
- [26]. Dhurat R, Sukesh M. Principles and Methods of Preparation of Platelet-Rich Plasma: A Review and Author's Perspective. *J Cutan Aesthet Surg*. 2014;7(4):189-97.
- [27]. Marx RE. Platelet-rich plasma (PRP): What Is PRP and What Is Not PRP? *Implant Dent* 2001;10:225-8
- [28]. Paryani K., Kim S.G. Regenerative endodontic treatment of permanent teeth after completion of root development: A report of 2 cases. *J Endod* 2013; 39: 929-934

Dr Haridas Das Adhikari, et. al. "Comparative evaluation of Platelet Rich Plasma and Platelet Rich Fibrin as a scaffold for Regenerative Endodontic Procedure: A Clinical study." *IOSR Journal of Dental and Medical Sciences (IOSR-JDMS)*, 20(06), 2021, pp. 51-58.