

Non-Metastatic Squamous Cell Carcinoma of the Eyelid

IMAD LIDYA, KAOUTAR NAYA, LOUAI SERGHINI, AMINA BERRAHO.

Corresponding author: IMAD LIDYA

Department of Ophthalmology B, Hospital of Specialties, University Mohammed V, CHU Ibn Sina, 10000 Rabat, Morocco.

Date of Submission: 14-07-2021

Date of Acceptance: 30-07-2021

I. Manuscript

A 55-year-old man was referred for growing lesions on his left eyelid for several years. The patient had not seen a physician during the progression of the disease.

On admission, a large ulcerated lesion was seen on his left upper eyelid (Figur.1).

Ophthalmologic examination objective a 10/10 visual acuity bilaterally. Ocular tone was normal in both eyes.

Slit lamp examination showed no abnormalities in the anterior segment and fundus.

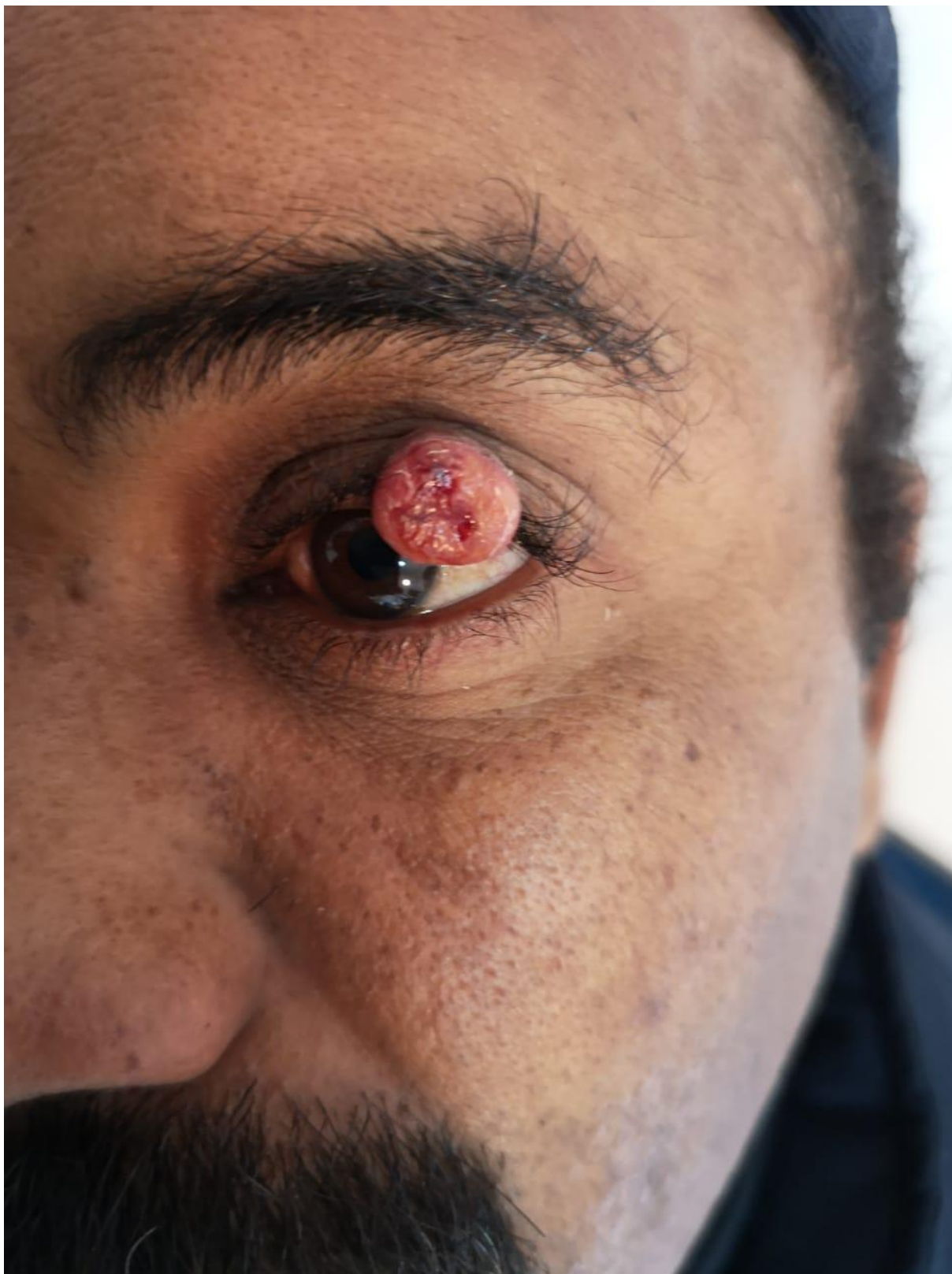Cerbro-orbital imaging showed no loco regional invasion; extension workup for secondary locations was unremarkable.

A fine needle biopsy of the lesion was performed.

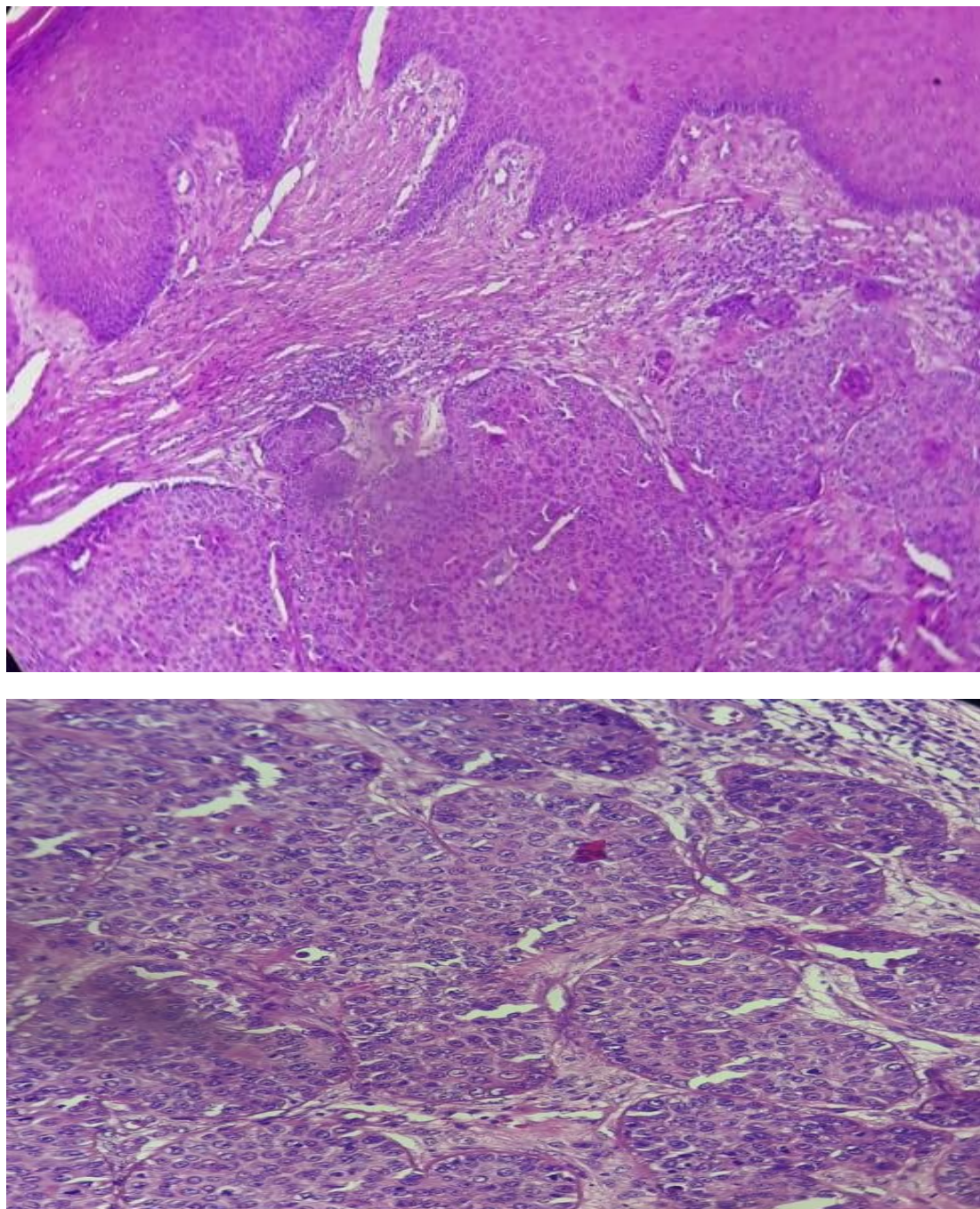
Histopathological evaluation of the eyelid lesion revealed a well-differentiated squamous cell carcinoma.

The patient will benefit from a surgical removal with palpebral reconstruction.

« Declaration of interests:the authors declare that they have no interests in relation to this article».



Figur 1. A large squamous cell carcinoma of the left upper eyelid. Informed consent was obtained from the patient for publication of this figure.



Figur 2. Image showing the histological appearance of well-differentiated, infiltrating squamous cell carcinoma. (Magnification x 10; x 40)

IMAD LIDYA, et. al. " Non-Metastatic Squamous Cell Carcinoma of the Eyelid." *IOSR Journal of Dental and Medical Sciences (IOSR-JDMS)*, 20(07), 2021, pp. 41-43